

# Potential role of serum amyloid A in hidradenitis suppurativa



Michela Iannone, MD,<sup>a</sup> Teresa Oranges, MD,<sup>a,b</sup> Andrea Chiricozzi, MD,<sup>a</sup> Vincenzo De Tata, PhD,<sup>c</sup> Marco Romanelli, MD, PhD,<sup>a</sup> and Valentina Dini, MD, PhD<sup>a</sup>  
Pisa and Florence, Italy

**Key words:** amyloidosis; antibiotics; biomarker; clindamycin; hidradenitis suppurativa; rifampicin; serum amyloid A.

## INTRODUCTION

Hidradenitis suppurativa (HS) is a chronic relapsing inflammatory skin disease, characterized by recurrent and painful nodules, abscesses, and sinus tracts involving the hair follicle.<sup>1</sup> HS has been related to various cutaneous and systemic complications, such as chronic pain, anemia, lymphedema, and amyloid A (AA) amyloidosis, with a significant reduction in the patient's quality of life.<sup>1</sup>

AA amyloidosis in HS has been rarely reported<sup>2-9</sup>; however, AA amyloidosis related to other chronic inflammatory diseases has been well described. The deposition of AA may induce damage to viscera, connective tissue, and blood vessel walls, with the kidney as a major target. AA amyloidosis has been detected in a subclinical phase in some reports. An early detection of AA fibrils and a prompt systemic treatment of inflammation can stop the long-term deposition of AA and prevent related complications.<sup>10</sup>

## CASE REPORT

We assessed a 73-year-old man presenting with Hurley II HS. He had a history of well-controlled type 2 diabetes, hypothyroidism, and acute myocardial infarction. The disease duration was 51 years, with a worsening of clinical features over the last 3 years. The patient had been using short-term antibiotic therapies.

Physical examination found nodules and abscesses in axillae, inguinal areas (Fig 1), perineal region, back, and chest. Laboratory tests found a

### Abbreviations used:

AA: amyloid A  
HS: hidradenitis suppurativa  
SAA: serum amyloid A

high serum level (168  $\mu\text{g}/\text{mL}$ ) of acute-phase reactant serum amyloid A (SAA) compared with normal range from 0 to 6.4  $\mu\text{g}/\text{mL}$ , normal creatinine clearance (63 mL/min), no urinary proteinuria (<150 mg/24 h), glycated hemoglobin (<7%), and microalbuminuria (280 mg/24 h).

Considering the very high serum level of SAA as an inflammatory marker, we decided to investigate by performing a biopsy from abdominal adipose tissue stained with Congo-red–based light microscopy, which yielded a negative result. We used immunoelectron microscopy of abdominal fat, which showed perivascular fibril deposits, marked as AA fibrils using gold-labeled Immunogold secondary antibodies (Fig 2, A). This was a case of subclinical AA amyloidosis, with false-negative response to Congo-red–based light microscopy caused by scanty and unevenly distributed amyloid deposits. The detection of a high serum level of SAA was key in the decision to obtain a prompt diagnosis and start systemic treatment that could provide a rapid improvement.

We treated the patient with clindamycin, 600 mg/d, and rifampicin, 600 mg/d, for 12 weeks. We achieved a good response with improvement in skin lesions, reduction of SAA (8  $\mu\text{g}/\text{mL}$ ), and

From the Departments of Dermatology<sup>a</sup> and Translational Research on New Technologies in Medicine and Surgery,<sup>c</sup> University of Pisa and the Department of Health Sciences, Anna Meyer Children's University Hospital, University of Florence.<sup>b</sup>

Funding sources: None.

Conflicts of interest: None disclosed.

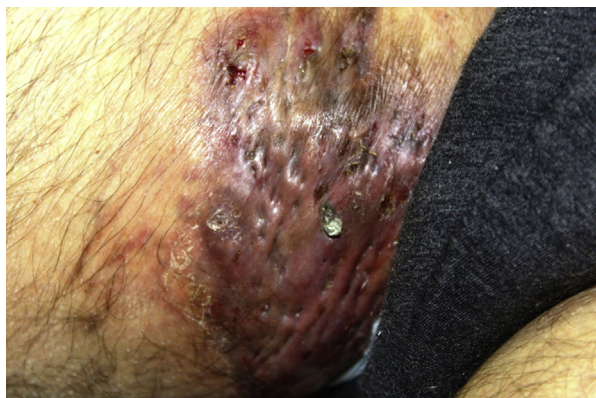Correspondence to: Michela Iannone, MD, Department of Dermatology, University of Pisa, Via Roma, 67 56126, Pisa, Italy. E-mail: [drmichelaiannone@gmail.com](mailto:drmichelaiannone@gmail.com).

JAAD Case Reports 2019;5:406-9.

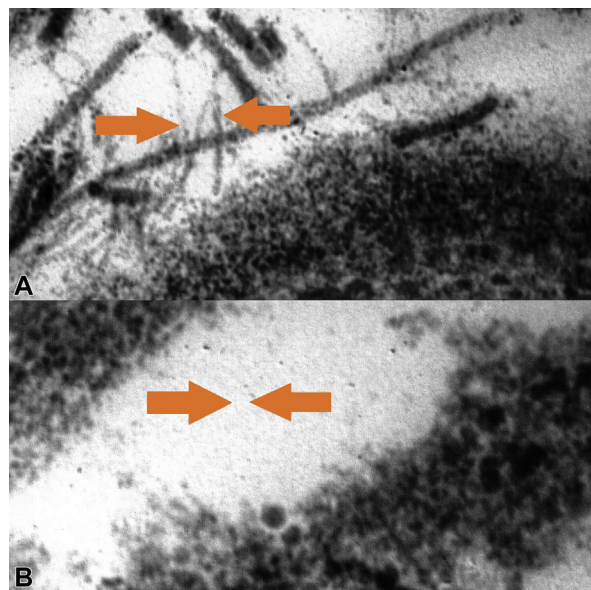
2352-5126

© 2019 by the American Academy of Dermatology, Inc. Published by Elsevier, Inc. This is an open access article under the CC BY-NC-ND license (<http://creativecommons.org/licenses/by-nc-nd/4.0/>).

<https://doi.org/10.1016/j.jidcr.2019.02.026>



**Fig 1.** In a patient with HS, infiltrated inflammatory plaque affecting inguinal area.



**Fig 2.** **A**, Chains, not branched, marked by gold-labeled Immunogold secondary antibodies on abdominal fat biopsy with amyloid ultrastructure in an HS patient before treatment. **B**, Absence of amyloid A chain on abdominal fat biopsy in the patient after treatment. (Electron microscopy; original magnifications: **A**,  $\times 70$ ; **B**,  $\times 100$ .)

reduction in AA fibrils in abdominal fat (Fig 2, B). We repeated SAA after 3 months (last follow-up) when it was in the normal range ( $5.3 \mu\text{g/mL}$ ). Clinical follow-up showed a disease-remission phase with cordlike scars, bridging scars, hyperpigmented atrophic scars, fibrotic plaques, and one isolated active nodule.

Because systemic diseases are known to be associated with elevated SSA, we evaluated all the comorbidities of the patient's medical history, but the episode of acute myocardial infarction occurred more than 5 years before SAA elevation without dysfunctional complications. Diabetes was well

under control as shown by the glycated hemoglobin values, so the only disease in acute phase at the time of our evaluation was HS, and the reduction in SAA after treatment reinforced our hypothesis that the elevated SAA is related to hidradenitis and not to the patient's comorbidities.

## DISCUSSION

We found eight cases reported in the literature on amyloidosis and HS in the last decades<sup>2-9</sup> (Table D); none of the patients had presented with subclinical amyloidosis. All patients were between 39 and 62 years and had chronic HS of variable duration, from 3 to 25 years. Previous treatments were also very heterogeneous. Clinical presentation of AA amyloidosis was characterized by nephrotic proteinuria or nephritic syndrome. In all 8 cases, AA deposits were confirmed by kidney or colon biopsies.

Assigned therapies were very heterogeneous. Two patients showed an improvement in renal function in 4 to 14 weeks of treatment with infliximab ( $5 \text{ mg/kg}$ )<sup>4,9</sup>; one patient showed an improvement in renal function after 24 weeks of clindamycin,  $600 \text{ mg/d}$ , and prednisone,  $50 \text{ mg/d}$ ,<sup>7</sup> another patient showed a systemic improvement after treatment with adalimumab and fludrocortisone.<sup>5</sup> All the other patients had kidney failure.<sup>2-8</sup>

A literature review on AA amyloidosis found that more effective therapeutic control of inflammatory activity in patients with subclinical amyloidosis could prevent evolution of disease. No precise data are available on the role of SAA in subclinical amyloidosis, but, in patients with symptomatic AA amyloidosis, outcome is favorable when the SAA concentration is maintained below  $10 \text{ mg/L}$ .<sup>10</sup>

HS should be managed as a chronic inflammatory systemic disease. As in several chronic inflammatory diseases, there may be damage to internal organs from the aggregation and deposition of fibrils originating from proteolytic fragments of SAA, produced by the liver in response to chronic inflammation. To avoid severe complications, we recommend a careful survey of adult patients with moderate-to-severe HS and clinical duration of greater than 3 years including workup to detect serum levels of SAA. We also recommend more effective anti-inflammatory treatment in patients with elevated SAA, maintaining SAA levels less than  $10 \text{ mg/L}$ .

Since high serum levels of SAA could be predictive of a severe complication such as AA amyloidosis and no studies are available to date, clinicians should consider further research to establish whether this association can be verified at the population level

**Table I.** Literature data report on HS and amyloidosis

Study	Age of patient (y)	HS duration (y)	Previous therapies	Comorbidities	Localization	Clinical amyloid-osis presentation	Detection of amyloid deposits	Assigned therapy	Outcome
Titze et al <sup>2</sup>	62	25	NR	Coronary heart disease, hypertension, hypercholesterolemia	Axillae, inguinal areas, perineal area	Nephrotic syndrome, diarrhea	Colon biopsy	Ramipril, diuretics, cefuroxime	Kidney failure
Caliskan et al <sup>3</sup>	44	NR	None	None	Axillae, inguinal areas, perianal area	Nephrotic proteinuria	Kidney biopsy	Ramipril, colchicine	Kidney failure
Montes-Romero et al <sup>4</sup>	39	9	Antiandrogens, topical and systemic antibiotics, isotretinoin	Hypothyroidism	Axillae, perineal area, scrotum, Perianal area	Nephrotic proteinuria	Kidney biopsy	Infliximab	Improvement in 14 wks
Girouard et al <sup>5</sup>	39	21	Infliximab, surgery Systemic tetracycline, linezolid and clindamycin	NR	NR	Nephrotic proteinuria	Kidney biopsy	Adalimumab and fludrocortisone	Improvement
Ilgen et al <sup>6</sup>	42	3	Topical steroids, topical keratolytics, systemic roxithromycin, rifampicin and clindamycin	None	Axillae, inguinal areas, perineal area, perianal area	Nephrotic syndrome	Perineal skin biopsy Kidney biopsy	Colchicine	Kidney failure
Utrera-Busquets et al <sup>7</sup>	37	16	Systemic antibiotics, antiandrogens, dapsona, prednisone, infliximab, methotrexate, adalimumab	Graves disease, obesity	Axillae, inguinal areas, gluteal area	Nephrotic syndrome	Renal biopsy	Allopurinol, furosemide, sodium bicarbonate, lanthanum carbonate, systemic prednisone and clindamycin, surgery	Improvement in 24 wks

Schandorff et al <sup>8</sup>	54	8	Long-term systemic tetracycline, systemic rifampicin and clindamycin	None	Anogenital region, inguinal areas	Kidney failure	Renal biopsy	Acitretin, prednisolone, adalimumab, anakinra, surgery	Kidney failure
Özer et al <sup>9</sup>	43	11	Systemic antibiotics and steroid injections	None	Axillae, inguinal areas	Nephrotic proteinuria	Renal biopsy	Infliximab	Improved in 4 wks

NR, Data not reported.

and what its clinical significance is in hidradenitis patients.

#### REFERENCES

1. Oranges T, Dini V, Chiricozzi A, Panduri S, Romanelli M. Complications. In: John Wiley and Sons, ed. *Hidradenitis suppurativa: a diagnostic atlas*. Hoboken, NY: Wiley; 2017: 65-68.
2. Titze J, Schneider M, Krause H, et al. Diarrhea, nephrotic syndrome and hidradenitis suppurativa: an unusual case. *Nephrol Dial Transplant*. 2003;18:192-194.
3. Caliskan Y, Yazici H, Kucuk M, et al. Nephrotic syndrome associated with hidradenitis suppurativa. *Clin Nephrol*. 2005; 63:171-172.
4. Montes-Romero JA, Callejas-Rubio JL, Sánchez-Cano D, et al. Amyloidosis secondary to hidradenitis suppurativa. Exceptional response to infliximab. *Eur J Intern Med*. 2008;19:32-33.
5. Girouard SD, Falk RH, Rennke HG, et al. Hidradenitis suppurativa resulting in systemic amyloid A amyloidosis: a case report and review of the literature. *Dermatol Online J*. 2012; 18(1):2.
6. Ilgen U, Çelebi ZK, Kuzu I, et al. Renal amyloidosis secondary to hidradenitis suppurativa. *Clin Kidney J*. 2013;6:667-668.
7. Utrera-Busquets M, Romero-Maté A, Castaño Á, et al. Severe hidradenitis suppurativa complicated by renal AA amyloidosis. *Clin Exp Dermatol*. 2016;41:287-289.
8. Schandorff KD, Miller IM, Krustup D, et al. Renal amyloid A amyloidosis as a complication of hidradenitis suppurativa. *Clin Nephrol*. 2016;86:51-54.
9. Özer İ, Karaçin C, Adışen E, et al. Two diseases one remedy? Systemic amyloidosis secondary to hidradenitis suppurativa: Treatment with infliximab. *Dermatol Ther*. 2017;30(2). <https://doi.org/10.1111/dth.12445>.
10. Obici L, Merlini G. AA amyloidosis: basic knowledge, unmet needs and future treatments. *Swiss Med Wkly*. 2012;142: w13580.