

Vegetative chronic genital herpes with satisfactory response to imiquimod*

Stella Meireles Siqueira¹, Bruna Barroso Gonçalves¹, Julia Bozetti Loss¹, Rogerio Ribeiro Estrella¹

DOI: <http://dx.doi.org/10.1590/abd1806-4841.20198014>

Abstract: Vegetative chronic genital herpes is an atypical presentation of herpes simplex 2 that it is usually seen in patients coinfecting with human immunodeficiency virus. Clinically, it is characterized by extensive ulcers that evolve to chronification and hypertrophic pseudotumor forms. Antiviral drugs are recommended for the treatment, and acyclovir is the most used one. Foscarnet is the treatment of choice to resistant cases, although treatment failure has been reported. We report a male patient, previously diagnosed with human immunodeficiency virus who developed vegetative chronic genital herpes resistant to acyclovir and successfully treated with imiquimod.

Keywords: Antiviral agents; Drug therapy; Efficacy; Herpes genitalis; Herpes simplex; Therapeutics

INTRODUCTION

Genital herpes is one of the most prevalent sexually transmitted diseases in the world. It is caused by the herpes simplex virus (HSV). The disease can be asymptomatic or present itself with different clinical features. HSV-2 is the most common serotype associated to genital herpes. Clinically, it can vary from erosive balanitis to vulvitis or painful vaginitis.¹

A large number of recurrences and atypical presentations of HSV skin lesions have been reported in individuals coinfecting with human immunodeficiency virus (HIV). In contrast, HSV infection increases the risk of HIV transmission and disease progression. Genital herpes ulcers can be larger in these patients and, in rare cases, it can become hypertrophic and vegetative.²

Vegetative chronic genital herpes is difficult to treat. Some reports reveal no response or several recurrence cases after treat-

ment with antiviral drugs.² We report a case of a male patient infected with HIV presented with vegetative chronic genital herpes successfully treated with imiquimod.

CASE REPORT

A 41-year-old Caucasian male patient diagnosed with acquired immunodeficiency syndrome three years ago, using Lopinavir/Ritonavir and maintaining an undetectable viral load presented with ulcerative and vegetative skin lesion on the body of the penis for five months. The lesion started small and grew progressively (Figure 1). A skin biopsy was performed three months before, and histopathological examination suggested chronic herpes. The patient was treated with oral acyclovir for 7 days. Due to the lack of response, he was hospitalized and was started on IV acyclovir,

Received 20 December 2017.

Accepted 25 April 2018.

* Work conducted at the Hospital Universitário Antônio Pedro, Universidade Federal Fluminense, Niterói (RJ), Brazil.
Financial support: None.
Conflict of interest: None.

¹ Dermatology Service, Universidade Federal Fluminense, Niterói (RJ), Brazil

MAILING ADDRESS:

Stella Meireles Siqueira

E-mail: stellamsiqueira@gmail.com

©2019 by Anais Brasileiros de Dermatologia



but also showed no response after 14 days. A new biopsy was performed and immunohistochemical study was positive for HSV-1 and HSV-2, confirming the diagnosis of conic herpes. We opted for topical treatment with imiquimod 5% cream 3 times a week during 2 weeks. Because of the patient's good tolerance and favorable response to the drug (Figure 2), we increased dosage to 5 times a week for 4 more weeks and application under occlusion. After 12 weeks

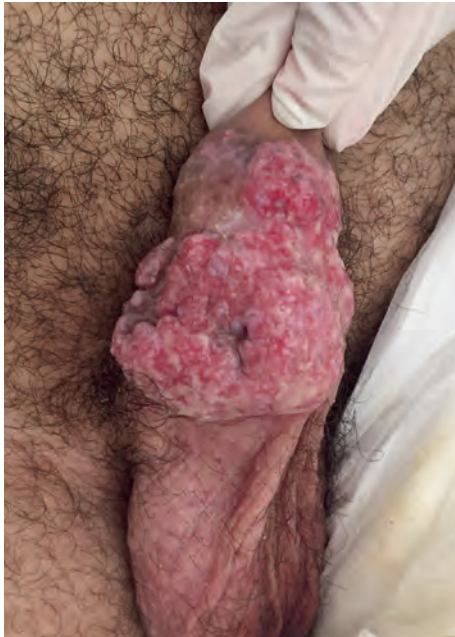

FIGURE 1: Ulcerative and vegetative skin lesion on the body of the penis

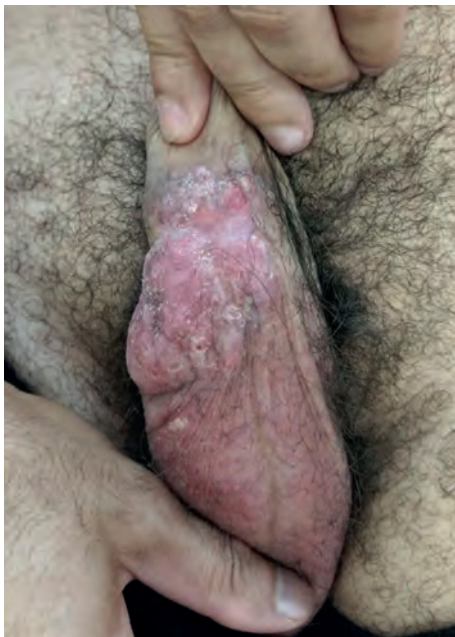

FIGURE 2: After 2 weeks of treatment with imiquimod cream

of treatment, we observed an excellent response with total healing of the lesion (Figure 3).

DISCUSSION

Vegetative chronic genital herpes is a dramatic clinical presentation that may arise mainly in patients that are also infected with HIV. It is characterized by painful, vegetative, and exudative ulcers.² Biopsy is important to exclude neoplastic and other infectious diseases. Although systemic antiviral drugs don't seem to be effective, foscarnet has a variable efficacy, resulting in many episodes of recurrence.^{2,3}

Imiquimod is an immune response modulator with an indirect antiviral and antitumoral responses.^{2,4} The exact mechanism by which it acts as an antiviral is still unknown. It induces the endogenous synthesis of many cytokines, as *interferon alpha* (IFN- α), tumor necrosis factor (TNF), and interleukins, which are involved in *T helper* type 1 (TH1) response activation. It results in the production of *interferon gama*, a powerful antiviral cytokine.⁵

This topical medicine is approved for treatment of external genital warts, caused by human papilloma virus (HPV).⁵ The efficiency of imiquimod 5% cream is not well established in the literature, but its use has been described to treat some cases of hypertrophic genital lesions.²

In 2006, Brummitt reported the case of a patient with an exophytic perianal lesion resistant to acyclovir, ganciclovir, valaciclovir. Also, the lesion recurred after treatment with foscarnet. After treatment with imiquimod 5% cream for 12 weeks 3 times a week, the patient had a good response.³ In 2007, Abbo and Vincek reported the case of a patient with severe immunosuppression who presented with vegetative herpes on the penis and scrotum. The lesion was successfully treated with imiquimod 3 times a week associated with

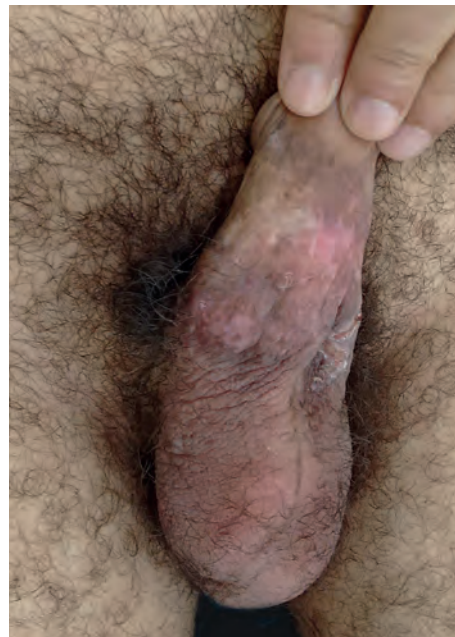

FIGURE 3: Total healing after 12 weeks of treatment with imiquimod cream

famciclovir. The treatment resulted in total remission of the skin lesions after 2-8 weeks of treatment.⁶

Lestre and João also described the posology of 3 times a week during the first 2 weeks, then 5 times a week for 8 more weeks. This increase in famciclovir dosage can lead to a faster response, without causing any more side effects.² The authors also consider that application under occlusion can potentialize treatment efficacy, which inspired the prescribed treatment for our patient.

Vegetative genital chronic herpes has been seen in literature as difficult to manage, with many reports of resistance or recurrence after treatment with the available systemic antiviral drugs. We report the case of a satisfactory response after the use of imiquimod cream, in agreement with positive experiences previously described in literature. We understand that performing comparative and random allocation studies would be important to define treatment protocols for this disease presentation. □

REFERENCES

1. Looker KJ, Elmes JAR, Gottlieb SL, Schiffer JT, Vickerman P, Turner KME, et al. Effect of HSV-2 infection on subsequent HIV acquisition: an updated systematic review and meta-analysis. *Lancet Infect Dis.* 2017;17:1303-16.
2. Lestre SIA, João A, Carvalho C, Serrão VV. Hypertrophic perianal herpes successfully treated with imiquimod. *An Bras Dermatol.* 2011;86:1185-8
3. Brummitt CF. Imiquimod 5% cream for the treatment of recurrent, acyclovir-resistant genital herpes. *Clin Infect Dis.* 2006;42:575.
4. Hober D, Ajram L, Chehadeh W, Lazrek M, Goffard A, Dewilde A, et al. Mécanismes de l'activité antivirale indirecte de l'imiquimod. *Ann Biol Clin (Paris).* 2005;63:155-63.
5. Gilbert J, Drehs MM, Weinberg JM. Topical imiquimod for acyclovir-unresponsive herpes simplex 2 virus infection. *Arch Dermatol.* 2001;137:1015-7.
6. Abbo L, Vincek V, Dickinson G, Shrestha N, Doblecki S, Haslett PAJ. Selective defect in plasmacytoid dendritic cell function in a patient with AIDS-associated atypical genital herpes simplex vegetans treated with imiquimod. *Clin Infect Dis.* 2007;44:25-7.

AUTHORS' CONTRIBUTIONS

Stella Meireles Siqueira

 ORCID 0000-0002-2589-5176

Statistical analysis; Approval of the final version of the manuscript; Conception and planning of the study; Elaboration and writing of the manuscript; Obtaining, analyzing and interpreting the data; Effective participation in research orientation; Intellectual participation in propaedeutic and/or therapeutic conduct of the cases studied; Critical review of the literature; Critical review of the manuscript

Bruna Barroso Gonçalves

 ORCID 0000-0001-5237-6681


Statistical analysis; Approval of the final version of the manuscript; Conception and planning of the study; Elaboration and writing of the manuscript; Obtaining, analyzing and interpreting the data; Effective participation in research orientation; Intellectual participation in propaedeutic and/or therapeutic conduct of the cases studied; Critical review of the literature; Critical review of the manuscript

Julia Bozetti Loss

 ORCID 0000-0002-6323-9823

Conception and planning of the study; Obtaining, analyzing and interpreting the data; Intellectual participation in propaedeutic and/or therapeutic conduct of the cases studied

Rogério Ribeiro Estrella

 ORCID 0000-0003-3321-434X

Obtaining, analyzing and interpreting the data; Intellectual participation in propaedeutic and/or therapeutic conduct of the cases studied

How to cite this article: Siqueira SM, Gonçalves BB, Loss JB, Estrella RR. Vegetative chronic genital herpes with satisfactory response to imiquimod. *An Bras Dermatol.* 2019;94(2):221-3