

Image of the Month

A Rare Cause of an Already Rare Cause of GI Hemorrhage

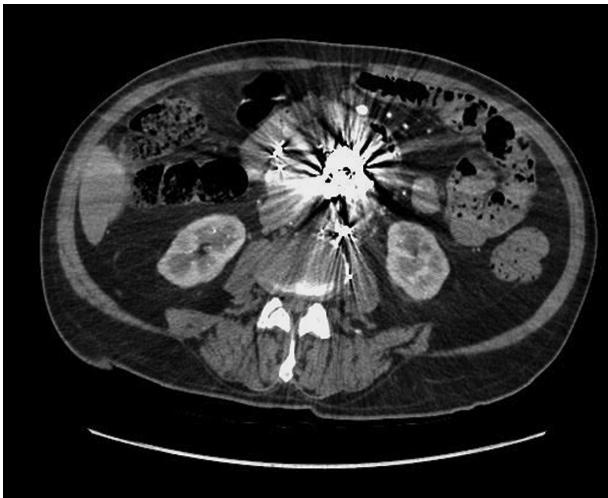

Figure 1. Computed tomography scan of the embolization material and endocoils inside the aneurysm sac.

A 75-year-old male with a three-month history of intermittent melena and a 40 g/L decrease in hemoglobin was referred to gastroenterology for further investigation. His surgical history was significant for an elective percutaneous endovascular aneurysm repair five years ago, complicated by a recurrent Type 2 endoleak, requiring a total of four trans-arterial and trans-lumbar embolization with copolymers, gelfoam, and endocoils. Computed tomography (CT) scan demonstrated a stable aneurysm sac diameter with no disruption of the aneurysm wall, extravasation of contrast material into the bowel, or signs of perigraft gas (Figure 1). On esophagogastroduodenoscopy (EGD), an aortoenteric fistula secondary to a perforating endocoil was seen in the third part of the duodenum (Figure 2), which was confirmed during a subsequent duodenal diversion procedure.

Secondary aorto-enteric fistula (AEF) is a serious but rare complication of abdominal aortic aneurysm repair (1). Erosion of metallic endocoils into the aortic wall post-endoleak embolization is an extremely rare cause of AEF, with only one published case that was diagnosed at laparotomy (2). While CT is the diagnostic modality of choice in a stable patient, the high sensitivity (94%) and specificity (85%) in this case were likely affected by significant signal artifact from the embolization material (3). In summary, endoscopic examination of the 3rd and 4th portion of the duodenum

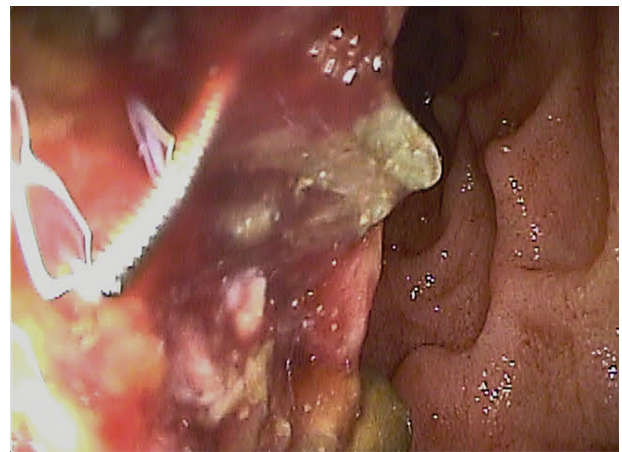


Figure 2. Perforating endocoil in the third part of the duodenum.

is a useful diagnostic adjuvant to CT imaging in patients with previous endoleak embolization for the diagnosis of AEF.

Conflict of interest statement: The authors have no conflicts to declare.

Contribution: YC drafted the initial manuscript. EJC edited and provided final approval of manuscript.

Yin Chan and Edwin J. Cheng

Division of Gastroenterology and Hepatology, Teaching Research and Wellness Centre, University of Calgary, 3280 Hospital Dr., Calgary, Alberta T2N 4N1, Canada

Correspondence: Dr Yin Chan, Teaching Research and Wellness Centre, 3280 Hospital Dr. NW Room 6D20, Calgary, Alberta, T2N 4N1, e-mail yin.chan@ucalgary.ca

References

1. Bergqvist D, Bjorck M, Nyman R. Secondary aortoenteric fistula after endovascular aortic interventions: a systematic literature review. *J Vasc Interv Radiol* 2008;19(2 Pt 1):163–5.
2. Elkouri S, Blair JF, Therasse E, Oliva VL, Bruneau L, Soulez G. Aortoduodenal fistula occurring after type II endoleak treatment with coil embolization of the aortic sac. *J Vasc Surg* 2003;37(2):461–4.
3. Low RN, Wall SD, Jeffrey RB Jr, Sollitto RA, Reilly LM, Tierney LM Jr. Aortoenteric fistula and perigraft infection: evaluation with CT. *Radiology* 1990;175(1):157–62.