

Modified Stoppa Approach for Acetabulum Fracture: A Review*

Técnica de Stoppa modificada para fratura de acetábulo: uma revisão

Ashwani Soni¹ Ravi Gupta¹ Ramesh Sen²

¹Department of Orthopedics, Government Medical College and Hospital, Chandigarh, India

²Department of Orthopaedics, Fortis Hospital Mohali, Sahibzada Ajit Singh Nagar, India

Address for correspondence Ashwani Soni, Department of Orthopedics, Government Medical College and Hospital, Chandigarh, India (e-mail: asoniortho@gmail.com).

Rev Bras Ortop 2019;54:109–117.

Abstract

Fracture acetabulum is a grave injury and a challenge for orthopedic surgeons. Anterior and posterior approaches have been described for fixation of acetabulum fractures. The modified Stoppa approach is considered an alternate to anterior approach, which provides access to pelvis from inside the cavity. The purpose of this article is to review the available literature on use of the modified Stoppa approach in acetabulum fractures. The available data suggest that modified Stoppa approach is useful in anterior acetabulum fractures and some posterior acetabulum fractures, especially where buttressing of medial wall is required.

Keywords

- ▶ acetabulum
- ▶ fractures bone
- ▶ fracture fixation
- ▶ modified stoppa

Resumo

Fraturas acetabulares são lesões graves e desafiantes para cirurgiões ortopédicos. As abordagens anterior e posterior foram descritas para a fixação dessas fraturas. A técnica de Stoppa modificada é considerada uma alternativa à abordagem anterior, que fornece acesso à pelve do interior da cavidade. O objetivo do presente artigo é revisar a literatura disponível sobre o uso da abordagem de Stoppa modificada em fraturas de acetábulo. Os dados disponíveis sugerem que a abordagem de Stoppa modificada é útil em fraturas anteriores de acetábulo e em algumas fraturas posteriores, especialmente onde o reforço da parede medial se faz necessário.

Palavras-chave

- ▶ acetábulo
- ▶ fraturas osso
- ▶ fixação de fratura
- ▶ stoppa modificado

Introduction

Treatment of acetabular fractures is a challenge for an orthopaedic surgeon. Understanding three dimensional anatomy and fixing the fracture accordingly is the key to treat. After initial work done by Judet¹ and Letournel² who described the classification system and approaches, various modifications of

approaches have been developed to improve outcome. Ilioinguinal approach was originally described by Letournel³ in 1961 for fixation of fracture acetabulum. As an intrapelvic approach, it became popular for fixation of anterior wall and column fractures, anterior fractures associated with post hemitransverse fractures and even both column fractures.

Stoppa approach has been used for treatment of inguinal Stoppa approach has been used for treatment of inguinal hernias.^{4,5} Hirvensalo et al⁶ in 1993 and Cole and Bolhofner⁷ in 1994 were the first who independently described

* Study conducted at Department of Orthopedics, Government Medical College and Hospital, Chandigarh, India. Published originally by Elsevier Editora Ltda.

received
August 5, 2017
accepted
September 28, 2017
published online
April 15, 2019

DOI <https://doi.org/10.1016/j.rboe.2017.09.006>
ISSN 0102-3616.

Copyright © 2019 by Sociedade Brasileira de Ortopedia e Traumatologia. Published by Thieme Revnter Publicações Ltda, Rio de Janeiro, Brazil

License terms



intrapelvic extraperitoneal approaches for fixation of pelvic acetabulum fractures which was a modification of stoppa approach.

Modified stoppa approach provides direct access to the pubic bones, the posterior surface of the ramus, the quadrilateral surface, the pubic eminence, and the infrapectineal surface. This approach also provides access as to the sciatic buttress, sciatic notch, and anterior sacroiliac joint. This approach provides mechanical advantage in reduction and fixation of medial displaced fractures as compare to other approaches and claimed to be a viable alternative of ilioinguinal approach for treatment of anterior acetabulum fractures. Though studies are available on use of modified stoppa approach for acetabulum fracture, there is no review article available. For the first time we review the literature on modification of stoppa approach for acetabulum fractures.

Materials and Methods

The methodology is described in PRISMA flow diagram (→Fig. 1). The Pubmed/Medline and Cochrane database were searched with keywords “modified stoppa,” “anterior intra pelvic,” “anterior intrapelvic,” “extended pfannensteil,” “ilio anterior,” and “third window ilioinguinal” to retrieve the articles in which modified stoppa approach was used to fix acetabulum fractures (on 22 December 2016). The keywords

we used were the alternate names by which modified stoppa approach is described in literature. Inclusion criteria were—all articles where modified stoppa approach was used to fix acetabulum fractures. Exclusion criteria were—articles in language other than English, case reports, cadaveric studies, articles without clinical experience, associated pelvic ring injuries and articles where ilioinguinal approach was used. The articles were evaluated for demographic data, mode of injury, classification of fracture, delay in surgery, surgical time, blood loss, additional approaches used, functional and radiological outcome and complications. Total 552 articles were found. 506 articles were not related to modified stoppa approach for acetabulum fractures. Nine article were excluded which were regarding modified stoppa approach for acetabulum fractures but in language other than English. Three cadaveric studies⁸⁻¹⁰ and two case reports^{11,12} were excluded. Nine articles¹³⁻²¹ were excluded in which modified stoppa approach was described as a technique without clinical experience. Three articles were excluded as patients treated for pelvic ring injuries were also included in these studies.²²⁻²⁴ One article by Chesser et al²⁵ was excluded as patients treated using ilioinguinal approach were also included in this study. One article by Bastian et al²⁶ was excluded as in 9% of patients in this study modified stoppa approach was changed to ilioinguinal approach intraoperatively and the results were combined for ilioinguinal and

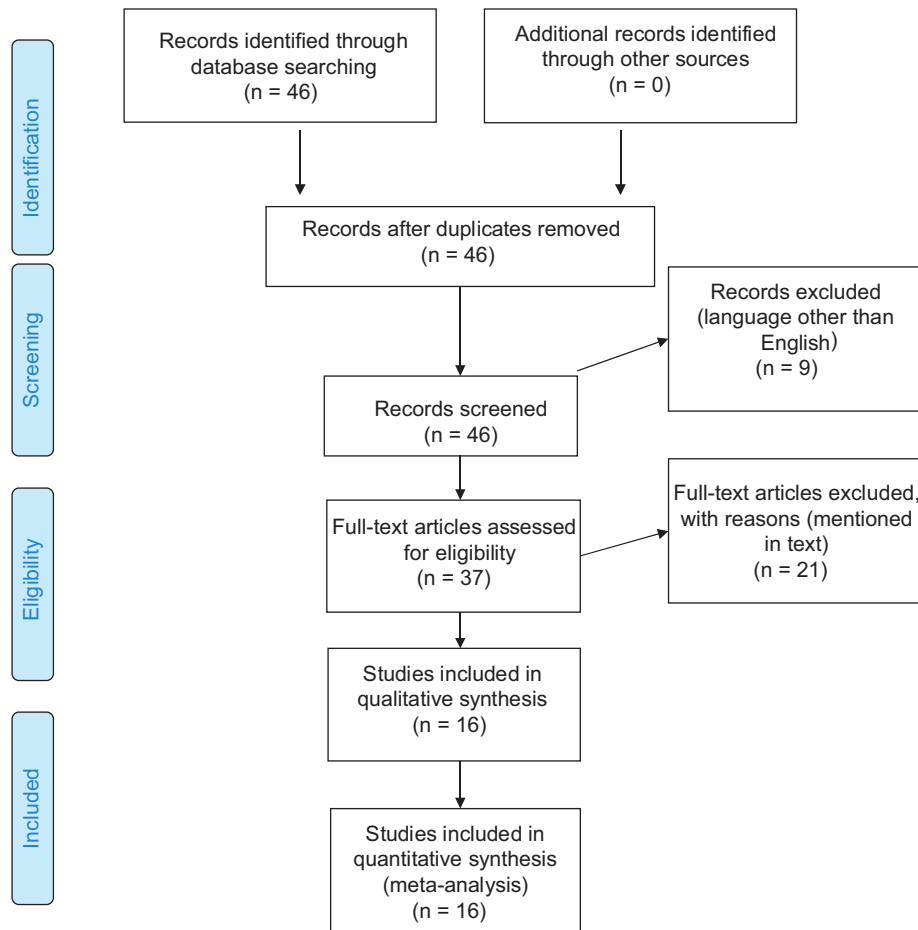


Fig. 1 PRISMA flow chart.

modified stoppa approach. Two articles by Keel et al^{27,28} were excluded. In these studies the author described pararectus approach where fracture was approached from a plane lateral to rectus muscles. The author himself described their technique different from modified stoppa approach and claimed it to be better than modified stoppa approach.

Results

Total 16 articles were found to match our selection criteria including one retrospective study by Rocca et al²⁹ comparing ilioinguinal approach with stoppa approach. The demography of patients was described combined for modified stoppa and ilioinguinal approaches but results were analyzed separately. We included this article in our review while analyzing the outcomes (post op reduction using Matta's method, functional outcome using Matta's modification of Merle d'Aubinne score and Matta's radiological criteria in this study) but excluded it while analyzing the demographic data of patients. References of all 16 articles were manually searched for any missing article. Data are extracted for age, sex ratio, mode of injury, classification of fracture, delay in surgery, surgical time, blood loss, additional approaches used, functional and radiological outcome and complications.

Demography

In 16 studies total 609 patients were treated for fracture acetabulum with modified stoppa approach.^{7,30-43} There were 427 males and 139 females. The ratio for male to female was available for 566 patients.^{7,30-43} Out of total 609 patients we excluded 34 patients treated by Rocca et al²⁹ because the demographic data of these patients was described combined with patients treated with ilioinguinal approach. Out of 10 patients treated by Casstevens et al³⁶ male female ratio was available for eight patients. Out of 57 patients treated by Sagi et al³¹ seven patients were skeletally immature and were evaluated only for surgical approach, surgical time, blood loss and complications. In all studies male patients outnumbered females.

In 11 studies (326 patients) age varies between 10-88 years.^{7,30-35,37,39,41,42} Age was described as mean age by Elmadag et al,⁴⁰ Shazar et al³⁸ and Dailey et al⁴³ which was 49.3 years, 41.88 ± 15.7 years and 55.88 ± 20.31 years in their respective studies.

Mode of Injury

Mode of injury was evaluated from 6 studies (271 patients).^{31-33,35,39,42,43} Road traffic accident was the most common mode in 129 patients followed by fall from height in 108 patients, industrial accident in six patients, crush injury in three patients and sports injury in one patient. Cole et al⁷ reported road traffic accident as the most common mode of injury in 83% of their 55 patients.

Classification of Fractures

In 14 studies 456 patients were classified according to Judet and Letournel classification.^{7,30-42} There were 128 associated both column, 89 anterior column with posterior hemi-

transverse, 84 anterior column, 54 T type, 53 transverse, 29 transverse with posterior wall, 13 anterior column, three anterior column with wall, two anterior wall and one posterior column fractures. The most common fracture pattern was both column fracture in six studies and anterior column in five studies. Dailey et al⁴³ used anterior intrapelvic approach (AIP) in patients with associated both column fracture and anterior column with posterior hemi-transverse fracture only in 112 patients.

Delay in Surgery

Time delay for surgery was mentioned in eight studies (260 patients) ranges from 0 day to 30 days.^{7,31-35,39-41} Mean time from injury to surgery was 4.83 + /-3.74 in study by Dailey et al.⁴³

Surgical Time

Surgical time ranges from 80 minutes to 568 minutes in seven studies (250 patients).^{7,30,33,35,39,41,42} Anderson et al³⁰ described surgical time as time which includes breaking down the sterile field, obtaining postoperative radiographs, and having the attending physician review the radiographs after they are developed, a process that takes at least 30 minutes. In their study the time ranges from three hours to eight hours 48 minutes. Casstevens et al³⁶ described surgical time as median surgical time which was 232 minutes for their 10 patients. Shazar et al,³⁸ Laflamme et al³² and Dailey et al⁴³ described surgical time as mean surgical time which was 240.5 minutes, 167 ± 41 minutes and 276.59 ± 103.66 for their 103 patients, 21 patients and 112 patients respectively.

Blood Loss

Estimated blood loss in 9 studies (299 patients) ranges from 100 ml - 5000 ml.^{7,29,30,32,33,35,39-41} Casstevens et al,³⁶ Laflamme et al³² and Dailey et al⁴³ described blood loss as mean blood loss which was 1270 mL, 1376 ± 608 mL and 1159.73 ± 1072.5 mL in 10 patients, 21 patients and 112 patients respectively.

Approach

Modified stoppa approach was combined with Kocher Langenbeck, lateral window and medial window of ilio inguinal approach in various studies (► Table 1).

Outcome

Post op reduction - Matta's method

Post operatively fracture reduction was evaluated in 12 studies (408 patients) by using scoring system described by Matta⁴⁴ in 1996.^{30-35,37-39,41,42} Reduction was anatomic (≤ 1 mm) in 290 patients, imperfect (> 1 to < 3 mm) in 77 patients and poor (≥ 3 mm) in 34 patients. Seven patients had either anatomic or imperfect reductions. Hammad et al⁴² found that out of 10 patients with poor outcome six had type B fracture acetabulum and 10 patients with anatomical reduction, 6 had type C fracture. Sagi et al³¹ found that poor fracture reductions occurred most frequently (75%) with associated both column

Table 1 Approaches used by authors

Sr no		No of patients	Approach
1	Elmadag et al ³³	36	MS
2	Hammad et al ⁴²	21	MS ± LW 14% requires KL
3	Kim et al ³⁴	22	MS – 13 MS + KL – 9 (5 ACPHT, 4 Trans + PW) MS + LW – 2
4	Rocca et al ²⁹	34	MS + LW (Ace approach)
5	Elmadag et al ⁴⁰	17	MS
6	Shazar et al ³⁸	103	MS – 32 MS + LW – 57 MS + KL – 11 MS + MW + LW - 2 MS + SP - 1
7	Laflamme and Herbert-Davies ³⁷	9	MS + LW
8	Casstevens et al ³⁶	10	MS
9	Liu et al ³⁵	29	MS + LW (Newly modified stoppa approach)
10	Ma et al ³⁹	30	MS – 8 MS + LW – 22
11	Anderson et al ³⁰	17	MS + Post app – excluded from study MS + LW – included Exact no not mentioned
12	Sagi et al ³¹	57 (7 sklt immature)	MS – 23 MS + LW – 34 (additional SM in 2 pt) (AIP approach)
13	Isaacson et al ⁴¹	36	MS + LW – 23 MS + KL – 3
14	Laflamme et al ³²	21	MS + LW
15	Cole and Bolhofner ⁷	55	Only MS – 32 MS + KL – 18 primarily anterior approach) (6 patients required lateral Avila approach in addition to primarily anterior approach)
16	Dailey and Archdeacon ⁴³	112	AIP approach (as described by Sagi HC et al ⁹)

Abbreviations: ACPHT, Anterior column posterior hemitransverse fracture; KL, Kocher Langenbech; LW, Lateral window of ilioinguinal; MS, modified Stoppa; MW, Medial window of ilioinguinal; SP, Smith Peterson; Trans + PW, Transverse with posterior wall fracture.

fractures. In their results percentage of excellent reduction was maximum (92%) in anterior column fracture whereas percentage of excellent reduction was minimum (67%) in transverse fractures. Similarly the lowest percentage of excellent reduction (75%) was found in transverse fractures by Shazar et al³⁸ but in their study highest percentage (92.9%) of anatomical reduction was achieved in anterior column with posterior hemitransverse fractures.

Harris Hip Score

Harris hip score was evaluated by four studies.^{32,35,37,40} In three studies (82 patients) Harris hip score was 35 excellent, 34 good, eight fair and five poor.^{32,35,40} Laflamme et al³⁷ found mean Harris hip score 81 (range 51–100) in a series of 9 patients.

Merle d'Aubinne score

In four studies^{30,32,39,40} (133 patients) Merle d'Aubinne score^{45,46} was 58 excellent, 59 good, eight fair, eight poor.

Isaacson et al⁴¹ in their study described 12 very good, two good, four medium, one fair and three poor results according to Merle d'Aubinne score.⁴⁵

Matta modification of Merle d'Aubinne score

Matta's modification of Merle d'Aubinne score^{44,47} was used to evaluate the functional results three studies^{33,34,42} (72 patents). 15 patients had excellent, 30 had good, 11 had fair, 16 had poor results. Cole et al⁷ in their study described functional results according to Matta modification of Merle d'Aubinne score⁴⁷ in percentage. The authors had 47% excellent, 42% good, 9% fair and 2% poor results.

Matta's Radiological Criteria

In three studies^{34,36,39} (70 patients) radiological results were classified according to Matta.^{44,47} 45 excellent, 14 good, 6 fair and 5 poor results were found. Cole et al⁷ in their study described radiological score according to Matta's radiological

criteria⁴⁷ in percentage. The authors had 64% excellent, 25% good, 7% fair and 4% poor results. Laflamme et al³² evaluated the functional results of internal fixation of osteopenic acetabular fractures involving quadrilateral plate in 19 elderly patients.³¹ He found (mean \pm SD) SF-12 PCS – 45.3 (\pm 12.1), SF-12 MCS – 55.9 (\pm 8.5), PMA – 16.8 (\pm 1.3), HHS (Harris Hip Score) – 86.2 (\pm 13.9), WOMAC (pain) – 3.4 (\pm 3.5), WOMAC (stiffness) – 1.3 (\pm 1.5), WOMAC (ADL) – 11.7 (\pm 12.2).

Complications

Obturator nerve injury was the most frequent complication whereas hip joint arthritis was the most frequent late complication (\blacktriangleright **Table 2**).

Discussion

Judet et al⁴⁸ described acetabulum as a socket surrounded and supported by an arch formed by two columns of bones, anterior and posterior, and roof of the acetabulum as keystone of this arch. He emphasised on the importance of these columns saying that in order to fix acetabulum fracture these columns should be restored.

The classical approach to fix posterior and anterior column fracture is Kocher Langenback and ilioinguinal approach respectively. However with time other approaches were developed for anterior acetabulum.

Hirvensalo et al⁶ in 1993 and Cole et al⁷ in 1994 were the first to describe the use of preperitoneal space to fix the pelvic fractures. Hirvensalo et al⁶ treated 18 pelvic ring injuries using low Pfannenstiel approach. Rectus abdominis and pectineus muscles were detached from the rami and subperiosteal dissection was done along the inner surface of pelvic brim up to sacroiliac joint. Iliopectineal fascia, external iliac vessels, femoral nerve and psoas muscle were undisturbed. Obturator vessels, nerves and corona mortis were protected. The approach was termed as “the ilioanterior approach”. The lateral window of ilioinguinal approach was used along with this ilioanterior approach when fracture extended to that region. Since this study included pelvic ring injuries, we excluded this study from our review. Cole and Bolhofner⁷ treated 55 acetabular fractures with intrapelvic approach which they termed as “Extended Pfannenstiel” but after further discussion and research it was later termed as “modified Stoppa” approach, quite similar to Stoppa approach used to repair hernia. The authors extended the stoppa approach posteriorly along the brim elevating the iliopectineal and obturator fascia. The authors concluded that this new approach may offer improved reduction and fixation of certain types of acetabular fractures and may decrease the rate of complications associated with extrapelvic extensile approaches.

Alternate to Ilioinguinal Approach

Modified stoppa approach along with or without other approaches provides alternate to ilioinguinal approach for fixation of anterior acetabulum fractures,^{30,32–35,39} Elmadag et al³³ concluded in their retrospective study of 36

patients that modified stoppa approach is a good alternative to ilioinguinal approach even for many complex acetabular fractures despite a steep learning curve due to proximity of neurovascular structure. Kim et al³⁴ in their study of 22 patients concluded that modified stoppa approach can be an alternative to classic ilioinguinal approach with excellent and good results though comminution of acetabular fracture was important factor leads to non anatomic reduction and unsatisfactory clinical results.

Access to Quadrilateral Plate

Modified stoppa approach provides access to acetabulum from inside the pelvis making easy to address the fractures involving quadrilateral plate.^{30,31,34,35,42} Laflamme et al³² stated that quadrangular plate can be fixed so well using this approach that it can be a viable alternate to arthroplasty in old patients or patients having osteoporosis with certain fracture acetabulum. The author treated 21 patients, more than 60 year of age or with established osteoporosis, with acetabular fractures involving quadrilateral plate. Modified stoppa approach along with lateral window was used to fix acetabular fractures and buttress the quadrilateral plate. The authors concluded that the initial treatment of osteoporotic acetabular fracture involving anterior column and quadrilateral plate, fixation of fracture using modified stoppa approach to buttress the quadrilateral plate should be considered as a viable alternative to total hip arthroplasty.

Access to Posterior Column

Modified stoppa approach when combined with lateral window of ilioinguinal approach provides access to posterior column also. This helps in fixation of fracture anterior acetabulum extending into posterior acetabulum.^{29,30,41} Using modified stoppa approach along with lateral window of ilioinguinal, Anderson RC et al treated 17 young patients (age < 60 years) having acetabular fractures with anterior and posterior column displaced.²⁹ The authors concluded that in certain fractures involving displaced anterior and posterior columns (even with more than 5 mm displacement of posterior column), anatomic or imperfect reduction can be achieved using modified stoppa approach along with lateral window of ilioinguinal approach. Isaacson et al in their prospective study of 36 patients reported good functional outcome with minimal complication rates using modified stoppa approach for acetabular fractures including fractures extending into and displacing posterior column.⁴¹ Though, author highlighted the difficulty but feasibility of treating posterior column displacement by anterior approach alone.

Variations of the Approach

Though many authors combine modified stoppa approach with other approaches (\blacktriangleright **Table 2**), certain modifications of the approach have also been described.^{30,34,35} Rocca et al²⁹ combined modified stoppa approach, as described by Cole and Bolhofner, with proximal and lateral window of

Table 2 Complications

Complications	No of patients	Management
<i>Intra operative complications</i>		
Corona mortis injury	2	Packing and ligation in 1 patient Details of 1 patient not mentioned
Obturator artery injury	1	Packing and ligation
External iliac vein injury	1	Primary repair
Superior gluteal artery injury	1	Packing and embolization
<i>Post-operative complications</i>		
Obturator nerve injury	21	Recovered in 3–6 months in 20 patients Partial recovery in 1 patient
Deep infection	13	Debridement and antibiotics in 11 patients Debridement, antibiotics and plate removal in 1 patient Hip joint fusion in 1 patient
Lateral femoral cutaneous nerve palsy	8	Recovered in 3–6 months in 5 patients Details not mentioned for 2 patients
Foot drop	5	Recovered in 6–12 months
Superficial infection	5	Dressing and antibiotics
Deep vein thrombosis	7	Chemical prophylaxis in 1 patient Details not mentioned for 3 patients
Intra articular screw	2	Removed
Sciatic nerve palsy	1	Recovered in 6 weeks
Seroma at operative site	1	Treated operatively, no infection was found
Peritoneum breach	1	Wound was closed without sequelae
Wound dehiscence	1	Surgical closure done
Delayed wound healing	1	Healed in 3 weeks with infra-red heat lamp treatment
<i>Late complications</i>		
Hip joint arthritis	15	
Ectopic bone formation	9	Conservative in 3 patients with full range of motion Details not mentioned for 6 patients
Avascular necrosis femur head	5	
Loss of reduction	4	THR done in 2 patients Details not mentioned for 2 patients
Rectus atrophy without hernia	2	
Lateral inguinal hernia	4	Repair done
Non-union	1	Fixation and bone grafting at 10 months
<i>Other complications</i>		
Fatal pulmonary embolism	2	
Non-fatal pulmonary embolism	1	
Stroke	1	
Common iliac artery thrombosis	1	
Fatal liver cirrhosis	1	

ilioinguinal approach and termed it as Anterior Combined Endopelvic (ACE) approach. Sagi et al³¹ described modification of Rives-Stoppa approach as Anterior Intra-Pelvic (AIP) approach. Lateral window of ilioinguinal approach was used along with if required. Excellent visualization and access to

the quadrilateral plate and posterior column was reported. Good to excellent reduction in majority of cases was achieved with complication rates comparable to ilioinguinal approach. The authors found the approach helpful when comminution of quadrilateral plate and posterior column exists and

recommended this technique as a potential alternative to the ilioinguinal approach for anterior exposure of acetabulum. Instead of using midline incision, Liu et al³⁵ treated 29 acetabular fractures through the inner two-third of the line 2 cm above the inguinal ligament and parallel to it. Rectus fascia was split, inferior epigastric artery was ligated and transversalis fascia was incised just superior to the symphysis pubis. This anterior approach was combined with lateral approach on the iliac crest. The approach was termed as 'Newly modified Stoppa approach'. The authors concluded that this approach provides excellent access to anterior column, quadrilateral surface and sciatic notch, permits excellent reduction, fixation and good postoperative outcomes and is a viable alternative to ilioinguinal approach. The complication rates were found to be comparable to ilioinguinal approach.

Different Technical Tricks

Since operating surgeon can approach acetabulum from inside the pelvis using modified stoppa approach, different technical tips were described utilising this advantage. Casstevens et al³⁶ in 10 patients described a technical trick using modified stoppa approach to reduce and buttress screw fixation of impacted dome of acetabulum. Similarly Laflamme et al,³⁷ in nine patients described technical trick of direct reduction of superomedial dome impaction in geriatric acetabular fractures using modified stoppa approach.

Timing of Surgery

We found only one study evaluating the effect of timing of surgery using modified ilioinguinal approach. Dailey et al⁴³ evaluated influence of timing of surgery on blood loss and surgery time in patients with fracture acetabulum. 176 patients having posterior wall fracture acetabulum were treated with Kocher Langenbeck approach. 112 patients having associated both column fracture or anterior column with posterior hemi-transverse fracture were treated with anterior intrapelvic approach. We included in our study 112 patients treated with anterior intrapelvic approach. The author did not find any difference in terms of blood loss or operative time for early (< 48 hours) or late (> 48 hours) fixation of fractures, either posterior wall or associated both column/ anterior column with posterior hemi-transverse.

Comparison with Ilioinguinal Approach

Five studies compared the results of stoppa approach vs ilioinguinal approach in fixation of fracture acetabulum.^{34,38-40,42} Rocca et al²⁹ treated 34 patients using ACE approach (modified stoppa approach combined with lateral window of ilioinguinal approach) and compared it with 42 patients treated with ilioinguinal approach for fracture acetabulum. It was concluded that ACE technique is an easier and viable alternative to ilioinguinal approach to expose anterior acetabulum and quadrilateral plate with slightly better clinical outcome and comparable complication rates. Hammad AS et al concluded that reduction accuracy and clinical scores were similar with

both approaches.⁴² The stoppa approach might be more advantageous in direct buttressing of quadrilateral plate and associated both column fractures whereas middle window of ilioinguinal approach better exposes anterior wall and transversely oriented fractures. Elmadag et al⁴⁰ concluded that there is no advantage of stoppa approach over ilioinguinal in term of complications and bleeding except the former has cosmetically better scar. Also with stoppa approach bilateral fractures can be treated with single incision and better visualization is provided in lateral compression injuries. Shazar et al³⁸ concluded that AIP approach provides higher rate of anatomical reduction as compare to ilioinguinal approach in lesser surgical time with comparable complications rates. Ma et al³⁹ concluded that there was no significant difference in reduction quality, imaging follow-up results, clinical outcomes and complications between modified stoppa approach and ilioinguinal approach in acetabular fracture fixation. However operative time, blood loss, wound drainage and blood transfusion is less with stoppa approach. The author recommended stoppa approach for anterior exposure of acetabulum, especially for fracture involving quadrilateral plate.

The present studies on modified stoppa approach for treating acetabulum fractures are highly variable in term of their study design. Different methods of result assessments were used by different authors. Different modifications and technical tricks have also been described with different aims and objectives using this approach. Moreover associated pelvic ring fractures and additional use of other approaches for acetabulum fractures makes it difficult to evaluate the results of modified stoppa approach in acetabulum fractures.

Conclusion

Though there is high variability of study design in past studies, the available literature suggests that modified stoppa approach is useful anterior approach for fixation of fracture acetabulum especially for buttressing the quadrilateral plate. Posterior column fractures can be addressed with this approach or it can be fixed with combined KL approach. For fractures extending to the iliac crest, a lateral window can be made without exposing the neurovascular bundle as done in ilioinguinal approach. Good reduction is achieved with acceptable complication rates with this approach.

Conflicts of Interest

The authors declare no conflicts of interest.

References

- 1 Judet R, Judet J, Letournel E. [Surgical treatment of recent fractures of the acetabulum. (Apropos of 46 operated cases)]. *Mem Acad Chir (Paris)* 1962;88:369-377
- 2 Letournel E, Judet R. *Fractures of the acetabulum*. 2nd. New York: Springer-Verlag; 1974

- 3 Letournel E. Fractures of the cotyloid cavity, study of a series of 75 cases]. *J Chir (Paris)* 1961;82:47–87
- 4 Rives J, Stoppa R, Fortesa L, Nicaise H. [Dacron patches and their place in surgery of groin hernia. 65 cases collected from a complete series of 274 hernia operations]. *Ann Chir* 1968;22(03):159–171
- 5 Stoppa RE, Rives JL, Warlaumont CR, Palot JP, Verhaeghe PJ, Delattre JF. The use of Dacron in the repair of hernias of the groin. *Surg Clin North Am* 1984;64(02):269–285
- 6 Hirvensalo E, Lindahl J, Böstman O. A new approach to the internal fixation of unstable pelvic fractures. *Clin Orthop Relat Res* 1993; (297):28–32
- 7 Cole JD, Bolhofner BR. Acetabular fracture fixation via a modified Stoppa limited intrapelvic approach. Description of operative technique and preliminary treatment results. *Clin Orthop Relat Res* 1994;(305):112–123
- 8 Bastian JD, Savic M, Cullmann JL, Zech WD, Djonov V, Keel MJ. Surgical exposures and options for instrumentation in acetabular fracture fixation: Pararectus approach versus the modified Stoppa. *Injury* 2016;47(03):695–701
- 9 Bible JE, Choksi AA, Kadakia RJ, Evans JM, Mir HR. Quantification of bony pelvic exposure through the modified Stoppa approach. *J Orthop Trauma* 2014;28(06):320–323
- 10 Kacra BK, Arazi M, Cicekcibasi AE, Büyükmumcu M, Demirci S. Modified medial Stoppa approach for acetabular fractures: an anatomic study. *J Trauma* 2011;71(05):1340–1344
- 11 Murcia-Asensio A, Ferrero-Manzanal F, Lax-Pérez R, Fernández-Fairén M. Stoppa approach for intrapelvic damage control and reconstruction of complex acetabular defects with intra-pelvic socket migration: A case report. *Int J Surg Case Rep* 2016;25:143–148
- 12 Elmadag M, Acar MA. A modified stoppa (technique) approach for treatment of pediatric acetabular fractures. *Case Rep Orthop* 2013;2013:478131
- 13 Archdeacon MT, Kazemi N, Guy P, Sagi HC. The modified Stoppa approach for acetabular fracture. *J Am Acad Orthop Surg* 2011;19 (03):170–175
- 14 Archdeacon MT. Comparison of the ilioinguinal approach and the anterior intrapelvic approaches for open reduction and internal fixation of the acetabulum. *J Orthop Trauma* 2015;29(Suppl 2):S6–S9
- 15 Collinge CA, Lebus GF. Techniques for reduction of the quadrilateral surface and dome impaction when using the anterior intrapelvic (modified Stoppa) approach. *J Orthop Trauma* 2015; 29(Suppl 2):S20–S24
- 16 Guy P. Evolution of the anterior intrapelvic (Stoppa) approach for acetabular fracture surgery. *J Orthop Trauma* 2015;29(Suppl 2):S1–S5
- 17 Hagen JE, Weatherford BM, Nascone JW, Sciadini MF. Anterior intrapelvic modification to the ilioinguinal approach. *J Orthop Trauma* 2015;29(Suppl 2):S10–S13
- 18 Houry A, Weill Y, Mosheiff R. The Stoppa approach for acetabular fracture. *Oper Orthop Traumatol* 2012;24(4-5):439–448
- 19 Kistler BJ, Sagi HC. Reduction of the posterior column in displaced acetabulum fractures through the anterior intrapelvic approach. *J Orthop Trauma* 2015;29(Suppl 2):S14–S19
- 20 Qureshi AA, Archdeacon MT, Jenkins MA, Infante A, DiPasquale T, Bolhofner BR. Infrapectineal plating for acetabular fractures: a technical adjunct to internal fixation. *J Orthop Trauma* 2004;18 (03):175–178
- 21 Sagi HC, Bolhofner B. Osteotomy of the Anterior Superior Iliac Spine as an Adjunct to Improve Access and Visualization Through the Lateral Window. *J Orthop Trauma* 2015;29(08):e266–e269
- 22 Vikmanis A, Vikmanis A, Jakusonoka R, Juntins A, Pavare Z. Mid-term outcome of patients with pelvic and acetabular fractures following internal fixation through a modified Stoppa approach. *Acta Orthop Belg* 2013;79(06):660–666
- 23 Jakob M, Droeser R, Zobrist R, Messmer P, Regazzoni P. A less invasive anterior intrapelvic approach for the treatment of acetabular fractures and pelvic ring injuries. *J Trauma* 2006;60(06):1364–1370
- 24 Ponsen KJ, Joosse P, Schigt A, Goslings JC, Luitse JS. Internal fracturefixation using the Stoppa approach in pelvic ring and acetabular fractures: technical aspects and operative results. *J Trauma* 2006;61(03):662–667. Erratum in. *J Trauma* 2007;62 (6):1490
- 25 Chesser TJ, Eardley W, Mattin A, Lindh AM, Acharya M, Ward AJ. The modified ilioinguinal and anterior intrapelvic approaches for acetabular fracture fixation: indications, quality of reduction, and early outcome. *J Orthop Trauma* 2015;29(Suppl 2):S25–S28
- 26 Bastian JD, Tannast M, Siebenrock KA, Keel MJ. Mid-term results in relation to age and analysis of predictive factors after fixation of acetabular fractures using the modified Stoppa approach. *Injury* 2013;44(12):1793–1798
- 27 Keel MJ, Tomagra S, Bonel HM, Siebenrock KA, Bastian JD. Clinical results of acetabular fracture management with the Pararectus approach. *Injury* 2014;45(12):1900–1907
- 28 Keel MJ, Ecker TM, Cullmann JL, Bergmann M, Bonel HM, Büchler L, et al. The Pararectus approach for anterior intrapelvic management of acetabular fractures: an anatomical study and clinical evaluation. *J Bone Joint Surg Br* 2012;94(03):405–411
- 29 Rocca G, Spina M, Mazzi M. Anterior Combined Endopelvic (ACE) approach for the treatment of acetabular and pelvic ring fractures: A new proposal. *Injury* 2014;45(Suppl 6):S9–S15
- 30 Andersen RC, O'Toole RV, Nascone JW, Sciadini MF, Frisch HM, Turen CW. Modified stoppa approach for acetabular fractures with anterior and posterior column displacement: quantification of radiographic reduction and analysis of interobserver variability. *J Orthop Trauma* 2010;24(05):271–278
- 31 Sagi HC, Afsari A, Dziadosz D. The anterior intra-pelvic (modified rives-stoppa) approach for fixation of acetabular fractures. *J Orthop Trauma* 2010;24(05):263–270
- 32 Laflamme GY, Hebert-Davies J, Rouleau D, Benoit B, Leduc S. Internal fixation of osteopenic acetabular fractures involving the quadrilateral plate. *Injury* 2011;42(10):1130–1134
- 33 Elmadag M, Guzel Y, Aksoy Y, Arazi M. Surgical Treatment of Displaced Acetabular Fractures Using a Modified Stoppa Approach. *Orthopedics* 2016;39(02):e340–e345
- 34 Kim HY, Yang DS, Park CK, Choy WS. Modified Stoppa approach for surgical treatment of acetabular fracture. *Clin Orthop Surg* 2015;7 (01):29–38
- 35 Liu Y, Yang H, Li X, Yang SH, Lin JH. Newly modified Stoppa approach for acetabular fractures. *Int Orthop* 2013;37(07): 1347–1353
- 36 Casstevens C, Archdeacon MT, d'Heurle A, Finnan R. Intrapelvic reduction and buttress screw stabilization of dome impaction of the acetabulum: a technical trick. *J Orthop Trauma* 2014;28(06): e133–e137
- 37 Laflamme GY, Hebert-Davies J. Direct reduction technique for superomedial dome impaction in geriatric acetabular fractures. *J Orthop Trauma* 2014;28(02):e39–e43
- 38 Shazar N, Eshed I, Ackshota N, Hershkovich O, Khazanov A, Herman A. Comparison of acetabular fracture reduction quality by the ilioinguinal or the anterior intrapelvic (modified Rives-Stoppa) surgical approaches. *J Orthop Trauma* 2014;28(06):313–319
- 39 Ma K, Luan F, Wang X, Ao Y, Liang Y, Fang Y, et al. Randomized, controlled trial of the modified Stoppa versus the ilioinguinal approach for acetabular fractures. *Orthopedics* 2013;36(10): e1307–e1315
- 40 Elmadağ M, Güzel Y, Acar MA, Uzer G, Arazi M. The Stoppa approach versus the ilioinguinal approach for anterior acetabular fractures: a case control study assessing blood loss complications and function outcomes. *Orthop Traumatol Surg Res* 2014;100 (06):675–680
- 41 Isaacson MJ, Taylor BC, French BC, Poka A. Treatment of acetabulum fractures through the modified Stoppa approach: strategies and outcomes. *Clin Orthop Relat Res* 2014;472(11):3345–3352
- 42 Hammad AS, El-Khadrawe TA. Accuracy of reduction and early clinical outcome in acetabular fractures treated by the standard ilio-inguinal versus the Stoppa/iliac approaches. *Injury* 2015;46 (02):320–326

- 43 Dailey SK, Archdeacon MT. Open reduction and internal fixation of acetabulum fractures: does timing of surgery affect blood loss and OR time? *J Orthop Trauma* 2014;28(09):497-501
- 44 Matta JM. Fractures of the acetabulum: accuracy of reduction and clinical results in patients managed operatively within three weeks after the injury. *J Bone Joint Surg Am* 1996;78(11):1632-1645
- 45 D'Aubigne RM, Postel M. Functional results of hip arthroplasty with acrylic prosthesis. *J Bone Joint Surg Am* 1954;36-A(03):451-475
- 46 Merle D'Aubigné R. [Numerical classification of the function of the hip. 1970]. *Rev Chir Orthop Repar Appar Mot* 1990;76(06):371-374
- 47 Matta JM, Anderson LM, Epstein HC, Hendricks P. Fractures of the acetabulum. A retrospective analysis. *Clin Orthop Relat Res* 1986;(205):230-240
- 48 Judet R, Judet J, Letournel E. Fractures of the acetabulum: classification and surgical approaches for open reduction Preliminary report. *J Bone Joint Surg Am* 1964;46:1615-1646