

Immunohistochemical Expression of Androgen Receptors (AR) in Various Breast Cancer Subtypes

Nour El Hoda S. Ismael¹, Rasha A. Khairy¹, Suzan M. Talaat^{2*}, Fatima A. Abd El-Fattah²

¹Pathology Department, Faculty of Medicine, Cairo University, Cairo, Egypt; ²Pathology Department, Ahmed Maher Teaching Hospital, Cairo, Egypt

Abstract

Citation: Nour El Hoda IS, Khairy RA, Talaat SM, Abd El-Fattah FA. Immunohistochemical Expression of Androgen Receptors (AR) in Various Breast Cancer Subtypes. Open Access Maced J Med Sci. 2019 Apr 30; 7(8):1259-1265. https://doi.org/10.3889/oamjms.2019.311

Keywords: Androgen receptors; Breast cancer; Hormonal status; Immunohistochemistry; Luminal; Triple-negative

***Correspondence:** Suzan M. Talaat. Pathology Department, Faculty of Medicine, Cairo University, Cairo, Egypt. E-mail: sonyekanugraha@usu.ac.id

Received: 03-Feb-2019; **Revised:** 13-Apr-2019; **Accepted:** 16-Apr-2019; **Online first:** 29-Apr-2019

Copyright: © 2019 Nour El Hoda S. Ismael, Rasha A. Khairy, Suzan M. Talaat, Fatima A. Abd El-Fattah. This is an open-access article distributed under the terms of the Creative Commons Attribution-NonCommercial 4.0 International License (CC BY-NC 4.0)

Funding: This research did not receive any financial support

Competing Interests: The authors have declared that no competing interests exist

BACKGROUND: Breast carcinoma ranks the first among malignant tumours in females and is the chief cause of cancer-related mortality. Androgen is implicated in the induction of proliferation and growth of mammary cells through binding to their corresponding receptors. Androgens influence the risk of acquiring breast cancer through either direct binding to androgen receptors (AR) or indirectly through their transformation to estradiol or competing for steroid binding proteins.

AIM: To study the expression of AR in various breast cancer subtypes and to elucidate its clinical significance by correlating it with clinicopathological parameters.

METHODS: One hundred and fifty breast cancer cases were studied using AR immunohistochemistry, and its expression was correlated with different clinicopathologic parameters and with ER, PR, Her-2/neu and Ki 67 expression.

RESULTS: AR was expressed in 91 breast carcinoma cases out of 150 examined. There was a statistically significant correlation between AR expression and tumour size, mitotic count, tumour necrosis, infiltrative borders, the hormonal status of the tumour and subsequently luminal subtypes ($p < 0.05$). A subset of studied TNBC (34.6%) also expressed AR. On the other hand, there was no significant correlation between AR expression and other clinicopathological parameters.

CONCLUSION: Positive AR immunostaining was associated with favourable prognostic factors and luminal subtypes (A&B). Also, a subset of TNBC cases showed positive AR expression. These results introduce the current potent, next-generation AR- antagonist as possible target therapy in breast cancer. Further researches on AR expression in breast cancer are recommended on a larger scale with follow up and survival to validate the current results.

Introduction

Breast carcinoma occupies the first rank among malignant tumours in females [1]. It is the second most common cause of cancer-related death in women, exceeding 1.7 million reported cases per year all over the world. Relative difference in incidence is noted between various regions as high occurrence was recorded in North America and the North of Europe, followed by the South region of Europe and Latin America, and lowest records were reported in Asia and Africa, but with a high tendency for rising incidence lately due to increased affluence of some of these regions [2].

In Egypt, breast cancer ranks second among different malignancies [1]. In 2013, breast cancer cases were estimated as 18192 [3] and raised to 23081 in 2018 [1].

Breast cancer is a nonuniform disease with diverse clinical backgrounds, histomorphology, outcome and response to treatment regimens. Moreover, neoplasms sharing similar histopathologic features can differ in their responses to therapy and finally, have different prognosis. This can be attributed to molecular diversity among histologically similar tumours [4].

Steroid hormones induce the growth of mammary cells by attaching to their corresponding

receptors, resulting in the clonal proliferation of both non-neoplastic and neoplastic cells. These signals can act directly by affecting hormone receptor-positive cells, or through the induction of growth factors elaboration that acts indirectly on receptor-negative cells. Three major receptors belong to this steroid superfamily; estrogen receptor is (ER), progesterone receptor (PR) and androgen receptor (AR) [5].

The fundamental role of estrogen and progesterone receptors in breast cancer prognosis and therapy management is well known and established. In contrast, few data is known about the exact role of the androgen receptor (AR) in breast tumorigenesis. The androgen receptor (AR) is more widely expressed in breast cancers than other steroid receptors [6], [7], [8].

Androgens influence the risk of acquiring breast cancer through either direct binding to AR or indirect through their transformation to estradiol or competing for steroid binding proteins [9].

In the post-menopausal period, women develop falling in the estrogen levels, and subsequently, adrenal androgens become the dominant stock in replenishing estrogen to cells. This new metabolic pathway represents the main source of estrogens and circulating androgen levels are implicated in the rising rates reported for breast cancer [10], [11].

Currently, investigators suggest that AR (+) tumours have favourable characteristics and that tumours expressing both AR and ER are associated with better outcome [12], [13].

To date, controversy exists among epidemiological, clinical, and preliminary clinical data on the basic role of androgens and of ARs in (ER)-negative breast carcinoma. However, results reported from most preliminary clinical researches suggest that activated ARs, initiate and induce the proliferation and growth, especially in HER2 positive cell lines, due to the crosstalk between AR and HER2 pathways. The proposed mechanism of action is that androgens are bidirectional: mainly proliferative, as androgens are the main harbingers of estrogens, but also anti-proliferative, because stimulated AR limits the ER activity [14].

In cases of ER-negative disseminated breast cancer, AR expression is noted in a subset defined as 'molecular apocrine' tumours and is associated with lower 5-year survival [15], [16].

The subcategory of TNBC positively expressing AR has been termed as the luminal androgen receptor (LAR) subtype. The prognostic and predictive value of AR in TNBC remains a challenging topic of research [17].

AR can be a promising candidate for target therapy in breast cancer [15]. The AR antagonist (enzalutamide) implicated in prostate cancer

treatment, has shown promising results in some patients with advanced TNBC whose tumours were AR-positive [18].

Methods

One hundred and fifty cases of breast carcinoma with a wide range of age were randomly retrieved from the pathology files of the Pathology Department, Ahmed Maher Teaching Hospital during the period from January 2013 to December 2016. Patients with pure in situ duct carcinoma were excluded. The study was approved by the local Ethics Committee of the General Organization of Teaching Hospitals and Institutes.

The collected specimens were tru-cut needle biopsy (n = 10), wide local excision with axillary evacuation (n = 85), and modified radical mastectomy (n = 55).

Five μ m thick sections were prepared from Formalin-fixed paraffin-embedded blocks and stained with routine Hematoxylin and eosin for confirmation of histopathological diagnosis and further tumour subtyping, grading and, staging. Other data were assessed such as; foci of tumoral necrosis, lymphovascular tumour emboli, perineural invasion, lymphocytic response and status of lymph nodes were reported.

The immunohistochemical (IHC) staining procedure was done using an immunostainer (Shandon Sequenza) through the labelled streptavidin-biotin method with the following reagents: Citrate buffer, 10X, heat-induced epitope retrieval, (Thermo medical Catalog number: AP-9003-500), Hydrogen peroxide block (Lab Vision, USA, Catalog number: TA-060-HP), Ultravision large volume detection system (Lab Vision, USA, Catalog number: TP-060-HL) including Ultra V block, Biotinylated goat anti-polyvalent plus (link) & Streptavidin peroxidase plus (label) and DAB plus substrate system (Lab Vision, USA, Catalog number: TA-060-HDX) including DAB plus chromogen & DAB plus substrate. The primary antibodies were: AR: a mouse polyclonal antibody (Thermo Medical Catalog number: MS-433-R7), ER: a rabbit monoclonal antibody (Thermo Medical Catalog number: RM-9101-R7), PR: a rabbit monoclonal antibody (Thermo Medical Catalog number: RM-9102-R7), HER-2/neu: a mouse monoclonal antibody (Thermo Medical Catalog number: MS-730-R7) and Ki67: a rabbit polyclonal antibody (Thermo Medical Catalog number: RB-9043-R7).

The adjacent breast tissue served as a positive internal control for For ER, PR, Her-2/neu and Ki 67 while prostatic tissue was used as a positive

control for AR. The slides were at least examined by two pathologists, totally blind to the reported clinical data. The following cut-off values were used for scoring of IHC-stained slides:

- The examined sections were reported as ER-positive if more than or equal 1% of ER nuclear staining was noted in tumour cells [19].

- The examined sections were reported as HER-2/neu positive in score 3+; cases with more than or equal 10% of tumour cells showed intense complete membranous staining [19].

- The Ki-67 proliferative activity was determined through semi-quantitative scoring. A cut-off point 20% for the Ki-67 nuclear staining positivity was used to classify cases into either low proliferative (< 20%) or high proliferative ($\geq 20\%$) [20].

- A combination of 4 IHC markers (ER, PR, HER-2/neu, and Ki-67) was used for further subtyping of breast carcinoma according to St. Gallen international expert Consensus, 2013 [21].

- The examined sections were reported as AR-positive when more than 1% of tumour cells showed positive nuclear immunostaining [22], [23].

Statistical Package for Social Science (SPSS 17.0 for Windows; SPSS Inc, Chicago, IL, 2010) was used for data analysis. Chi-Square test was used to examine the correlation between two qualitative variables and between one quantitative and one qualitative variable. P-value was set as significant (S) when ≤ 0.05 .

Results

The patient's age showed a wide range of age from 31 to 73 years with a mean age of 55.86 ± 13.11 years. The studied patients were all females. Tumour size ranged from 1 cm to 11.5 cm with Mean \pm SD 3.2 ± 1.8 . Most of the cases were invasive duct carcinoma of no special type (NST) with a percentage of 85.3%.

After exclusion of the Tru-cut cases (10), the majority of tumors were histologically grade II (77.1%), average mitotic rate (1- 10/10 HPF) (53.5%), were negative for tumor necrosis, (89.3%) , had infiltrative tumor borders (71.4%), showed moderate lymphocytic response (37.1%), had positive lymphovascular emboli (88.6%), weres stage T2 (55%) and were N0 (48.6%).

Regarding the intrinsic subtypes; after exclusion of cases with equivocal Her-2/neu (21), 129 cases were classified; 40 cases were Luminal A (31%), 54 cases were were Luminal B (41.9%), 9 cases were Her-2 Enriched (7%), and 26 cases were triple negative (7%).

The majority of cases were AR positive (60.7%) where AR expression was positive in 39.2% of luminal A cases, 43% of luminal B cases, 6.3% of Her-2 Enriched and 11.4% of triple-negative cases. AR expression was more in the luminal subtypes (Figure 1).

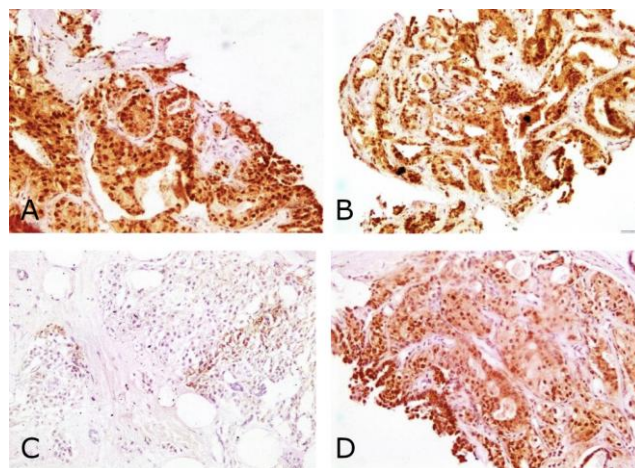


Figure 1: A) AR-positive nuclear expression (X200 original magnification) in Luminal B breast carcinoma; B) ER-positive nuclear expression (X100 original magnification); C) negative HER-2 neu membranous staining (X100 original magnification); D) high Ki-67 $\geq 20\%$ (X200 original magnification)

On the correlation of AR expression with the clinicopathological parameters; there was a statistically significant correlation between AR status and both tumour size, and it's the mitotic count. AR expression was associated with tumours of smaller size and low mitotic count (P value: 0.017 and < 0.001 respectively).

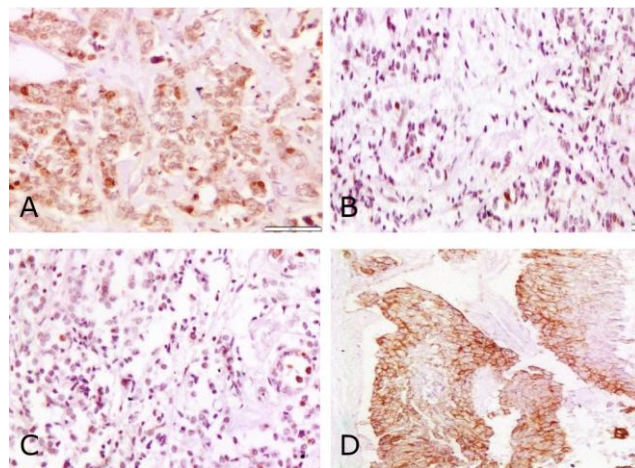


Figure 2: A) AR-positive nuclear expression (X200 original magnification) in HER-2 enriched breast carcinoma; B) ER-negative nuclear expression (X200 original magnification); C) PR negative nuclear expression (X200 original magnification); D) positive HER-2 neu complete membranous staining (X100 original magnification)

Also, there was a statistically significant correlation between AR status and tumour necrosis, tumour borders, its hormonal status and subsequently tumour subtype. AR expression was associated with

the absence of tumour necrosis, with infiltrative borders, with positive ER, positive PR and with luminal subtypes (P-value: < 0.001, 0.005, 0.004, 0.016 and 0.006 respectively) (Figures 1, 2, and 3).

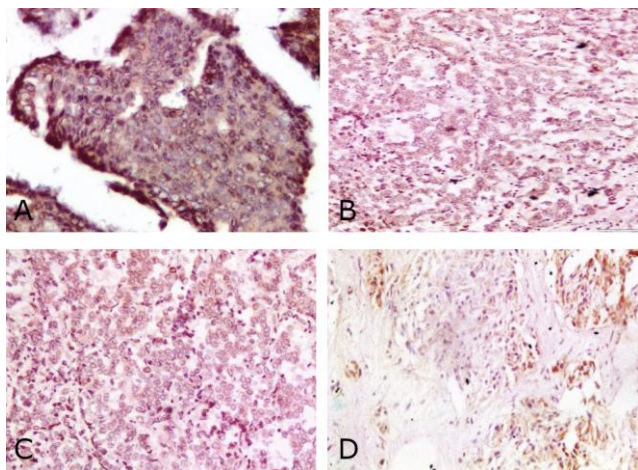


Figure 3: A) AR Negative nuclear expression (X200 original magnification) in Triple Negative breast carcinoma; B) ER-negative nuclear expression (X200 original magnification); C) PR negative nuclear expression (X200 original magnification); D) negative HER-2 neu membranous staining (X200 original magnification)

No correlation could be found between AR status and patients age, tumour site, multifocality, histologic type, grade, lymphocytic response, lymphovascular invasion, perineural invasion, T stage, N stage, Her-2/neu status and ki 67 status (Table 1).

Table 1: Clinicopathological findings and their correlation with androgen receptors expression

	AR - n (%)	AR + n (%)	Total n (%)	P value
Right side	27 (45.8)	48 (52.7)	75 (50)	0.33
Left side	32 (54.2)	43 (47.3)	75 (50)	
Unifocal	49 (89.1)	75 (88.2)	124 (88.6)	0.924
Multifocal	6 (10.9)	10 (11.8)	16 (11.4)	
IDC (NST)	55 (93.2)	73 (80.2)	128 (85.3)	0.125
ILC	0 (0)	10 (11)	10 (6.7)	
Tubular/Cribiform/ mixed	3 (5.1)	4 (4.4)	7 (4.7)	0.087
Others	1 (1.7)	4 (4.4)	5 (3.3)	
Grade I&II	50 (90.9)	84 (98.8)	134 (95.7)	0.087
III	5 (9.1)	1 (1.2)	6 (4.3)	
No mitosis	12 (21.4)	34 (40.5)	46 (32.9)	< 0.001*
1-10/10 HPF	28 (50)	47 (56.9)	75 (53.5)	
> 10/10 HPF	15 (28.6)	4 (3.6)	19 (13.6)	
Necrosis absent	42 (76.4)	83 (97.6)	125 (89.3)	< 0.001*
Present	13 (23.6)	2 (2.4)	15 (10.7)	
Infiltrative border	32 (58.2)	68 (80)	100 (71.4)	0.005*
Pushing	23 (41.8)	17 (20)	40 (28.6)	
No Lymphocytic response	9 (16.4)	23 (27.1)	32 (22.9)	0.14
With lymphocytic response	46 (83.6)	62 (73.9)	108 (77.1)	
No vascular emboli	8 (16.5)	8 (27.1)	16 (11.4)	0.14
With vascular emboli	47 (83.5)	77 (72.9)	124 (88.6)	
No perineural invasion	55 (100)	84 (98.8)	139 (99.3)	0.83
With perineural invasion	0 (0)	1 (1.2)	1 (0.7)	
T Stage I & II	43 (78.2)	74 (87.1)	117 (83.6)	0.166
III&IV	12 (21.8)	11 (12.9)	23 (16.4)	
N Stage N0	25 (45.5)	43 (50.6)	68 (48.6)	0.55
N1, N2	30 (55.5)	42 (49.4)	72 (51.4)	
ER-	22 (37.7)	15 (16.7)	37 (24.7)	0.004*
ER+	37 (62.3)	76 (83.3)	113 (75.3)	
PR-	26 (45.3)	23 (25)	49 (32.7)	0.016*
PR+	32 (54.7)	69 (75)	101 (67.3)	
Her2-	38 (67.9)	76 (84)	114 (76)	0.084
Her2+	9 (15.1)	6 (6.2)	15 (10)	
Equivocal Her2	12 (17)	9 (9.9)	21 (14)	
Low Ki 67	17 (29.3)	37 (40.2)	54 (36)	0.139
High Ki 67	42 (70.7)	54 (59.8)	96 (64)	
Luminal A	9 (18)	31 (39.2)	40 (31)	0.006*
Luminal B	20 (40)	34 (43)	54 (41.9)	
Her-2 enriched Triple	4 (8)	5 (6.3)	9 (7)	
Negative	17 (34)	9 (11.4)	26 (20.2)	

Discussion

The chief role of androgen receptor signalling in neoplastic breast cells remains questionable. It has been reported in previous studies to be involved in the proliferation and growth of normal mammary cells [24].

This work studied the relation between AR expression and clinicopathological parameters in 150 cases of invasive breast carcinoma.

A significant correlation was found between AR expression and tumour size. This finding is in agreement with Ogawa et al., [25], Niemeier et al., [26], Collins et al., [27], and Aleskandarany et al., [28] studies which found that AR expression was higher in the smaller tumours. On the other hand, Gonzalez et al. [29] and Samaka et al., [30] found no significant correlation between AR expression and the size of the tumour. Gonzalez et al., [29] used both tissue microarrays and immunohistochemistry and Samaka et al., [30] used a smaller number of cases.

AR expression is significantly associated with infiltrative borders of the tumour, and this is in concordance with Putti et al., [31]. But this is in contrast to Gonzalez et al., [29] study which found no significant relation between AR expression and the type of tumour borders. This discrepancy might be the result of their use of tissue microarray in testing for AR.

The mitotic count is significantly inversely correlated to AR expression where the cases with lower mitotic figures showed a higher percentage of AR expression. This is in harmony with Safarpour et al., [32] and Aleskandarany et al., [28].

AR expression was significantly associated with the absence of tumour necrosis, and this is similar to Niemeier et al., [26] study results.

A significant correlation between AR expression and hormonal status was found. This is by Park et al., [6], Qi et al., [33], Safarpour et al., [32], Vera-Badillo et al., [34], and Chottanapund et al., [35]. On the contrary; Gonzalez et al. [29] found no correlation between AR status and the hormonal status of breast cancer. This might be the result of their use of tissue microarray in testing for AR.

As Ogawa et al., [25], Park et al., [6] and Qi et al., [33], no significant relation between AR expression and Her-2/neu expression could be found, though Agrawal et al., [36], Chottanapund et al., [35], and Samaka et al., [30] found that AR expression is more in tumours expressing Her-2/neu. This might be due to different primary antibodies used.

No significant relation between AR expression and Ki 67 expression was found as Vera-Badillo et al., [34], but in contrast to Qi et al., [33], and Samaka et al., [30], this might be due to their use of 14 % as

cut-off, not 20% as we used.

Regarding the correlation between AR expression and the subtypes, AR was expressed in significantly higher proportions of luminal breast carcinoma cases. This is by Collins et al., [27], Qi et al., [33], Aleskandarany et al., [28] and Samaka et al., [30].

In our study, the triple negative cases were 20.2%. This is within the documented range for triple negative cases (15-20%) of Kohler et al., a study [37]. AR was expressed in 34.6% of the TN cases, and that is within the wide range of 6.6 to 75% documented by Rampurwala et al., [38]. These subsets of patients are possible candidates for the promising anti-androgen target therapy.

No correlation could be found between AR status and patients age, tumour site, multifocality, histologic type, grade, lymphocytic response, lymphovascular invasion, perineural invasion, T stage, N stage, Her-2/neu status and ki 67 status.

Gonzalez et al., [29] also found no significant correlation between AR expression and histologic grade, lymphocytic response, lymphovascular invasion or N stage.

Ogawa et al., [25] and Collins et al., [27] found androgen receptor-positive tumours were lower grade and more often node-negative.

Soiland et al., [39] found no significant correlation between AR expression and patients age.

Park et al., [6] revealed a significant correlation between AR expression and both histologic type and grade.

Qi et al., [33] did not find a significant correlation between AR expression and both patients age and N stage.

Ruibal et al., [40] tested AR expression in 816 breast cancers using immunohistochemistry and found no relation between AR expression and the tumour multifocality.

Agrawal et al., [36] found no significant correlation between AR expression and both histologic type and N stage but found a significant correlation between AR expression and histologic grade.

Aleskandarany et al., [28] found that nuclear AR immunostaining was significantly associated with features favouring good prognosis including older age groups, smaller tumour size, lower histologic grade and lobular carcinoma.

Samaka et al., [30] found a significant relation between AR expression and the patient's age and no significant relation with histologic type, lymphovascular invasion or N stage.

In the highlight of the previously mentioned results, we conclude that positive AR immunostaining

was associated with smaller tumour size, infiltrative margins, lower mitotic count, negative tumour necrosis, positive ER and PR expression and mainly luminal subtypes (A&B) and in a subset of TNBC cases.

The most used therapy for advanced BC (Tamoxifen-resistant-BCs and TNBCs) is based on the use of AR antagonists, such as bicalutamide and enzalutamide, a first- and second-generation AR antagonist, respectively [41], [42]. Both the antagonists have been used in clinical trials with positive results [43]. Other therapies for TNBC are based on the use of CYP17A1 inhibitors, such as abiraterone acetate and seviteronel. These inhibitors reduce the androgen production and 11the androgen levels. They are now being tested in phase 2 clinical trials [44], [45], alone or in combination with AR antagonists [46].

In conclusion, positive AR expression was associated with favourable prognostic factors and luminal subtypes (A&B). Also, a subset of TNBC cases showed positive AR expression. These results introduce the current potent, next-generation AR-antagonist as possible target therapy in breast cancer. Further researches on AR expression in breast cancer are recommended on a larger scale with follow up and survival to validate the current results.

References

1. International Agency for Research on Cancer (IARC) and World Health Organization (WHO): GLOBOCAN 2012: Estimated cancer incidence, mortality and prevalence worldwide in 2012. Lyon, france: IARC, 2018. Available for <http://globocan.iarc.fr/>.
2. Collins LC, Breast; In, Rosai and Ackerman's Surgical Pathology, Goldblum JR, Lamps LW, Mckenney JK, et al., 11th Edition, Elsevier 2018:1434-1527.
3. Baraka H, Kamel H, Ibrahim AS, et al. Cancer Incidence in Egypt: Results of the National Population-Based Cancer Registry Program. Journal of Cancer Epidemiology. 2014; 18. <https://doi.org/10.1155/2014/437971>
4. Shawarby MA, Al-Tamimi DM, Ahmed A. Molecular classification of breast cancer: an overview with emphasis on ethnic variations and future perspectives. Saudi Journal of Medicine and Medical Sciences. 2013; 1(1):14. <https://doi.org/10.4103/1658-631X.112908>
5. Mishra AK, Agrawal U, Negi S, et al. Expression of androgen receptor in breast cancer & its correlation with other steroid receptors & growth factors. Indian J Med Res. 2012; 135(6):843-852.
6. Park S, Koo J, Lee JH, et al. Expression of androgen receptors in primary breast cancer. Ann Oncol. 2010; 21(3):488-492. <https://doi.org/10.1093/annonc/mdp510> PMID:19887463
7. Bhatnagar A, Negi S, Mohil R, et al. Expression of androgen receptor in breast cancer & its correlation with other steroid receptors & growth factors. Indian J Med Res. 2012; 135(6):843-852.
8. Cochrane DR, Bernales S, Jacobsen BM, Citty DM, Howe EN, D'Amato NC, Spoelstra NS, Edgerton SM, Jean A, Guerrero J, Gómez F. Role of the androgen receptor in breast cancer and

- preclinical analysis of enzalutamide. *Breast Cancer Research*. 2014; 16(1):R7. <https://doi.org/10.1186/bcr3599>
9. Ashwani KM, Usha A, Shivani N, et al. Expression of androgen receptor in breast cancer & its correlation with other steroid receptors & growth factors. *Indian J Med Res*. 2012; 135(6):843-852.
10. Chetrite GS, Cortes-Prieto J, Philippe JC, Wright F, Pasqualini JR. Comparison of estrogen concentrations, estrone sulfatase and aromatase activities in normal, and in cancerous, human breast tissues. *The Journal of steroid biochemistry and molecular biology*. 2000; 72(1-2):23-7. [https://doi.org/10.1016/S0960-0760\(00\)00040-6](https://doi.org/10.1016/S0960-0760(00)00040-6)
11. Laura CC, Kimberly C, Jonathan M, et al. Androgen Receptor Expression in Breast Cancer in Relation to Molecular Phenotype: Results from the Nurses' Health Study. *Mod Pathol*. 2012.
12. Elebro K, Borgquist S, Simonsson M, et al. Combined Androgen and Estrogen Receptor Status in Breast Cancer: Treatment Prediction and Prognosis in a Population-Based Prospective Cohort. *Clin Cancer Res*. 2015; 21(16):3640-50. <https://doi.org/10.1158/1078-0432.CCR-14-2564> PMID:25904752
13. Hu R, Dawood S, Holmes MD, et al. Androgen Receptor Expression and Breast Cancer Survival in Postmenopausal Women. *Clin Cancer Res*. 2011; 17(7):1867-1874. <https://doi.org/10.1158/1078-0432.CCR-10-2021> PMID:21325075 PMID:PMC3076683
14. Abba C, Berrino F, Castellano I, et al. Postmenopausal breast cancer, androgens, and aromatase inhibitors. *Breast Cancer Research and Treatment*. 2013; 139(1):1-11. <https://doi.org/10.1007/s10549-013-2505-2>
15. Gucalp A, Tolaney S, Isakoff SJ, et al. Phase II Trial of Bicalutamide in Patients with Androgen Receptor-Positive, Estrogen Receptor-Negative Metastatic Breast Cancer. *Clin Cancer Res*. 2013; 19(19):5505-5512. <https://doi.org/10.1158/1078-0432.CCR-12-3327> PMID:23965901 PMID:PMC4086643
16. Park S, Koo JS, Kim MS, et al. Androgen receptor expression is significantly associated with better outcomes in estrogen receptor-positive breast cancers. *Ann Oncol*. 2011; 22(8):1755-1762. <https://doi.org/10.1093/annonc/mdq678> PMID:21310761
17. McNamara KM, Yoda T, Takagi K, et al. Androgen receptor in triple negative breast cancer. *J Steroid Biochem Mol Biol*. 2013; 133:66-76. <https://doi.org/10.1016/j.jsbmb.2012.08.007>
18. Traina TA, Miller K, Yardley DA, et al. : Results from a phase 2 study of enzalutamide (ENZA), an androgen receptor (AR) inhibitor, in advanced AR+ triple-negative breast cancer (TNBC). *Journal of clinical oncology*. 2015; 33(15):1003-1003. https://doi.org/10.1200/jco.2015.33.15_suppl.1003
19. Hammond ME, Hayes DF, Dowsett M, et al. American Society of Clinical Oncology/College of American Pathologists guideline recommendations for immunohistochemical testing of estrogen and progesterone receptors in breast cancer. *Arch Pathol Lab Med*. 2010; 134(6):907-922. <https://doi.org/10.1200/JOP.777003>
20. Bustreo S, Osella-Abate S, Cassoni P, et al. Optimal Ki67 cut-off for luminal breast cancer prognostic evaluation: a large case series study with a long-term follow-up. *Breast Cancer Res Treat*. 2016; 157:363-371. <https://doi.org/10.1007/s10549-016-3817-9> PMID:27155668 PMID:PMC4875067
21. Goldhirsch A, Winer EP, Coates AS, et al. Personalizing the treatment of women with early breast cancer: highlights of the St Gallen International Expert Consensus on the Primary Therapy of Early Breast Cancer 2013. *Annals of Oncology*. 2013; 24:2206-2223. <https://doi.org/10.1093/annonc/mdt303> PMID:23917950 PMID:PMC3755334
22. Sutton LM, Cao D, Sarode V, et al. Decreased androgen receptor expression is associated with distant metastases in patients with androgen receptor-expressing triple-negative breast carcinoma. *Am J Clin Pathol*. 2012; 138(4):511-6. <https://doi.org/10.1309/AJCP8AVF8FDPTZLH> PMID:23010705
23. Mrklíč I, Pogorelič Z, Capkun V, et al. : Expression of androgen receptors in triple negative breast carcinomas. *Acta Histochem*. 2013; 115(4):344-8. <https://doi.org/10.1016/j.acthis.2012.09.006> PMID:23031358
24. Birrell SN, Hall RE, Tilley WD, Role of the androgen receptor in human breast cancer. *J Mammary Gland Biol Neoplasia*. 1998; 3:95-103. <https://doi.org/10.1023/A:1018730519839>
25. Ogawa Y, Ikeda K, Nagahara H, et al. Androgen receptor expression in breast cancer: relationship with clinicopathological factors and biomarkers. *Int J Clin Oncol*. 2008; 13:431-435. <https://doi.org/10.1007/s10147-008-0770-6> PMID:18946753
26. Niemeier LA, Dabbs DJ, Beriwal S, et al. : Androgen receptor in breast cancer: expression in estrogen receptor-positive tumors and in estrogen receptor-negative tumors with apocrine differentiation. *Mod Pathol*. 2010; 23(2):205-12. <https://doi.org/10.1038/modpathol.2009.159> PMID:19898421
27. Collins LC, Cole K, Marotti J, et al. Androgen Receptor Expression in Breast Cancer in Relation to Molecular Phenotype: Results from the Nurses' Health Study. *Mod Pathol*. 2011; 24(7):924-931. <https://doi.org/10.1038/modpathol.2011.54> PMID:21552212 PMID:PMC3128675
28. Aleskandarany MA, Abduljabbar R, Ashankyty I, et al. Prognostic significance of androgen receptor expression in invasive breast cancer: transcriptomic and protein expression analysis. *Breast Cancer Research and Treatment*. 2016; (159):215-227. <https://doi.org/10.1007/s10549-016-3934-5>
29. Gonzalez LO, Corte MD, Vazquez J, et al. Androgen receptor expression in breast cancer: relationship with clinicopathological characteristics of the tumors, prognosis, and expression of metalloproteases and their inhibitors. *BMC Cancer* 2008; 8:149. <https://doi.org/10.1186/1471-2407-8-149> PMID:18507821 PMID:PMC2416360
30. Samaka RM, Younes SF. Androgen Receptor Expression in Breast Carcinoma of Egyptian Patients. *J Clin Diagn Res*. 2016; 10(11):17-21. <https://doi.org/10.7860/JCDR/2016/23364.8919>
31. Putti TC, Abd El-Rehim DM, Rakha EA, et al. Estrogen receptor-negative breast carcinomas: a review of morphology and immunophenotypical analysis. *Modern Pathology*. 2005; 18:26-35. <https://doi.org/10.1038/modpathol.3800255> PMID:15332092
32. Safarpour D, Pakneshan S, and Tavassoli FA. Androgen receptor (AR) expression in 400 breast carcinomas: is routine AR assessment justified. *Am J Cancer Res*. 2014; 4(4):353-368.
33. Qi J, Yang Y, Zhu H, et al. Expression of the Androgen Receptor and its Correlation with Molecular Subtypes in 980 Chinese Breast Cancer Patients. *Breast Cancer* 2012; 6:1-8. <https://doi.org/10.4137/BCBCR.S8323>
34. Vera-Badillo FE, Templeton AJ, de Gouveia P, et al. Androgen Receptor Expression and Outcomes in Early Breast Cancer: A Systematic Review and Meta-Analysis. *J Natl Cancer Inst*. 2014; 106(1):319. <https://doi.org/10.1093/jnci/djt319> PMID:24273215
35. Chottanapund S, Van Duursen MBM, Ratchaworapong K, et al. Androgen Receptor Expression in Thai Breast Cancer Patients. *Med. Sci*. 2016; 4(3):15. <https://doi.org/10.3390/medsci4030015>
36. Agrawal A, Ziolkowski P, Grzebieniak Z, et al. Expression of Androgen Receptor in Estrogen Receptor-positive Breast Cancer. *Appl Immunohistochem Mol Morphol*. 2016; 24(8):550-555. <https://doi.org/10.1097/PAI.0000000000000234> PMID:26230371 PMID:PMC5010278
37. Kohler BA, Sherman RL, Howlander N, et al. Annual report to the nation on the status of cancer, 1975-2011, featuring incidence of breast cancer subtypes by race/ethnicity, poverty, and state. *J Nat Cancer Inst*. 2015; 107(6). <https://doi.org/10.1093/jnci/djv048>
38. Rampurwala M, Wisinski KB, O'Regan R. Role of the Androgen Receptor in Triple-Negative Breast Cancer. *Clin Adv Hematol Oncol*. 2016 Mar; 14(3):186-193.
39. Søjland H, Kørner H, Skaland I, et al. Prognostic Relevance of Androgen Receptor Detection in Operable Breast Cancer. *Journal of Surgical Oncology*. 2008; 98:551-558. <https://doi.org/10.1002/jso.21156> PMID:18937259

40. Ruibal A, Herranz M, Cortes J, et al. Infiltrating Breast Carcinomas Multifocality: Clinical and Biological Features. *The Open Breast Cancer Journal*. 2012; 4:18-23. <https://doi.org/10.2174/1876817201204010018>
41. Harvell DM, Spoelstra NS, Singh M, et al. Molecular signatures of neoadjuvant endocrine therapy for breast cancer: characteristics of response or intrinsic resistance. *Breast Cancer Res Treat*. 2008; 112:475-88. <https://doi.org/10.1007/s10549-008-9897-4> PMID:18327671
42. De Amicis F, Thirugnansampanthan J, Cui Y, et al. Androgen receptor overexpression induces tamoxifen resistance in human breast cancer cells. *Breast Cancer Res Treat*. 2010; 121:1-11. <https://doi.org/10.1007/s10549-009-0436-8> PMID:19533338 PMCID:PMC2995248
43. Arce-Salinas C, Riesco-Martinez MC, Hanna W, et al. Complete response of metastatic androgen receptor-positive breast cancer to bicalutamide: case report and review of the literature. *J Clin Oncol*. 2016; e21-4. <https://doi.org/10.1200/JCO.2013.49.8899>
44. Bonnefoi H, Grellety T, Tredan O, et al. A phase II trial of abiraterone acetate plus prednisone in patients with triple-negative androgen receptor positive locally advanced or metastatic breast cancer (UCBG 12-1). *Ann Oncol*. 2016; 27:812-8. <https://doi.org/10.1093/annonc/mdw067> PMID:27052658
45. CYP17 Lyase and Androgen Receptor Inhibitor Treatment with Seviteronel Trial (INO- VT-464-006; NCT02580448-CLARITY-01), 2015. Available online at: <https://clinicaltrials.gov/ct2/show/NCT02580448> (Last Update Posted: March 2, 2018).
46. Palbociclib in Combination With Bicalutamide for the Treatment of AR(+) Metastatic Breast Cancer (MBC), 2015.