



CASE REPORT

Case Report: Gastric Mucormycosis- a rare but important differential diagnosis of upper gastrointestinal bleeding in an area of *Helicobacter pylori* endemicity [version 1; peer review: 1 approved with reservations, 1 not approved]

Sudeep Adhikari ¹, Ajaya Raj Gautam¹, Buddhi Paudyal ¹, Keshav Raj Sigdel¹,
Buddha Basnyat ²

¹Internal Medicine, Patan Academy of Health Sciences, Kathmandu, Nepal

²Oxford University Clinical Research Unit, Patan Hospital, Kathmandu, Nepal

v1 First published: 17 Jan 2019, 4:5 (<https://doi.org/10.12688/wellcomeopenres.15026.1>)
Latest published: 27 Mar 2019, 4:5 (<https://doi.org/10.12688/wellcomeopenres.15026.2>)

Abstract

A 57 years female from the hills of Nepal presented with upper gastrointestinal bleeding with gastric ulcer evident on endoscopy. Though initially treated with *Helicobacter pylori* (*H. pylori*) eradication therapy alone, biopsy later on revealed both mucormycosis and *H. pylori* infection. She was then treated with antifungals liposomal amphotericin B followed by posaconazole which led to complete recovery. Mucormycosis is a rare but life-threatening fungal disease of immunocompromised host though our patient was immunocompetent. If recognized and treated at early stage, as in our patient, prognosis is good. A high index of suspicion is required for considering this disease in *H. pylori* endemic regions such as Nepal, and is crucial for early recognition and treatment.

Keywords

gastric mucormycosis, mucormycosis, helicobacter pylori, peptic ulcer disease, upper gastrointestinal disease



This article is included in the [Oxford University Clinical Research Unit \(OUCRU\) gateway](#).

Open Peer Review

Referee Status:

Invited Referees

1 2

REVISED

version 2

published
27 Mar 2019

version 1

published
17 Jan 2019

report

report

1 **Gaetano Alfano** , University of Modena and Reggio Emilia, Italy

2 **M. Veronica Dioverti**, John Hopkins University, USA

Any reports and responses or comments on the article can be found at the end of the article.

Corresponding author: Sudeep Adhikari (sudeepadh123@gmail.com)

Author roles: **Adhikari S:** Data Curation, Writing – Original Draft Preparation, Writing – Review & Editing; **Gautam AR:** Data Curation, Resources, Writing – Review & Editing; **Paudyal B:** Conceptualization, Project Administration, Supervision, Writing – Review & Editing; **Sigdel KR:** Supervision, Writing – Review & Editing; **Basnyat B:** Conceptualization, Project Administration, Supervision, Writing – Review & Editing

Competing interests: No competing interests were disclosed.

Grant information: This work was supported by the Wellcome Trust [106680].

The funders had no role in study design, data collection and analysis, decision to publish, or preparation of the manuscript.

Copyright: © 2019 Adhikari S *et al.* This is an open access article distributed under the terms of the [Creative Commons Attribution Licence](https://creativecommons.org/licenses/by/4.0/), which permits unrestricted use, distribution, and reproduction in any medium, provided the original work is properly cited.

How to cite this article: Adhikari S, Gautam AR, Paudyal B *et al.* **Case Report: Gastric Mucormycosis- a rare but important differential diagnosis of upper gastrointestinal bleeding in an area of Helicobacter pylori endemicity [version 1; peer review: 1 approved with reservations, 1 not approved]** Wellcome Open Research 2019, 4:5 (<https://doi.org/10.12688/wellcomeopenres.15026.1>)

First published: 17 Jan 2019, 4:5 (<https://doi.org/10.12688/wellcomeopenres.15026.1>)

Introduction

Upper gastrointestinal bleeding is a common medical emergency which is usually treated with initial stabilization followed by upper gastrointestinal endoscopy. Peptic ulcer disease is a common finding in endoscopy which is usually associated with infection with *Helicobacter pylori* (*H. pylori*)¹. In a developing country such as Nepal, *H. pylori* infection is so common² that treatment with two antibiotics and one proton pump inhibitor therapy, popularly called as 'triple therapy', is usually started empirically for eradication even before the presence of the infection is established. But there can be instances when some rare disease can be the cause of ulcers and bleeding, which if overlooked may lead to a fatal outcome without proper treatment. Here we present a case of upper gastrointestinal bleeding diagnosed as gastric mucormycosis.

Mucormycosis is a rare and often a life-threatening fungal disease, caused by a mold of the order Mucorales, characterized by vascular invasion by hyphae with thrombosis and necrosis³. This is classically a fatal disease of immunocompromised state, with rhino-cerebral, pulmonary and cutaneous being the common types⁴. Contrary to the classical description of this disease, our patient with gastric mucormycosis was an immunocompetent individual who recovered after antifungal treatment.

Case report

A 57 years old, smoker female from Sindhuli, a hilly district of Nepal, with no known comorbidities, presented to the Emergency Department of Patan Hospital, Lagankhel, Lalitpur in April of 2018 with one day history of two episodes of bright red blood-mixed vomitus (around 500 ml per episode), but she had dyspepsia, malena and fatigability for 4 months duration. On assessment, she was pale with blood pressure of 90/50 mmHg and heart rate of 130 beats per minute. She was resuscitated with intravenous fluids and packed cell transfusion.

Laboratory parameters with normal range in parentheses:

Complete blood count before transfusion: white cell count $7.9 (4-10) \times 10^9/L$; neutrophils 70%; lymphocytes 26%; monocytes 4%; red blood cells $2.8 (4.2-5.4) \times 10^{12}/L$; haemoglobin 9 (12-15) g/dL; platelets $295 (150-400) \times 10^9/L$.

Biochemistry: random blood sugar 124 (65-110)mg/dL; urea 49 (17-45) mg/dL; creatinine 0.9 (0.8-1.3) mg/dL; sodium 140 (135-145) mmol/L and potassium 4 (3.5-5) mmol/L.

Hepatic panel: bilirubin total 1 (0.1-1.2) mg/dL and direct 0.6 (0-0.4) mg/dL; alanine transaminase 35 (5-30) units/L; aspartate transaminase 40 (5-30) units/L; alkaline phosphatase 98 (50-100) IU/L; albumin 3.5 (3.5-5) g/dL

After stabilization, she underwent upper gastrointestinal endoscopy the same day which revealed an ulcer (10 mm × 6 mm) in lesser curvature of the stomach without active bleeding. The provisional diagnosis was gastric ulcer due to *H. pylori*

infection. The main differential diagnosis was gastric carcinoma, hence biopsy was taken from the ulcer.

She was started on triple therapy regimen empirically for *H. pylori* eradication containing clarithromycin 500 mg, amoxicillin 1 gm and pantoprazole 40 mg twice daily for 14 days, and discharged. When she returned for follow-up, the histopathology showed fungi with broad ribbon like morphology, fruiting bodies consistent with mucor in the ulcer, as well as in granulation tissue suggesting fungal invasion but no necrosis or vascular thrombi (Figure 1). It was also positive for *H. pylori* in Giemsa staining. She was diagnosed with gastric mucormycosis with *H. pylori* coinfection. She was readmitted and started on liposomal amphotericin B, 5 mg/kg on the first day followed by 10 mg/kg for the next 13 days. After a total of 2 weeks of therapy she was discharged with posaconazole 300 mg once daily, as an oral step-down therapy.

On repeat follow up in 1 month, she was asymptomatic. Repeat endoscopy showed a healing ulcer in lesser curvature of stomach. She took posaconazole for one more month. She was doing well when she was last followed up in October 2018.

Discussion

Our patient presented with upper gastrointestinal bleed, and received *H. pylori* eradication treatment empirically after ulcer was evident on endoscopy. This is standard practice in Nepal as prevalence of *H. pylori* infection is very high in the general population², and it is also not always possible to perform tests for *H. pylori* detection as the tests are either unavailable or unaffordable. Fortunately, we took a gastric biopsy to try to rule out gastric malignancy. The biopsy serendipitously helped to clinch the proper diagnosis of gastric mucormycosis, which otherwise would not have been possible. Though our patient

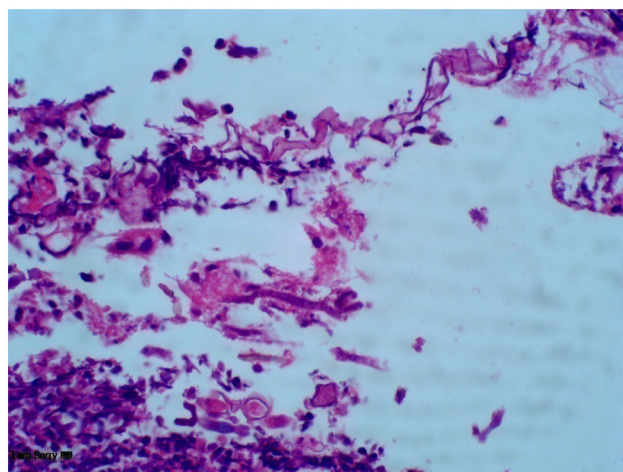


Figure 1. Histopathology examination of ulcer showing fungi with broad ribbon like morphology and fruiting bodies consistent with mucor.

had coinfection with *H. pylori*, the diagnosis of mucormycosis became alarming because of its high fatality, and the need of specific antifungal treatment with amphotericin B.

Mucormycosis is a life threatening disease occurring in immunocompromised patients. The known risk factors for this disease include diabetes mellitus, particularly with ketoacidosis, treatment with glucocorticoids, hematologic malignancies, hematopoietic cell or solid organ transplantation, treatment with deferoxamine, iron overload, AIDS, injection drug use, trauma/burns, premature birth and malnutrition⁵. But our patient had none of these risk factors, yet suffered from the disease.

The common sites of mucormycosis are the sinuses (39%), lungs (24%) and skin (19%). The gastrointestinal tract is involved in only 7% of patients, with the stomach being the most common site. Gastrointestinal mucormycosis is usually fatal (85% mortality)^{4,6}. It can be classified into three forms- colonization of pre-existing ulcer, infiltration, and vascular invasion, with increasing fatality in this order⁷. Juan *et al.* have reviewed 12 cases of gastrointestinal mucormycosis in immunocompetent individuals, out of which only one survived³. Tathe *et al.* reported a case of gastric mucormycosis associated with gastric ulcer who recovered with antifungal treatment, and hypothesized that survival was due to detection and treatment at early nonfatal stage of the disease (colonization with early infiltration of pre-existing ulcer by the fungi rather than invasive ulcerative form of the disease which is almost always fatal)⁸. Another case who survived after surgery and antifungal treatment had chronic granulomatous and suppurative gastritis with zygomycosis hyphae⁹. The survival of our patient may be attributed to it being the less invasive form of disease, the absence of necrosis and thrombosis, and possibly also because of early diagnosis and prompt treatment.

Though validation by epidemiological studies is yet to be done, the estimated burden of mucormycosis in Nepal has been reported as 0.2 per 100000 per year¹⁰, while in India it is estimated at 0.14 per 100000¹¹. A study in Nepal reported 3 cases of mucormycosis among 331 cases of benign sinonasal masses¹², but no account of the gastrointestinal form of disease has been documented in Nepal. The prevalence of mucormycosis appears to be low in Nepal, and we do not routinely consider its possibility in the differential diagnosis of peptic ulcer disease. Our case demonstrates the obvious usefulness of doing a proper gastric histopathological study, where available, even in areas of *H. pylori* endemicity.

Conclusion

Rare diseases like gastric mucormycosis may present as upper gastrointestinal bleeding, mimicking peptic ulcer disease. It may also co-exist with *H. pylori* infection. Mucormycosis is a life-threatening fungal disease of immunocompromised state, but it may rarely affect immunocompetent individuals too. Though usually fatal, recognition and treatment at its early stage may lead to recovery.

Consent

Written informed consent for publication of clinical details and clinical images was obtained from the patient herself.

Data availability

All data underlying the results are available as part of the article and no additional source data are required

Grant information

This work was supported by the Wellcome Trust [106680].

The funders had no role in study design, data collection and analysis, decision to publish, or preparation of the manuscript.

References

- Chen ZJ, Freeman ML: **Management of upper gastrointestinal bleeding emergencies: evidence-based medicine and practical considerations.** *World J Emerg Med.* 2011; **2**(1): 5–12.
[PubMed Abstract](#) | [Free Full Text](#)
- Sherpa TW, Sherpa KT, Nixon G, *et al.*: **The prevalence of Helicobacter pylori infection in Sherpa residents of the Upper Khumbu, an isolated community in Eastern Nepal.** *N Z Med J.* 2012; **125**(1365): 30–7.
[PubMed Abstract](#)
- Juan Hu, Xinxin Zhou, Chengfu Xu, *et al.*: **Fatal gastrointestinal mucormycosis in an immunocompetent patient: a case report and review of the literature.** *Int J Clin Exp Med.* 2018; **11**(4): 4301–4306.
[Reference Source](#)
- Roden MM, Zaoutis TE, Buchanan WL, *et al.*: **Epidemiology and outcome of zygomycosis: a review of 929 reported cases.** *Clin Infect Dis.* 2005; **41**(5): 634–653.
[PubMed Abstract](#) | [Publisher Full Text](#)
- Cox GM: **Mucormycosis (zygomycosis).** In: *UpToDate*, Kauffman CA, Thorer AR (Ed), UpToDate, Waltham, MA. (Accessed on October 27, 2018).
[Reference Source](#)
- Agha FP, Lee HH, Boland CR, *et al.*: **Mucormycoma of the colon: early diagnosis and successful management.** *AJR Am J Roentgenol.* 1985; **145**(4): 739–741.
[PubMed Abstract](#) | [Publisher Full Text](#)
- Thomson SR, Bade PG, Taams M, *et al.*: **Gastrointestinal mucormycosis.** *Br J Surg.* 1991; **78**(8): 952–954.
[PubMed Abstract](#) | [Publisher Full Text](#)
- Tathe SP, Dani AA, Chawhan SM, *et al.*: **Gastric mucormycosis: Diagnosis by imprint cytology.** *Diagn Cytopathol.* 2016; **44**(10): 820–822.
[PubMed Abstract](#) | [Publisher Full Text](#)
- Abreu BFBB, Duarte ML, Santos LRD, *et al.*: **A rare case of gastric mucormycosis in an immunocompetent patient.** *Rev Soc Bras Med Trop.* 2018; **51**(3): 401–402.
[PubMed Abstract](#) | [Publisher Full Text](#)
- Khwakhali US, Denning DW: **Burden of serious fungal infections in Nepal.** *Mycoses.* 2015; **58** Suppl 5: 45–50.
[PubMed Abstract](#) | [Publisher Full Text](#)
- Chakrabarti A, Sood P, Denning DW: **Estimating fungal infection burden in India using computational models: mucormycosis burden as a case study.** In: 23rd European Congress of Clinical Microbiology and Infectious Diseases (ECCMID, 23rd) Berlin 2013 Apr (p. P1044).
[Reference Source](#)
- Nepal A, Chettri ST, Joshi RR, *et al.*: **Benign sinonasal masses: a clinicopathological and radiological profile.** *Kathmandu Univ Med J (KUMJ).* 2013; **11**(41): 4–8.
[PubMed Abstract](#) | [Publisher Full Text](#)

Open Peer Review

Current Referee Status:



Version 1

Referee Report 20 March 2019

<https://doi.org/10.21956/wellcomeopenres.16394.r34802>



M. Veronica Dioverti

John Hopkins University, Baltimore, MD, USA

The authors presented a case of a 57 yo immunocompetent patient that presented with upper GI bleed, diagnosed with H pylori and latter with mucormycosis based on path. She was treated with antifungals alone. There is no mention of evaluation for surgical intervention, which is mainstay therapy for this invasive fungal infection.

Overall, grammar needs to be further reviewed and corrected (probably needs re-writting); for example: "A 57 years old, smoker female from Sindhuli, a hilly district of Nepal, with no known comorbidities, presented to the Emergency Department of Patan Hospital, Lagankhel, Lalitpur in April of 2018 with one day history of two episodes of bright red blood-mixed vomitus (around 500 ml per episode), but she had dyspepsia, malena and fatigability for 4 months duration. On assessment, she was pale with blood pressure of 90/50 mmHg and heart rate of 130 beats per minute" should read: A 57 year old female from Sindhuli, Nepal, no known medical comorbidities other than smoking, presented to the emergency department with two episodes of hematemesis over 24 hours. She had a 4-month history of dyspepsia, melena and fatigability. On physical exam, she was pale, blood pressure was 90/50 mmgHg with a heart rate of 130 beats per minute"

"Laboratory parameters with normal ranges in parenthesis, are as follow:"

Question #1 - Background history/case progression:

- Histopathology: granulation tissue suggesting fungal invasion? Was there fungal invasion or no? This should be discernable on path, there should be clear necrosis and vascular invasion in order to make a diagnosis of invasive mucor.
- Was surgical intervention entertained? This is a crucial component of mucormycosis management
- Was posaconazole level checked? This is important for treatment follow up

Question #2:

Physical exam/labs: only physical exam comments were that patient was "pale" and they provided blood pressure/heart rate. How about abdominal pain, guarding? Any other ominous signs/symptoms? Was imaging obtained? Oftentimes, mucor will invade nearby tissue. For laboratory, was there a culture sent? In terms of treatment follow up, did she tolerate high doses of amphotericin? Was a posaconazole level checked prior to stopping amphotericin?

Question #3:

Authors should extend discussion to include how were other patients managed? Typically, management includes surgery. Duration of antifungal therapy is typically longer that 1 month, indicating that perhaps

this was not the correct diagnosis? How long were the other case reported treated for?

Question #4:

More details need to be included as mentioned above

References

1. Dioverti MV, Cawcutt KA, Abidi M, Sohail MR, Walker RC, Osmon DR: Gastrointestinal mucormycosis in immunocompromised hosts. *Mycoses*. 2015; **58** (12): 714-8 [PubMed Abstract](#) | [Publisher Full Text](#)

Is the background of the case's history and progression described in sufficient detail?

Partly

Are enough details provided of any physical examination and diagnostic tests, treatment given and outcomes?

Partly

Is sufficient discussion included of the importance of the findings and their relevance to future understanding of disease processes, diagnosis or treatment?

No

Is the case presented with sufficient detail to be useful for other practitioners?

Partly

Competing Interests: No competing interests were disclosed.

Reviewer Expertise: Transplant and oncology infectious diseases; fungal infections in immunocompromised patients; CMV infections in immunocompromised patients

I have read this submission. I believe that I have an appropriate level of expertise to state that I do not consider it to be of an acceptable scientific standard, for reasons outlined above.

Author Response 23 Mar 2019

Sudeep Adhikari, Patan Academy of Health Sciences, Nepal

Thank you for your constructive feedback to our manuscript.

The grammar has been reviewed and corrected as suggested by the reviewer.

Question #1 - Background history/case progression:

- Histopathology: granulation tissue suggesting fungal invasion? Was there fungal invasion or no? This should be discernable on path, there should be clear necrosis and vascular invasion in order to make a diagnosis of invasive mucor.
- Was surgical intervention entertained? This is a crucial component of mucormycosis management
- Was posaconazole level checked? This is important for treatment follow up

Response to question 1

- In the histopathology examination there was no evidence of fungal invasion, as necrosis and vascular invasion were not present. Changes have been made in the revised manuscript.

- Surgical intervention was not done, as our patient had early form of the disease. Case reports where medical therapy alone was used for the management, have been cited in the revised manuscript. (1,2)
- The need of overlapping amphotericin and posaconazole before stopping amphotericin till the therapeutic level of posaconazole is achieved has been discussed in the revised manuscript. (3) But the unavailability of the test of blood level of posaconazole in our setup hindered the use of the standard management practice in our case.

Question #2:

Physical exam/labs: only physical exam comments were that patient was "pale" and they provided blood pressure/heart rate. How about abdominal pain, guarding? Any other ominous signs/symptoms? Was imaging obtained? Oftentimes, mucor will invade nearby tissue. For laboratory, was there a culture sent? In terms of treatment follow up, did she tolerate high doses of amphotericin? Was a posaconazole level checked prior to stopping amphotericin?

Response to question 2

- Other physical examinations were unremarkable, including the abdominal exam.
- Abdominal imaging to exclude the invasion of nearby tissue was not done, as our patient had non-invasive form of the disease.
- Confirmation of the infection via culture was not done, because this test is not readily available in our setup.
- Our patient had no complication on using amphotericin B. The hospital stay was uneventful.
- Posaconazole level testing is not available in our setup.

Question #3:

Authors should extend discussion to include how were other patients managed? Typically, management includes surgery. Duration of antifungal therapy is typically longer than 1 month, indicating that perhaps this was not the correct diagnosis? How long were the other case reported treated for?

Response to question 3

- Case reports of using medical therapy alone without the surgery, have been included in the discussion.
- Our patient received posaconazole for 2 months only due to financial constraints. But she had clinical as well as histopathological remission from the disease. One case was treated for 6 months with antifungal therapy. (1)

Question #4:

More details need to be included as mentioned above

Response to question 4

- Details have been added as suggested.

References

1. Alfano G, Fontana F, Francesca D, Assirati G, Magistri P, Tarantino G, Ballarin R, Rossi G, Franceschini E, Codeluppi M, Guaraldi G, Mussini C, Di Benedetto F, Cappelli G: Gastric Mucormycosis in a Liver and Kidney Transplant Recipient: Case Report and Concise Review of Literature. *Transplant Proc.* 2018; **50** (3): 905-909
2. Tathe SP, Dani AA, Chawhan SM, et al.: Gastric mucormycosis: Diagnosis by imprint cytology. *Diagn Cytopathol.* 2016;44(10):820–822. 27321416 10.1002/dc.23518

3. Dioverti MV, Cawcutt KA, Abidi M, Sohail MR, Walker RC, Osmon DR: Gastrointestinal mucormycosis in immunocompromised hosts. *Mycoses*. 2015; **58** (12): 714-8 [PubMed Abstract](#) | [Publisher Full Text](#)

Competing Interests: No competing interests were disclosed.

Referee Report 13 March 2019

<https://doi.org/10.21956/wellcomeopenres.16394.r34951>



Gaetano Alfano

Surgical, Medical and Dental Department of Morphological Sciences, Section of Nephrology, University of Modena and Reggio Emilia, Modena, Italy

Adhikari et al. describe an interesting case of gastric mucormycosis in an immunocompetent patient coming from an area where *H. Pylori* infection is endemic (Nepal). The case is singular because histological examination of the biopsy specimen obtained from the gastric ulcer showed a confection of *Mucormycetes* and *H. Pyroli*. Additionally, the case underlined the importance of histologic examination in the early diagnosis of *Mucormycosis* organisms.

Some further information should be provided in order to improve the quality of the manuscript:

- The text lacks data regarding the clinical course of the patients after admission. In particular, the authors should describe the change in gastrointestinal symptomatology with the start of the specific therapy.
- Please discuss if culture of gastric mucosal specimen or molecular analysis were performed to identify *Mucormycetes*
- It is well-known that the management of *Mucormycetes* infection is based on the prompt institution of appropriate antifungal therapy and surgery. Studies report that surgical treatment has been associated with improved survival when combined with medical treatment (Roden et al., 2005¹; Turner, Soudry, Nayak, & Hwang, 2013²).

Since the patient did not undergo surgical debridement of the gastric ulcer, the authors should discuss why surgical intervention was not performed.

On this issue, we published a similar case that was successfully treated with a conservative strategy. After the diagnosis of *Mucormycosis*, surgery was postponed because the institution of antifungal therapy controlled the disease and resolved the gastrointestinal symptoms progressively (Alfano et al., 2018³). Although this therapeutic strategy cannot be generalized in absence of randomized controlled trial, antifungal therapy may be considered a first attempt in the early stage of a gastric mucormycosis of non-critically ill patients. Authors may underline that further studies are necessary to establish the best treatment of uncomplicated cases of gastric mucormycosis.

References

1. Roden MM, Zaoutis TE, Buchanan WL, Knudsen TA, Sarkisova TA, Schaufele RL, Sein M, Sein T, Chiou CC, Chu JH, Kontoyiannis DP, Walsh TJ: Epidemiology and outcome of zygomycosis: a review of 929 reported cases. *Clin Infect Dis*. 2005; **41** (5): 634-53 [PubMed Abstract](#) | [Publisher Full Text](#)
2. Turner JH, Soudry E, Nayak JV, Hwang PH: Survival outcomes in acute invasive fungal sinusitis: a

systematic review and quantitative synthesis of published evidence. *Laryngoscope*. 2013; **123** (5): 1112-8 [PubMed Abstract](#) | [Publisher Full Text](#)

3. Alfano G, Fontana F, Francesca D, Assirati G, Magistri P, Tarantino G, Ballarin R, Rossi G, Franceschini E, Codeluppi M, Guaraldi G, Mussini C, Di Benedetto F, Cappelli G: Gastric Mucormycosis in a Liver and Kidney Transplant Recipient: Case Report and Concise Review of Literature. *Transplant Proc*. 2018; **50** (3): 905-909 [PubMed Abstract](#) | [Publisher Full Text](#)

Is the background of the case's history and progression described in sufficient detail?

Partly

Are enough details provided of any physical examination and diagnostic tests, treatment given and outcomes?

Yes

Is sufficient discussion included of the importance of the findings and their relevance to future understanding of disease processes, diagnosis or treatment?

Yes

Is the case presented with sufficient detail to be useful for other practitioners?

Yes

Competing Interests: No competing interests were disclosed.

Reviewer Expertise: Nephrology, immunology, infectious disease.

I have read this submission. I believe that I have an appropriate level of expertise to confirm that it is of an acceptable scientific standard, however I have significant reservations, as outlined above.

Author Response 23 Mar 2019

Sudeep Adhikari, Patan Academy of Health Sciences, Nepal

Thank you for your constructive feedback.

Question- The text lacks data regarding the clinical course of the patients after admission. In particular, the authors should describe the change in gastrointestinal symptomatology with the start of the specific therapy.

Response- Our patient's initial symptoms were resolved during the therapy with antifungal agents. This has been added in the manuscript.

Question- Please discuss if culture of gastric mucosal specimen or molecular analysis were performed to identify Mucormycetes

Response- Culture of gastric mucosal specimen or molecular analysis were not performed as these tests are not readily available in our setup.

Question- It is well-known that the management of Mucormycetes infection is based on the prompt institution of appropriate antifungal therapy and surgery. Studies report that surgical treatment has been associated with improved survival when combined with medical treatment

(Roden et al., 2005¹; Turner, Soudry, Nayak, & Hwang, 2013²). Since the patient did not undergo surgical debridement of the gastric ulcer, the authors should discuss why surgical intervention was not performed.

On this issue, we published a similar case that was successfully treated with a conservative strategy. After the diagnosis of Mucormycosis, surgery was postponed because the institution of antifungal therapy controlled the disease and resolved the gastrointestinal symptoms progressively (Alfano et al., 2018³). Although this therapeutic strategy cannot be generalized in absence of randomized controlled trial, antifungal therapy may be considered a first attempt in the early stage of a gastric mucormycosis of non-critically ill patients. Authors may underline that further studies are necessary to establish the best treatment of uncomplicated cases of gastric mucormycosis.

Response- The surgical intervention is one important component of management. But we did not opt for the surgical management as our patient had early non-invasive form of the disease. Examples of cases where the early disease had been managed by antifungals alone have given in the revised manuscript.

Competing Interests: No competing interests were disclosed.