

## Retrospective Study

## Surgical complications after different therapeutic approaches for locally advanced rectal cancer

Tian-Cheng Zhan, Da-Kui Zhang, Jin Gu, Ming Li

**ORCID number:** Tian-Cheng Zhan (0000-0002-4711-5505); Da-Kui Zhang (0000-0001-7599-3404); Jin Gu (0000-0002-9650-1963); Ming Li (0000-0002-6753-6905).

**Author contributions:** Li M and Zhan TC contributed to the design and organization of the study, the acquisition of data, the analysis and interpretation of data, and drafting the article; Gu J and Zhang DK contributed to the design and organization of the study, the acquisition of data, and drafting the article.

**Informed consent statement:** This study is a retrospective study. As confirmed by the Ethics Committee of Beijing Cancer Hospital, no additional informed consent statement is required.

**Conflict-of-interest statement:** There are no conflicts of interest or source of funding.

**Open-Access:** This article is an open-access article which was selected by an in-house editor and fully peer-reviewed by external reviewers. It is distributed in accordance with the Creative Commons Attribution Non Commercial (CC BY-NC 4.0) license, which permits others to distribute, remix, adapt, build upon this work non-commercially, and license their derivative works on different terms, provided the original work is properly cited and the use is non-commercial. See: <http://creativecommons.org/licenses/by-nc/4.0/>

**Manuscript source:** Unsolicited

**Tian-Cheng Zhan, Jin Gu, Ming Li,** Key Laboratory of Carcinogenesis and Translational Research (Ministry of Education), Department of Colorectal Surgery, Peking University Cancer Hospital and Institute, Beijing Cancer Hospital, Beijing 100142, China

**Da-Kui Zhang,** Department of General Surgery, China-Japan Friendship Hospital, Beijing 100029, China

**Corresponding author:** Ming Li, MD, Professor, Key Laboratory of Carcinogenesis and Translational Research (Ministry of Education), Department of Colorectal Surgery, Peking University Cancer Hospital and Institute, No. 52 Fucheng Road, Haidian District, Beijing 100142, China. [limingmd@126.com](mailto:limingmd@126.com)

**Telephone:** +86-10-88196086

**Fax:** +86-10-88196086

## Abstract

### BACKGROUND

Preoperative radiochemotherapy is widely used in locally advanced rectal cancer. It can improve local control of rectal cancer. However, some researchers believe it increases the incidence of surgical complications. They doubt its safety. Patients with locally advanced rectal cancer receive three different treatments in our hospital, including long-course radiochemotherapy, short-course radiotherapy, and surgery directly. We can compare their differences in postoperative complications.

### AIM

To investigate surgical complications caused by different preoperative radiotherapy regimens.

### METHODS

We retrospectively analyzed 1197 patients admitted between 2008 and 2010 with locally advanced rectal cancer. Three hundred and forty-six patients were treated with preoperative long-course radiochemotherapy (25 × 2 Gy) followed by total mesorectal excision (TME) 6–8 wk later, and 259 patients received short-course radiotherapy (10 × 3 Gy) and subsequently TME 7–10 d later. The remaining 592 patients underwent TME alone without neoadjuvant therapy. According to Clavien–Dindo classification, surgical complications were evaluated for up to 30 d after discharge from hospital.

### RESULTS

There were no deaths in 30 d in all groups after treatment. The major

manuscript

**Received:** December 26, 2019**Peer-review started:** December 27, 2019**First decision:** January 11, 2019**Revised:** March 16, 2019**Accepted:** March 26, 2019**Article in press:** March 26, 2019**Published online:** May 15, 2019**P-Reviewer:** Arias F, Gurzu S**S-Editor:** Wang JL**L-Editor:** Filipodia**E-Editor:** Wu YXJ

complications were anastomotic leakage and perineal wound complications. The results suggested that both long-course [odds ratio (OR) = 3.624, 95% confidence interval (CI): 1.689–7.775,  $P = 0.001$ ] and short-course (OR = 5.150, 95% CI: 1.828–14.515,  $P = 0.002$ ) radiotherapy were associated with anastomotic leakage. Temporary ileostomy was a protective factor for anastomotic leakage (OR = 6.211, 95% CI: 2.525–15.385,  $P < 0.001$ ). The severity of anastomotic leakage did not increase in patients following preoperative radiotherapy ( $P = 0.411$ ). Compared with TME alone, short-course radiotherapy was associated with an increase in perineal wound complications (OR = 5.565, 95% CI: 2.203–14.057,  $P < 0.001$ ), but long-course radiotherapy seemed safe regarding this complication (OR = 1.692, 95% CI: 0.651–4.394,  $P = 0.280$ ). Although the severity of perineal wound complications increased in patients following short-course radiotherapy ( $P < 0.001$ ), additional intervention was not necessary.

### CONCLUSION

Radiotherapy increased the incidence but not severity of anastomotic leakage. Short-course radiotherapy was also accompanied with perineal wound complications, but intervention appeared unnecessary to ameliorate the complications.

**Key words:** Rectal cancer; Radiotherapy; Surgical complications; Total mesorectal excision; Anastomotic leakage

©The Author(s) 2019. Published by Baishideng Publishing Group Inc. All rights reserved.

**Core tip:** Preoperative radiotherapy is a promising treatment for rectal cancer. Our aim is to investigate surgical complications caused by radiotherapy. Both long-course and short-course radiotherapy increased the incidence of anastomotic leakage but did not affect the severity. Additional ileostomy was an effective method to reduce the risk of anastomotic leakage. Short-course radiotherapy was accompanied with increased incidence of perineal wound complications, but intervention appeared unnecessary to ameliorate the complications.

**Citation:** Zhan TC, Zhang DK, Gu J, Li M. Surgical complications after different therapeutic approaches for locally advanced rectal cancer. *World J Gastrointest Oncol* 2019; 11(5): 393-403

**URL:** <https://www.wjgnet.com/1948-5204/full/v11/i5/393.htm>

**DOI:** <https://dx.doi.org/10.4251/wjgo.v11.i5.393>

## INTRODUCTION

Patients with locally advanced rectal cancer were recommended to receive neoadjuvant radiochemotherapy, especially for those with positive circumferential resection margin or extensive nodal involvement. It can improve local control for these patients. The rate of local recurrence has decreased significantly as a result of neoadjuvant radiochemotherapy. Some researchers believe that preoperative radiotherapy can improve survival of patients with resectable rectal cancer. It is suggested that patients who are sensitive to radiotherapy can achieve better prognosis. Approximately 15% of patients can achieve complete response after long-course neoadjuvant radiochemotherapy<sup>[1]</sup>. Different protocols for short-course radiotherapy that consists of 30 Gy in 10 fractions are recommended by the Chinese Anti-Cancer Association<sup>[2]</sup>. The biological equivalent dose of the short-course radiotherapy is similar to the commonly used regimen (5 × 5 Gy). Although the tumor regression is not as good as with long-course radiochemotherapy, with < 5% complete response rate, the advantages are no surgical delay, reduced toxicity from capecitabine, and avoidance of overtreatment of non-responders. However, some surgeons believe that preoperative radiochemotherapy increases surgical complications. Anastomotic leakage is thought to be associated with malnutrition resulting from radiotherapy<sup>[3]</sup>. Perineal wound complications after abdominoperineal resection (APR) are also considered to be associated with tissue edema and infection caused by radiotherapy. In addition, toxicity of radiochemotherapy may decrease patients' tolerance to surgery.

The aim of this study was to evaluate surgical complications of patients with locally advanced rectal cancer following different neoadjuvant therapy and radical surgery. We compared the incidence and severity of surgical complications at 30 d after surgery in different groups and the contribution of neoadjuvant therapy to surgical complications.

## MATERIALS AND METHODS

### Patients

We performed a retrospective consecutive study of 1197 patients with mid-to-low rectal cancer ( $\leq 10$  cm from anal verge) who received low anterior resection and APR at the Peking University Cancer Hospital between 2008 and 2010. Among them, 346 patients were treated with long-course chemoradiotherapy, and 259 received short-course radiotherapy. Radical resection was performed in all patients. The remaining 592 patients received total mesorectal excision (TME) immediately after rectal cancer was diagnosed. Surgical complications were evaluated for up to 30 d after discharge from hospital according to Clavien–Dindo classification. The median duration of admission for patients who underwent resection was 19 (range 5–81) d. Among them, 197 patients (16.3%) were hospitalized for  $> 30$  d.

### Radiotherapy

Two different neoadjuvant radiotherapy regimens were applied. Three hundred and forty-six patients received long-course preoperative radiochemotherapy that consisted of 50 Gy in 25 fractions with capecitabine (825 mg/m<sup>2</sup>, twice daily) as radiosensitizer. The other 259 patients were treated with short-course radiotherapy that consisted of 30 Gy in 10 fractions. Its biological equivalent dose was 36 Gy, which was close to the dose of  $5 \times 5$  Gy radiation (37.5 Gy).

### Surgery

TME was the standard approach for surgical treatment of rectal cancer. All patients underwent laparotomy at Beijing Cancer Hospital at 6–8 wk after long-course radiochemotherapy or 7–10 d after short-course radiotherapy. Low anterior resection (LAR) was performed in 894 patients. Temporary ileostomy was performed based on the pathological conditions during the operation. APR was performed in 303 patients.

### Surgical complications

Surgical complications were evaluated using predetermined conditions of common complications (Table 1). The main complications are anastomotic leakage and perineal wound complications. The definition of anastomotic leakage was different from those in the literature. It was confirmed by detection of fluid collection through the drainage tubes. Digital rectal examinations were used to evaluate the size of the leakage. Computed tomography was not routinely performed unless puncture drainage or surgical reintervention was needed. The severity of these complications was evaluated by Clavien–Dindo classification (Table 2).

### Statistical analysis

The association between neoadjuvant radiotherapy and surgical complications was analyzed using two-sided  $\chi^2$  or Fisher's exact test. The two key complications, anastomotic leakage and perineal wound complications, were also evaluated. The clinical variables included general information about the patients and tumor characteristics, as well treatment-related variables such as diverting ileostomy. Logistic regression was performed to investigate the independent factors associated with anastomotic leakage and perineal wound complications.  $P < 0.05$  was considered as statistically significant.

## RESULTS

### Groups and patient characteristics

A total of 1197 patients with locally advanced rectal cancer who received LAR and APR were analyzed. They all underwent laparotomy. The patients were divided into three groups according to different preoperative therapy (Figure 1). Group 1: 346 patients treated with preoperative long-course chemoradiotherapy followed by TME 6–8 wk after. Group 2: 259 patients were treated with short-course radiotherapy ( $10 \times 3$  Gy) followed by TME 7–10 d after. Group 3: 592 patients received radical surgery only. Patient and tumor characteristics are summarized in Table 3. The median

**Table 1** Definition of postoperative surgical complications (during admission and 30 d thereafter)

	Definition
Anastomotic leakage	Any gas or feces collection around the anastomosis after low anterior resection in the drainage tubes; clinical suspicion confirmed by surgery
Perineal wound complications	Perineal wound dehiscence and wound necrosis after abdominoperineal resection resulting from infection
Ileus	Absence of bowel sounds or defecation after 5 d following surgery
Bleeding	Gastrointestinal or abdominal hemorrhage, decrease in hemoglobin level directly after surgery treated conservatively with blood transfusion or by reintervention
Intra-abdominal abscess	Any intra-abdominal fluid collection unrelated to the anastomosis or perineal wound
Abdominal wound complications	Fascial dehiscence, superficial wound infection
Urological complications	Ureter leakage, urinary incontinence, ureter stenosis
Intestinal necrosis	Caused by bowel ischemia
Gastrointestinal perforation	Intestinal contents discharge from abdominal cavity; clinical suspicion confirmed by surgery
Intravenous line infection	Fever, chills and increase in leukocyte count, excluding other infections; the symptoms disappear after removing the intravenous line
Stoma complications	Stoma necrosis, stoma infection, parastomal hernia
General complications	Cardiovascular, pulmonary, neurological events

duration of admission for patients who underwent resection was 19 (range 5–81) d. One hundred and ninety-seven patients (16.3%) stayed in the hospital for > 30 d.

#### **Treatment-related postoperative complications**

Eight hundred and ninety-four patients underwent LAR, and 303 patients received APR. There were no deaths within 30 d after surgery. Forty-three patients required surgical reintervention. We analyzed 12 different complications, including anastomotic leakage, perineal wound complications, ileus, bleeding, intra-abdominal abscess, abdominal wound complications, urological complications, intestinal necrosis, gastrointestinal perforation, intravenous line infection, stoma complications, and general complications. Anastomotic leakage and perineal wound complications were the two major complications after resection. The severity of postoperative complications is summarized in Table 4. There were no significant differences in the grade of treatment-related complications except for perineal wound complications. Higher grade of perineal wound complication was observed in patients following short-course radiotherapy.

In 894 patients who received LAR, anastomotic leakage was the most obvious complication. Anastomotic leakage developed in 48 (5.4%) patients. Nineteen (2.1%) patients who required surgical reintervention were classified as Grade 3b according to the Clavien–Dindo classification. Our data suggested that preoperative radiotherapy ( $P = 0.001$ ) and diverting ileostomy ( $P < 0.001$ ) were significant independent factors (Table 5). Both long-course [odds ratio (OR) = 3.624, 95% confidence interval (CI): 1.689–7.775,  $P = 0.001$ ] and short-course (OR = 5.150, 95%CI: 1.828–14.515,  $P = 0.002$ ) neoadjuvant radiotherapy increased the incidence of anastomotic leakage (6.78%, 5.96%, and 4.54% in Groups 1, 2, and 3, respectively), but neither was associated with the severity of the complication ( $P = 0.411$ ) (Table 4). Temporary diverting ileostomy was a protective factor to reduce the incidence of anastomotic leakage (OR = 6.211, 95%CI: 2.525–15.385,  $P < 0.001$ ). The majority of patients with neoadjuvant radiotherapy underwent additional surgery of temporary ileostomy, especially in those with short-course radiotherapy (69.4%, 83.1%, and 7.4% in Groups 1, 2, and 3, respectively,  $P < 0.001$ ).

Three hundred and three patients received APR. More than 16.5% of patients suffered from perineal wound complications. The incidence of perineal wound complications in the three groups was 11.8%, 26.8%, and 9.4%, respectively. Short-course chemoradiotherapy was closely associated with perineal wound complications (OR = 5.565, 95%CI: 2.203–14.057,  $P < 0.001$ ). In contrast, long-course radiochemotherapy did not significantly influence development of perineal wound complications (OR = 1.692, 95%CI: 0.651–4.394,  $P = 0.280$ ) (Table 6). The grade of these complications differed significantly among the three groups ( $P < 0.001$ ) (Table 4). Patients receiving short-course radiotherapy had higher-grade perineal wound complications. However, there were no Grade 3b perineal wound complications, and

Table 2 Clavien–Dindo classification of surgical complications

Grade	Definition
I	Any deviation from the normal postoperative course without the need for pharmacological treatment or surgical, endoscopic and radiologic interventions. Allowed therapeutic regimens are drugs including antiemetics, antipyretics, analgesics and diuretics, and electrolytes and physiotherapy. This grade also includes wound infections opened at the bedside.
II	Requiring pharmacological treatment with drugs other than those allowed for grade I complications. Blood transfusions and total parenteral nutrition are also included.
III	Requiring surgical, endoscopic or radiological intervention
IIIa	Intervention not under general anesthesia
IIIb	Intervention under general anesthesia
IV	Life-threatening complication (including CNS complications) <sup>1</sup> requiring IC/ICU management
IVa	Single organ dysfunction (including dialysis)
IVb	Multiple organ dysfunction
V	Death as a result of complications

<sup>1</sup>Brain hemorrhage, ischemic stroke, or subarachnoid bleeding, but excluding transient ischemic attacks. Adapted from Clavien–Dindo classification. CNS: Central nervous system; IC: Intermediate care; ICU: Intensive care unit.

none of these patients required surgical reintervention.

### Reintervention

Among all the studied patients, only 43 with Grade 3b complications required reintervention. The reasons included anastomotic leakage, ileus, bleeding, intra-abdominal abscess, abdominal wound complications, urological complications, and intestinal necrosis. Some patients with anastomotic leakage required reintervention. The reintervention rate for anastomotic leakage repair in all three groups did not differ significantly (37.5%, 66.7%, and 30.4% in Groups 1, 2, and 3, respectively,  $P = 0.411$ ), indicating that neither long-course nor short-course radiotherapy increased the need for reintervention. The increase in perineal wound complications caused by short-course radiotherapy was mild. None of the patients with perineal wound complications required reintervention.

## DISCUSSION

Neoadjuvant radiochemotherapy has become important to reduce local recurrence of locally advanced rectal cancer. In China, an increasing number of patients have been recommended to receive radiotherapy before surgery, but an increase in postoperative complications if patients receive preoperative radiation has been a major concern<sup>[4]</sup>. The present study compared the major postoperative complications associated with long-course and short-course radiotherapy followed by TME in a large series of patients with locally advanced rectal cancer. Compared to those without radiotherapy, the increase in surgical complications caused by two different preoperative radiotherapy regimens was acceptable, and postoperative mortality did not increase. No patients died within 30 d after surgery, although preoperative radiotherapy might have been associated with anastomotic leakage and perineal wound complications. Temporary ileostomy prevented the occurrence and severity of anastomotic leakage. The grade of surgical complications did not differ significantly, except for perineal wounds, which did not always require surgical reintervention.

Several studies have investigated whether preoperative radiotherapy increases surgical complications<sup>[5]</sup>. The conclusions were not in agreement. Most of these studies have suggested that preoperative radiotherapy does not increase postoperative morbidity<sup>[6]</sup>. However, the complications in patients with neoadjuvant radiotherapy seem to be more severe, as demonstrated by the need for more surgical reintervention to treat the complications<sup>[7]</sup>. Our study indicated that long-course and short-course chemoradiotherapy were not associated with increased incidence or grade of complications. Conservative measures do not have any benefit after radiotherapy<sup>[8]</sup>. Reintervention is more often used for patients who receive radiotherapy if anastomotic leakage cannot be healed. This was one of the major setbacks of



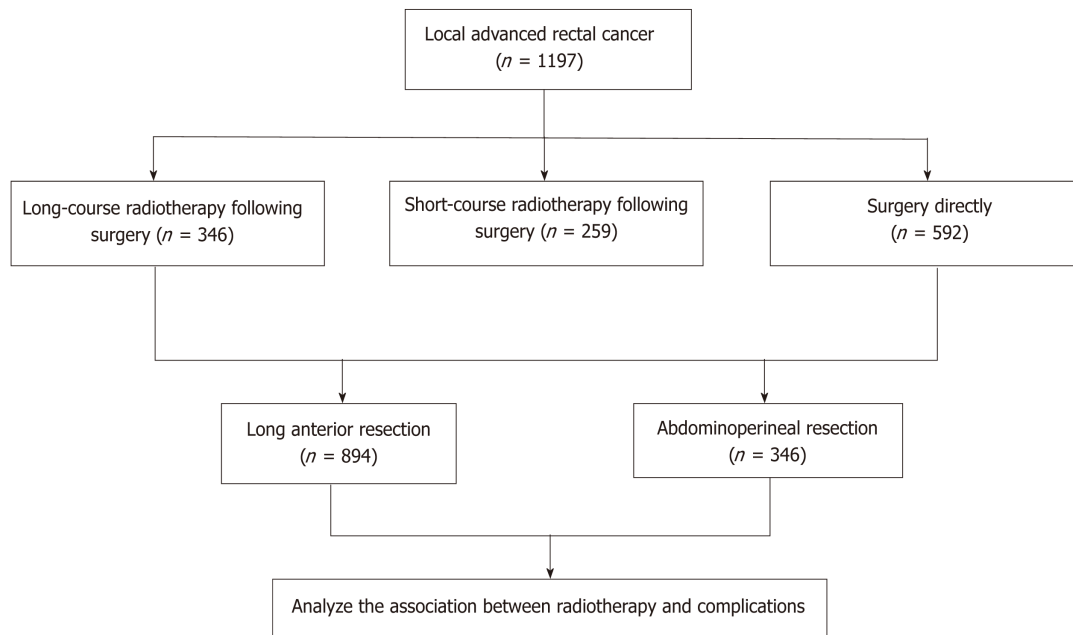


Figure 1 Flow diagram of treatment.

radiotherapy.

Anastomotic leakage is the most serious surgical complication after LAR for rectal cancer. It occurs in 3.5%–25.0% of patients after surgery<sup>[9,10]</sup>. The rates reported varied according to different definitions being used. In some studies, anastomotic leakage was diagnosed by computed tomography, magnetic resonance imaging, or radiography. The incidence rates were usually higher by imaging diagnosis than clinical observation. In this study, we defined leakage by the presence of gas or feces around the anastomosis in the drainage tubes. Radiology was used only when surgical reintervention was required. There were many risk factors believed to be associated with anastomotic leakage, such as male gender, lower location of the tumor, and preoperative radiotherapy<sup>[11,12]</sup>. Neoadjuvant radiotherapy has been implicated as a causative factor for the increased rate of anastomotic leakage<sup>[13]</sup>. It might be due to the local effect of radiation, and subsequently increased technical difficulty during the operation. Radiotherapy may also decrease the oxygen supply to the local tissue around the anastomosis. It can slow down the healing process and cause leakage. In our study, the rate for all these patients was 5.4%. It was a low incidence and within the acceptable range compared with other complications.

It is agreed that preoperative radiotherapy is associated with an increase in anastomotic leakage. Patients with radiotherapy may need a longer time for healing of leakage. As a result, a temporary defunctioning ileostomy was constructed during rectal surgery for patients who underwent preoperative radiotherapy, and it was reversed after 6 mo<sup>[14]</sup>. It is believed that ileostomy can reduce anastomotic leakage<sup>[15]</sup>. In the present study, more patients with radiotherapy had a defunctioning ileostomy than those who underwent surgery alone. Defunctioning ileostomy also decreases the grade of leakage as the feces are diverted<sup>[16]</sup>. This may be an effective approach to avoid surgical reintervention caused by anastomotic leakage.

Perineal wound complications are commonly seen after APR. Previously reported rates varied between 5.9% and 31.0%<sup>[17,18]</sup>. Most perineal wound complications, such as wound gaping, are mild and do not require a prolonged stay in hospital or surgical reintervention. However, severe wound complications can impair quality of life<sup>[19]</sup>. For example, patients with open wounds are usually accompanied with pain and movement limitation. They might also delay subsequent adjuvant chemotherapy, which may result in worse prognosis. Previous studies have shown that the rate of perineal wound complications increases in patients who receive preoperative radiotherapy<sup>[4,20]</sup>. Our study also showed a significant increase in perineal wound complications after short-course radiotherapy compared with patients who received long-course radiotherapy and those who did not receive neoadjuvant treatment. In addition, the grade of the complications was also higher in the short-course radiotherapy group. The grade of these complications was always 3a. However, no reintervention was required to manage these complications.

**Table 3 Patient and treatment characteristics**

Characteristics	No. of patients
Age in yr	59 (21–88)
Sex ratio, male: female	721: 485
Zubrod-ECOG-WHO	
0	1060
1	106
2	40
3	0
4	0
5	0
Preoperative treatment	
25 × 2 Gy with capecitabine	346
10 × 3 Gy	259
None	592
Distance from anal verge	
≤ 5 cm	817
5–10 cm	389
Surgery	
LAR	894
APR	303
Hartmann procedure	27
No resection	7
Diverting stoma after LAR	
Yes	313
No	581
Pathological TNM classification	
pT0	70
pT1	59
pT2	326
pT3	661
pT4	81
pN0	687
pN1	284
pN2	226

ECOG-WHO: Eastern Cooperative Oncology Group-World Health Organization; LAR: Low anterior resection; APR: Abdominoperineal resection.

Although our study had a large patient cohort, it was limited by its retrospective nature. It is difficult to fully evaluate late complications for > 30 d after hospital discharge, and the incidence might have been underestimated.

The use of preoperative radiochemotherapy for rectal cancer has been debated for decades, including indications, methods, TRG, and so on. Preoperative chemoradiotherapy may be affected by several factors, such as carcinoembryonic antigen and histological regression score. Acellular mucin pools are also thought to be a useful predictor for complete response in several studies<sup>[21,22]</sup>, but it is controversial. The association between postoperative complications and mucin pools is worth study. From 2008–2010, which is the recruitment period, we had not begun to detect routinely regression rate and mucin pool in our hospital. Therefore, these data were not collected for this study. It is one of the limitations of our study.

Since the sample includes more 1000 patients, we can compare the local control, survival, and quality of life among different groups. We can compare differences of clinical effect between different preoperative therapies, and additional studies are necessary in the future.

In conclusion, preoperative radiotherapy was associated with two major surgical complications: anastomotic leakage and perineal wound complications. There were no significant differences in other complications. Both long-course and short-course

Table 4 Postoperative complications (events during admission and 30 d thereafter)

Complications	Treatment group	No. of patients	Total	Grade 1	Grade 2	Grade 3a	Grade 3b	Grade 4a	Grade 4b	Grade 5	P value
Anastomotic leakage (LAR)	1	236	16		10		6				0.411
	2	151	9		3		6				
	3	507	23		16		7				
Perineal wound complications (APR)	1	110	13	9	3	1					< 0.001
	2	108	29	14	13	2					
	3	85	8	4	3	1					
Ileus	1	346	11	2	5		4				0.069
	2	259	14		13		1				
	3	592	14	2	12						
Bleeding	1	346	10	1	8		1				0.485
	2	259	10	2	7						
	3	592	14	2	10		2				
Intra-abdominal abscess	1	346	12	2	5	4	1				0.932
	2	259	10		5	2	3				
	3	592	20	3	8	6	3				
Abdominal wound complications	1	346	10	7	2		1				0.474
	2	259	10	6	4						
	3	592	14	11	2		1				
Urological complications	1	346	17	10	4		3				0.154
	2	259	16	5	8		3				
	3	592	20	12	6		2				
Intestinal necrosis	1	346	2				2				0.689
	2	259	3		2		1				
	3	592	4				4				
Gastrointestinal perforation	1	346	0								1.000
	2	259	0								
	3	592	0								
Intravenous line infection	1	346	8		8						0.641
	2	259	8		8						
	3	592	12		12						
Stoma complications	1	269	11	4	7						0.702
	2	228	14	3	11						
	3	119	5	2	3						
General complications	1	346	36	21	15						0.520
	2	259	34	17	17						
	3	592	54	28	25	1					

Group 1: Patients received 25 × 2 Gy radiation with capecitabine; Group 2: Patients received 10 × 3 Gy radiation; Group 3: Patients did not receive radiation; LAR: Low anterior resection; APR: Abdominoperineal resection.

radiochemotherapy increased the incidence of anastomotic leakage, but the grade remained close to that in patients treated with surgery alone. A temporary defunctioning ileostomy seemed to be an effective method to reduce the risk of anastomotic leakage for patients who received radiotherapy. Short-course radiochemotherapy increased the incidence and grade of perineal wound complications. Reintervention may not be necessary to ameliorate the perineal wound complications as the damage is usually low grade.



**Table 5** Logistic regression analysis of anastomotic leakage

Characteristics	Anastomotic leakage			
	$\chi^2$	OR	95%CI of Exp(B)	P value
Age	1.748	1.542	0.812–2.928	0.186
Sex	1.081	1.410	0.738–2.695	0.299
Distance from anal verge	0.508	1.276	0.653–2.496	0.476
Pathological T stage	13.089	2.620	1.555–4.415	< 0.001
Pathological N stage	1.402	0.768	0.496–1.189	0.236
Preoperative radiotherapy	14.029			0.001
Long course CRT/surgery directly	10.931	3.624	1.689–7.775	0.001
short course RT/surgery directly	9.614	5.150	1.828–14.515	0.002
diverting stoma	15.804	6.211	2.525–15.385	< 0.001

OR: Odds ratio; CRT: Chemoradiotherapy; RT: Radiotherapy.

**Table 6** Logistic regression analysis of perineal wound complications

Characteristics	Perineal wound complications			
	$\chi^2$	OR	95%CI of Exp(B)	P value
Age	1.576	1.508	0.794–2.865	0.209
Sex	1.542	1.513	0.787–2.907	0.214
Distance from anal verge	1.045	1.779	0.590–5.376	0.307
Pathological T stage	0.391	1.121	0.784–1.602	0.532
Pathological N stage	0.791	1.227	0.782–1.927	0.374
Preoperative radiotherapy	16.757			<0.001
long course CRT/surgery directly	1.166	1.692	0.651–4.394	0.280
short course RT/surgery directly	13.184	5.565	2.203–14.057	<0.001

OR: Odds ratio; CRT: Chemoradiotherapy; RT: Radiotherapy.

## ARTICLE HIGHLIGHTS

### Research background

Preoperative radiochemotherapy can improve local control of rectal cancer. However, some researchers believe it increases the incidence of surgical complications. Patients with locally advanced rectal cancer receive three different treatments in our hospital, including long-course radiochemotherapy, short-course radiotherapy, and surgery directly. We can compare differences in their postoperative complications.

### Research motivation

Some surgeons suspect that preoperative radiochemotherapy increases surgical complications, such as anastomotic leakage. As a result, surgeons are more likely to do additional diverting ileostomy for these patients. Our motivation is to determine if radiochemotherapy increases the incidence of complications or only increases the severity of complications. These findings can guide our treatment strategies.

### Research objectives

To investigate surgical complications caused by three different preoperative radiotherapy regimens. It includes the incidence and severity of complications.

### Research methods

This is a retrospective study. We analyzed 1197 patients with locally advanced rectal cancer between 2008 and 2010. Three hundred and forty-six patients were treated with preoperative long-course radiochemotherapy, and 259 patients received short-course radiotherapy ( $10 \times 3$  Gy) before surgery. The remaining 592 patients underwent total mesorectal excision (TME) alone without neoadjuvant therapy. The incidence of surgical complications was evaluated for up to 30 d after discharge from hospital. Severity was also studied according to Clavien–Dindo classification.

### Research results

The major complications were anastomotic leakage and perineal wound complications. Both long-course and short-course radiotherapy were associated with incidence of anastomotic leakage, but the severity of anastomotic leakage did not increase in patients following preoperative radiotherapy. Temporary ileostomy can reduce incidence of anastomotic leakage. Compared with TME alone, short-course radiotherapy was associated with an increase in incidence and severity of perineal wound complications. Long-course radiotherapy seemed safe regarding this complication.

### Research conclusions

Radiotherapy increased incidence but not severity of anastomotic leakage. Short-course radiotherapy was also accompanied with perineal wound complications. However, intervention appeared unnecessary to ameliorate the complications. The increase of complications seems to be acceptable. Our surgeons are more likely to use diverting ileostomy for patients with preoperative radiotherapy.

### Research perspectives

We determined the advantages and disadvantages of preoperative radiotherapy, and this knowledge will inform our selection of different preoperative treatments. Our study is a retrospective study with a large sample size. In our opinion, a prospective randomized controlled study needs to be designed and performed.

## REFERENCES

- 1 **Martin ST**, Heneghan HM, Winter DC. Systematic review and meta-analysis of outcomes following pathological complete response to neoadjuvant chemoradiotherapy for rectal cancer. *Br J Surg* 2012; **99**: 918-928 [PMID: [\[\[22362002 DOI: 10.1002/bjs.8702\]\]](#)]
- 2 **Zhan T**, Gu J, Li M, Du C. Intermediate-fraction neoadjuvant radiotherapy for rectal cancer. *Dis Colon Rectum* 2013; **56**: 422-432 [PMID: [\[\[23478609 DOI: 10.1097/DCR.0b013e31828576c6\]\]](#)]
- 3 **Yamano T**, Yoshimura M, Kobayashi M, Beppu N, Hamanaka M, Babaya A, Tsukamoto K, Noda M, Matsubara N, Tomita N. Malnutrition in rectal cancer patients receiving preoperative chemoradiotherapy is common and associated with treatment tolerability and anastomotic leakage. *Int J Colorectal Dis* 2016; **31**: 877-884 [PMID: [\[\[26888783 DOI: 10.1007/s00384-016-2507-8\]\]](#)]
- 4 **Ansari N**, Solomon MJ, Fisher RJ, Mackay J, Burmeister B, Ackland S, Heriot A, Joseph D, McLachlan SA, McClure B, Ngan SY. Acute Adverse Events and Postoperative Complications in a Randomized Trial of Preoperative Short-course Radiotherapy Versus Long-course Chemoradiotherapy for T3 Adenocarcinoma of the Rectum: Trans-Tasman Radiation Oncology Group Trial (TROG 01.04). *Ann Surg* 2017; **265**: 882-888 [PMID: [\[\[27631775 DOI: 10.1097/SLA.0000000000001987\]\]](#)]
- 5 **Swellengrebel HA**, Marijnen CA, Verwaal VJ, Vincent A, Heuff G, Gerhards MF, van Geloven AA, van Tets WF, Verheij M, Cats A. Toxicity and complications of preoperative chemoradiotherapy for locally advanced rectal cancer. *Br J Surg* 2011; **98**: 418-426 [PMID: [\[\[21254020 DOI: 10.1002/bjs.7315\]\]](#)]
- 6 **Milgrom SA**, Goodman KA, Nash GM, Paty PB, Guillem JG, Temple LK, Weiser MR, Garcia-Aguilar J. Neoadjuvant radiation therapy prior to total mesorectal excision for rectal cancer is not associated with postoperative complications using current techniques. *Ann Surg Oncol* 2014; **21**: 2295-2302 [PMID: [\[\[24604589 DOI: 10.1245/s10434-014-3624-7\]\]](#)]
- 7 **Jonker FH**, Tanis PJ, Coene PP, van der Harst E; Dutch Surgical Colorectal Audit Group. Impact of Neoadjuvant Radiotherapy on Complications After Hartmann Procedure for Rectal Cancer. *Dis Colon Rectum* 2015; **58**: 931-937 [PMID: [\[\[26347964 DOI: 10.1097/DCR.0000000000000432\]\]](#)]
- 8 **Johnston MJ**, Robertson GM, Frizelle FA. Management of late complications of pelvic radiation in the rectum and anus: a review. *Dis Colon Rectum* 2003; **46**: 247-259 [PMID: [\[\[12576899 DOI: 10.1097/01.DCR.0000050451.16169.59\]\]](#)]
- 9 **Akiyoshi T**, Ueno M, Fukunaga Y, Nagayama S, Fujimoto Y, Konishi T, Kuroyanagi H, Yamaguchi T. Incidence of and risk factors for anastomotic leakage after laparoscopic anterior resection with intracorporeal rectal transection and double-stapling technique anastomosis for rectal cancer. *Am J Surg* 2011; **202**: 259-264 [PMID: [\[\[21871980 DOI: 10.1016/j.amjsurg.2010.11.014\]\]](#)]
- 10 **Vermeer TA**, Orsini RG, Daams F, Nieuwenhuijzen GA, Rutten HJ. Anastomotic leakage and presacral abscess formation after locally advanced rectal cancer surgery: Incidence, risk factors and treatment. *Eur J Surg Oncol* 2014; **40**: 1502-1509 [PMID: [\[\[24745995 DOI: 10.1016/j.ejso.2014.03.019\]\]](#)]
- 11 **Law WL**, Chu KW. Anterior resection for rectal cancer with mesorectal excision: a prospective evaluation of 622 patients. *Ann Surg* 2004; **240**: 260-268 [PMID: [\[\[15273550\]\]](#)]
- 12 **Park JS**, Choi GS, Kim SH, Kim HR, Kim NK, Lee KY, Kang SB, Kim JY, Lee KY, Kim BC, Bae BN, Son GM, Lee SI, Kang H. Multicenter analysis of risk factors for anastomotic leakage after laparoscopic rectal cancer excision: the Korean laparoscopic colorectal surgery study group. *Ann Surg* 2013; **257**: 665-671 [PMID: [\[\[23333881 DOI: 10.1097/SLA.0b013e31827b8ed9\]\]](#)]
- 13 **Qin Q**, Ma T, Deng Y, Zheng J, Zhou Z, Wang H, Wang L, Wang J. Impact of Preoperative Radiotherapy on Anastomotic Leakage and Stenosis After Rectal Cancer Resection: Post Hoc Analysis of a Randomized Controlled Trial. *Dis Colon Rectum* 2016; **59**: 934-942 [PMID: [\[\[27602924 DOI: 10.1097/DCR.0000000000000665\]\]](#)]
- 14 **Hain E**, Maggiori L, Manceau G, Zappa M, Prost à la Denise J, Panis Y. Persistent Asymptomatic Anastomotic Leakage After Laparoscopic Sphincter-Saving Surgery for Rectal Cancer: Can Diverting Stoma Be Reversed Safely at 6 Months? *Dis Colon Rectum* 2016; **59**: 369-376 [PMID: [\[\[27050598 DOI: 10.1097/DCR.0000000000000568\]\]](#)]
- 15 **Hüser N**, Michalski CW, Erkan M, Schuster T, Rosenberg R, Kleeff J, Friess H. Systematic review and meta-analysis of the role of defunctioning stoma in low rectal cancer surgery. *Ann Surg* 2008; **248**: 52-60 [PMID: [\[\[18580207 DOI: 10.1097/SLA.0b013e318176bf65\]\]](#)]
- 16 **Matthiessen P**, Hallböök O, Rutegård J, Simert G, Sjö Dahl R. Defunctioning stoma reduces symptomatic anastomotic leakage after low anterior resection of the rectum for cancer: a randomized multicenter trial.

- Ann Surg* 2007; **246**: 207-214 [PMID: [\[\[17667498 DOI: 10.1097/SLA.0b013e3180603024\]\]](#)]
- 17 **Han JG**, Wang ZJ, Qian Q, Dai Y, Zhang ZQ, Yang JS, Li F, Li XB. A prospective multicenter clinical study of extralevator abdominoperineal resection for locally advanced low rectal cancer. *Dis Colon Rectum* 2014; **57**: 1333-1340 [PMID: [\[\[25379997 DOI: 10.1097/DCR.0000000000000235\]\]](#)]
- 18 **Musters GD**, Sloothak DA, Roodbeen S, van Geloven AA, Bemelman WA, Tanis PJ. Perineal wound healing after abdominoperineal resection for rectal cancer: a two-centre experience in the era of intensified oncological treatment. *Int J Colorectal Dis* 2014; **29**: 1151-1157 [PMID: [\[\[25064389 DOI: 10.1007/s00384-014-1967-y\]\]](#)]
- 19 **Colov EP**, Klein M, Gögenur I. Wound Complications and Perineal Pain After Extralevator Versus Standard Abdominoperineal Excision: A Nationwide Study. *Dis Colon Rectum* 2016; **59**: 813-821 [PMID: [\[\[27505109 DOI: 10.1097/DCR.0000000000000639\]\]](#)]
- 20 **De Nardi P**, Summo V, Vignali A, Capretti G. Standard versus extralevator abdominoperineal low rectal cancer excision outcomes: a systematic review and meta-analysis. *Ann Surg Oncol* 2015; **22**: 2997-3006 [PMID: [\[\[25605518 DOI: 10.1245/s10434-015-4368-8\]\]](#)]
- 21 **Gurzu S**, Bara T, Bara T, Kadar Z, Molnar C, Kovecsi A, Jung I. Clinical significance of carcinoembryonic antigen expression of acellular mucin pools after preoperative chemoradiotherapy of rectal carcinoma. *Cancer Biother Radiopharm* 2014; **29**: 295-297 [PMID: [\[\[25203146 DOI: 10.1089/cbr.2014.1640\]\]](#)]
- 22 **Reynolds IS**, McNamara DA, Kay EW, O'Neill B, Deasy J, Burke JP. The significance of mucin pools following neoadjuvant chemoradiotherapy for locally advanced rectal cancer. *J Surg Oncol* 2018; **118**: 1129-1134 [PMID: [\[\[30261095 DOI: 10.1002/jso.25247\]\]](#)]



Published By Baishideng Publishing Group Inc  
7041 Koll Center Parkway, Suite 160, Pleasanton, CA 94566, USA  
Telephone: +1-925-2238242  
Fax: +1-925-2238243  
E-mail: [bpgoffice@wjgnet.com](mailto:bpgoffice@wjgnet.com)  
Help Desk: <https://www.f6publishing.com/helpdesk>  
<https://www.wjgnet.com>

