

Next-generation-sequencing technology used for the detection of *Mycoplasma hominis* in renal cyst fluid: a case report

This article was published in the following Dove Press journal:
Infection and Drug Resistance

Nan Xiao¹
Wei Gai²
Wei-Guo Hu¹
Jian-Xing Li¹
Yan Zhang²
Xiu-Ying Zhao¹

¹Department of Clinical Laboratory, Beijing Tsinghua Changgung Hospital, School of Clinical Medicine, Tsinghua University, Beijing, People's Republic of China; ²National Engineering Research Center for Beijing Biochip Technology, Beijing, People's Republic of China

Background: *Mycoplasma* is an opportunistic pathogen causing both urogenital and extra-genital infections. The lack of cell wall renders *Mycoplasma* difficult to culture and identify with ordinary methods. Next-generation sequencing (NGS) is a new technology helping a lot in the diagnosis of infective diseases. In this case, NGS played a key role in the diagnosis of *Mycoplasma* infection.

Case presentation: A mid-aged man suffering from renal cyst underwent cyst incision followed by invasive treatments to eliminate hematoma caused by renal artery hemorrhage. After the cyst incision operation, the patient had a persistent high temperature. The persistent increase of blood neutrophile granulocyte count and C-reaction protein suggested an unresolved infection. The empirically chosen anti-infective agents were meropenem and linezolid since the ordinary bacterial cultures of surgical site drainage and blood yielded a negative result. At postoperation day (POD) 17, NGS result of his drainage clearly indicated the pathogen was *Mycoplasma hominis*. At POD 24, the drug sensitivity test showed resistance to quinolones, clarithromycin and erythromycin, but intermediate to azithromycin. Since then, the antimicrobial agents were changed into azithromycin and kept unchanged until the patient was fully recovered and discharged at POD 39.

Conclusion: When the ordinary laboratory diagnostic methods failed, NGS diagnosis could reduce the hospitalization expenses and shorten the lengths of hospital stay.

Keywords: NGS, *Mycoplasma*, renal cyst, infection

Introduction

Mycoplasma species are often isolated from genitourinary system from healthy adults and sometimes cause upper genitourinary tract infection.¹ It is also reported being isolated from several different categories of extragenital infections.² The growth of atypical bacterial pathogens such as *Mycoplasma* needs special growth media³ or commercially available kits.^{4,5} Next-generation sequencing (NGS) is a powerful new technology to uncover the identity of pathogens which was difficult to be identified by traditional methods.⁶ In this case, NGS helps to diagnose the infection of *Mycoplasma hominis* (*M. hominis*) in a renal cyst and hematoma of a patient without immunosuppression.

Case presentation

Medical history and preliminary diagnosis

A 54-year-old male patient with Han nationality was presented in the Department of Urology of a tertiary hospital, because of a cyst in the right kidney. The cyst was found 5

Correspondence: Xiu-Ying Zhao
Beijing Tsinghua Changgung Hospital,
School of Clinical Medicine, Tsinghua
University, 168 Litang Road, Changping
District, Beijing 102218, People's Republic
of China
Tel +86 105 611 9228
Fax +86 105 611 8500
Email zhaoxiuying2001@163.com

years ago during a physical examination, and it was left untreated until recently it became obviously bigger. The patient reported a past history of hypertension for 2 years, whose highest record was 140/90 mmHg. He had taken bisoprolol 2.5 mg qd for treatment. No history of other disorders was reported.

The preoperation computed tomography (CT) showed that the middle and low pole of the right kidney had elliptical cystic which had low density with clear border and no enhancement. And there was also an adrenal nodular hyperplasia presented in the left adrenal (Figure 1A). And the patient also had a ++++ leukocyte esterase urinalysis result which equaled ≥ 500 WBC/mL. The diagnoses of the patient were 1) acquired renal cyst, 2) benign adrenal tumors, 3) hypertension, 4) urinary tract infection.

Surgical operations

The patient undertook a selective operation during which surgeons performed a renal cyst incision with flexible ureteroscope. After general anesthesia, Storz ureteroscope was placed through the urethra. According to preoperative CT image localization, laser (1.0 J \times 20 Hz) was used to incise the mucosal wall of the bulging collecting system. There were loose tissues and no clear cyst wall. Ultrasound-guided puncture of right kidney cyst was performed. The incision was about 1.5 cm without bleeding. Double-J tube and catheter were indwelled after the operation.

At postoperation day (POD) 2, patient suffered from abdominal distension and pain, with the drop of blood pressure and hemoglobin. Bedside color Doppler ultrasonography showed that a moderate echo mass was in front of

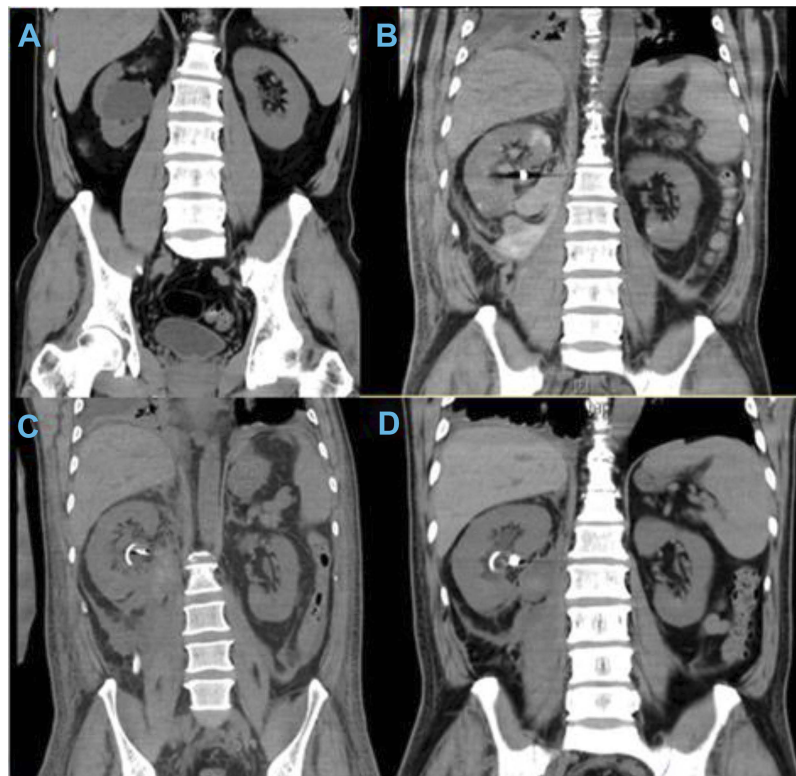


Figure 1 (A) An elliptical cyst located in middle and low pole of the right kidney, which had low density with clear border and no enhancement, had been found. The size of the cyst was about $36 \times 51 \times 37$ mm. And there was also an adrenal nodular hyperplasia with the diameter of 5 mm presented in the left adrenal. The left renal pelvis was compressed, and the left kidney was normal in size and position, with regular morphology and no abnormal density in renal parenchyma. Bilateral ureters showed no dilatation and abnormal density shadow. (B) At POD4, compared with the previous CT image, DJ tube could be seen in the right urinary tract, and high-density artifacts were seen in the right sinus. The shape of the right kidney was irregular and the density was not uniform. There were multiple wedge-shaped high-density shadows, and exudation and high-density shadows were seen around the right kidney and behind the peritoneum. The maximum cross section was about 104×72 mm. The middle and lower pole of the right kidney showed elliptical cystic low density, which was slightly smaller than the former, and the size was about 4.5×2.6 cm. The size and shape of the left kidney can be seen. The left renal pelvis and ureter had no obvious dilatation or abnormal density shadow. (C) At POD 14, double-J tube could be seen. Drainage tube shadows were seen in the right retroperitoneal space. High-density artifacts can be seen in the right sinus. The morphology of the right kidney was irregular and the density of parenchyma was uneven. The cystic density in front of the right iliac psoas was obviously lower compared with before. A small amount of fluid in the abdomen and pelvis was presented. (D) At POD 27, high-density artifacts can be seen in the right sinus. The morphology of the right kidney was irregular and the density of parenchyma became more uniform. The size of the irregular cystic shadow in the anterior part of right iliopsoas muscle was smaller, and the density was lower than before. A smaller amount of effusion was seen in the abdominal cavity. And no clear effusion was found in the pelvic cavity.

psoas major muscle about 5 cm from the lower pole of right kidney. Renal artery embolization was performed successfully under local anesthesia, and renal artery branch hemorrhage was found during the operation (Figure 1B).

Three days later (POD 5), the patient's hemoglobin was 79 g/L. He suffered from tachycardia and atrial fibrillation. Four units of suspended red blood cell and 400 mL plasma were transfused. Since the symptom of cardiac and pulmonary insufficiency caused by abdominal distention, diaphragmatic elevation and compression of the lungs cannot be relieved, the patient undertook the removal of the retroperitoneal hematoma. After the operation, he was moved to intensify care unit (ICU).

Course of the disease after operations

Because of the renal artery hemorrhage and the damage of the right renal structure, the patient suffered from perirenal and retroperitoneal hematoma. The efficient drainage helped with the reducoin of the hematoma and suspected urinary fistula. Four times of CT results before and after the invasive operations are shown in Figure 1. However, since the cyst incision operation, the inflammatory markers were high, which included body temperature, blood neutrophile granulocyte

count (NEUT) and C-reaction protein, suggesting an infection statue of the patient (Figure 2).

The steadily high levels of inflammatory markers necessitated anti-infective agents. The timeline of the invasive operations, symptoms and anti-infective medicine prescriptions is shown in Figure 3. At POD 3–4, cefimazole was prescribed when the patient was in the urology ward. When he was moved to ICU, the drug was changed into cefoperazone/sulbactam for 3 days. Nevertheless, the cephalosporin prescripts seemed not helpful to his symptoms. At POD 8–17, meropenem and linezolid were used instead of cephalosporin. The symptoms and CT results gradually improved (Figure 1C). During these days, all the bacteria cultures of drainage and blood yielded a negative result. However, some pin-point colonies were detected on the Columbia blood agar (CBA) plate and chocolate agar (Figure 4). The Gram stain failed to reveal any identifiable shapes of a typical bacterium. And the identity of the colonies could not be resolved with commonly used bacterial identification methods available in our laboratory. By the time, meropenem and linezolid seemed effective since his condition gradually improved though the infective pathogens were unknown. At POD 14, the drainage was

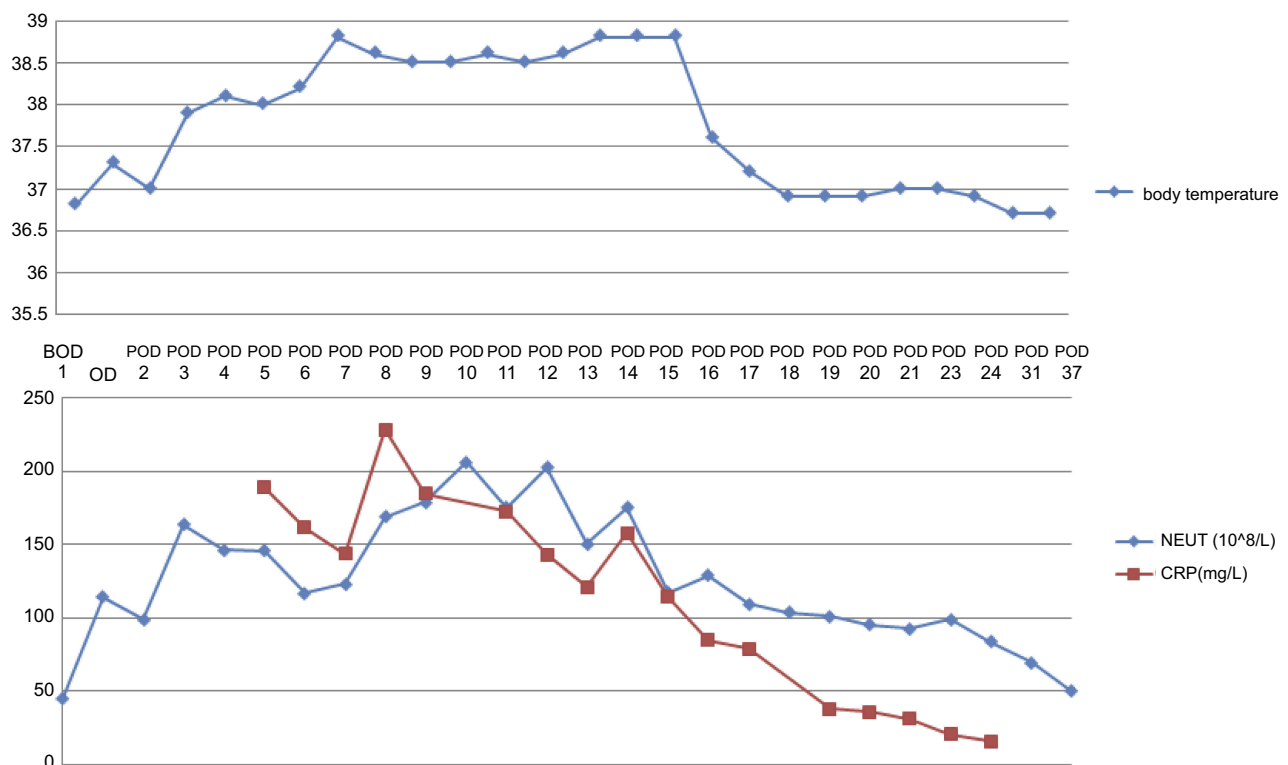


Figure 2 Blood neutrophile granulocyte count (NEUT 10⁸/L), C-reaction protein (CRP mg/L) and body temperatures from before-operation-day (BOD) 1 to POD 37.

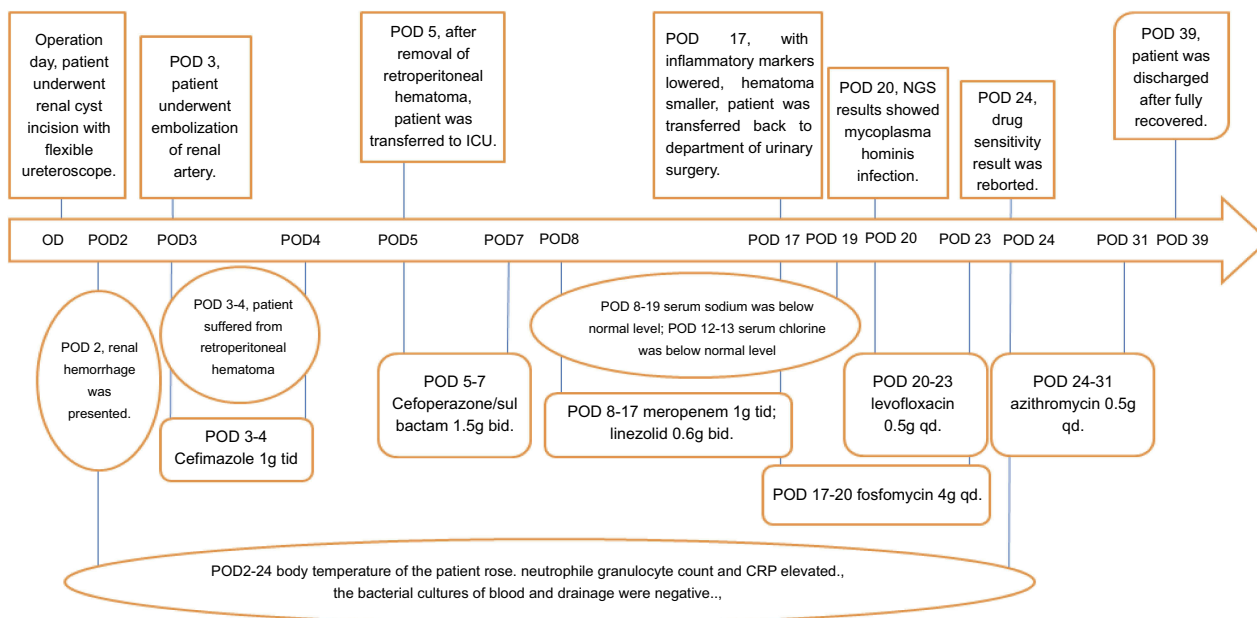


Figure 3 The timeline of this case with the times of invasive operation, symptoms and the prescripts of anti-infective agents.

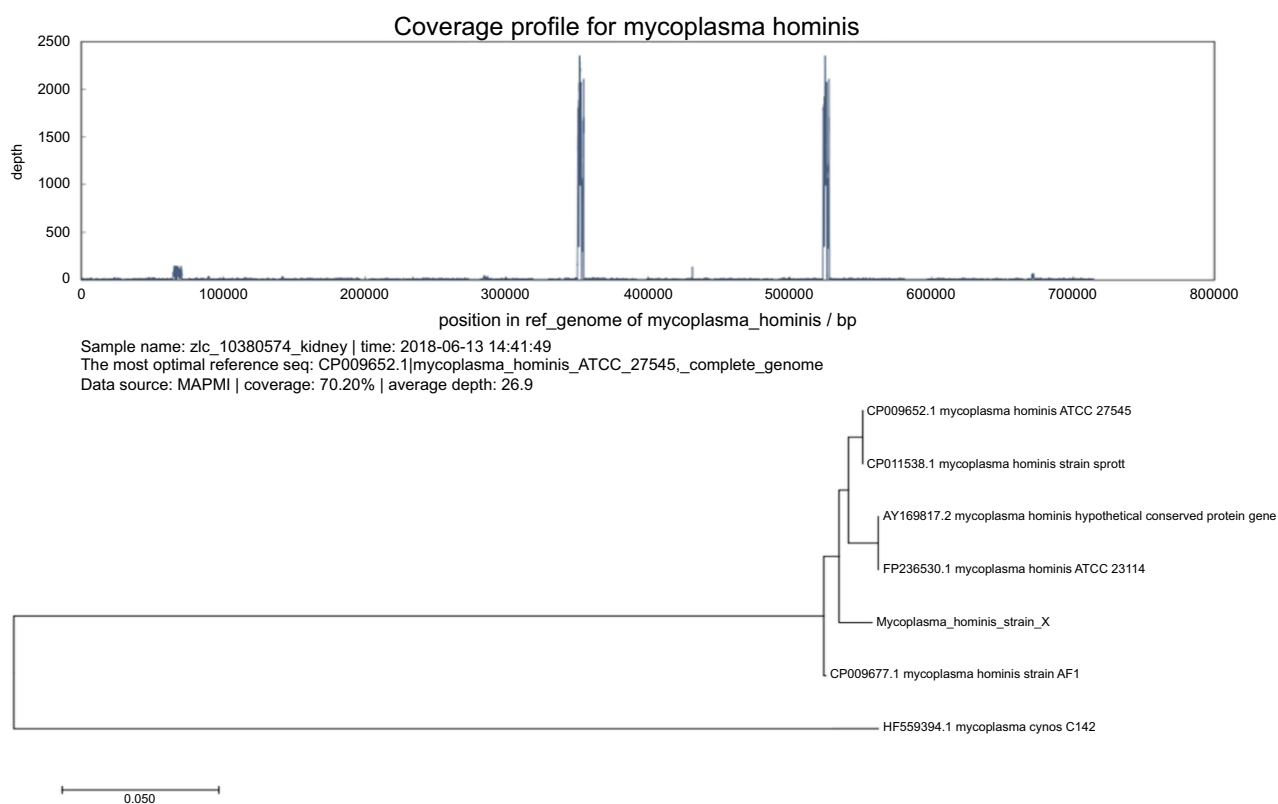


Figure 4 The coverage profile and phylogenetic tree of the *M. hominis* strain X.

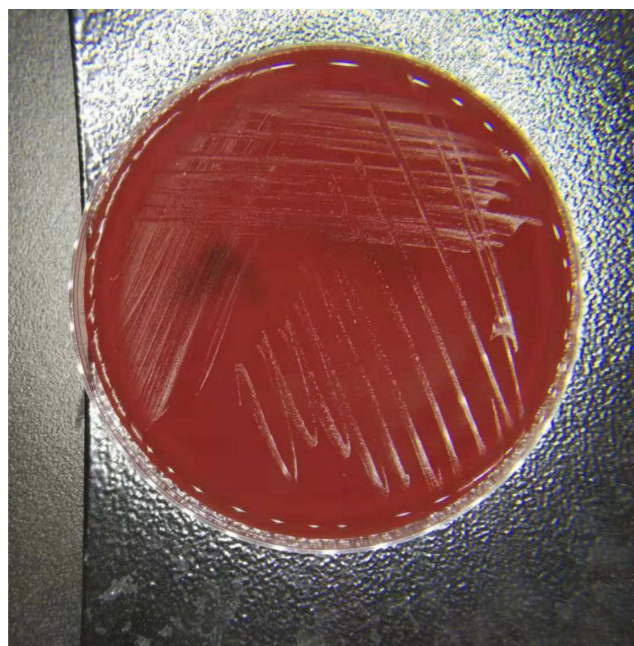
sent for next-generation-sequencing (NGS). The result showed a *M. hominis* infection (Table 1, Figure 5), which was reported to the attending doctor at POD 17. The anti-infective agents were changed empirically to

fosfomycin and levofloxacin. And the prescript was changed to azithromycin after the sensitivity test result was reported. It was kept the same until the inflammatory markers regained their normal levels and CT results

Table 1 NGS result

Virus screen result				
	Species	Reads count*	Coverage [#]	Estimated copies/mL
–	–	–	–	–
Bacteria screen result				
	Species	Reads count*	Coverage [#]	Estimated copies/mL
I	<i>Mycoplasma hominis</i> strain X	85,023	70.20%	880,000
Fungus screen result				
	Species	Reads count	Coverage	Estimated copies/mL
–	–	–	–	–

Notes: *Reads count: sequences generated by high-throughput sequencing platforms; [#]coverage: the proportion of the whole genome covered by the sequence obtained from the sequencing; –, no results detected.

**Figure 5** The pin-point colonies grew on CBA plate.

showed this treatment was effective (Figure 1D). The patient was fully recovered and discharged at POD 39.

After been discharged from the hospital, the patient was called to come back to do a CT scan as follow-up evaluation. He simply dismissed the requirement and did not come back so far.

The NGS result and anti-infective drug sensitivity result

The result of NGS showed that the most prominent pathogen was *M. hominis* which had the highest reads count and the

estimated copy number and designed as *M. hominis* strain X (Table 1). The genomic sequence of the strain X was reconstructed. According to the sequence of strain X and the data download from NCBI BLAST, a phylogenetic tree was constructed with maximum likelihood method by MEGA 7.0. The phylogenetic tree used HF559394.1 *Mycoplasma cynos* C142 as outgroup. The closest strain to strain X was CP009652.1 *M. hominis* ATCC 27545 and CP011538.1 *M. hominis* strain sprout (Figure 4).

The anti-infective drug sensitivity test was done with *M. hominis* IST (BioMerieux, France), which is a widely applied commercial *Mycoplasma* culture, detecting and drug sensitivity test kit with satisfying sensitivity and specificity^{4,5}. The result is show in Table 2. And the strain X had resistance to quinolones, clarithromycin and erythromycin. The sensitivity to azithromycin was intermediate.

Discussion and conclusion

Mycoplasma species lack a cell wall and grow relatively slowly. *M. hominis* appears as an amorphous mass when

Table 2 Anti-infective drug sensitivity result

Drugs	Result
Doxycycline hyclate	S*
Josamycine	S
Levofloxacin	R [#]
Erythromycin	R
Tetracycline	S
Ciprofloxacin	R
Azithromycin	I [^]
Clarithromycin	R

Abbreviations: S, sensitive; R, resistance; I, intermediate.

being Gram-stained, and its identification and anti-infective agent sensitivity test with routine culture methods are difficult.⁷ The *M. hominis* is frequently isolated from the lower genitourinary system from healthy adults and is sometimes responsible for infections of the upper genitourinary tract.¹ Asymptomatic carriage of this bacterium is common, and the majority of individuals do not develop any disease.⁸ Some researchers believed it had some debatable negative effect on men fertility.⁹ The *M. hominis* is also reported being isolated from extragenital infection. Categories of such infections include septicemia, joint infections, central nervous system infections, respiratory tract infections and wound infections². It was reported as a likely pathogen causing a hematoma or perinephric abscess in renal transplantation recipients.^{7,10–12} Nevertheless, sometimes normal people could suffer from hematoma and abscess caused by *M. hominis* infection.¹³

The patient in this case was basically a middle-aged man who had no obvious underlying disease leading to a possible immunosuppressive status. He suffered from a renal cyst in right kidney. After the cyst was incised, renal artery hemorrhage occurred and he underwent two extracorporeal operations to stop the bleeding and eliminate the hematoma. Since he reported having hypertension for 2 years, we suspect it was the possible cause of the renal artery bleeding. He experienced a long-term fever indicating infection but without any culture finding. The culture media used for routine bacterial culture in our laboratory included CBA, MacConkey agar and chocolate agar, neither of which is the suitable growth media for *Mycoplasma*. The identity of the pin-point colonies was a frustrating myth which could not be solved by the routine methods available in our lab, including BioMerieux Compact II (France) and MALDI-TOF (Bruker, Germany). The NGS helped us uncover this finding and rendered it possible to do *Mycoplasma* drug sensitivity test.

The drug sensitivity test showed that the *M. hominis* strain X was resistant to most macrolide agents and quinolones. The drug sensitivity pattern was similar to previous reports.^{14,15} Although the drug sensitivity test showed that the tetracycline was sensitive, the notorious side effects of tetracycline on young patients¹⁶ render the usage of this medicine very limited in China. Since the sensitivity to azithromycin was intermediate in this case, it was chosen as a single drug prescript. And it was proved to be effective. Before that, the physicians in ICU tried their luck with meropenem and linezolid. Since *M. hominis* was reported

sensitive to linezolid,¹⁷ we speculate that linezolid maybe the real effective agent which cured the severe infection. This case also indicates that we should pay attention to *Mycoplasma* infection of patients undergoing renal cyst incision or other surgeries.

In this case, it was the NGS that helped with the diagnosis of the infection. Before the explicit pathogen and corresponding drug sensitivity were reported, the empirical antibiotics were applied including cephalosporins, meropenem and linezolid. Such prescriptions lasted for about 2 weeks and costed up to more than \$2000, not mention the expenses generated from the elongated hospital stay. Although the cost of NGS was higher than the routine bacterial culture and identification, it could certainly save a lot of money costed by useless medication and shorten the hospitalization time.

Ethics approval and consent to participate

According to the Declaration of Helsinki and International ethical guidelines for biomedical research involving human subjects, the ethics committee of Beijing Tsinghua Changgung hospital supervised the treatment and operation of the patient reported in this case report. The committee approved the study procedure. The reference number of the approval is 18149-0-01. The patient was fully aware of the data obtained from him was used in this study. He signed the informed consent and provided a written informed consent for the case details to be published.

Abbreviations list

NGS, next-generation sequencing technology; OD, operation day; POD, postoperation day; D-J tube, Double-J tube; NEUT, blood neutrophil granulocyte count; CRP, C-reaction protein; CBA, Columbia blood agar; *M. hominis*, *Mycoplasma hominis*.

Availability of data and material

The sequence of the *M. hominis* strain has been submitted to NCBI Blast. This data set will be available within dates in the link <https://www.ncbi.nlm.nih.gov/bioproject/507519>. All the related data was presented in the manuscript.

Disclosure

The authors report no conflicts of interest in this work.

References

- Legg JM, Titus TT, Chambers I, Wilkinson R, Koerner RJ, Gould FK. Hematoma infection with *Mycoplasma hominis* following transplant nephrectomy. *Clin Microbiol Infect*. 2000;6:619–621.
- Madoff S, Hooper DC. Nongenitourinary infections caused by *Mycoplasma hominis* in adults. *Rev Infect Dis*. 1988;10:602–613. doi:10.1093/clinids/10.3.602
- Kenny GE, Balows A, Hausler WJ Jr., Herrman KL, Isenberg HD, Shadomy HJ. *Mycoplasmas, Manual of Clinical Microbiology*. Washington, D.C: American Society for Microbiology; 1991:478–482, 1263–1264, and 1280.
- D’Inzeo T, De Angelis G, Fiori B, et al. Comparison of Mycoplasma IES, Mycofast Revolution and Mycoplasma IST2 to detect genital mycoplasmas in clinical samples. *J Infect Dev Ctries*. 2017;11:98–101. doi:10.3855/jidc.8039
- Clegg A, Passey M, Yoannes M, Michael A. High rates of genital mycoplasma infection in the highlands of Papua New Guinea determined both by culture and by a commercial detection kit. *J Clin Microbiol*. 1997;5:197–200.
- Wilson MR, Naccache SN, Samayoa E, et al. Actionable diagnosis of neuroleptospirosis by next-generation sequencing. *N Engl J Med*. 2014;370:2408–2417. doi:10.1056/NEJMoa1401268
- Taylor-Robinson D, Mandell GL, Bennett JE, Dolin R. *Ureaplasma urealyticum* and *Mycoplasma hominis*. In: *Principles and Practice of Infectious Diseases*. New York: Churchill Livingstone. 1995:1713–1717.
- Horner P, Donders G, Cusini M, Gomberg M, Jensen JS, Unemo M. Should we be testing for urogenital *Mycoplasma hominis*, *Ureaplasma parvum* and *Ureaplasma urealyticum* in men and women? – a position statement from the European STI Guidelines Editorial Board. *J Eur Acad Dermatol Venereol*. 2018. doi:10.1111/jdv.15146
- Stojanov M, Baud D, Greub G, Vuillemoz N. Male infertility: the intracellular bacterial hypothesis. *New Microbes New Infect*. 2018;22(26):37–41. doi:10.1016/j.nmni.2017.12.005
- Camara B, Mouzin M, Ribes D, et al. Perihepatitis and perinephric abscess due to *Mycoplasma hominis* in a kidney transplant patient. *Exp Clin Transplant*. 2007;5:708–709.
- Orange GV, Jones M, Henderson IS. Wound and perinephric haematoma infection with *Mycoplasma hominis* in a renal transplant recipient. *Nephrol Dial Transplant*. 1993;8:1395–1396.
- Gerber L, Gaspert A, Braghetta A, et al. *Ureaplasma* and *Mycoplasma* in kidney allograft recipients—A case series and review of the literature. *Transpl Infect Dis*;2018:e12937. doi:10.1111/tid.12937.
- Koshiha H, Koshiha A, Daimon Y, Noguchi T, Iwasaku K, Kitawaki J. Hematoma and abscess formation caused by *Mycoplasma hominis* following cesarean section. *Int J Womens Health*. 2011;3:15–18. doi:10.2147/IJWH.S16703
- Redelinghuys MJ, Ehlers MM, Dreyer AW, Lombaard HA, Kock MM. Antimicrobial susceptibility patterns of *Ureaplasma* species and *Mycoplasma hominis* in pregnant women. *BMC Infect Dis*. 2014;14:171. doi:10.1186/1471-2334-14-171
- Azizmohammadi S, Azizmohammadi S. Antimicrobial susceptibility patterns of *Ureaplasma urealyticum* and *Mycoplasma hominis* isolated from pregnant women. *Iran Red Crescent Med J*. 2015;17:e17211. doi:10.5812/ircmj.23191v2
- Dorval J, Demers PP. Side effects of tetracyclines in pediatrics. *Laval Med*. 1968;39(10):939–954.
- Kenny GE, Cartwright FD. Susceptibilities of *Mycoplasma hominis*, *M. pneumoniae*, and *Ureaplasma urealyticum* to GAR-936, dalbopristin, dirithromycin, evernimicin, gatifloxacin, linezolid, moxifloxacin, quinupristin-dalbopristin, and telithromycin compared to their susceptibilities to reference macrolides, tetracyclines, and quinolones. *Antimicrob Agents Chemother*. 2001;45:2604–2608.

Infection and Drug Resistance

Dovepress

Publish your work in this journal

Infection and Drug Resistance is an international, peer-reviewed open-access journal that focuses on the optimal treatment of infection (bacterial, fungal and viral) and the development and institution of preventive strategies to minimize the development and spread of resistance. The journal is specifically concerned with the epidemiology of

antibiotic resistance and the mechanisms of resistance development and diffusion in both hospitals and the community. The manuscript management system is completely online and includes a very quick and fair peer-review system, which is all easy to use. Visit <http://www.dovepress.com/testimonials.php> to read real quotes from published authors.

Submit your manuscript here: <https://www.dovepress.com/infection-and-drug-resistance-journal>