



Case report

Evaluation of interferon alpha 2b as adjunctive therapy for conjunctival melanoma

Matthew J. Benage, Nicole C. Morrow, Ben J. Janson, Mark A. Greiner*

Department of Ophthalmology and Visual Sciences, University of Iowa Carver College of Medicine, Iowa City, IA, USA

A B S T R A C T

Keywords:

Conjunctival melanoma
Interferon alpha 2b
Adjunctive therapy
Topical chemotherapeutics

Purpose: Interferon alpha 2b (IFN- α 2b) has been used as an adjunctive agent to treat conjunctival melanoma (CM), however its efficacy is unproved due to a paucity of data. We present 5 cases of incompletely excised CM lesions to inform clinical decision making regarding the adjunctive use of IFN- α 2b.

Observations: We identified all biopsy proven CM cases treated between 1997 and 2017 at the University of Iowa. Of these, we analyzed cases in which topical IFN- α 2b drops were prescribed after the initial excision to treat surgical margins that were positive for primary acquired melanosis [PAM] with or without atypia or invasive CM. We noted the origin of CM (nevus, PAM, or de novo), presence and location of margins positive for residual melanoma, duration of IFN- α 2b treatment, recurrences, time to recurrence, and outcome at last follow-up. Topical IFN- α 2b drops (1 million IU/mL 4 times daily for 3–6 months) were used as adjunctive therapy in 5 cases following incomplete surgical excision of CM. The preceding lesion was PAM in 4 cases and compound nevus in 1 case. In 2 cases, margins were positive for PAM with atypia and both resulted in remission of melanoma at 54 and 33 months, respectively. However, in 3 cases, margins were positive for invasive melanoma and all 3 developed recurrence of melanoma despite IFN- α 2b use.

Conclusions and Importance: There are limited data regarding the efficacy of IFN- α 2b as adjunctive therapy for incomplete excision of CM lesions. In this series, adjunctive topical IFN- α 2b did not prevent recurrence in cases with surgical margins positive for invasive melanoma. Our results indicate that caution should be exercised when considering adjunctive IFN- α 2b to treat CM lesions not excised completely.

1. Introduction

Conjunctival melanoma (CM) is a rare but potentially fatal ocular surface tumor that represents approximately 2% of all ocular malignancies.^{1,2} The current standard of care includes wide local excision followed by double freeze-thaw cryotherapy to margins with or without adjunctive mitomycin C (MMC).³ However, incomplete excision and recurrences occur commonly.⁴ In addition to surgical resection, various adjuvant therapies have been described including radiotherapy, cryotherapy, and topical chemotherapeutic agents. MMC has been described as an effective adjuvant for primary acquired melanosis (PAM) with atypia and CM.^{5,6} Unfortunately, MMC's adverse effects – injection, tearing, as well as more serious consequences such as limbal stem cell deficiency, punctal stenosis, disciform keratitis, and corneal haze – may limit its use.⁷

Recently, there has been interest in treating CM with interferon

alpha 2b (IFN- α 2b) due to its favorable side effect profile and efficacy in treating ocular squamous surface neoplasia.⁸ However, evidence for its use in treating CM is limited. Herein, we present our cases of incomplete surgical excision of CM, with margins positive for PAM or CM, to inform clinical decision making in the adjunctive use of IFN- α 2b.

2. Methods

We reviewed all biopsy proven CM cases treated between 1997 and 2017 at the University of Iowa. The initial surgical technique in all cases was a wide “no touch” excisional biopsy with ≥ 3 mm margins followed by application of double-freeze thaw cryotherapy to surgical margins. All patients underwent a systemic evaluation with computed tomography and/or positron emission tomography. All biopsies were submitted for histopathologic analysis with evaluation for TNM staging according to AJCC 7th Edition with an ocular pathologist.

Abbreviations: Conjunctival melanoma, CM; interferon alpha 2b, IFN- α 2b; primary acquired melanosis, PAM; mitomycin C, MMC

* Corresponding author. Cornea and External Diseases, Department of Ophthalmology and Visual Sciences, University of Iowa Carver College of Medicine, 200 Hawkins Drive, Iowa City, IA, 52242, USA.

E-mail address: mark-greiner@uiowa.edu (M.A. Greiner).

<https://doi.org/10.1016/j.ajoc.2019.100467>

Received 19 September 2018; Received in revised form 12 February 2019; Accepted 13 May 2019

Available online 22 May 2019

2451-9936/© 2019 The Authors. Published by Elsevier Inc. This is an open access article under the CC BY-NC-ND license

(<http://creativecommons.org/licenses/by-nc-nd/4.0/>).

Table 1
Clinical characteristics of conjunctival melanoma treated with IFN- α 2b.

Number	Age	Gender	Size (mm)	Location	Origin	Color	TMN	Depth of invasion (mm)	Histopathology	Surgical margins	Duration of IFN- α 2B therapy (months)	Outcome	Recurrence after initial IFN- α 2B therapy	Follow up duration (months)
1	59	F	8 × 4	Bulbar	PAM with atypia	Amelanotic	pT1cN0M0	1.49	Epithelioid	Positive PAM with atypia at inferior margins	6	Remission	N/A	54
2	32	F	1 × 1	Bulbar	Compound nevus	Pigmented	pT1isN0M0	1	Epithelioid	Positive PAM with atypia at horizontal margins	6	Remission	N/A	33
3	91	F	7 × 7	Bulbar	PAM	Pigmented with feeder vessels	pT1cN0M0	3.45	Epithelioid	Invasive melanoma at deep and limbal borders. PAM at temporal and inferior borders	6	Recurrence with metastatic disease to lung, mediastinum and pelvis at 7 months. Ultimately passed away	Seven months following initial resolution of pigment had ptosis. Pathology showed lacrimal gland mass infiltrating the lateral rectus muscle identical to previous biopsy.	N/A
4	63	M	4 × 7	Superior and nasal bulbar	Compound nevus	Pigmented	Not enough information	0.43	Spindle	Invasive melanoma at all horizontal borders	6	Incomplete regression after 6 months of therapy	Six months after therapy had recurrence of pigmentation on superior conjunctiva. Pathology showed infiltrating melanoma with PAM with atypia at superior margin with melanoma in-situ at nasal margin. Treated with excisional biopsy with MMC.	14
5	59	F	1.5 × 1.7	Nasal bulbar	PAM	Pigmented	pT1aN0M0	0.39	Epithelioid	Invasive melanoma at all horizontal borders and possibly deep margin	3	No response and ultimate enucleation	Rebiopsy after lack of response to treatment showed malignant melanoma with positive deep and limbal margins.	12

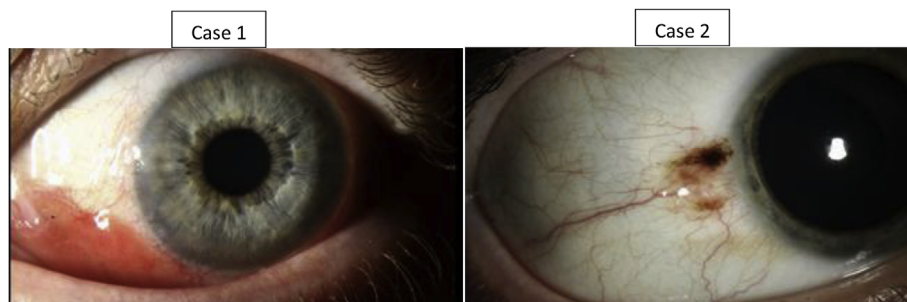


Fig. 1. Clinical pictures of the initial presentation of two cases with surgical margins positive for PAM with atypia after initial excision, with remission of disease after use of topical adjunctive IFN- α 2b.

We identified and included for analysis all cases in which topical IFN- α 2b drops (1 million IU/mL instilled 4 times daily for 3–6 months)^{9,10} were prescribed after the initial excision for surgical margins that were positive for primary acquired melanosis [PAM] with or without atypia or invasive CM (see Table 1). We noted the origin of CM (nevus, PAM, or de novo), presence and location of margins positive for residual melanoma, duration of IFN- α 2b treatment, recurrences, time to recurrence, and outcome at last follow-up. Complete resolution was defined as clinical absence of pigmentation or metastatic disease.

3. Findings

3.1. Case 1

59-year-old female presenting for an amelanotic bulbar conjunctival lesion. The lesion measured 8 × 4 mm (Fig. 1). She underwent excisional biopsy. The biopsy displayed conjunctival melanoma arising from PAM that was positive for PAM with atypia at the inferior surgical margin. She underwent IFN- α 2B treatment for 6 months. She had no recurrence of melanoma at 54-month follow up.

3.2. Case 2

32-year-old female presenting due to increasing size of a pigmented bulbar conjunctival lesion (Fig. 1). The lesion measured 1 × 1 mm. She underwent excisional biopsy which displayed conjunctival melanoma arising from a compound nevus. The horizontal margins were remarkable for PAM with severe atypia. She underwent treatment with IFN- α 2B for 6 months. She had no recurrence of melanoma at 33-month follow up.

3.3. Case 3

91-year-old female presenting for a large, enlarging lesion on the bulbar conjunctiva (Fig. 2). The lesion measured 7 × 7 mm, with large feeder vessels. The patient underwent excisional biopsy. Pathology revealed invasive conjunctival melanoma with residual melanoma at the deep and limbal borders in addition to PAM at the inferior and temporal borders. She underwent therapy with IFN- α 2B for 6 months with

complete resolution of conjunctival pigmentation. Seven months following discontinuation of IFN- α 2B, she was noted to have new onset of ptosis. MRI displayed a well-defined mass of lacrimal gland, so she underwent an orbitotomy with biopsy. Pathology displayed invasive melanoma infiltrating the lateral rectus and lacrimal gland, which appeared pathologically identical to her previous CM. Further evaluation with oncology revealed metastatic disease to lung, mediastinum, and pelvis. Ultimately, this patient perished from metastatic disease.

3.4. Case 4

63-year-old male presenting for evaluation of recurrent bulbar conjunctival melanoma of the right eye (Fig. 2). He had an excisional biopsy prior to presenting to the University of Iowa. Pathology from that excision displayed conjunctival melanoma with invasive melanoma at all horizontal borders. At time of evaluation, he had diffuse pigmentation of the superior and nasal bulbar conjunctiva. Given that a large resection would be required, IFN- α 2B was offered as adjunctive therapy. He was treated with IFN- α 2B for 6 months, with the end point being elimination of pigmentation. Most of the pigment had resolved at the end of the 6-month treatment and the patient elected to observe pigmentation. Six months following cessation of IFN- α 2B, the patient had recurrence of pigmentation on the superior conjunctiva, which warranted an excisional biopsy. This revealed infiltrating melanoma with PAM with atypia at nasal margin and melanoma in situ at nasal margin. Excisional biopsy with cryotherapy and mitomycin C application was performed again. The biopsy displayed invasive melanoma of nasal conjunctiva with clear surgical margins. He had no recurrence of melanoma at 14-month follow up.

3.5. Case 5

59-year-old female presenting for recurrent melanoma of the nasal bulbar conjunctiva (Fig. 2). She had a previous biopsy that showed invasive melanoma at all surgical borders. One month later, she was evaluated at the University of Iowa. At time of evaluation, she was noted to have a nasal 1.5 mm by 1.7 mm pigmented bulbar lesion. After discussion, the patient elected to treat initially with IFN- α 2B. She underwent a 3-month course of IFN- α 2B. There was no change in

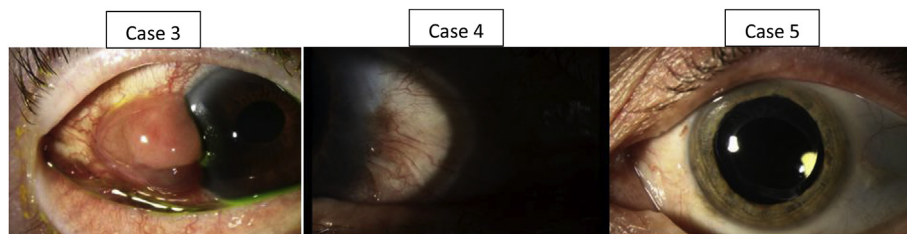

Fig. 2. Clinical pictures of initial presentation of three cases with margins positive for invasive melanoma after initial excision, with recurrence of disease and subsequent requirement for additional surgery after use of topical adjunctive IFN- α 2b.

pigmentation of lesion, so excisional biopsy with cryotherapy was performed. The pathology displayed malignant melanoma with positive deep and limbal margins. The patient elected for enucleation. She had no systemic or local recurrence at 12-month follow up.

4. Discussion

IFN- α 2b is a cytokine that has been utilized for ocular conditions such as squamous cell carcinoma of the conjunctiva, carcinoma in situ, and conjunctival papilloma.¹¹ Evidence for use of IFN- α 2b in conjunctival melanoma is limited and lacking data for appropriate use and prognostic clinical characteristics.

The precise mechanism of IFN- α 2b in the case of melanocytic lesions of the conjunctiva is speculative. There is evidence that melanomas have receptors for interferons, and therefore, IFN- α 2b may act directly by a cytotoxic mechanism. It is also suggested that IFN- α 2b may act via an indirect mechanism by upregulating MHC class 1 expression, therefore enhancing activity of cytotoxic CD8⁺ T cells, natural killer cells, and macrophages.^{9,12}

There have been previous studies describing the use of IFN- α 2b in conjunctival melanoma following surgical excision. Kikuchi et al. described use of IFN- α 2b following excisional therapy for CM in 5 cases. This is the only study that has described surgical margins at time of excision, which may be important for predicting efficacy of IFN- α 2b for remission. In that study, 4 of 5 cases reported remission without recurrence at 18–78 months. In 3 of these cases without disease recurrence, surgical margins were positive for invasive melanoma. It is not clear whether the deep border was involved in any of the cases in that study. However, in one case, there was PAM with atypia at horizontal margin without recurrence of disease. In the single case with positive deep margins for invasive melanoma, recurrence was reported with ultimate exenteration.¹⁰ Finger et al. described use of IFN- α 2b in 5 patients with CM, and 3 of 5 cases had complete remission of disease up to 13 months. One case displayed decreased pigmentation but not complete resolution after 6 weeks of treatment. Another case had 3 recurrences of CM and required 3 excisional biopsies despite IFN- α 2b use.¹³ Herold et al.¹⁴ reported the use of IFN- α 2b in 3 eyes with CM. In that series, 1 of 3 cases required additional excision, and 2 cases achieved remission through 19 and 20 months of follow-up. Garip et al. reported recurrence of CM in 4 of 7 cases treated with IFN- α 2b. Five of 7 cases required repeated treatment with IFN- α 2b, and in 6 cases a decrease in pigmentation was reported.⁹ Altogether, in the literature, there have been 20 reported cases of CM treated by IFN- α 2b. Remission was described in 11 cases at an average of 15 months duration. Repeat biopsy and repeat IFN- α 2b therapy was described in 9 cases. Unfortunately, the data are still unclear regarding the predictive clinical characteristics for success in management with IFN- α 2b.

There have been mixed results using topical IFN- α 2b as adjunctive therapy for CM in all studies we reviewed. While the literature has been descriptive regarding the clinical response of CM to adjunctive IFN- α 2b therapy, there has not been an organized effort devoted to identifying key characteristics that may predict successful therapy. In our series, the pathologic margins of the excisional biopsy appear to be instructive for predicting the clinical response to IFN- α 2b. In our 3 cases of invasive melanoma at the margins, all cases required additional surgical therapy. In both of our cases with PAM at the surgical margins, there was no recurrence of disease. Current studies have all used topical IFN- α 2b, without any series investigating subconjunctival therapy. While it may be useful to deliver therapy directly proximate to the positive surgical margin via subconjunctival injection, further investigation would be required. This series is small and retrospective, limiting its universality. However, CM is a rare disease with even fewer patients being treated with IFN- α 2b, which represents a limitation common to investigations in this area. With our study, clinicians may now apply clinical characteristics that carry prognostic value to help guide the use of topical IFN- α 2b adjunctive therapy in cases of conjunctival

melanoma with positive margins.

5. Conclusions

IFN- α 2b does not have sufficient evidence currently to support its use as an adjunctive therapy following incomplete resection of CM with positive margins for invasive melanoma. Caution must be used in the setting of excisional biopsy margins that are positive for invasive conjunctival melanoma because patients may require additional excisional therapy despite adjunctive IFN- α 2b use and metastasis may still occur despite its use. Adjuvant IFN- α 2b therapy following excisional biopsy in cases with margins positive for PAM or melanoma in situ may prove beneficial for control and remission of disease.

5.1. Patient consent

The accumulation of data was carried out with approval from our Institutional Review Board (IRB). Written consent to publish these cases was not obtained. This report does not obtain any personal identifying information.

Acknowledgements and Disclosures

Funding

No funding or grant support.

Conflicts of interest

No conflicting relationship exists for any author.

Authorship

All authors attest they meet the current ICMJE criteria for authorship.

Acknowledgements

None.

Appendix A. Supplementary data

Supplementary data to this article can be found online at <https://doi.org/10.1016/j.ajoc.2019.100467>.

References

- Seregard S. Conjunctival melanoma. *Surv Ophthalmol.* 1998;42(4):321–350.
- Isager P, Engholm G, Overgaard J, Storm H. Uveal and conjunctival malignant melanoma in Denmark 1943–97: observed and relative survival of patients followed through 2002. *Ophthalmic Epidemiol.* 2006;13(2):85–96.
- Wong JR, Nanji AA, Galor A, Karp CL. Management of conjunctival malignant melanoma: a review and update. *Expert Rev Ophthalmol.* 2014;9(3):185–204.
- Shields CL, Naseripour M, Shields JA, Eagle Jr RC. Topical mitomycin-C for pagetoid invasion of the conjunctiva by eyelid sebaceous gland carcinoma. *Ophthalmology.* 2002;109(11):2129–2133.
- Finger PT, Milner MS, McCormick SA. Topical chemotherapy for conjunctival melanoma. *Br J Ophthalmol.* 1993;77(11):751–753.
- Kurli M, Finger PT. Topical mitomycin chemotherapy for conjunctival malignant melanoma and primary acquired melanosis with atypia: 12 years' experience. *Albrecht Von Graefes Arch Clin Exp Ophthalmol Albrecht von Graefes Archiv fur klinische und experimentelle Ophthalmologie.* 2005;243(11):1108–1114.
- Ditta LC, Shieldkrot Y, Wilson MW. Outcomes in 15 patients with conjunctival melanoma treated with adjuvant topical mitomycin C: complications and recurrences. *Ophthalmology.* 2011;118(9):1754–1759.
- Karp CL, Galor A, Chhabra S, Barnes SD, Alfonso EC. Subconjunctival/perilesional recombinant interferon alpha2b for ocular surface squamous neoplasia: a 10-year review. *Ophthalmology.* 2010;117(12):2241–2246.
- Garip A, Schaumberger MM, Wolf A, et al. Evaluation of a short-term topical interferon alpha-2b treatment for histologically proven melanoma and primary acquired melanosis with atypia. *Orbit.* 2016;35(1):29–34.

10. Kikuchi I, Kase S, Ishijima K, Ishida S. Long-term follow-up of conjunctival melanoma treated with topical interferon alpha-2b eye drops as adjunctive therapy following surgical resection. *Albrecht Von Graefes Arch Clin Exp Ophthalmol Albrecht von Graefes Archiv fur klinische und experimentelle Ophthalmologie*. 2017;255(11):2271–2276.
11. Ferrantini M, Capone I, Belardelli F. Interferon-alpha and cancer: mechanisms of action and new perspectives of clinical use. *Biochimie*. 2007;89(6-7):884–893.
12. Baron S, Tying SK, Fleischmann Jr WR, et al. The interferons. Mechanisms of action and clinical applications. *Jama*. 1991;266(10):1375–1383.
13. Finger PT, Sedeeq RW, Chin KJ. Topical interferon alfa in the treatment of conjunctival melanoma and primary acquired melanosis complex. *Am J Ophthalmol*. 2008;145(1):124–129.
14. Herold TR, Hintschich C. Interferon alpha for the treatment of melanocytic conjunctival lesions. *Albrecht Von Graefes Arch Clin Exp Ophthalmol Albrecht von Graefes Archiv fur klinische und experimentelle Ophthalmologie*. 2010;248(1):111–115.