

Case report

Case of isolated *Rhizobium radiobacter* contact lens-related infectious keratitis: A plant microbe now emerging as a human pathogenBeau J. Fenner^{a,b}, Ashish Kumar^a, Nicholas Y.Q. Tan^{a,b}, Marcus Ang^{a,b,c,*}^a Singapore National Eye Centre, 11 Third Hospital Avenue, Singapore^b Singapore Eye Research Institute, 20 College Road Discovery Tower Level 6, The Academia, Singapore^c Ophthalmology and Visual Sciences, Duke National University of Singapore, 20 College Road Discovery Tower Level 6, The Academia, Singapore

ARTICLE INFO

Keywords:

Rhizobium radiobacter

Infectious keratitis

Contact lens

Atypical bacterial keratitis

ABSTRACT

Purpose: To report a case of contact lens-related infectious keratitis caused by the Gram-negative plant pathogen *Rhizobium radiobacter*.

Observations: A 26-year old lady with history of contact lens use presented with three weeks history of right eye redness and pain, with the left eye also being involved in the past week. Slit lamp examination of the right eye demonstrated multiple faint subepithelial and stromal infiltrates with no overlying epithelial defect, and no anterior chamber activity. Anterior segment optical coherence tomography demonstrated multiple hyper-reflective foci scattered at various depths of the corneal stroma. Corneal scrapings grew *Rhizobium radiobacter*, and culture-directed antibiotic therapy with topical gentamicin and levofloxacin resulted in slow clinical improvement of the *R. radiobacter* keratitis without visual sequelae.

Conclusions and importance: We have described the clinical features, microbial susceptibilities, and response to treatment in a case of *R. radiobacter* infectious keratitis.

R. radiobacter has recently emerged as a source for several ocular and systemic infections and was identified in a series of polymicrobial keratitis cases. Our case report of monomicrobial *R. radiobacter* keratitis adds to the sparse literature on this uncommon but potentially sight-threatening infection.

1. Introduction

Bacterial keratitis is one of the most commonly encountered sight-threatening conditions in ophthalmology. In developed regions, contact lens-related bacterial keratitis accounts for most of these infections. Estimates of the incidence of contact lens-related bacterial keratitis range from as low as one in 5000 per year of wear for rigid contact lenses to as high as one in 500 per year for extended wear soft contact lenses.^{1–3} For the past several decades a small number of bacterial pathogens have been recognized as the etiologic agents for most contact lens-related keratitis cases, including *Pseudomonas aeruginosa*, *Staphylococcus aureus* and commensal species of *Staphylococcus* and *Streptococcus*.^{4,5} Less commonly, corneal infections are caused by atypical organisms including environmental bacteria and fungi that may evade microbiological diagnosis. Mixed microbial infections may also occur with atypical organisms that have been associated with a poor visual prognosis due to the difficulty in addressing various antibiotic susceptibilities.⁶

Here we report a case of atypical bacterial keratitis caused by the

Gram-negative plant pathogen *Rhizobium radiobacter*, which has previously been found to cause several human infections and has recently been identified as a cause of bacterial keratitis.

2. Case report

A 26-year-old Chinese female with a history of monthly disposable soft contact lens wear and poor lens hygiene (used whilst bathing and occasional swimming) presented to our hospital with a one-week history of left eye redness, pain and photophobia. This was preceded by right eye redness and pain for three weeks that was symptomatically improving without treatment.

On presentation her best-corrected visual acuity was 20/30 in the right eye 20/40 in the left. Slit lamp examination of the right eye disclosed multiple faint subepithelial and stromal infiltrates without significant corneal edema or anterior chamber reaction, few punctate epithelial erosions and a pseudo-dendritic staining lesion. (Fig. 1A and B). The left eye had a central stromal infiltrate associated with a 3.5 × 2.5 mm epithelial defect and anterior chamber cells 1 + with

* Corresponding author. Singapore National Eye Centre, 11 Third Hospital Avenue, 168751, Singapore.

E-mail address: Marcus.Ang@sneec.com.sg (M. Ang).

<https://doi.org/10.1016/j.ajoc.2019.100476>

Received 10 October 2018; Received in revised form 20 May 2019; Accepted 27 May 2019

Available online 30 May 2019

2451-9936/© 2019 The Authors. Published by Elsevier Inc. This is an open access article under the CC BY-NC-ND license

(<http://creativecommons.org/licenses/by-nc-nd/4.0/>).

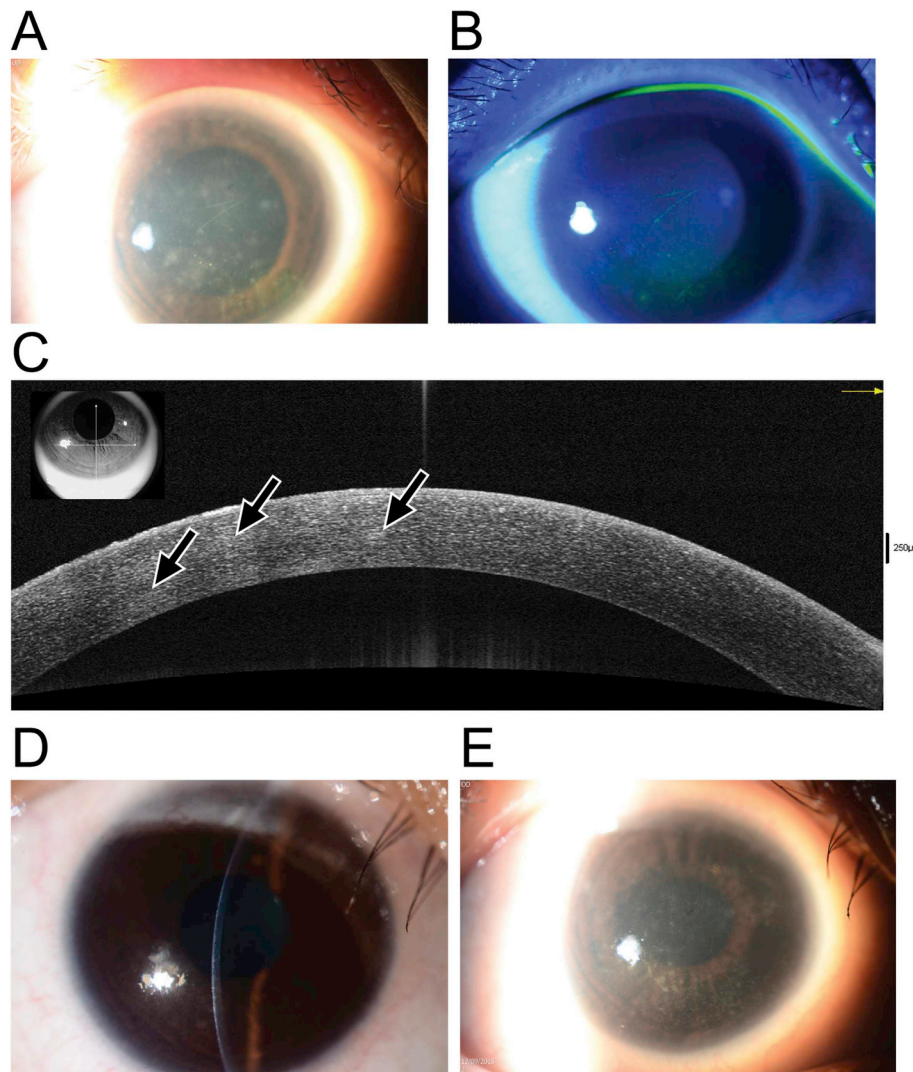


Fig. 1. A. Clinical photograph showing *Rhizobium radiobacter* keratitis at presentation, with multiple foci of feathery subepithelial and stromal infiltrates. B. Fluorescein staining with cobalt blue illumination of the infection at presentation showing punctate epithelial erosions but no epithelial defect. C. Anterior segment optical coherence tomography (AS-OCT) demonstrating the presence of multiple mildly hyperreflective foci throughout the anterior, middle, and deep stroma (arrows). D and E. Clinical photographs showing stromal scar formation following two weeks of antibiotic therapy.

mild conjunctival injection. No radial perineuritis was noted. Bilateral peripheral corneal vascularization consistent with contact lens overwear was seen. Posterior segment examination of both eyes was unremarkable.

Anterior segment optical coherence tomography of the right eye demonstrated multiple hyper-reflective foci corresponding to the stromal infiltrates, which occurred from the subepithelial region down the deep stromal and predescemetic layers (Fig. 1C). Corneal scrapings of both eyes were taken for microscopy and cultures and the patient was commenced on empirical antibiotic therapy with hourly cefazolin 50 mg/mL and gentamicin 14 mg/mL (compounded by Singapore General Hospital pharmacy services). In view of the significant complaints of severe ocular pain, with the atypical appearance of the infiltrates and concomitant history of contact lens wear, this prompted suspicion of possible *Acanthamoeba* infection which is common in the local setting. Accordingly, hourly topical chlorhexidine 0.02% (compounded by Singapore General Hospital pharmacy services) was added to the initial treatment regime in the first 24 hours before culture results were obtained.

Corneal scrape cultures from the right eye grew *Rhizobium radiobacter* on brain heart infusion broth with sensitivity to cefepime (MIC 4 µg/mL), ciprofloxacin (MIC 0.25 µg/mL) and gentamicin (MIC 4 µg/

mL). No microbial growth was observed on blood, chocolate or Sabaraud agar, non-nutrient agar with *E. coli* overlay, or thioglycolate broth, and fungal microscopy was negative. Cultures from the contact lens of the right eye returned mixed bacterial growth with *Bacillus* spp., *Elizabethkingia* spp., *Serratia marcescens*, *Pseudomonas aeruginosa*, and *Stenotrophomonas maltophilia*. No growth was seen on cultures for the left eye scraping, while the left contact lens returned *Bacillus* spp., *Serratia marcescens*, *Stenotrophomonas maltophilia*, *Elizabethkingia* spp., and *Pseudomonas aeruginosa*. Bacterial identification was performed using MALDI-TOF mass spectrometry fingerprinting (MALDI Biotyper, Bruker, MA, USA).

In view of these data the treatment was changed on day four of treatment to hourly levofloxacin 1.5% (Santen Pharmaceuticals, Osaka, Japan), hourly cefazolin, and two-hourly chlorhexidine to both eyes during waking hours and ciprofloxacin 0.3% ointment (Alcon Laboratories, Texas, USA) overnight. With this therapy moderate symptomatic and clinical improvement was noted within a week, with shrinkage of the right eye stromal infiltrates and reduction in the size of the epithelial defect. The left eye ulcer had become consolidated with early scar formation. Antibiotics were tapered to three-hourly by two weeks and the patient converted to levofloxacin 1.5% monotherapy for both eyes at four weeks. Chlorhexidine drops were maintained until

four weeks in view of the high initial clinical suspicion of *Acanthamoeba*. At this time the right eye was quiet with small stromal opacities (Fig. 1 D and E) while the left eye had a central anterior to mid stromal scar. The best corrected visual acuity at this most recent follow-up was 20/20 on the right and 20/25 on the left.

3. Discussion

Here we present the atypical clinical features of a contact lens-related keratitis secondary to monomicrobial *Rhizobium* infection, which may mimic that of *Acanthamoeba* infection or may even be mistaken for viral infections such as HSV keratitis. Our case report is distinct from a previous publication of a single case of pre-existing fungal keratitis with secondary *R. radiobacter* infection, only isolated after four weeks of pre-treatment, which made it difficult to characterize its clinical presentation and signs.

Human infection by the plant pathogen *R. radiobacter* (previously *Agrobacterium radiobacter*) has been appreciated since the late 1980s, with clinical syndromes including bacteremia, urinary tract infections, cerebral abscesses, pericarditis and endocarditis, and peritonitis.^{7–14} *R. radiobacter* is an aerobic, motile, oxidase-positive and non-spore-forming Gram-negative bacillus that is unique among rhizobia in that it causes disease in humans. A noticeable trend in these infections is the tendency of *R. radiobacter* to adhere to implanted devices.¹⁵ As a plant pathogen, *Rhizobium* colonizes plant roots using well characterized biofilm adherence mechanisms¹⁶ which may also be employed during human infections.¹⁵ A series of case reports have also implicated *R. radiobacter* in ocular infections, including endophthalmitis^{17–20} and conjunctivitis.²¹ More recently, Barker and colleagues published the first report of infectious keratitis involving *R. radiobacter*.²² In their series three out of four cases were contact lens wearers, with contact lens cultures returning a similar complement of environmental bacterial flora to those reported here, including *Serratia*, *Stenotrophomonas*, and *Pseudomonas* species, among others. Similar to that case series, our patient's clinical picture was that of an atypical infectious keratitis, although in their series *R. radiobacter* was isolated with several other bacteria from the corneal scrapes, or following pre-treatment for a fungal keratitis for several weeks prior to isolation of *R. radiobacter*.

Taking our new case and those reported by Barker et al.²² together, several consistencies are apparent. *Rhizobium radiobacter* keratitis infections appear to be mainly contact lens-related with poor contact lens hygiene as a prominent risk factor. Additionally, the contact lens contamination exists as a mixed bacterial population comprising environmental bacteria. Clinically, the appearance of the corneal infiltrates is highly variable, but does not resemble typical Gram-negative keratitis. Infiltrates have a variable appearance, although only a single case from Baker and colleagues' series and the case presented here were demonstrated to have *R. radiobacter* as the sole etiological agent. The intensity of inflammation ranged from dense stromal infiltrates with hypopyon to subepithelial infiltrates without epithelial defects and more limited anterior chamber reaction. It is also important to note that in our patient the eye infected with *R. radiobacter* was only minimally symptomatic at presentation and appeared to have improved without antibiotic therapy prior to presentation. This contrasts with the large deep stromal infiltrate and hypopyon noted in the monomicrobial infection described by Barker and colleagues, although in their case the infection was complicated by the previous involvement of fungus which was treated for several weeks prior to re-scraping and identification of *R. radiobacter*. It is also interesting to note that despite the plethora of bacterial species isolated from the contact lenses of our patient, *R. radiobacter* was only isolated from a corneal scraping. This suggests either a very low initial inoculum was present in the contact lens that prevented detection in the contact lens, or that *R. radiobacter* was introduced into the eye from direct trauma, with the contact lens wear compromising the epithelial barrier and enabling bacterial penetration into the stroma. Another important finding noted to by Barker et al. is

the absence of an epithelial defect at presentation,²² which is a finding shared by our case.

Antibiotic sensitivities noted for the current *R. radiobacter* infection and that of Barker et al. include fluoroquinolones, cephalosporins, and gentamicin. In each case the infection improved within a month of starting appropriate antibiotic therapy, although in our case the response to treatment appeared to be far slower than that observed in the monomicrobial infection reported by Barker and coworkers. As with other atypical infections in our Asian population of contact lens wearers, poor response to antibiotic therapy may require therapeutic or tectonic keratoplasty to fully treat the condition.^{23–25}

This interesting case of an atypical bacterial keratitis caused by *R. radiobacter* serves to provide the clinical presentation of keratitis and raise the awareness amongst clinicians for consideration in patients with atypical presentations and poor response to treatment. An increased surveillance of this plant pathogen may reveal this as an emerging cause of multiple local and systemic infections in humans.

Patient consent

Consent to publish the case report was not obtained. This report does not contain any personal information that could lead to identification of the patient.

Acknowledgements and disclosures

Funding

No funding or grant support

Conflicts of interest

The authors have no financial disclosures.

Authorship

All authors attest that they meet the current ICMJE criteria for Authorship.

Acknowledgements

None.

References

- Liesegang TJ. Contact lens-related microbial keratitis: Part I: Epidemiology. *Cornea*. 1997;16:125–131.
- Cheng KH, Leung SL, Hoekman HW, et al. Incidence of contact-lens-associated microbial keratitis and its related morbidity. *Lancet*. 1999;354:181–185.
- Stapleton F, Keay L, Edwards K, et al. The incidence of contact lens-related microbial keratitis in Australia. *Ophthalmology*. 2008;115:1655–1662.
- Stapleton F, Naduvilath T, Keay L, et al. Risk factors and causative organisms in microbial keratitis in daily disposable contact lens wear. *PLoS One*. 2017;12:e0181343.
- Green M, Apel A, Stapleton F. Risk factors and causative organisms in microbial keratitis. *Cornea*. 2008;27:22–27.
- Ahn M, Yoon KC, Ryu SK, Cho NC, You IC. Clinical aspects and prognosis of mixed microbial (bacterial and fungal) keratitis. *Cornea*. 2011;30:409–413.
- Edmond MB, Riddler SA, Baxter CM, Wicklund BM, Pasculle AW. *Agrobacterium radiobacter*: a recently recognized opportunistic pathogen. *Clin Infect Dis*. 1993;16:388–391.
- Dunne Jr WM, Tillman J, Murray JC. Recovery of a strain of *Agrobacterium radiobacter* with a mucoid phenotype from an immunocompromised child with bacteremia. *J Clin Microbiol*. 1993;31:2541–2543.
- Amaya RA, Edwards MS. *Agrobacterium radiobacter* bacteremia in pediatric patients: case report and review. *Pediatr Infect Dis J*. 2003;22:183–186.
- Paphitou NI, Rolston KV. Catheter-related bacteremia caused by *Agrobacterium radiobacter* in a cancer patient: case report and literature review. *Infection*. 2003;31:421–424.
- Chen CY, Hansen KS, Hansen LK. *Rhizobium radiobacter* as an opportunistic pathogen in central venous catheter-associated bloodstream infection: case report and review. *J Hosp Infect*. 2008;68:203–207.

12. Rojas LO, Martinez LF, Vives CH, Lopez EA, Cifuentes M. Cerebral abscess caused by *Rhizobium radiobacter*: first case report. *AIDS*. 2012;26:897–898.
13. Badrising S, Bakker L, Lobatto S, van Es A. Peritonitis in a peritoneal dialysis patient due to *Rhizobium radiobacter* and *Moraxella osloensis*: case report and literature review. *Perit Dial Int*. 2014;34:813–815.
14. Riley PS, Weaver RE. Comparison of thirty-seven strains of Vd-3 bacteria with *Agrobacterium radiobacter*: morphological and physiological observations. *J Clin Microbiol*. 1977;5:172–177.
15. Sawhney S, Naab T, Oneal P. *Rhizobium radiobacter* infection in a 27-year-old african American woman with munchausen syndrome. *Lab Med*. 2016;47:e32–e34.
16. Heindl JE, Wang Y, Heckel BC, Mohari B, Feirer N, Fuqua C. Mechanisms and regulation of surface interactions and biofilm formation in *Agrobacterium*. *Front Plant Sci*. 2014;5:176.
17. Pierre-Filho Pde T, Ribeiro AP, Passos ED, Torigoe M, de Vasconcellos JP. Endophthalmitis caused by *Agrobacterium radiobacter*. *Scand J Infect Dis*. 2003;35:410–411.
18. Moreau-Gaudry V, Chiquet C, Boisset S, et al. Three cases of post-cataract surgery endophthalmitis due to *Rhizobium (Agrobacterium) radiobacter*. *J Clin Microbiol*. 2012;50:1487–1490.
19. Al-Abdullah AA, Al-Falah M, Al-Rashaed S, Khandekar R, Arevalo JF. Endophthalmitis caused by *Rhizobium radiobacter* after posterior chamber phakic intraocular lens implantation to correct myopia. *J Refract Surg*. 2015;31:561–563.
20. Namdari H, Hamzavi S, Peairs RR. *Rhizobium (Agrobacterium) radiobacter* identified as a cause of chronic endophthalmitis subsequent to cataract extraction. *J Clin Microbiol*. 2003;41:3998–4000.
21. Jacobson JA, Call NB, Kasworm EM, Dirks MS, Turner RB. Safety and efficacy of topical norfloxacin versus tobramycin in the treatment of external ocular infections. *Antimicrob Agents Chemother*. 1988;32:1820–1824.
22. Barker NH, Thompson JM, Mullen MG, et al. *Rhizobium radiobacter*: a recently recognized cause of bacterial keratitis. *Cornea*. 2016;35:679–682.
23. Ang M, Mehta JS, Mantoo S, Tan D. Deep anterior lamellar keratoplasty to treat microsporidial stromal keratitis. *Cornea*. 2009;28:832–835.
24. Ang M, Mehta JS, Sng CC, Htoon HM, Tan DT. Indications, outcomes, and risk factors for failure in tectonic keratoplasty. *Ophthalmology*. 2012;119:1311–1319.
25. Ang M, Mehta JS, Arundhati A, Tan DT. Anterior lamellar keratoplasty over penetrating keratoplasty for optical, therapeutic, and tectonic indications: a case series. *Am J Ophthalmol*. 2009;147:697–702 e2.