



Case report

Bilateral methamphetamine-induced ischemic retinopathy

Jingli Guo¹, Wenyi Tang¹, Wei Liu^{**},², Yongjin Zhang, Ling Wang^{**},², Wenji Wang

Dept. of Ophthalmology, Eye and ENT Hospital of Fudan University, NHC Key Laboratory of Myopia (Fudan University), Shanghai, China



ARTICLE INFO

Keywords:

Intranasal

Ischemic retinopathy

Methamphetamine

Multimodal imaging

Panretinal photocoagulation

ABSTRACT

Purpose: To describe the multimodal imaging and treatment of a 37-year-old male presenting with bilateral ischemic retinopathy induced by methamphetamine abuse.

Observations: A 37-year-old male presented with progressively deteriorating vision and was found to have branch retinal artery occlusion and central retinal vein occlusion in both eyes along with secondary vitreous hemorrhage in the left eye following seven years of intermittent intranasal methamphetamine abuse. Fundus fluorescein angiography and optical coherence tomography angiography revealed large areas of non-perfusion in the peripheral retina along with peripapillary neovascularization. Systemic evaluation revealed ischemic foci scattered in the deep brain on magnetic resonance angiography scanning. Based on the retinal findings, the patient was diagnosed with methamphetamine-induced ischemic retinopathy. He received panretinal photocoagulation, which improved the vision in the right eye and vitreous hemorrhage in the left eye. The vision in the left eye remained stable.

Conclusions and importance: This case highlights that intranasal methamphetamine abuse is associated with bilateral simultaneous central retinal vein occlusion and branch retinal artery occlusion. To our knowledge, extensive bilateral ischemic retinopathy has not been documented previously with newer modalities. In addition, PRP may be considered for the treatment of ischemic retinopathy induced by methamphetamine abuse.

1. Introduction

Methamphetamine is a recreational drug that is structurally similar to amphetamine and exerts adrenomimetic actions similar to cocaine.¹ Methamphetamine is a psychostimulant belonging to the phenethylamine and amphetamine class of psychoactive drugs, which can result in several harmful pathophysiologic outcomes encompassing the psychologic, cardiovascular, and neurological systems.² Crystal methamphetamine typically refers to a highly purified form of methamphetamine that is intended for smoking, and has similar effects to intravenous methamphetamine.¹ To date, however, few studies have highlighted the specific changes to the eye.^{3–6} Here, we report the first case of presumed methamphetamine-induced ischemic retinopathy detected by multimodal imaging.

2. Case report

A 37-year-old man with no significant medical history was referred to our outpatient clinic to evaluate deteriorating vision in both eyes after seven years of intranasal methamphetamine abuse. Best-corrected visual acuity (BCVA) was 20/50 in the right eye and 20/200 in the left eye. The intraocular pressure was normal in both eyes. The pupils were round and reactive to light with a relative afferent pupillary defect. Anterior segment exam was normal in both eyes. Fundus examination revealed bilateral optic disc hyperemia with retinal neovascularization, radial superficial hemorrhages, whitening of the temporal vascular arcades, and marked bilateral venous distortion (Fig. 1). There was extensive vitreous hemorrhage (VH) in the left eye (Fig. 1). Spectral domain-optical coherence tomography (SD-OCT; Heidelberg Engineering, Heidelberg, Germany) showed bilateral atrophy in the temporal macula (Fig. 2). Fluorescein angiography and indocyanine green angiography revealed sporadic microaneurysms, a large peripheral area of

* Corresponding author. Dept. of Ophthalmology, Eye and ENT Hospital of Fudan University, NHC Key Laboratory of myopia (Fudan University), Shanghai, 200031, China.

** Corresponding author. Dept. of Ophthalmology, Eye and ENT Hospital of Fudan University, NHC Key Laboratory of myopia (Fudan University), Shanghai, 200031, China.

E-mail addresses: bfgf14@aliyun.com (W. Liu), mickylw@163.com (L. Wang).

¹ Both authors contributed equally as First authors.

² Both authors contributed equally as Corresponding authors.

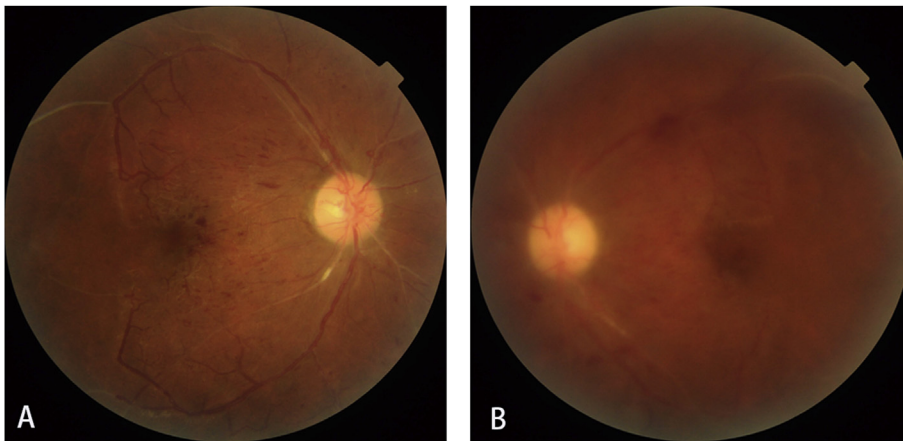


Fig. 1. Color fundus photographs of the A) right and B) left eyes of a 37-year-old man with bilateral ischemic retinopathy. Bilateral optic disc hyperemia and edema with retinal neovascularization, radial superficial retinal hemorrhage, and whitening of the temporal vascular arcade were found. (For interpretation of the references to colour in this figure legend, the reader is referred to the Web version of this article.)

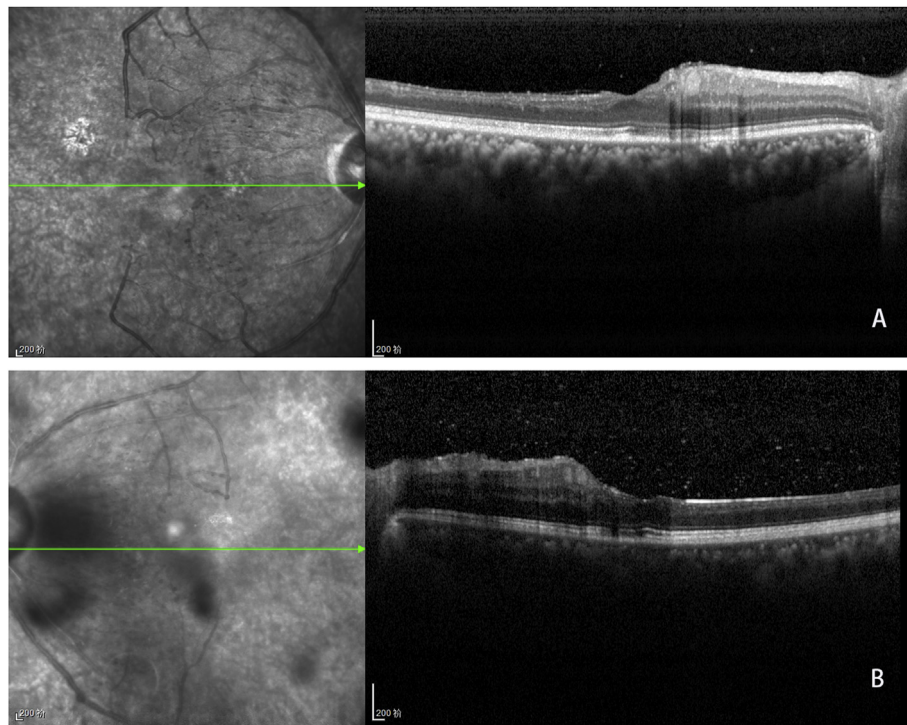


Fig. 2. Bilateral spectral domain-optical coherence tomography of the patient on initial presentation of the A) right and B) left eyes revealed bilateral retinal atrophy in the temporal macula.

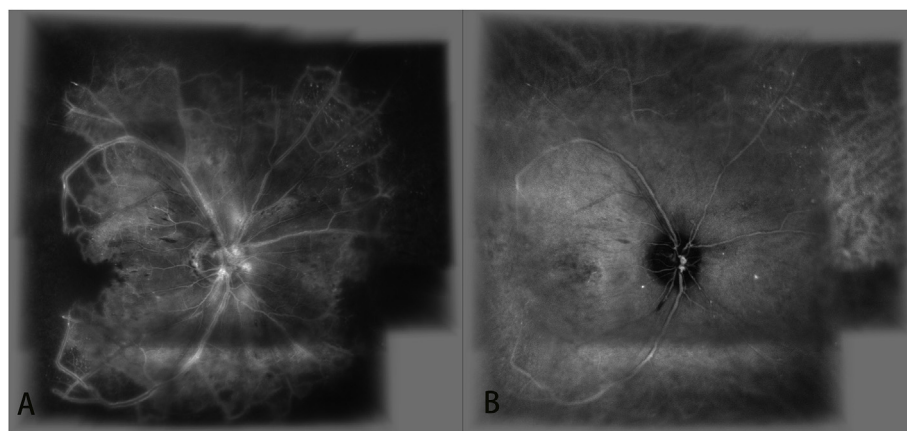


Fig. 3. A) Fluorescein angiography and B) indocyanine green angiography of the right eye revealed sporadic microaneurysms, a large peripheral area of hypofluorescence secondary to non-perfusion, venous beading, and hyperfluorescence and leakage at the optic disc, indicative of retinal neovascularization.

hypofluorescence secondary to non-perfusion, and venous beading, together with hyperfluorescence and leakage at the disc, indicative of retinal neovascularization in the right eye (Fig. 3).

In order to look for the cause of ischemic retinopathy, the patient underwent related system examinations. Review of systems was unremarkable. Magnetic resonance angiography revealed scattered ischemic foci in deep locations in the brain. Carotid duplex ultrasound, abdominal ultrasonography, and echocardiography were normal. Laboratory data, including complete blood count, sedimentation rate, coagulation function, c-reactive protein, angiotensin converting enzyme level, antinuclear antibodies, anticardiolipin antibody, anti-Toxoplasma gondii antibodies, and fluorescent treponemal antibody absorption tests, were normal.

The patient was diagnosed with methamphetamine-induced ischemic retinopathy and received panretinal photocoagulation (PRP) to treat neovascularization in both eyes. After treatment, the BCVA increased to 20/25 in the right eye and remained stable in the left eye, and VH in the left eye resolved. Spectral-domain optical coherence tomography angiography (SD-OCTA; Optovue RTVue XR 100, Avanti, Fremont, CA, USA) showed that retinal neovascularization decreased after PRP (Fig. 4). There were persistent large areas of ischemia in the inner retina in both eyes at the last follow-up confirmed by wide-angle swept-source OCTA (SS-OCTA, PlexElite 9000; Carl Zeiss Meditec Inc., Dublin, USA) (Fig. 5).

3. Discussion

Methamphetamine is a synthetic amine belonging to the amphetamine class of drugs that exerts acute and chronic effects on the central and peripheral nervous systems.⁷ Its acute effects include cardiovascular and psychiatric changes, whereas its chronic effects include structural and functional brain damage.⁸ Methamphetamine may be taken orally, intravenously, or intranasally. The mode of administration is associated with differences in ischemic and hemorrhagic lesions, with

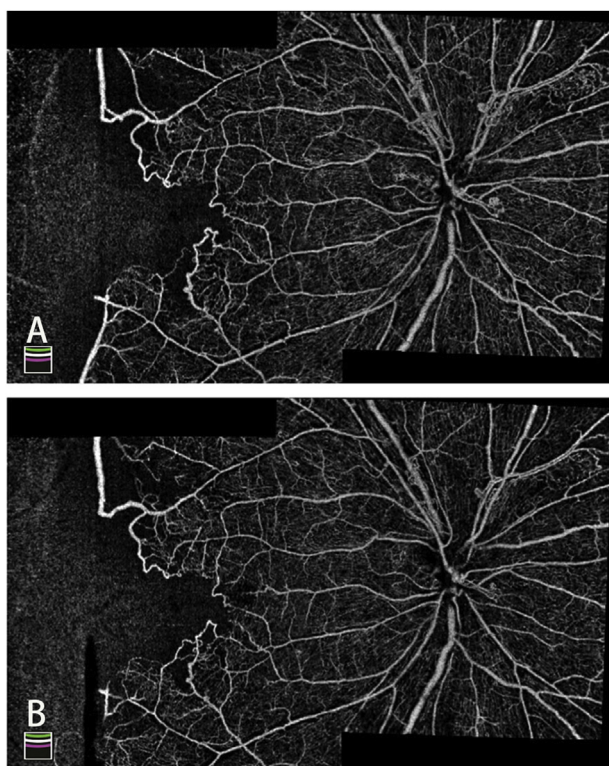


Fig. 4. Spectral domain-optical coherence tomography angiography images of the right eye obtained A) before and B) after panretinal photocoagulation showed the resolution of retinal neovascularization.

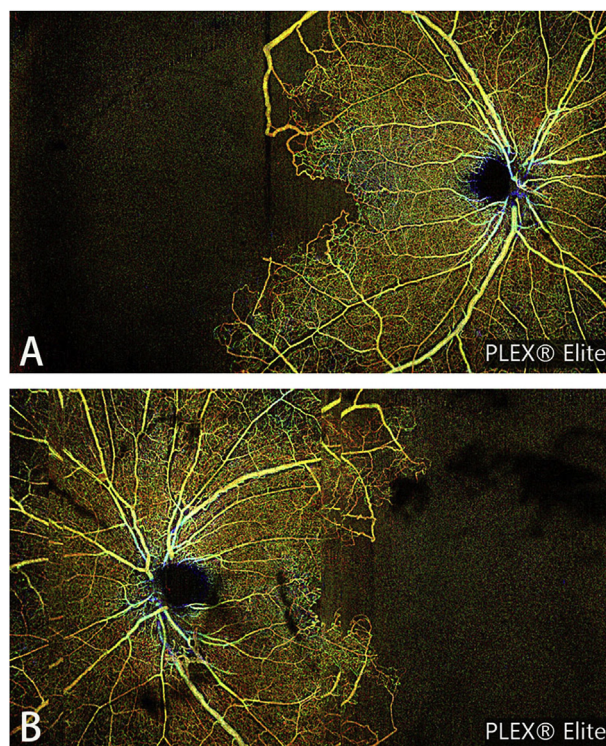


Fig. 5. The retinal vascular alterations at the last follow-up were made evident using the wide-angle swept-source optical coherence tomography angiography following panretinal photocoagulation treatment of the A) right and B) left eyes. This imaging modality can be used to reveal the characteristics of lesions and permits convenient follow-up after treatment.

a higher incidence of ischemic lesions caused by intranasal administration.¹ The pathologic mechanisms by which methamphetamine leads to ischemic and hemorrhagic diseases is not entirely clear. Wolkoff et al. suggested that chronic effects of methamphetamine led to neuronal loss secondary to microvascular damage.⁷ Lappin et al. proposed that vasculitis was responsible for cerebral infarction secondary to methamphetamine use in several cases in young patients.¹ Cerebral artery occlusion caused vasculitis, and repeated vascular spasm resulted in arterial narrowing and cerebral artery beading, with consequent ischemia and infarction in the brain.^{8,9}

Previous reports of methamphetamine-induced ocular disorders have included anophthalmia, microphthalmia, folded retina, hypoplastic optic discs, scleritis, crystalline retinopathy, central retinal artery occlusion, intraretinal hemorrhage, and retinal vasculitis in rats and patients.^{3,10,11} However, few reports have described ischemic retinopathy as side effects of methamphetamine use. In addition, the ocular effects depended on the route of administration and the disparate pharmacological mechanisms of methamphetamine. The adverse effects of methamphetamine on ocular development in babies born to mother using methamphetamine, particularly anophthalmia, microphthalmia, folded retina, and hypoplastic optic discs, were probably related to methamphetamine-induced oxidative damage in vital DNA structures in the fetal brain.^{3,11} Other disorders, such as scleritis, which were initially reported following intravenous administration in the recipient using the drug, also occurred as direct pharmacological and physiological effects of methamphetamine.^{3,11} Finally, the manifestation of central retinal artery occlusion, intraretinal hemorrhage, and retinal vasculitis were possibly attributed to the sympathomimetic effects of methamphetamine, which might induce extensive vasoconstriction or vascular spasm.³⁻⁵

The patient presented with bilateral branch retinal artery occlusion combined with central retinal vein occlusion, which has not been

reported previously. Wallace et al. reported unilateral central retinal vein occlusion and intraretinal hemorrhage, which they thought was related to vasospasm.⁴ Based on prior experimental and clinical results, we speculate that methamphetamine-induced oxidative stress resulted in extensive vasoconstriction or vascular spasm, which might lead to the manifestation of ischemic retinopathy (i.e. widespread areas of dropout in the superficial and deep capillary plexuses and retinal neovascularization at the optic disc revealed by OCTA examinations) after seven years of intranasal methamphetamine abuse in this patient.

Treatment options for methamphetamine-induced ischemic retinopathy have not been reported. Based on the principle of ischemic retinopathy, there are three options: 1) intravitreal anti-vascular endothelial growth factor (VEGF) therapy, 2) PRP, and 3) pars plana vitrectomy for VH. The foveal avascular ring was destroyed in the patient with extensive regions of non-perfusion in the macular region revealed by OCTA examinations. We considered that intravitreal anti-VEGF would possibly aggravate the macular ischemia as anti-VEGF drugs might worsen retinal artery occlusion^{12,13,14}; therefore, PRP was our preferred treatment. The extent of ischemia was controlled in both eyes by PRP, and consequently, the VH in the left eye gradually resolved and the BCVA in the right eye finally improved. However, a limitation in this study was the lack of a urine drug test.

4. Conclusion

Here, we report the first case of methamphetamine-induced ischemic retinopathy detected by multimodal imaging. We also report an effective method to prevent the progression of ischemic retinopathy in such cases.

Patient consent

All procedures were performed according to the principles of the Declaration of Helsinki. Written informed consent was obtained from the patient for publication of this case report.

Conflicts of interest

None of the authors has any conflicting interests to disclose.

Authorship

All authors attest that they meet the current ICMJE criteria for Authorship.

Financial disclosures

None.

Financial support

This case report was supported by grant SHDC12016116 from the Science and Technology Commission of Shanghai Municipality.

Acknowledgments

The authors would like to thank everyone involved in the care of this patient for their valuable contribution to this case report. The authors also thank the patient for agreeing to publish this report.

Appendix A. Supplementary data

Supplementary data to this article can be found online at <https://doi.org/10.1016/j.ajoc.2019.100473>.

References

- Lappin JM, Darke S, Farrell M. Stroke and methamphetamine use in young adults: a review. *J Neurol Neurosurg Psychiatry*. 2017;88(12):1079–1091.
- Yu S, Zhu L, Shen Q, Bai X, Di X. Recent advances in methamphetamine neurotoxicity mechanisms and its molecular pathophysiology. *Behav Neurol*. 2015;2015 103969.
- Hazin R, Cadet JL, Kahook MY, Saed D. Ocular manifestations of crystal methamphetamine use. *Neurotox Res*. 2009;15(2):187–191.
- Wallace RT, Brown GC, Benson W, Sivalingham A. Sudden retinal manifestations of intranasal cocaine and methamphetamine abuse. *Am J Ophthalmol*. 1992;114(2):158–160.
- Shaw HJ, Lawson JG, Stulting RD. Amaurosis fugax and retinal vasculitis associated with methamphetamine inhalation. *J Clin Neuro Ophthalmol*. 1985;5(3):169–176.
- Shah RJ, Cherney EF. Diffuse retinal ischemia following intravenous crushed oxycodone abuse. *JAMA Ophthalmol*. 2014;132(6):780–781.
- Wolkoff DA. Methamphetamine abuse: an overview for health care professionals. *Hawaii Med J*. 1997;56(2):34–36 44.
- Rothrock JF, Rubenstein R, Lyden PD. Ischemic stroke associated with methamphetamine inhalation. *Neurology*. 1988;38(4):589–592.
- Ohta K, Mori M, Yoritaka A, Okamoto K, Kishida S. Delayed ischemic stroke associated with methamphetamine use. *J Emerg Med*. 2005;28(2):165–167.
- McGee SM, McGee DN, McGee MB. Spontaneous intracerebral hemorrhage related to methamphetamine abuse: autopsy findings and clinical correlation. *Am J Forensic Med Pathol*. 2004;25(4):334–337.
- Acuff-Smith KD, George M, Lorens SA, Vorhees CV. Preliminary evidence for methamphetamine-induced behavioral and ocular effects in rat offspring following exposure during early organogenesis. *Psychopharmacology (Berlin)*. 1992;109(3):255–263.
- Poulsen EJ, Mannis MJ, Chang SD. Keratitis in methamphetamine abusers. *Cornea*. 1996;15(5):477–482.
- Manousaridis K, Talks J. Macular ischaemia: a contraindication for anti-VEGF treatment in retinal vascular disease? *Br J Ophthalmol*. 2012;96(2):179–184.
- von Hanno T, Kinge B, Fossen K. Retinal artery occlusion following intravitreal anti-VEGF therapy. *Acta Ophthalmol*. 2010;88(2):263–266.