



Original Article

Comparative validation of the radiographic and tomographic measurement of patellar height[☆]

Marco Antonio Schueda^{a,*}, Diego Costa Astur^b, Gustavo Gonçalves Arliani^b,
Gilberto Hornburg^c, Ricardo Serpa^d, Walter Heinig Neto^d, Camila Cohen Kaleka^e,
Moisés Cohen^f

^a Orthopedist and coordinator of the Knee Surgery and Arthroscopy Post-Graduation Service of Instituto de Ortopedia e Traumatologia (IOT) and Trauma Sports, Joinville, SC, Brazil

^b Orthopedist at the Sports Traumatology Center of the Orthopedics and Traumatology Department of Escola Paulista de Medicina da Universidade Federal de São Paulo (Unifesp), São Paulo, SP, Brazil

^c Radiologist at the Imaging Diagnostic Service of Hospital Dona Helena, Joinville, SC, Brazil

^d Orthopedist and Postgraduate Student at the Knee Surgery and Arthroscopy Service of IOT and Trauma Sports, Joinville, SC, Brazil

^e Orthopedist at Faculdade de Ciências Médicas da Santa Casa de Misericórdia, São Paulo, SP, Brazil

^f Full Professor and Head of the Orthopedics and Traumatology Department of Escola Paulista de Medicina da Unifesp, São Paulo, SP, Brazil

ARTICLE INFO

Article history:

Received 8 May 2012

Accepted 3 August 2012

Keywords:

Joint instability

Patella

Radiography

Tomography

ABSTRACT

Objective: To evaluate and validate the radiographic measurement of patellar height with computerized tomography scans.

Methods: Measured the patellar height through the lateral radiographic image supported by one foot and sagittal tomographic view of the knee in extension, flexion of 20°, and quadriceps contraction of 40 patients (80 knees), asymptomatic and no history of knee injuries using Insall-Salvati index. There were 20 adult females and 20 adult males.

Results: The height patellar index was higher in women of all images taken, in proportion. There was no statistical difference of patellar height index between the radiographics and tomographics images.

Conclusion: The Insall-Salvati index in females was higher in all cases evaluated. Furthermore, it is possible to measure the patellar height index during tomographic study without distorting the results obtained, using to define the presence of patella alta or patella baja.

© 2013 Sociedade Brasileira de Ortopedia e Traumatologia. Published by Elsevier Editora Ltda. Este é um artigo Open Access sob a licença de [CC BY-NC-ND](http://creativecommons.org/licenses/by-nc-nd/4.0/)

[☆] Study conducted at Centro Diagnostico por Imagem do Hospital Dona Helena, Joinville, SC, Brazil.

* Corresponding author at: Rua Borges Lagoa 783, 5° andar, Vila Clementino, CEP 04038-032, São Paulo, SP, Brazil.

E-mail: mcastur@yahoo.com (M.A. Schueda).

Validação comparativa da medida da altura patelar radiográfica e tomográfica

R E S U M O

Palavras-chave:

Instabilidade articular
Patela
Radiografia
Tomografia

Objetivo: Avaliar e validar a medida da altura patelar radiográfica em exames tomográficos em extensão, flexão de 20° e contração do quadríceps.

Métodos: Mensuração, com o uso do índice de Insall-Salvati, da altura patelar, por meio da imagem radiográfica com apoio monopodálico de perfil do joelho e corte sagittal de tomografia do joelho em extensão, flexão de 20° e contração do quadríceps, de 40 indivíduos (20 de cada sexo, 80 joelhos), adultos, assintomáticos e sem histórico de lesão.

Resultados: O índice de altura patelar foi maior nas mulheres em todas as imagens feitas, de forma proporcional. Não existiu diferença estatística dos valores da altura patelar entre o estudo radiográfico e o tomográfico.

Conclusão: O valor do índice de Insall-Salvati no sexo feminino foi maior em todas as situações avaliadas. Além disso, é possível mensurar, com o método usado e sem distorções dos resultados obtidos, o valor da altura patelar durante o estudo tomográfico para definir a presença de patela alta ou baixa.

© 2013 Sociedade Brasileira de Ortopedia e Traumatologia. Publicado por Elsevier Editora Ltda. Este é um artigo Open Access sob a licença de [CC BY-NC-ND](#)

Introduction

The position of the patella in relation to the femur has great clinical importance and it is a predisposing factor in the etiology of femoropatellar pain and instability.^{1,2} Defining whether the joint between the patella and the femur is anatomically functional is a determining factor to understand and treat this orthopedic syndrome.

The change in patellar height is called patella alta when the patella is above its anatomical position and patella infera when the patella is below its anatomical position.

This change in the vertical plane may result in other pathologies of the knee, such as osteochondropathy, patellar luxation and inflammatory processes that cause pain and joint effusion.³⁻⁵ The correct evaluation of its position is important for the alignment study of this joint and diagnosis in patients with anterior knee pain.

Several methods have been described for patellar height measurement through lateral radiographic images of the knee.^{3,6-9} Thus, the radiographic study makes possible to determine whether the patella is incongruous in the vertical plane in relation to the femoral condyles.

The use of computed tomography (CT) for the study of patella abnormalities was described by the French school of Lyon.¹⁰ The CT examination allows determining values that were developed to define the patella lateralization in the coronal plane and the shape of the patellar bone and condyles with the knee in different degrees of flexion and in muscle contraction. However, this technique does not include the study of patellar height.

The aim of this study is to assess the agreement between tomographic measurements of patellar height and lateral knee radiographic images in randomly selected patients.

Materials and methods

This study was approved by the ethics committee of the current institution. Eighty knees of forty asymptomatic individuals, with no previous history of knee injury, were randomly recruited and examined by radiography and CT between December 2009 and August 2010.

The following protocol was used for each assessed knee:

- 1 Lateral radiography of the knee supported by one foot only and 20 degrees of flexion (Fig. 1).
- 2 Computed tomography with sagittal view assessment in full extension, 20 degrees of flexion and quadriceps contraction (Fig. 2).

The radiography and CT assessments were performed by the same radiology technician, using standard positioning among the study participants.

The Insall-Salvati technique was chosen to measure patellar height in radiographic and CT assessments. For this purpose, the patellar tendon length and the patellar longest axis were measured. The association between these values, respectively, results in the Insall-Salvati index. The normal value of Insall-Salvati index in the lateral knee radiographic measurement is 1.02; values <0.8 are considered patella infera, whereas values >1.2 are considered patella alta.⁶

Statistical analysis was performed using Student's t test to assess the distribution of continuous variables and to estimate the difference between the observed values.

Results

The 40 study participants, 20 men and 20 women, were aged 18-52 years, with a mean age of 30.8 years.

The mean values found for the radiographic patellar height measurement, tomographic measurement in extension (CTE),

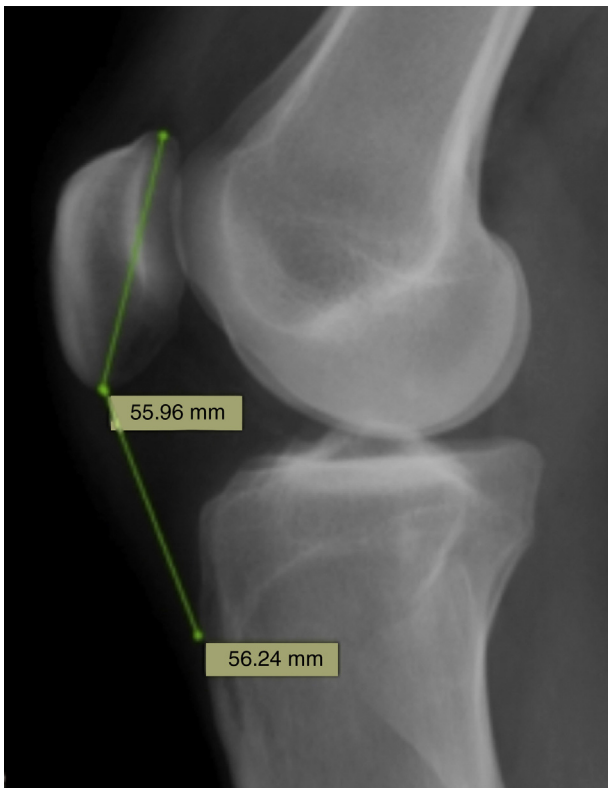


Fig. 1 – Lateral radiographic image of the knee with patellar height measurement using the Insall-Salvati technique.

20 degrees of flexion (CTF) and in quadriceps contraction (CTC) of the 80 evaluated knees can be seen in Table 1. It can be observed that there was a statistically significant difference between patellar height measurement techniques and gender of the assessed patient ($p < 0.05$). Regarding the side of the studied knee, right and left, there was no statistical difference in patellar height evaluation ($p > 0.05$).

Among the 40 patients, there was a statistical correlation between CT and radiographic measurements of patellar

height with the knee flexed at 20 degrees (ISF), in extension (ISE) and with contraction of the quadriceps (ISC) ($p < 0.05$). Based on the radiographic patellar height study (R), equations were defined to correlate the expected value of the patellar height at the CT (Table 2).

Discussion

Patellofemoral misalignment generates an abnormal contact between these structures, developing into an overload of the articular surface and the forces on the extensor mechanism,¹¹ predisposing to patellar luxation, chondromalacia and knee osteoarthritis.¹² These pathologies often cause knee pain. Most studies of anterior knee pain causal factors have sought to associate these abnormalities with patellar tilt and displacement, the morphology of the femoral trochlea^{13,14} and the tibiofemoral frontal plane alignment.^{15,16}

There are also changes in the sagittal plane, involving the patella alta and the patella infera. Patella alta is considered a clinical entity associated with pain and patellofemoral instability, as a consequence of decreased bone stability of the patella with the femur.¹¹ However, patellar height measurement is demonstrated and analyzed by lateral radiographic images with the relaxed quadriceps muscle. The contraction of this muscle causes elevation and lateralization of the patella and influences pain symptoms and signs of instability in the affected knee.^{11,17}

Several methods have been described for measurement of patellar height. Insall and Salvati⁶ were the first to describe a specific method to establish patellar height and associated the patellar tendon length with the greatest patellar length on radiographs. Bierdert and Albrecht¹⁸ used MRI to evaluate patellar height and correlated the patella to the femur. For this purpose, they used cartilaginous landmarks and thus eliminated the bone variation, which is possibly the largest source of error in accurate patellar height measurement.^{19,20}

The results of this study show that the Insall-Salvati method can be applied to CT with sagittal view in

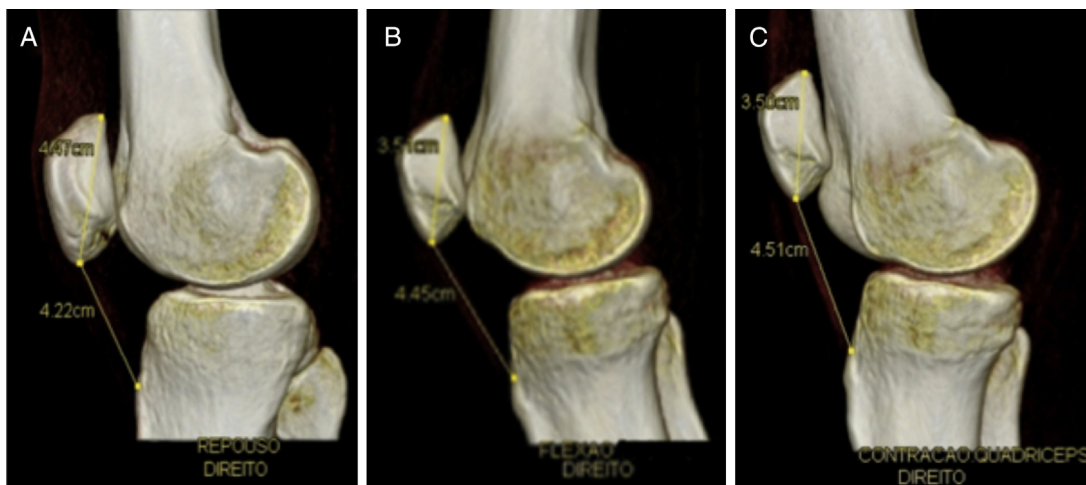


Fig. 2 – Computed tomography with sagittal view assessment of the knee in full extension (A), 20 degrees of flexion (B) and quadriceps contraction (C).

Table 1 – Mean measurement of patellar height using the Insall–Salvati method for radiographic assessment (R) and CT in extension (CTE), 20 degrees of flexion (CTF) and quadriceps contraction (CTC) between men and women. It can be observed that there were significant differences between the genders in all assessments ($p < 0.05$).

Imaging assessment	Male		Female		p value
	Mean	SD	Mean	SD	
Patellar height value					
R	1.07	0.15	1.2	0.17	<0.05
CTE	0.95	0.14	1.04	0.18	<0.05
CTC	1.04	0.14	1.17	0.19	<0.05
CTF	1.03	0.14	1.16	0.18	<0.05

SD = standard deviation.

Table 2 – Formulas developed to obtain the patellar height value using the Insall–Salvati index on CT in extension (ISE), 20 degrees of flexion (ISF) and quadriceps contraction (ISC) in the presence of the Insall–Salvati index obtained at the radiographic assessment (R) supported by one foot only, in male and female patients.

	Patellar height conversion equations	
	Male	Female
Extension	ISE = $0.11 + 0.78 \times R$	ISE = $0.03 + 0.84 \times R$
20 degrees of flexion	ISF = $0.12 + 0.85 \times R$	ISF = $0.02 + 0.95 \times R$
Quadriceps contraction	ISC = $0.14 + 0.84 \times R$	ISC = $0.02 + 0.96 \times R$

extension, as well as with 20 degrees of flexion and in contraction.⁶ This index was higher in female individuals for all measurements. This difference is probably due to the smaller size of the patella in females, as mentioned in other studies.^{21–24} Redziniak et al.²⁵ suggested in their study that the Insall–Salvati index measurement in men ranges from 0.9 to 1.1 and in women, from 0.94 to 1.18, which shows that this index is higher in women. Miller et al.²⁶ found no such difference between men and women in his study.

The results obtained when comparing patellar height measurement through radiography and CT showed a significant correlation. Considering that CT has been used as the main complementary resource in the assessment of pathologies caused by patellofemoral misalignment,^{3,27} patellar height measurement, together with the imaging study used by the Lyon protocol⁸ helps its understanding in different situations without compromising the results obtained, as there was no statistical difference between the different positions studied in radiographs and CT scans. Thus, regardless of the measurement being made through radiographic or tomographic assessment, patellar height can be obtained by the index measurement.

A criticism of the study is that only the Insall–Salvati index was correlated, as this index is not unanimously accepted in the literature for patellar height evaluation.

Conclusion

The Insall–Salvati index in females was higher in all assessed situations. Furthermore, it is possible to measure, with the method used and without distortion of the results, the value of patellar height during the tomographic study to define the presence of the patella alta or patella infera.

Conflicts of interest

The authors declare no conflicts of interest.

REFERENCES

1. Kannus PA. Long patellar tendon: radiographic sign of patellofemoral pain syndrome – a prospective study. *Radiology*. 1992;185:859–63.
2. Kujala UM, Osterman K, Kvist M, Aalto T, Friberg O. Factors predisposing to patellar chondropathy and patellar apicitis in athletes. *Int Orthop*. 1986;10:195–200.
3. Insall J, Goldberg V, Salvati E. Recurrent dislocation and the high-riding patella. *Clin Orthop Relat Res*. 1972;88:67–9.
4. Insall J, Falvo KA, Wise DW. Chondromalacia patellae. A prospective study. *J Bone Joint Surg Am*. 1976;58:1–8.
5. Møller BN, Krebs B, Jurik AG. Patellar height and patellofemoral congruence. *Arch Orthop Trauma Surg*. 1986;104:380–1.
6. Insall J, Salvati E. Patella position in the normal knee joint. *Radiology*. 1971;101:101–4.
7. Blackburne JS, Peel TE. A new method of measuring patellar height. *J Bone Joint Surg Br*. 1977;59:241–2.
8. Caton J, Deschamps G, Chambat P, Lerat JL, Dejour H. Patella infera. Apropos of 128 cases. *Rev Chir Orthop Reparatrice Appar Mot*. 1982;68:317–25.
9. De Carvalho A, Holst Andersen A, Topp S, Jurik AG. A method for assessing the height of the patella. *Int Orthop*. 1985;9:195–7.
10. Dejour H, Walch G, Nove-Josserand L, Guier C. Factors of patellar instability: an anatomic radiographic study. *Knee Surg Sports Traumatol Arthrosc*. 1994;2:19–26.
11. Ward SR, Terk MR, Powers CM. Patella alta: association with patellofemoral alignment and changes in contact area during weight-bearing. *J Bone Joint Surg Am*. 2007;89:1749–55.
12. Lancourt JE, Cristini JA. Patella alta and patella infera. Their etiological role in patellar dislocation, chondromalacia, and

- apophysitis of the tibial tubercle. *J Bone Joint Surg Am.* 1975;57:1112-5.
13. Hunter DJ, Zhang YQ, Niu JB, Felson DT, Kwok K, Newman A, et al. Patella malalignment, pain, and patellofemoral progression: the Health ABC Study. *Osteoarthritis Cartilage.* 2007;15:1120-7.
 14. Kalichman L, Zhang Y, Niu J, Goggins J, Gale D, Zhu Y, et al. The association between patellar alignment on magnetic resonance imaging and radiographic manifestations of knee osteoarthritis. *Arthritis Res Ther.* 2007;9:R26.
 15. Cahue S, Dunlop D, Hayes K, Song J, Torres L, Sharma L. Varus-valgus alignment in the progression of patellofemoral osteoarthritis. *Arthritis Rheum.* 2004;50:2184-90.
 16. Elahi S, Cahue S, Felson DT, Engelman L, Sharma L. The association between varus-valgus alignment and patellofemoral osteoarthritis. *Arthritis Rheum.* 2000;43:1874-80.
 17. Duncan R, Peat G, Thomas E, Wood L, Hay E, Croft P. Does isolated patellofemoral osteoarthritis matter? *Osteoarthritis Cartilage.* 2009;17:1151-5.
 18. Bierdert RM, Albrecht S. The patellochlear index: a new index for assessing patellar height. *Knee Surg Sports Traumatol Arthrosc.* 2006;14:707-12.
 19. Singerman R, Davy DT, Goldberg VM. Effects of patella alta and patella infera on patellofemoral contact forces. *J Biomech.* 1994;27:1059-65.
 20. Yamaguchi GT, Zajac FE. A planar model of the knee joint to characterize the knee extensor mechanism. *J Biomech.* 1989;22:1-10.
 21. Norman O, Egund N, Ekelund L, Rünow A. The vertical position of the patella. *Acta Orthop Scand.* 1983;54:908-13.
 22. Aglietti P, Insall JN, Cerulli G. Patellar pain and incongruence. I: Measurements of incongruence. *Clin Orthop Relat Res.* 1983;217-24, 176.
 23. Dowd GS, Bentley G. Radiographic assessment in patellar instability and chondromalacia patellae. *J Bone Joint Surg Br.* 1986;68:297-300.
 24. Marks KE, Bentley G. Patella alta and chondromalacia. *J Bone Joint Surg Br.* 1978;60:71-3.
 25. Redziniak DE, Diduch DR, Mihalko WM, Fulkerson JP, Novicoff WM, Sheibani-Rad S, et al. Patellar instability. *J Bone Joint Surg Am.* 2009;91:2264-75.
 26. Miller TT, Staron RB, Feldman F. Patellar height on sagittal MR imaging of the knee. *Am J Roentgenol.* 1996;167:339-41.
 27. Camanho GL, Camanho LF. O realinhamento proximal do aparelho extensor, por via artroscópica, no tratamento da luxação femoropatelar. *Rev Bras Ortop.* 2000;35:109-13.