

The role of endoscopy in the management of hereditary diffuse gastric cancer syndrome

Shria Kumar, Jessica M Long, Gregory G Ginsberg, Bryson W Katona

ORCID number: Shria Kumar (0000-0001-9745-2676); Jessica M Long (0000-0003-0382-7890); Gregory G Ginsberg (0000-0002-2023-7422); Bryson W Katona (0000-0001-8186-9119).

Author contributions: Kumar S and Katona BW planned the minireview format, reviewed literature, and wrote the paper; Long JM and Ginsberg GG provided expertise in genetics and endoscopy, respectively, and contributed via editing and writing

Supported by the National Institutes of Health T32 grant (Kumar S; Grant NO: 5T32DK7740-22).

Conflict-of-interest statement: Dr. Katona reports personal fees from Exact Sciences, other from Janssen, other from Immunovia, outside the submitted work.

Open-Access: This article is an open-access article which was selected by an in-house editor and fully peer-reviewed by external reviewers. It is distributed in accordance with the Creative Commons Attribution Non Commercial (CC BY-NC 4.0) license, which permits others to distribute, remix, adapt, build upon this work non-commercially, and license their derivative works on different terms, provided the original work is properly cited and the use is non-commercial. See: <http://creativecommons.org/licenses/by-nc/4.0/>

Manuscript source: Invited manuscript

Shria Kumar, Gregory G Ginsberg, Bryson W Katona, Division of Gastroenterology, University of Pennsylvania Perelman School of Medicine, Philadelphia, PA 19104, United States

Jessica M Long, Division of Hematology and Oncology, University of Pennsylvania Perelman School of Medicine, Philadelphia, PA 19104, United States

Corresponding author: Bryson W Katona, MD, PhD, Division of Gastroenterology, University of Pennsylvania Perelman School of Medicine, 3400 Civic Center Blvd., 751 South Pavilion, Philadelphia, PA 19104, United States. bryson.katona@uphs.upenn.edu

Telephone: +1-215-349-8222

Fax: +1-215-349-5915

Abstract

Hereditary diffuse gastric cancer (HDGC) syndrome is an inherited cancer risk syndrome associated with pathogenic germline *CDH1* variants. Given the high risk for developing diffuse gastric cancer, *CDH1* carriers are recommended to undergo prophylactic total gastrectomy for cancer risk reduction. Current guidelines recommend upper endoscopy in *CDH1* carriers prior to surgery and then annually for individuals deferring prophylactic total gastrectomy. Management of individuals from HDGC families without *CDH1* pathogenic variants remains less clear, and management of families with *CDH1* pathogenic variants in the absence of a family history of gastric cancer is particularly problematic at present. Despite adherence to surveillance protocols, endoscopic detection of cancer foci in HDGC is suboptimal and imperfect for facilitating decision-making. Alternative endoscopic modalities, such as chromoendoscopy, endoscopic ultrasound, and other non-white light methods have been utilized, but are of limited utility to further improve cancer detection and risk stratification in HDGC. Herein, we review what is known and what remains unclear about endoscopic surveillance for HDGC, among individuals with and without germline *CDH1* pathogenic variants. Ultimately, the use of endoscopy in the management of HDGC remains a challenging arena, but one in which further research to improve surveillance is crucial.

Key words: *CDH1* gene; Hereditary diffuse gastric cancer; Gastric cancer; Endoscopic screening; Endoscopy

©The Author(s) 2019. Published by Baishideng Publishing Group Inc. All rights reserved.

Core tip: Individuals with hereditary diffuse gastric cancer (HDGC) syndrome are at

Received: March 17, 2019
Peer-review started: March 19, 2019
First decision: April 4, 2019
Revised: April 8, 2019
Accepted: April 29, 2019
Article in press: April 29, 2019
Published online: June 21, 2019

P-Reviewer: Chen SQ, Cheng H, Xin Q

S-Editor: Yan JP

L-Editor: A

E-Editor: Ma YJ



increased risk of diffuse gastric cancer, and are often recommended to undergo prophylactic total gastrectomy, especially in the presence of a pathogenic germline *CDH1* variant. Endoscopy is important in the initial management and surveillance of individuals with HDGC syndrome, yet sensitivity of endoscopy for detection of cancer foci in this population is poor. Alternative endoscopic modalities have not been found to be helpful. Ultimately, there is much to be learned about how to best use endoscopy in management of HDGC.

Citation: Kumar S, Long JM, Ginsberg GG, Katona BW. The role of endoscopy in the management of hereditary diffuse gastric cancer syndrome. *World J Gastroenterol* 2019; 25(23): 2878-2886

URL: <https://www.wjgnet.com/1007-9327/full/v25/i23/2878.htm>

DOI: <https://dx.doi.org/10.3748/wjg.v25.i23.2878>

INTRODUCTION

Gastric cancer remains the fifth most common cancer worldwide. While the majority of cases are sporadic, 1-3% of gastric cancers are related to hereditary cancer syndromes, including hereditary diffuse gastric cancer syndrome (HDGC). Pathogenic germline *CDH1* variants have been associated with HDGC, although some families fulfilling HDGC clinical criteria do not have detectable germline variants^[1]. *CDH1* encodes for the tumor suppressor E-cadherin, which serves as a critical cell adhesion molecule^[2]. The connection of *CDH1* mutations to HDGC syndrome was first described in New Zealand, when Jones *et al.*^[1,3-5] suspected genetic predisposition as the cause of a high rate of gastric cancer in three Maori families. Since 1998, more than 120 different pathogenic variants of *CDH1* have been described, and carrying a germline *CDH1* pathogenic variant has been shown to portend a high risk of diffuse gastric cancer, characterized by signet ring cell carcinoma (SRCC) on histopathology, as well as lobular breast cancer in women^[6-8].

Genetic testing for *CDH1* variants is recommended for those who meet clinical criteria for HDGC^[1]. Criteria (considering first- and second-degree relatives) include having two or more family members with gastric cancer (including one confirmed diffuse gastric cancer), having one case of diffuse gastric cancer prior to age 40, or having both diffuse gastric cancer and lobular breast cancer in a family (with one diagnosed before age 50). Genetic testing can also be considered in those with cleft lip or palate and diffuse gastric cancer, in the presence of bilateral lobular breast cancer, or in families with two or more cases of lobular breast cancer before age 50. Testing for *CDH1* should include both sequencing and deletion/duplication analysis, and is now commonly performed by numerous commercial laboratories^[9]. Germline *CDH1* pathogenic variants are found in approximately 25%-50% of families meeting HDGC criteria, though rates vary by ethnic background and country^[9-12]. Those who meet testing criteria but do not have an identified *CDH1* pathogenic variant pose their own challenges in management and risk stratification. Recent studies have suggested *CTNNA1* and *MAP3K6* as other potential causative genes responsible for HDGC, however further work to confirm these associations is required^[10,13]. Additionally, other cancer susceptibility genes associated with a spectrum of cancers outside of gastric cancer, such as *BRCA2*, *STK11*, and *PALB2* have also been identified in families meeting HDGC criteria, suggesting some clinically-defined HDGC families may have a genetic basis related to another hereditary syndrome^[9].

The lifetime risk of diffuse gastric cancer in individuals with a germline *CDH1* pathogenic variant is reported to be up to 80%^[1,14,15]. However, this high cumulative lifetime risk of diffuse gastric cancer may be an over-estimate, as the advent of multi-gene panel testing has identified a notable number of *CDH1* pathogenic variants in families without a history of diffuse gastric cancer^[9,14-16], suggesting reduced penetrance in some families. Currently, individuals with a germline *CDH1* pathogenic variant are recommended to undergo prophylactic total gastrectomy, typically between the ages of 20-30^[17,18]. However, given the major implications for quality of life and nutritional status after gastrectomy, especially in younger patients, some patients opt to delay or defer prophylactic total gastrectomy^[19-22].

The role of endoscopy in the management of patients with HDGC has been studied extensively and plays an important role for diagnosis, surveillance, and risk stratification. Herein, we highlight the role of endoscopy in individuals with HDGC,

and review the recent research and advances in the field.

Guidelines for the use of endoscopy in HDGC with a known pathogenic *CDH1* variant

For patients with a pathogenic germline *CDH1* variant who undergo prophylactic total gastrectomy, baseline upper endoscopy is recommended prior to surgery to evaluate for gross tumor or other concomitant pathology that may alter the surgical approach^[1]. For those electing to defer risk reducing gastrectomy, annual surveillance endoscopy following the Cambridge protocol is advised. If microscopic or macroscopic disease is detected on surveillance, prompt gastrectomy referral is required^[1,17]. White light exam is recommended for surveillance, since other endo-scopical modalities have not proven efficacious, as discussed below.

Surveillance endoscopy via the Cambridge protocol

The Cambridge protocol was developed to help guide endoscopic surveillance in HDGC^[1]. Surveillance via the Cambridge protocol ideally should be performed in a high-volume center with a multi-disciplinary team having expertise in HDGC. Given the large number of biopsies performed, it is recommended to stop anticoagulation if possible prior to the procedure. Endoscopy should include a careful high definition white light (HDWL) exam in a session of at least 30 min. The endoscopic exam should include repeated insufflation and deflation to maximize visualization of the entire gastric mucosa and check for distensibility (the lack of which should raise concern for an infiltrative process such as *linitis plastica*). Additionally, the exam should utilize extensive washing with the assistance of mucolytic and anti-foaming agents, to permit careful examination and documentation of the entire gastric mucosa. If there is concern for poor distensibility, further evaluation should include computed tomography scan and endoscopic ultrasonography (EUS).

Prior to obtaining random gastric biopsies, all visible lesions, pale areas (considered more likely to have abnormal signet ring cells), and other gastric abnormalities should be separately biopsied and sent for pathologic evaluation^[5,23]. After sampling of all visible lesions, five random biopsies should then be taken from each of 6 anatomic regions: prepyloric, antrum, transitional zone, body, fundus, and cardia, with these groups of biopsies each being sent separately for pathologic analysis (see **Figure 1**). Despite no known association between *Helicobacter pylori* (*H. pylori*) and HDGC, baseline *H. pylori* testing on the gastric biopsy specimens is recommended given that *H. pylori* is considered a class I carcinogen by the World Health Organization. Subsequent treatment and confirmation of eradication of individuals who are *H. pylori* positive is advised^[1,24].

EFFICACY OF ENDOSCOPY IN *CDH1* FAMILIES

Endoscopic detection of SRCC foci in *CDH1* carriers is poor, and evaluation of surgical pathology demonstrates cancer foci in 45%-60% of those with negative endoscopic evaluations^[5,11,21,25]. The reason for this poor performance is due to the occult and difficult to predict nature of HDGC. HDGC is rarely restricted to one location in the stomach^[6,26]. Independent studies have found vastly different results when evaluating the regions of the stomach where the HDGC-related SRCC foci are located^[27-29]. This heterogeneity in location, as well as the inability to reliably visualize the SRCC foci on visual mucosal examination, both play a large role in the inability to reliably detect SRCC foci endoscopically. A model developed by Fujita *et al*^[28] evaluated yield of cancer foci in a topographic pattern on 10 gastrectomy specimens from individuals with pathogenic germline *CDH1* variants. This model estimated that for a 90% detection of cancer foci, the theoretical number of biopsies necessary to capture at least a single cancer focus was estimated to be 1768 per patient, which is clearly not clinically feasible. However, the yield of endoscopically detecting SRCC foci pre-operatively is both correlated with the number of biopsies taken and the number of SRCC lesions in the gastrectomy specimen^[30]. As described by de Almeida *et al*^[6], there are also practical issues beyond the number of biopsies required, including scarring from repeated biopsies, which may mimic pale areas concerning for malignancy and may cause confusion and repeated re-biopsy of the same areas of mucosa.

Unfortunately, the specific *CDH1* variant itself does not aid in determining the potential location of SRCC or the probability of finding SRCC, especially given the vast number of *CDH1* pathogenic variants that have been described^[9,31,32]. There is also limited data of the benefit of continued surveillance in *CDH1* carriers. Most cancer foci are detected on the index endoscopy, which is likely due to detecting prevalent rather than incident cases^[11]. This is likely due to the fact that multiple foci of SRCC

30-min, careful high definition white light endoscopic exam consisting of:
 Repeated insufflation and deflation to maximize visualization and check for distensibility
 Extensive washing
 Targeted biopsies of irregularities such as visible lesions or pale areas
 5 random biopsies from each area:
 (1) Fundus, (2) Cardia, (3) Body, (4) Transitional zone, (5) Antrum, (6) Prepyloric area

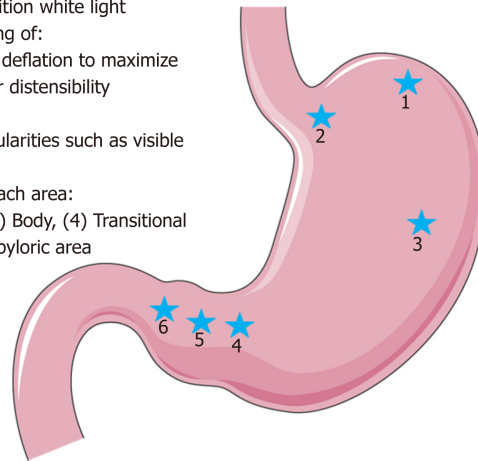


Figure 1 Illustrative representation of the Cambridge protocol for hereditary diffuse gastric cancer syndrome surveillance, full details in text and on image. Figure modified with text, markings (stars), and annotation after adaptation of "Stomach" from Servier Medical Art by Servier, licensed under a Creative Commons Attribution 3.0 Unported License. Original photo adapted from https://smart.servier.com/smart_image/stomach-3/.

develop before age 30 and have a long indolent course^[33]. It is further unknown how long these foci remain indolent, and what environmental or genetic predispositions can lead to more extensive disease.

In addition to the imperfect sensitivity of endoscopic surveillance, there are possible complications from endoscopy, as well as potential psychological hurdles in those individuals undergoing serial endoscopic evaluation, including concerns of lifelong endoscopy and the chances of false negatives^[9,11,19,34]. The concern of false reassurance in those with a negative endoscopy is not to be underestimated, either.

Chromoendoscopy

In an attempt to improve the efficiency of SRCC detection in *CDH1* carriers, several advanced endoscopic techniques have been studied, including the use of chromoendoscopy. Based on a Japanese study, Shaw *et al*^[5] published a series in 2005 describing annual chromoendoscopic surveillance in 33 patients with a pathogenic *CDH1* variant over a 5-year period. The patients initially drank a mucolytic (N-acetylcysteine) then changed position every 5 min for 30 min to ensure complete gastric coverage. The endoscopist then performed a HDWL endoscopic exam, and the patient received intravenous pentagastrin for gastric acid secretion, followed by spraying of methylene blue onto the mucosa. After absorption and suction, Congo red dye was sprayed and the mucosa was irrigated. Only pale areas were biopsied, and no random biopsies were performed. Of 56 total pale areas, 23 lesions (41%) showed SRCC (in 10 patients). When comparing these results to total gastrectomy pathology, it was shown that there was a positive correlation for foci 4-10 mm in size, but not for foci < 4 mm.

While initially promising, due to concerns about dye toxicity, chromoendoscopic exam is currently not recommended as standard of care for HDGC^[1,6]. Additionally, there were further concerns regarding the learning curve in chromoendoscopy as well as pale area detection and interpretation, as the number of pale areas detected by endoscopists increased annually, despite no change in relative number of annual surveillance procedures^[5,11].

Electronic enhanced imaging

Electronic enhanced imaging takes advantage of pre- and/or post-processing light wavelengths and filtering to amplify surface, subsurface and vascular prominence and contours. Beyond careful white-light examination with targeted and random biopsies, electronic enhanced imaging techniques have not proven to be particularly valuable for diagnosis, screening or surveillance of patients with pathologic *CDH1* gene mutations^[5,25,35]. Lim *et al*^[25] report that auto-fluorescence imaging (AFI) and narrow band imaging (NBI) were of limited utility, failing to reliably identify abnormal appearing mucosa for targeted tissue sampling. While AFI did not prove to aid in the detection of early foci of signet ring cell neoplasia, NBI was a useful imaging adjunct to delineate pale areas and, in conjunction with zoom magnification, allowed careful assessment of vascular and mucosal patterns, with a high negative predictive value in their study. Emerging electronic enhanced imaging techniques

with depth to the lamina propria layer will be tested in this condition owing to the unpredictable and patchy distribution of SRCC characteristic of early stage disease.

Endoscopic ultrasonography (EUS)

There is currently no recommendation for routine use of EUS in the management of HDGC. However, EUS can be considered for further investigation of abnormalities seen on standard HDWL endoscopic examination, such as poor distensibility of the stomach^[1]. To evaluate the utility of EUS in patients with HDGC due to a *CDH1* pathogenic variant, a retrospective analysis of 13 patients who underwent radial scanning endosonography in addition to guideline-recommended upper endoscopy before gastrectomy found no benefit in performing endoscopic ultrasound to improve detection of cancer foci^[34]. In that study, the sensitivity for identifying SRCC foci by HDWL endoscopy was 45%, similar to other descriptive series.

Confocal endoscopic microscopy

There is an ongoing NIH clinical trial evaluating the use of confocal endoscopic microscopy, which provides histologic imaging of gastric mucosa during upper endoscopy, and could improve endoscopic surveillance sensitivity (ClinicalTrials.gov Identifier: NCT03648879)^[36]. However, this technique remains experimental at this time, and should only be pursued in HDGC through a clinical trial.

Colorectal cancer screening

Although the majority of research on HDGC has focused on the role of upper endoscopic examination, there is limited evidence that there may be an association of colorectal SRCC in patients with germline *CDH1* pathogenic variants^[1]. More recent work has also speculated that the *CDH1* variant location may be an important predictor of colorectal cancer risk^[37]. Although based on limited data, enhanced colorectal cancer screening by colonoscopy is recommended for *CDH1* carriers with a family history of colon cancer, especially when there is a presence of signet ring cells and/or mucinous features of the cancer^[4,17]. In these individuals, screening should start at age 40 or 10 years prior to the youngest diagnosis in the family, and repeated every 3-5 years. In all other *CDH1* carriers, standard colorectal cancer screening guidelines should be followed based on the individual's personal and/or family history.

ROLE OF ENDOSCOPY IN PATIENTS WITH A PATHOGENIC *CDH1* VARIANT AND NO FAMILY HISTORY OF GASTRIC CANCER

Individuals with a pathogenic variant of *CDH1*, but without family history of gastric cancer, pose a unique challenge. There is limited evidence on endoscopic surveillance of these patients, and one small series found that despite no family history of gastric cancer and negative endoscopic evaluation, 50% of patients had SRCC on surgical pathology^[38]. It remains to be determined if these patients truly have decreased gastric cancer risk and reduced prevalence compared to *CDH1* carriers with a strong family history of gastric cancer^[9,14-16]. Another possibility is that in small or poorly reported-on families, family history may be inaccurate, as even in the best circumstances, family history collection can be poor^[39-41]. As such, these patients may have a true family history of gastric cancer that simply goes unrecognized.

A similar dilemma arises in *CDH1* carriers with lobular breast cancer and without a family history of diffuse gastric cancer. Recent studies regarding the management of lobular breast cancer, to which a pathogenic variant of *CDH1* increased risk, in the absence of gastric cancer family history have been small, though informative^[42-46]. These studies demonstrate that though rare, even in the absence of familial gastric cancer, lobular breast cancer may develop, and may even represent a separate cancer syndrome^[44,45,47]. This has clinical consequences for the screening of breast cancer in those with a pathogenic variant of *CDH1*, though the need for gastrectomy in these individuals is similarly cloudy^[42,43,47]. There have not been large reports of endoscopic utility in these patients.

An advantage of endoscopic surveillance in these groups would be the finding of SRCC on endoscopic biopsy, as this would justify the need for gastrectomy in the physician and patient alike. However, we would expect the sensitivity of endoscopy to be lacking, as it is in those with pathogenic variants of *CDH1* and HDGC, and therefore a negative endoscopic examination should not be overly reassuring regarding gastric cancer risk. This is an area with much uncertainty that requires further research, especially in light of the growing preponderance of multi-gene panel

testing with its resulting identification of incidental *CDH1* variants in families without a history of *CDH1*-associated cancers.

ROLE OF ENDOSCOPY IN HDGC FAMILIES WITHOUT A PATHOGENIC *CDH1* VARIANT

Individuals from families meeting HDGC criteria who lack a germline *CDH1* pathogenic variant present a significant challenge as prophylactic total gastrectomy is typically not recommended for these individuals. In these cases, endoscopic surveillance is recommended on a regular basis in a high-volume specialty center, as the identification of SRCC foci on HDWL endoscopy in these individuals can be helpful for guiding future surgical management^[1].

However, the yield of endoscopy for identifying malignant lesions is lower in those from families meeting HDGC criteria without a detectable *CDH1* pathogenic variant. This was demonstrated in a United Kingdom-based prospective cohort study of endoscopic surveillance in families with and without *CDH1* pathogenic variants; patients with *CDH1* pathogenic variants had significantly higher rates of SRCC on endoscopy than their *CDH1* negative counterparts^[11]. In this study, 85 individuals underwent endoscopic surveillance, including 54 patients (63.5%) with a *CDH1* pathogenic variant opting to delay gastrectomy and 31 patients undergoing surveillance who were *CDH1* negative. Endoscopic surveillance included 30 random biopsies as well as targeted biopsy of mucosal abnormalities. Of those with *CDH1* pathogenic variants, 33 (61.1%) had foci of SRCC detected during surveillance, the majority of which occurred at the index endoscopy. Those without a *CDH1* pathogenic variant had a much lower detection rate of SRCC, 3 of 31 (9.7%) patients. This difference was statistically significant ($P < 0.0005$), and no other factors, including age, sex, proton pump inhibitor use, or *H. pylori* infection were associated with the differential detection of cancer foci.

It has been considered that there may be a different pathogenesis for diffuse gastric cancer in *CDH1*-negative HDGC individuals, *i.e.*, that SRCC may not be the preceding lesion; however, this remains unclear and further investigation is required^[11]. Given the number of unanswered questions, including pathogenesis, yield of endoscopy, and rate and frequency of progression to cancer, the management of individuals from *CDH1*-negative HDGC families remains challenging. Mi *et al*^[11] suggested that risk stratification using allelic expression imbalance (as a marker for progression to neoplasia) may be helpful to better determine the risk for these individuals. Ideally in the future, enhanced understanding of the genetic basis for HDGC families currently without detectable *CDH1* pathogenic variants (such as via improved *CDH1* variant detection or identification of additional gastric cancer risk genes) may enable better risk stratification in this population.

Currently, endoscopic surveillance at a referral center is suggested for individuals from families meeting HDGC criteria and who lack a *CDH1* pathogenic variant. It is clear in this high-risk group that endoscopic detection of a gastric malignancy, including foci of SRCC, should prompt a referral for consideration of total gastrectomy, yet counseling these patients on negative endoscopies presents its own challenge. Additionally, the optimal frequency of surveillance in this population also remains to be determined^[18].

CONCLUSION

Management of patients with HDGC, both with and without pathogenic variants in *CDH1*, remains challenging given our lack of understanding about the critical drivers of penetrance, differential anatomical location of SRCC, and the imperfect sensitivity of endoscopy to detect early foci of SRCC. However, given the uncertainties in the field, the use of endoscopy in these individuals is an area that is ripe for future research, as improvement in endoscopic surveillance in HDGC would undoubtedly improve risk stratification, surgical management, and overall patient well-being in families with HDGC.

REFERENCES

- 1 van der Post RS, Vogelaar IP, Carneiro F, Guilford P, Huntsman D, Hoogerbrugge N, Caldas C, Schreiber KE, Hardwick RH, Ausems MG, Bardram L, Benusiglio PR, Bisseling TM, Blair V, Bleiker E, Boussioutas A, Cats A, Coit D, DeGregorio L, Figueiredo J, Ford JM, Heijkoop E, Hermens R, Humar B,

- Kaurah P, Keller G, Lai J, Ligtenberg MJ, O'Donovan M, Oliveira C, Pinheiro H, Ragunath K, Rasenberg E, Richardson S, Roviello F, Schackert H, Seruca R, Taylor A, Ter Huurne A, Tischkowitz M, Joe ST, van Dijk B, van Grieken NC, van Hillegersberg R, van Sandick JW, Vehof R, van Krieken JH, Fitzgerald RC. Hereditary diffuse gastric cancer: Updated clinical guidelines with an emphasis on germline CDH1 mutation carriers. *J Med Genet* 2015; **52**: 361-374 [PMID: 25979631 DOI: 10.1136/jmedgenet-2015-103094]
- 2 **Pecina-Slaus N.** Tumor suppressor gene E-cadherin and its role in normal and malignant cells. *Cancer Cell Int* 2003; **3**: 17 [PMID: 14613514 DOI: 10.1186/1475-2867-3-17]
 - 3 **van der Post RS, Carneiro F.** Emerging Concepts in Gastric Neoplasia: Heritable Gastric Cancers and Polyposis Disorders. *Surg Pathol Clin* 2017; **10**: 931-945 [PMID: 29103540 DOI: 10.1016/j.path.2017.07.011]
 - 4 **Jones EG.** Familial Gastric Cancer. *N Z Med J* 1964; **63**: 287-296 [PMID: 14158754]
 - 5 **Shaw D, Blair V, Framp A, Harawira P, McLeod M, Guilford P, Parry S, Charlton A, Martin I.** Chromoendoscopic surveillance in hereditary diffuse gastric cancer: An alternative to prophylactic gastrectomy? *Gut* 2005; **54**: 461-468 [PMID: 15753528 DOI: 10.1136/gut.2004.049171]
 - 6 **de Almeida Artifon EL, Marinho FRT.** Endoscopic screening for hereditary diffuse gastric cancer: One size does not fit all. *Gastrointest Endosc* 2018; **87**: 405-407 [PMID: 29406927 DOI: 10.1016/j.gie.2017.05.042]
 - 7 **Katona BW, Rustgi AK.** Gastric Cancer Genomics: Advances and Future Directions. *Cell Mol Gastroenterol Hepatol* 2017; **3**: 211-217 [PMID: 28275688 DOI: 10.1016/j.jcmgh.2017.01.003]
 - 8 **Guilford P, Hopkins J, Harraway J, McLeod M, McLeod N, Harawira P, Taite H, Scouler R, Miller A, Reeve AE.** E-cadherin germline mutations in familial gastric cancer. *Nature* 1998; **392**: 402-405 [PMID: 9537325 DOI: 10.1038/32918]
 - 9 **Hansford S, Kaurah P, Li-Chang H, Woo M, Senz J, Pinheiro H, Schrader KA, Schaeffer DF, Shumansky K, Zogopoulos G, Santos TA, Claro I, Carvalho J, Nielsen C, Padilla S, Lum A, Talhouk A, Baker-Lange K, Richardson S, Lewis I, Lindor NM, Pennell E, MacMillan A, Fernandez B, Keller G, Lynch H, Shah SP, Guilford P, Gallinger S, Corso G, Roviello F, Caldas C, Oliveira C, Pharoah PD, Huntsman DG.** Hereditary Diffuse Gastric Cancer Syndrome: CDH1 Mutations and Beyond. *JAMA Oncol* 2015; **1**: 23-32 [PMID: 26182300 DOI: 10.1001/jamaoncol.2014.168]
 - 10 **Gaston D, Hansford S, Oliveira C, Nightingale M, Pinheiro H, Macgillivray C, Kaurah P, Rideout AL, Steele P, Soares G, Huang WY, Whitehouse S, Blowers S, LeBlanc MA, Jiang H, Greer W, Samuels ME, Orr A, Fernandez CV, Majewski J, Ludman M, Dyack S, Penney LS, McMaster CR, Huntsman D, Bedard K.** Germline mutations in MAP3K6 are associated with familial gastric cancer. *PLoS Genet* 2014; **10**: e1004669 [PMID: 25340522 DOI: 10.1371/journal.pgen.1004669]
 - 11 **Mi EZ, Mi EZ, di Pietro M, O'Donovan M, Hardwick RH, Richardson S, Ziauddeen H, Fletcher PC, Caldas C, Tischkowitz M, Ragunath K, Fitzgerald RC.** Comparative study of endoscopic surveillance in hereditary diffuse gastric cancer according to CDH1 mutation status. *Gastrointest Endosc* 2018; **87**: 408-418 [PMID: 28688938 DOI: 10.1016/j.gie.2017.06.028]
 - 12 **Sugimoto S, Komatsu H, Morohoshi Y, Kanai T.** Recognition of and recent issues in hereditary diffuse gastric cancer. *J Gastroenterol* 2015; **50**: 831-843 [PMID: 26049741 DOI: 10.1007/s00535-015-1093-9]
 - 13 **Weren RDA, van der Post RS, Vogelaa IP, van Krieken JH, Spruijt L, Lubinski J, Jakubowska A, Teodorczyk U, Aalfs CM, van Hest LP, Oliveira C, Kamping EJ, Schackert HK, Ranzani GN, Gómez García EB, Hes FJ, Holinski-Feder E, Genuardi M, Ausems MGEM, Sijmons RH, Wagner A, van der Kolk LE, Cats A, Bjørnevoll I, Hoogerbrugge N, Ligtenberg MJL.** Role of germline aberrations affecting CTNNA1, MAP3K6 and MYD88 in gastric cancer susceptibility. *J Med Genet* 2018; **55**: 669-674 [PMID: 29330337 DOI: 10.1136/jmedgenet-2017-104962]
 - 14 **Gullo I, Devezas V, Baptista M, Garrido L, Castedo S, Morais R, Wen X, Rios E, Pinheiro J, Pinto-Ribeiro I, Ferreira RM, Preto J, Santos-Antunes J, Marques M, Campos M, Almeida F, Espinheira MDC, Amil Dias J, Figueiredo C, Oliveira C, Trindade E, Carneiro F.** Phenotypic heterogeneity of hereditary diffuse gastric cancer: Report of a family with early-onset disease. *Gastrointest Endosc* 2018; **87**: 1566-1575 [PMID: 29454568 DOI: 10.1016/j.gie.2018.02.008]
 - 15 **Huntsman DG, Carneiro F, Lewis FR, MacLeod PM, Hayashi A, Monaghan KG, Maung R, Seruca R, Jackson CE, Caldas C.** Early gastric cancer in young, asymptomatic carriers of germ-line E-cadherin mutations. *N Engl J Med* 2001; **344**: 1904-1909 [PMID: 11419427 DOI: 10.1056/NEJM200106213442504]
 - 16 **Huynh JM, Laukaitis CM.** Panel testing reveals nonsense and missense CDH1 mutations in families without hereditary diffuse gastric cancer. *Mol Genet Genomic Med* 2016; **4**: 232-236 [PMID: 27064202 DOI: 10.1002/mgg3.197]
 - 17 **Syngal S, Brand RE, Church JM, Giardiello FM, Hampel HL, Burt RW;** American College of Gastroenterology. ACG clinical guideline: Genetic testing and management of hereditary gastrointestinal cancer syndromes. *Am J Gastroenterol* 2015; **110**: 223-62; quiz 263 [PMID: 25645574 DOI: 10.1038/ajg.2014.435]
 - 18 **van der Post RS, van Dieren J, Grelack A, Hoogerbrugge N, van der Kolk LE, Snaebjornsson P, Lansdorp-Vogelaar I, van Krieken JH, Bisseling TM, Cats A.** Outcomes of screening gastroscopy in first-degree relatives of patients fulfilling hereditary diffuse gastric cancer criteria. *Gastrointest Endosc* 2018; **87**: 397-404.e2 [PMID: 28455161 DOI: 10.1016/j.gie.2017.04.016]
 - 19 **Hallowell N, Badger S, Richardson S, Caldas C, Hardwick RH, Fitzgerald RC, Lawton J.** An investigation of the factors effecting high-risk individuals' decision-making about prophylactic total gastrectomy and surveillance for hereditary diffuse gastric cancer (HDGC). *Fam Cancer* 2016; **15**: 665-676 [PMID: 27256430 DOI: 10.1007/s10689-016-9910-8]
 - 20 **Hallowell N, Lawton J, Badger S, Richardson S, Hardwick RH, Caldas C, Fitzgerald RC.** The Psychosocial Impact of Undergoing Prophylactic Total Gastrectomy (PTG) to Manage the Risk of Hereditary Diffuse Gastric Cancer (HDGC). *J Genet Couns* 2017; **26**: 752-762 [PMID: 27837291 DOI: 10.1007/s10897-016-0045-8]
 - 21 **Moslim MA, Heald B, Tu C, Burke CA, Walsh RM.** Early genetic counseling and detection of CDH1 mutation in asymptomatic carriers improves survival in hereditary diffuse gastric cancer. *Surgery* 2018; **164**: 754-759 [PMID: 30145018 DOI: 10.1016/j.surg.2018.05.059]
 - 22 **Worster E, Liu X, Richardson S, Hardwick RH, Dwerryhouse S, Caldas C, Fitzgerald RC.** The impact of prophylactic total gastrectomy on health-related quality of life: A prospective cohort study. *Ann Surg* 2014; **260**: 87-93 [PMID: 24424140 DOI: 10.1097/SLA.0000000000000446]
 - 23 **Fitzgerald RC, Hardwick R, Huntsman D, Carneiro F, Guilford P, Blair V, Chung DC, Norton J,**

- Ragunath K, Van Krieken JH, Dwerryhouse S, Caldas C; International Gastric Cancer Linkage Consortium. Hereditary diffuse gastric cancer: Updated consensus guidelines for clinical management and directions for future research. *J Med Genet* 2010; **47**: 436-444 [PMID: 20591882 DOI: 10.1136/jmg.2009.074237]
- 24 **Vogiatzi P**, Cassone M, Luzzi I, Lucchetti C, Otvos L, Giordano A. Helicobacter pylori as a class I carcinogen: Physiopathology and management strategies. *J Cell Biochem* 2007; **102**: 264-273 [PMID: 17486575 DOI: 10.1002/jcb.21375]
- 25 **Lim YC**, di Pietro M, O'Donovan M, Richardson S, Debiram I, Dwerryhouse S, Hardwick RH, Tischkowitz M, Caldas C, Ragunath K, Fitzgerald RC. Prospective cohort study assessing outcomes of patients from families fulfilling criteria for hereditary diffuse gastric cancer undergoing endoscopic surveillance. *Gastrointest Endosc* 2014; **80**: 78-87 [PMID: 24472763 DOI: 10.1016/j.gie.2013.11.040]
- 26 **Carneiro F**, Huntsman DG, Smyrk TC, Owen DA, Seruca R, Pharoah P, Caldas C, Sobrinho-Simões M. Model of the early development of diffuse gastric cancer in E-cadherin mutation carriers and its implications for patient screening. *J Pathol* 2004; **203**: 681-687 [PMID: 15141383 DOI: 10.1002/path.1564]
- 27 **Charlton A**, Blair V, Shaw D, Parry S, Guilford P, Martin IG. Hereditary diffuse gastric cancer: Predominance of multiple foci of signet ring cell carcinoma in distal stomach and transitional zone. *Gut* 2004; **53**: 814-820 [PMID: 15138207 DOI: 10.1016/S0016-5085(03)84094-5]
- 28 **Fujita H**, Lennerz JK, Chung DC, Patel D, Deshpande V, Yoon SS, Lauwers GY. Endoscopic surveillance of patients with hereditary diffuse gastric cancer: Biopsy recommendations after topographic distribution of cancer foci in a series of 10 CDH1-mutated gastrectomies. *Am J Surg Pathol* 2012; **36**: 1709-1717 [PMID: 23073328 DOI: 10.1097/PAS.0b013e31826ca204]
- 29 **Rogers WM**, Dobo E, Norton JA, Van Dam J, Jeffrey RB, Huntsman DG, Kingham K, Chun N, Ford JM, Longacre TA. Risk-reducing total gastrectomy for germline mutations in E-cadherin (CDH1): Pathologic findings with clinical implications. *Am J Surg Pathol* 2008; **32**: 799-809 [PMID: 18391748 DOI: 10.1097/PAS.0b013e31815e7f1a]
- 30 **Barber ME**, Save V, Carneiro F, Dwerryhouse S, Lao-Sirieix P, Hardwick RH, Caldas C, Fitzgerald RC. Histopathological and molecular analysis of gastrectomy specimens from hereditary diffuse gastric cancer patients has implications for endoscopic surveillance of individuals at risk. *J Pathol* 2008; **216**: 286-294 [PMID: 18825658 DOI: 10.1002/path.2415]
- 31 **Guilford P**, Humar B, Blair V. Hereditary diffuse gastric cancer: Translation of CDH1 germline mutations into clinical practice. *Gastric Cancer* 2010; **13**: 1-10 [PMID: 20373070 DOI: 10.1007/s10120-009-0531-x]
- 32 **Luo W**, Fedda F, Lynch P, Tan D. CDH1 Gene and Hereditary Diffuse Gastric Cancer Syndrome: Molecular and Histological Alterations and Implications for Diagnosis And Treatment. *Front Pharmacol* 2018; **9**: 1421 [PMID: 30568591 DOI: 10.3389/fphar.2018.01421]
- 33 **Tan RY**, Ngeow J. Hereditary diffuse gastric cancer: What the clinician should know. *World J Gastrointest Oncol* 2015; **7**: 153-160 [PMID: 26380059 DOI: 10.4251/wjgo.v7.i9.153]
- 34 **Kumar S**, Katona BW, Long JM, Domchek S, Rustgi AK, Roses R, Ginsberg GG. Endoscopic Ultrasound Has Limited Utility in Diagnosis of Gastric Cancer in Carriers of CDH1 Mutations. *Clin Gastroenterol Hepatol* 2019 [PMID: 31077828 DOI: 10.1016/j.cgh.2019.04.064]
- 35 **Brandão C**, Dinis-Ribeiro M. Early diagnosis of hereditary diffuse gastric cancer: (Not only) an endoscopic challenge! *Endosc Int Open* 2016; **4**: E1311-E1312 [PMID: 27995194 DOI: 10.1055/s-0042-121003]
- 36 **Templeton A**, Hwang JH. Confocal microscopy in the esophagus and stomach. *Clin Endosc* 2013; **46**: 445-449 [PMID: 24143300 DOI: 10.5946/ce.2013.46.5.445]
- 37 **Lo W**, Zhu B, Sabesan A, Wu HH, Powers A, Sorber RA, Ravichandran S, Chen I, McDuffie LA, Quadri HS, Beane JD, Calzone K, Miettinen MM, Hewitt SM, Koh C, Heller T, Wacholder S, Rudloff U. Associations of CDH1 germline variant location and cancer phenotype in families with hereditary diffuse gastric cancer (HDGC). *J Med Genet* 2019; pii: jmedgenet-2018-105361 [PMID: 30745422 DOI: 10.1136/jmedgenet-2018-105361]
- 38 **Stoffel EM**, Koeppe E, Hanson K, Osborne J, Jacobs M, Appelman HD, Wong S. Sa1765 Incidental Finding of Germline CDH1 Mutations: Implications for Clinical Management. *Gastroenterology* 2016; **150**: S360 [DOI: 10.1016/S0016-5085(16)31265-3]
- 39 **Mai PL**, Garceau AO, Graubard BI, Dunn M, McNeel TS, Gonsalves L, Gail MH, Greene MH, Willis GB, Wideroff L. Confirmation of family cancer history reported in a population-based survey. *J Natl Cancer Inst* 2011; **103**: 788-797 [PMID: 21562245 DOI: 10.1093/jnci/djr114]
- 40 **Murff HJ**, Spigel DR, Syngal S. Does this patient have a family history of cancer? An evidence-based analysis of the accuracy of family cancer history. *JAMA* 2004; **292**: 1480-1489 [PMID: 15383520 DOI: 10.1001/jama.292.12.1480]
- 41 **Fiedlerling J**, Shams AZ, Haug U. Validity of self-reported family history of cancer: A systematic literature review on selected cancers. *Int J Cancer* 2016; **139**: 1449-1460 [PMID: 27222437 DOI: 10.1002/ijc.30203]
- 42 **Benusiglio PR**, Malka D, Rouleau E, De Pauw A, Buecher B, Noguès C, Fourme E, Colas C, Coulet F, Warcoin M, Grandjouan S, Sezeur A, Laurent-Puig P, Molière D, Tlemsani C, Di Maria M, Byrde V, Delaloue S, Blayau M, Caron O. CDH1 germline mutations and the hereditary diffuse gastric and lobular breast cancer syndrome: A multicentre study. *J Med Genet* 2013; **50**: 486-489 [PMID: 23709761 DOI: 10.1136/jmedgenet-2012-101472]
- 43 **Masciari S**, Larsson N, Senz J, Boyd N, Kaurah P, Kandel MJ, Harris LN, Pinheiro HC, Troussard A, Miron P, Tung N, Oliveira C, Collins L, Schnitt S, Garber JE, Huntsman D. Germline E-cadherin mutations in familial lobular breast cancer. *J Med Genet* 2007; **44**: 726-731 [PMID: 17660459 DOI: 10.1136/jmg.2007.051268]
- 44 **Schrader KA**, Masciari S, Boyd N, Salamanca C, Senz J, Saunders DN, Yorida E, Maines-Bandiera S, Kaurah P, Tung N, Robson ME, Ryan PD, Olopade OI, Domchek SM, Ford J, Isaacs C, Brown P, Balmana J, Razzak AR, Miron P, Coffey K, Terry MB, John EM, Andrusis IL, Knight JA, O'Malley FP, Daly M, Bender P, kConFab, Moore R, Southey MC, Hopper JL, Garber JE, Huntsman DG. Germline mutations in CDH1 are infrequent in women with early-onset or familial lobular breast cancers. *J Med Genet* 2011; **48**: 64-68 [PMID: 20921021 DOI: 10.1136/jmg.2010.079814]
- 45 **Xie ZM**, Li LS, Laquet C, Penault-Llorca F, Uhrhammer N, Xie XM, Bignon YJ. Germline mutations of the E-cadherin gene in families with inherited invasive lobular breast carcinoma but no diffuse gastric cancer. *Cancer* 2011; **117**: 3112-3117 [PMID: 21271559 DOI: 10.1002/ncr.25876]
- 46 **Petridis C**, Shinomiya I, Kohut K, Gorman P, Caneppele M, Shah V, Troy M, Pinder SE, Hanby A,

- Tomlinson I, Trembath RC, Roylance R, Simpson MA, Sawyer EJ. Germline CDH1 mutations in bilateral lobular carcinoma in situ. *Br J Cancer* 2014; **110**: 1053-1057 [PMID: 24366306 DOI: 10.1038/bjc.2013.792]
- 47 **Corso G**, Intra M, Trentin C, Veronesi P, Galimberti V. CDH1 germline mutations and hereditary lobular breast cancer. *Fam Cancer* 2016; **15**: 215-219 [PMID: 26759166 DOI: 10.1007/s10689-016-9869-5]



Published By Baishideng Publishing Group Inc
7041 Koll Center Parkway, Suite 160, Pleasanton, CA 94566, USA
Telephone: +1-925-2238242
Fax: +1-925-2238243
E-mail: bpgoffice@wjgnet.com
Help Desk: <http://www.f6publishing.com/helpdesk>
<http://www.wjgnet.com>

