

# Chronic Urticaria Associated with *Helicobacter pylori*

Rajesh Essrani <sup>1</sup>, Matthew Sullivan <sup>2</sup>, Hiral Shah <sup>2</sup>

1. Internal Medicine, Lehigh Valley Health Network, Allentown, USA 2. Gastroenterology, Lehigh Valley Health Network, Allentown, USA

✉ **Corresponding author:** Rajesh Essrani, raj1\_essrani@hotmail.com

Disclosures can be found in Additional Information at the end of the article

---

---

## Abstract

A 31-year-old male presented with a complaint of chronic pruritus with diffuse urticarial wheals for the past seven months. He underwent extensive workup and was found to have positive *Helicobacter pylori* (*H. pylori*) stool antigen test. He was treated with bismuth subsalicylate, metronidazole, tetracycline, and omeprazole for two weeks. Pruritus and urticarial wheals disappeared in four weeks after therapy was started.

---

**Categories:** Internal Medicine, Medical Education, Gastroenterology

**Keywords:** tetracycline, chronic urticaria, bismuth subsalicylate, *helicobacter pylori*, metronidazole, omeprazole

## Introduction

Urticaria is a common skin disease characterized by widespread and transient wheals. It is classified as acute or chronic. Acute urticaria is defined as periodic outbreaks of urticarial lesions that resolve within six weeks, and chronic urticaria (CU) persists greater than six weeks [1]. The causes of CU are numerous; however, in at least 80%-90% of the patients, the etiology is undetermined [2-3]. The infection by *Helicobacter pylori* (*H. pylori*) has been the subject of investigation as a possible etiologic factor for CU in the last few years. *H. pylori* infection plays a role in the development of peptic ulcer disease, chronic active gastritis, and low-grade gastric mucosa-associated lymphoid tissue lymphoma and gastric malignancy [4-5]. We present an unusual case of CU in an adult patient with *H. pylori* infection and regression of chronic urticarial illness after treatment of *H. pylori* with bismuth-based quadruple therapy.

## Case Presentation

A 31-year-old male with a past medical history of mild intermittent asthma presented with a seven-month history of chronic pruritus with diffuse urticarial wheals (Figure 1).

**Received** 04/13/2019

**Review began** 04/17/2019

**Review ended** 04/19/2019

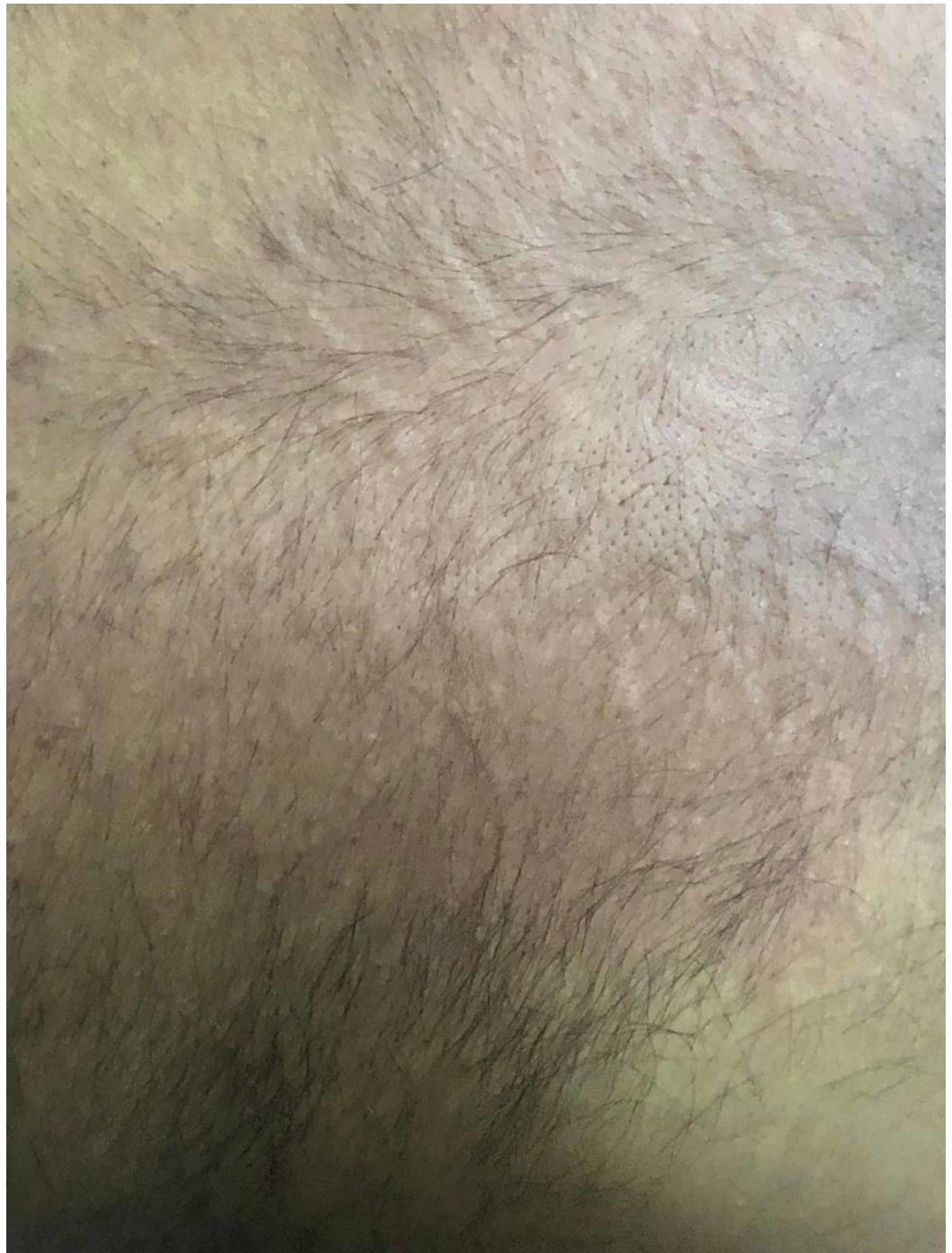
**Published** 04/23/2019

© Copyright 2019

Essrani et al. This is an open access article distributed under the terms of the Creative Commons Attribution License CC-BY 3.0., which permits unrestricted use, distribution, and reproduction in any medium, provided the original author and source are credited.

### How to cite this article

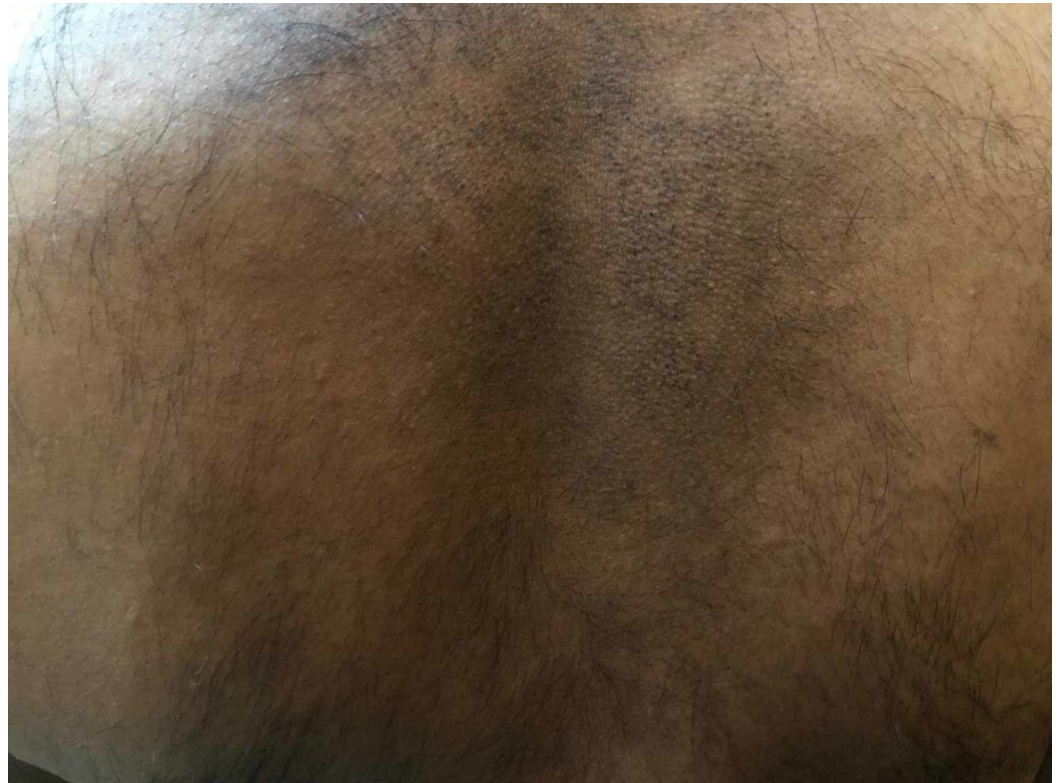
Essrani R, Sullivan M, Shah H (April 23, 2019) Chronic Urticaria Associated with *Helicobacter pylori*. Cureus 11(4): e4528. DOI 10.7759/cureus.4528



**FIGURE 1: Urticarial wheals on the back**

Allergy history for food, environment, and drugs was unremarkable. He underwent an extensive workup including complete blood count, basic metabolic panel, human immunodeficiency virus (HIV) testing, thyroid stimulating hormone, thyroid peroxidase antibodies, comprehensive stool panel, serum immunoglobulin E (IgE) level, and chest X-ray; all were unrevealing. He was initially treated empirically with cetirizine 5 mg daily without significant improvement. The cetirizine dose was subsequently increased to 10 mg with only minimal improvement. Ranitidine 150 mg twice daily was added but without much relief. A few weeks later, he complained of new onset of epigastric pain and was subsequently tested for *H. pylori* by stool antigen which resulted as positive. He was treated with bismuth subsalicylate, metronidazole, tetracycline, and omeprazole for two weeks. Pruritus and urticarial wheals disappeared four

weeks after therapy was started (Figure 2).



**FIGURE 2: Disappearance of urticarial wheals after treatment**

Repeat stool *H. pylori* was performed eight weeks after completing antibiotics and off omeprazole and confirmed eradication. The patient has had no recurrence of urticaria following treatment.

## Discussion

CU is defined by the presence of urticaria, angioedema, or both for six weeks or longer. The clinical manifestations of CU are typically limited to the skin, but sometimes systemic symptoms are seen [6-7]. CU is associated with various autoimmune disorders such as thyroid disorders, celiac disease, Sjogren syndrome, systemic lupus erythematosus, and type 1 diabetes mellitus. First line treatment of CU is the H1 anti-histamines, and as the second line, corticosteroids, leukotriene antagonists, H2 anti-histamines, immunosuppressants, monoclonal antibodies, and intravenous human immunoglobulin [8-9].

*H. pylori* lives in the stomach and is a leading cause of peptic ulcer disease. *H. pylori* has also been linked to a variety of conditions which can affect the skin such as CU, rosacea, psoriasis, Henoch-Schönlein purpura, Sjögren syndrome, systemic sclerosis, generalized pruritus (itch), atopic dermatitis, and aphthous ulceration [10-11].

Multiple studies have shown an association between CU and *H. pylori* infection. It is thought that *H. pylori* increases the permeability of the stomach lining, therefore, increasing the exposure to allergens in the gastrointestinal tract. Also, the immune response to *H. pylori* yields antibodies that may stimulate the release of histamine in the skin [12]. IgE-containing cells in the gastrointestinal tract seem to be the culprit, but there is limited proof for *H. pylori*-specific IgE. Thus, the likelihood that patients with urticaria develop specific IgE against *H. pylori* is an

appealing pathogenic explanation that likely has not been confirmed yet [10].

Shakouru et al. [13] evaluated 19 studies, 17 observational, and two double-blinded, randomized, controlled clinical trials, and observed that 10 of these studies showed a beneficial impact of *H. pylori* eradication in the resolution of the symptoms of CU.

Endoscopic and non-endoscopic methods can establish the diagnosis of *H. pylori* infection. The non-endoscopic, less invasive techniques, include serologic testing, labeled urea breath test, and the monoclonal antibody-based *H. pylori* stool antigen test. The endoscopic tests, performed on gastric biopsy specimens obtained during upper endoscopy, are the rapid urease test, histopathology, and culture [14].

Choosing the initial regimen to treat *H. pylori* should be guided by the presence of risk factors for regional antibiotic resistance patterns and eradication rates. *H. pylori* should be treated for 14 days. Risk factors for macrolide resistance include prior exposure to macrolide therapy for any reason and high local clarithromycin resistance rates ( $\geq 15\%$ ) or eradication rates with clarithromycin-based triple treatment  $\leq 85\%$ . Initial treatment options include quadruple bismuth therapy containing proton pump inhibitor (PPI), bismuth, metronidazole, and tetracycline (PBMT), and concomitant non-bismuth quadruple treatment comprising PPI, amoxicillin, metronidazole, and clarithromycin (PAMC). Patients without risk factors for macrolide resistance should be treated with triple therapy containing clarithromycin, amoxicillin, and PPI (CAP) [15-17]. Amoxicillin can be substituted with metronidazole only in penicillin-allergic individuals [16-18]. Levofloxacin-based triple therapy containing levofloxacin, amoxicillin and PPI (LAP) and sequential non-bismuth quadruple therapy (PPI, amoxicillin followed by PPI, metronidazole, and clarithromycin) shouldn't be used for first-line treatment [16].

Approximately 20% of patients fail an initial attempt at *H. pylori* eradication. In patients with persistent *H. pylori* infection, antibiotic therapy should be guided by the patient's initial treatment regimen, the use of other antibiotics, and the presence of relevant antibiotic allergies. Antibiotics included in the initial regimen should generally be avoided when prescribing a subsequent regimen. PBMT and LAP can be used in patients with no previous metronidazole exposure. If levofloxacin therapy fails, then PBMT is the next option even if previously exposed to metronidazole. The use of rifabutin-containing regimens (rifabutin, PPI, amoxicillin) should be used in patients who have failed to respond to at least three prior options. There is insufficient data to support non-bismuth quadruple therapy and PAMC for rescue therapy.

Eradication should be confirmed in all patients treated for *H. pylori* because of increasing antibiotic resistance [15,18]. Confirmation of elimination can be established with a urea breath test, stool antigen testing, or endoscopy-based testing. Tests to confirm eradication should be performed at least four weeks after completion of antibiotic treatment [15]. PPIs should be held for one to two weeks before testing to reduce false-negative results. Serologic testing should not be performed to confirm eradication as patients may continue to have circulating antibodies even after eradication.

## Conclusions

CU and dyspepsia are associated with *H. pylori* and its presence can be tested for by using an affordable, noninvasive, sensitive and specific test such as *H. pylori* stool antigen. *H. pylori* should be treated for 14 days with appropriate therapy and eradication should be confirmed. The case demonstrates that *H. pylori* should be included in the diagnostic workup of chronic urticaria, especially in patients without response to habitual treatment for chronic urticaria or those with concurrent gastrointestinal symptoms.

## Appendices

This article has been published as a poster and can be found on the following website - <https://www.eventscribe.com/2018/ACG/ajaxcalls/PosterInfo.asp?efp=RFNSWFFHSFY2NDIO&PosterID=160190>

## Additional Information

### Disclosures

**Human subjects:** Consent was obtained by all participants in this study. **Conflicts of interest:** In compliance with the ICMJE uniform disclosure form, all authors declare the following:

**Payment/services info:** All authors have declared that no financial support was received from any organization for the submitted work. **Financial relationships:** All authors have declared that they have no financial relationships at present or within the previous three years with any organizations that might have an interest in the submitted work. **Other relationships:** All authors have declared that there are no other relationships or activities that could appear to have influenced the submitted work.

## References

- Kilic G, Guler N, Suleyman A, Tamay Z: Chronic urticaria and autoimmunity in children . *Pediatr Allergy Immunol*. 2010, 21:837-842. [10.1111/j.1399-3038.2010.00986.x](https://doi.org/10.1111/j.1399-3038.2010.00986.x)
- Zuberbier T, Asero R, Bindslev-Jensen C, et al.: EAACI/GA2LEN/EDF/WAO guideline: definition, classification and diagnosis of urticaria. *Allergy*. 2009, 64:1417-1426. [10.1111/j.1398-9995.2009.02179.x](https://doi.org/10.1111/j.1398-9995.2009.02179.x)
- Nichols KM, Cook-Bolden FE: Allergic skin disease: major highlights and recent advances . *Med Clin North Am*. 2009, 93:1211-1224. [10.1016/j.mcna.2009.08.004](https://doi.org/10.1016/j.mcna.2009.08.004)
- Konturek SJ, Konturek PC, Konturek JW, Plonka M, Czesnikiewicz-Guzik M, Brzozowski T, Bielanski W: Helicobacter pylori and its involvement in gastritis and peptic ulcer formation . *J Physiol Pharmacol*. 2006, 57:29-50.
- Konturek PC, Konturek SJ, Brzozowski T: Gastric cancer and Helicobacter pylori infection . *J Physiol Pharmacol*. 2006, 57:51-65.
- Doong JC, Chichester K, Oliver ET, Schwartz LB, Saini SS: Chronic idiopathic urticaria: systemic complaints and their relationship with disease and immune measures. *J Allergy Clin Immunol Pract*. 2017, 5:1314-1318. [10.1016/j.jaip.2016.11.037](https://doi.org/10.1016/j.jaip.2016.11.037)
- Sabroe RA, Seed PT, Francis DM, Barr RM, Black AK, Greaves MW: Chronic idiopathic urticaria: comparison of the clinical features of patients with and without anti-FcεRI or anti-IgE autoantibodies. *J Am Acad Dermatol*. 1999, 40:443-450.
- Kanani A, Schellenberg R, Warrington R: Urticaria and angioedema. *Allergy Asthma Clin Immunol*. 2011, 7:S9. [10.1186/1710-1492-7-S1-S9](https://doi.org/10.1186/1710-1492-7-S1-S9)
- Powell RJ, Du Toit GL, Siddique N, et al.: BSACI guidelines for the management of chronic urticaria and angio-oedema. *Clin Exp Allergy*. 2007, 37:631-650. [10.1111/j.1365-2222.2007.02678.x](https://doi.org/10.1111/j.1365-2222.2007.02678.x)
- Hernando-Harder AC, Booken N, Goerdts S, Singer MV, Harder H: Helicobacter pylori infection and dermatologic diseases. *Eur J Dermatol*. 2009, 19:431-444. [10.1684/ejd.2009.0739](https://doi.org/10.1684/ejd.2009.0739)
- Wedi B, Kapp A: Helicobacter pylori infection in skin diseases: a critical appraisal . *Am J Clin Dermatol*. 2002, 3:273-282. [10.2165/00128071-200203040-00005](https://doi.org/10.2165/00128071-200203040-00005)
- Buhner S, Reese I, Kuehl F, Lochs H, Zuberbier T: Pseudoallergic reactions in chronic urticaria are associated with altered gastroduodenal permeability. *Allergy*. 2004, 59:1118-1123. [10.1111/j.1398-9995.2004.00631.x](https://doi.org/10.1111/j.1398-9995.2004.00631.x)
- Shakouri A, Compalati E, Lang DM, Khan DA: Effectiveness of Helicobacter pylori eradication in chronic urticaria: evidence-based analysis using the Grading of Recommendations Assessment, Development, and Evaluation system. *Curr Opin Allergy Clin Immunol*. 2010, 10:362-369. [10.1097/ACI.0b013e32833c79d7](https://doi.org/10.1097/ACI.0b013e32833c79d7)
- McColl KE: Helicobacter pylori infection. *N Engl J Med*. 2010, 362:1597-1604. [10.1056/NEJMcp1001110](https://doi.org/10.1056/NEJMcp1001110)

15. Chey W, Leontiadis G, Howden C, Moss S: ACG Clinical Guideline: treatment of Helicobacter pylori Infection. *Am J Gastroenterol*. 2017, 112:212-239. [10.1038/ajg.2016.563](https://doi.org/10.1038/ajg.2016.563)
16. Fallone CA, Chiba N, van Zanten SV, et al.: The Toronto consensus for the treatment of Helicobacter pylori Infection in adults. *Gastroenterology*. 2016, 151:51-69. [10.1053/j.gastro.2016.04.006](https://doi.org/10.1053/j.gastro.2016.04.006)
17. Yuan Y, Ford AC, Khan KJ, et al.: Optimum duration of regimens for Helicobacter pylori eradication (Article in English, Spanish]. *Cochrane Database Syst Rev*. 2013, 008337. [10.1002/14651858.CD008337.pub2](https://doi.org/10.1002/14651858.CD008337.pub2)
18. Malfertheiner P, Megraud F, O'Morain CA, et al.: Management of Helicobacter pylori infection--the Maastricht IV/ Florence Consensus Report. *Gut*. 2012, 61:646-664. [10.1136/gutjnl-2012-302084](https://doi.org/10.1136/gutjnl-2012-302084)