

Placental Infection With *Plasmodium vivax*: A Histopathological and Molecular Study

Alfredo Mayor,¹ Azucena Bardají,¹ Ingrid Felger,² Christopher L. King,³ Pau Cisteró,¹ Carlota Dobaño,¹ Danielle I. Staniscic,^{4,5} Peter Siba,⁵ Mats Wahlgren,⁶ Hernando del Portillo,^{1,7} Ivo Mueller,^{1,4,5} Clara Menéndez,¹ Jaime Ordi,^{1,8,a} and Stephen Rogerson^{9,a}

¹Barcelona Centre for International Health Research (CRESIB, Hospital Clínic-Universitat de Barcelona), Barcelona, Spain; ²Swiss Tropical and Public Health Institute, Basel, Switzerland; ³Center for Global Health and Diseases, Case Western Reserve University, Veterans' Affairs Research Service, Cleveland, Ohio; ⁴The Walter and Eliza Hall Institute of Medical Research, Melbourne, Australia; ⁵Papua New Guinea Institute of Medical Research, Madang; ⁶Department of Microbiology, Tumor and Cell Biology, Karolinska Institutet, Stockholm, Sweden; ⁷Institució Catalana de Recerca i Estudis Avançats, Barcelona; ⁸Department of Pathology, Hospital Clínic, University of Barcelona, Spain; and ⁹Department of Medicine, University of Melbourne, Australia

Background. Evidence of the presence of *Plasmodium vivax* in the placenta is scarce and inconclusive. This information is relevant to understanding whether *P. vivax* affects placental function and how it may contribute to poor pregnancy outcomes.

Methods. Histopathologic examination of placental biopsies from 80 Papua New Guinean pregnant women was combined with quantitative polymerase chain reaction (qPCR) to confirm *P. vivax* infection and rule out coinfection with other *Plasmodium* species in placental and peripheral blood. Leukocytes and monocytes/macrophages were detected in placental sections by immunohistochemistry.

Results. Monoinfection by *P. vivax* and *Plasmodium falciparum* was detected by qPCR in 8 and 10 placentas, respectively. Seven of the 8 women with *P. vivax* placental monoinfection were negative in peripheral blood. By histology, 3 placentas with *P. vivax* monoinfection showed parasitized erythrocytes in the intervillous space but no hemozoin in macrophages nor increased intervillous inflammatory cells. In contrast, 7 placentas positive for *P. falciparum* presented parasites and hemozoin in macrophages or fibrin as well as intervillous inflammatory infiltrates.

Conclusions. *Plasmodium vivax* can be associated with placental infection. However, placental inflammation is not observed in *P. vivax* monoinfections, suggesting other causes of poor delivery outcomes associated with *P. vivax* infection.

Cytoadherence of erythrocytes infected by *Plasmodium falciparum* has been shown to contribute to microvascular sequestration and to the high case fatality rate of severe falciparum malaria [1]. In contrast, sequestration of *Plasmodium vivax* within organs has not been confirmed in the very few autopsies and tissue biopsies studied (reviewed in [2]). However,

recent reports showing adherence of *P. vivax*-infected erythrocytes (IEs) to human receptors [2–4] suggest the possibility that this parasite might also be able to sequester in specific organs and tissues.

Histological evidence of *P. vivax* sequestration from autopsies conducted at the beginning of the 1900s preceded the possibility of molecular confirmation of *P. vivax* monoinfection [5, 6]. More recently, the postmortem examination of a woman with fatal respiratory distress, and polymerase chain reaction (PCR)-confirmed *P. vivax* infection showed heavy intravascular monocytic infiltrates provoking inflammatory lesions in the endothelium of the lungs, but without sequestration of IEs in the pulmonary microvasculature [7], suggesting organ damage unrelated to sequestration of *P. vivax* parasites.

In contrast to the considerable amount of data showing accumulation of *P. falciparum* IEs in the

Received 3 April 2012; accepted 6 June 2012; electronically published 10 October 2012.

^aJ. O. and S. R. contributed equally to this work.

Correspondence: Dr Alfredo Mayor, Barcelona Centre for International Health Research (CRESIB, Hospital Clínic-Universitat de Barcelona), C/ Rosselló 132, 4th floor, Barcelona 08036, Spain (agmayor@clinic.ub.es).

The Journal of Infectious Diseases 2012;206:1904–10

© The Author 2012. Published by Oxford University Press on behalf of the Infectious Diseases Society of America. All rights reserved. For Permissions, please e-mail: journals.permissions@oup.com.

DOI: 10.1093/infdis/jis614

intervillous spaces of the placenta [8], few reports have described other *Plasmodium* species in placental smears [9–19]. However, there is a lack of studies combining histology and molecular techniques in placental and peripheral blood to distinguish histological changes by *Plasmodium* species. Recently, placental histology has demonstrated a deposition of hemozoin associated with antenatal *P. vivax* infection among Karen women from the Thai-Burmese border, although parasites were rare or absent as antenatal care relied on active detection and prompt treatment and *P. vivax* monoinfection was not confirmed by PCR [20]. In another study among pregnant women residing in an area of Iquitos, Peru, with low transmission of *P. vivax* and *P. falciparum*, hemozoin deposition was observed in 22% of the placentas analyzed [21], including a cord blood infection and placental changes associated only with *P. vivax* infection. Case reports have revealed the presence of *P. vivax* in the placenta by PCR, either alone or in combination with *P. falciparum*, but they lacked histological confirmation [22, 23]. Although *P. vivax* infection has been associated with adverse pregnancy outcomes [24], the pathophysiological mechanisms underlying these adverse effects remain to be determined.

Detailed histological and molecular studies describing whether *P. vivax* parasites accumulate in human placentas and the pathological changes associated with the infection are a priority to understand how *P. vivax* can affect placental function and cause low birth weight [24], as well as to gain insights into the general mechanisms of disease severity associated with *P. vivax* malaria. The present study was undertaken to determine if *P. vivax* can be unequivocally associated with placental infection. To address this, we combined histological examination of placental samples with highly specific PCR methods to confirm *P. vivax* infection and rule out coinfection with other *Plasmodium* species.

MATERIALS AND METHODS

Study Site and Sample Collection

Pregnant women attending antenatal care at Alexishafen Health Centre in Madang, Papua New Guinea, between September 2005 and October 2007 were recruited in the context of a longitudinal study of malaria in pregnancy, following written informed consent. The study area is characterized by year-round, high level malaria transmission. At the time of the study, the prevalence of malaria in pregnant women in Madang at first antenatal care visit was 29%–41% (with 5%–20% of these infections described as *P. vivax* by microscopy). At delivery, 7%–18% of women were positive in their peripheral blood, and 16%–24% were placental smear positive, with 4%–20% of these infections due to *P. vivax* [25]. The study was approved by the Papua New Guinea Medical Research Advisory Council and by the Papua New Guinea

Institute of Medical Research Institutional Review Board. All women participating in this study were prescribed chloroquine as a treatment dose followed by weekly prophylaxis in accordance with Papua New Guinea standard treatment guidelines; in the latter part of the study an initial dose of 3 tablets of sulfadoxine-pyrimethamine was coadministered with chloroquine treatment, as recommended by the guidelines. Seventy-five percent of women regularly used bed nets, but <10% of these nets were insecticide-treated. Peripheral blood (6 mL) was collected during labor or shortly after delivery in ethylenediaminetetraacetic acid (EDTA) vacutainers. An incision was made in a macroscopically normal area in the center of the maternal side of the placenta, and blood was collected from the intervillous space with a sterile transfer pipette into an EDTA vacutainer. From the same incision point, one placental biopsy was collected and a full-thickness biopsy about 1 cm thick and 2 cm wide was placed in 10% neutral buffered formalin. Samples collected from 80 pregnant women were included in the study.

Placental Histology

Placental samples (90–168 mm²) were processed for histological examination and stained as previously described [26]. Hematoxylin and eosin-stained slides from all placentas were read independently by 2 pathologists. The following histological findings were recorded in all cases: presence of *Plasmodium* parasites, presence of hemozoin (identified by light microscopy as a coarse, brown, granular material with birefringency under polarized light) in free macrophages, presence of hemozoin in fibrin (either in macrophages covered by fibrin or free), and intervillous inflammation. Every case with a discrepant result between both readings was subject to a third blinded histological evaluation by one of the pathologists. A 2-out-of-3 consensus evaluation was established after this third evaluation. The percentage of IEs was established after counting 500 intervillous erythrocytes.

Immunohistochemistry

Immunohistochemical studies were performed using the automated immunohistochemical system TechMate 500 TM (Dako) and the EnVision system (Dako) in formalin-fixed, paraffin-embedded tissue. The total number of leukocytes was determined following staining with anti-CD45 (Clone 2B11, Dako) and macrophages were stained with anti-CD68 (Clone KP1, Dako). In brief, paraffin sections were deparaffinized and rehydrated in xylene and graded alcohols. After blocking with peroxidase for 7.5 minutes in ChemMate peroxidase-blocking solution (Dako), the slides were incubated with the primary antibodies (CD45 and CD68) for 30 minutes and washed in ChemMate buffer solution (Dako). After application of the peroxidase-labeled polymer for 30 minutes and washing, the slides were incubated with the diaminobenzidine substrate chromogen solution, washed in water, counterstained with hematoxylin,

washed again, dehydrated, and mounted. The number of CD45- and CD68-positive cells per high-power field (HPF = ×400) was calculated after counting 10 HPFs using an Olympus BX41 microscope (total area evaluated = 17.28 mm²).

DNA Template Extraction and Amplification

After peripheral and placental blood centrifugation, DNA was extracted from 200 µL of erythrocyte pellet using the QIAmp DNA blood Mini Kit (Qiagen) and finally resuspended in 200 µL of distilled water according to the supplier's instructions. Three microliters of extracted DNA was used for real-time quantitative PCR (qPCR) following previously published methods [27] with minor modifications. For optimal detection of parasite genomic DNA, 25-µL simplex reactions were performed for *P. falciparum* and *P. vivax*. Detection of *Plasmodium malariae* and *Plasmodium ovale* was performed using a duplex qPCR assay. Primers and probes corresponded to those previously described with the exception of an improved *P. vivax* probe, which has been changed to a minor groove binder (MGB) probe (Life Technologies) with a 5' VIC reporter and a 3' MGB nonfluorescent quencher to increase specificity of *P. vivax* detection. Forty-five cycles were performed. Positive and negative controls were included in the PCR experiments. Positive controls consisted of a *P. falciparum* and *P. vivax* amplicon cloned into plasmids. A standard curve of 10-fold serial dilutions of these plasmids as well as no template controls were included in each experiment. A sample was considered positive if the cycle threshold (Ct) value was <45.

Samples positive for *Plasmodium* species detected by qPCR were confirmed by PCR ligase detection reaction fluorescent microsphere assay (PCR-LDR-FMA) using 2.5 µL of DNA extraction as described elsewhere [27].

Definitions and Statistical Analysis

A placental infection was defined as unequivocally attributed to *P. vivax* if placental blood was positive for *P. vivax* by qPCR and PCR-LDR-FMA without evidence of coinfection with *P. falciparum*, *P. ovale*, or *P. malariae* either in the placenta or in peripheral blood by qPCR. The Kruskal-Wallis test was used to compare Cts obtained from samples positive for different *Plasmodium* species and the number of CD45⁺/CD68⁺ cells in uninfected placentas with numbers in *P. vivax* or *P. falciparum* monoinfected placentas.

RESULTS

The mean age of the 80 pregnant women included into the study was 23.1 years (SD, 7.3). Twenty-seven of the women (34%) were primigravidae. In 8 of the 80 women, qPCR revealed *P. vivax* mono-infection in the placenta; 7 of these women were negative in the peripheral blood for any *Plasmodium* species, and 1 woman was positive for *P. falciparum*.

Ten of the women were positive for *P. falciparum* in the placenta, 6 of whom were also positive for *P. falciparum* in peripheral blood. Only 1 mixed infection (*P. falciparum* plus *P. vivax*) was found in placental blood (Table 1). *Plasmodium* species-positive samples by qPCR were confirmed by PCR-LDR-FMA. Median Cts obtained by qPCR from placental blood positive for *P. falciparum* (36.73 [interquartile range {IQR}, 33.49–39.40]) were lower than Cts from *P. vivax*-positive infections (42.83, [IQR, 41.09–44.53], *P* = .005). *Plasmodium ovale* and *P. malariae* were not detected by qPCR in any of the peripheral or placental blood samples tested.

On histological examination, 3 of the 8 placentas positive for *P. vivax* by qPCR showed malarial parasites in the maternal erythrocytes of the intervillous space, with parasitemias of 1%, 4%, and 25% (Figure 1A and 1B). All IEs showed mature forms of the parasite containing hemozoin, but no hemozoin was observed in free macrophages or in fibrin. One of the 8 placentas had both malaria IEs (2% parasitized erythrocytes), together with mild to moderate deposition of malarial hemozoin in perivillous fibrin (Figure 1C); this woman had a *P. falciparum* infection in peripheral blood. Among the other 4 placentas not showing any parasite by histology, 3 presented hemozoin in perivillous fibrin. Hemozoin associated with *P. vivax* infection, either in the cytoplasm of the parasite or in fibrin, showed birefringence under polarized light (Figure 1D). No hemozoin within free macrophages was identified in any of the *P. vivax*-infected placentas.

Histology of the 10 placentas that were positive by qPCR only for *P. falciparum* showed 1 biopsy with no parasites or

Table 1. Placental Histology and Quantitative Polymerase Chain Reaction (qPCR) in Peripheral Blood From Women With qPCR-Confirmed *Plasmodium* Species Infection in Intervillous Placental Blood Samples

Placental Infection (qPCR) ^a	Placental Histology	Peripheral Infection (qPCR) ^a
8 only <i>P. vivax</i>	3 parasites	Negative
	3 hemozoin in fibrin	Negative
	1 parasites + hemozoin in fibrin	<i>P. falciparum</i>
	1 negative	Negative
10 only <i>P. falciparum</i>	2 parasites	Negative
	7 parasites + hemozoin in free macrophages and fibrin	6 <i>P. falciparum</i>
	1 negative	Negative
1 <i>P. falciparum</i> + <i>P. vivax</i>	1 parasites + hemozoin in free macrophages and fibrin	Negative

^a*Plasmodium vivax* and *Plasmodium falciparum* infections detected by qPCR were confirmed by PCR ligase detection reaction fluorescent microsphere assay.

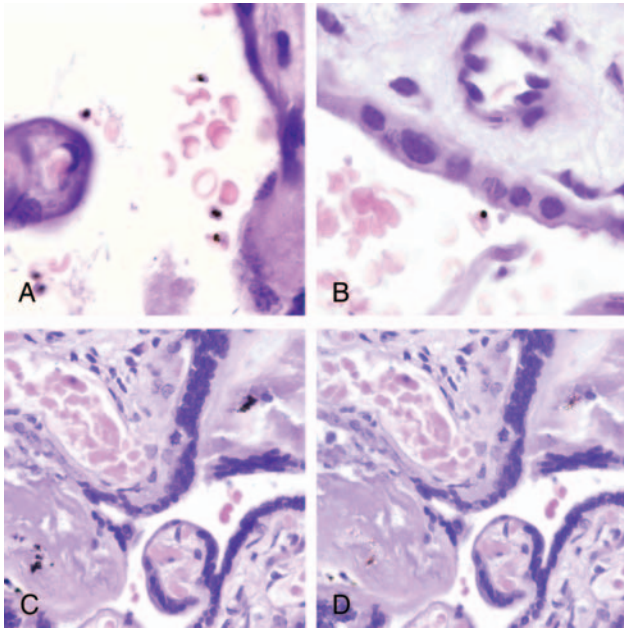


Figure 1. Histological sections of placentas with *Plasmodium vivax* mono-infections showing parasitized maternal red blood cells. All parasites identified were mature forms containing hemozoin (A and B). C, Malarial hemozoin in perivillous fibrin in a case positive for *P. vivax* by quantitative polymerase chain reaction. D, Malarial hemozoin showing birefringence under polarized light.

hemozoin; 2 with only malaria IEs; and 7 with malaria IEs and hemozoin in free macrophages and fibrin. Among those with IEs, placental parasitemias were 1% (4 placentas), 2%, 4%, 15% (1 placenta each), and 25% (2 placentas). Six of the 7 women with placental IEs and hemozoin in free macrophages and fibrin also had a *P. falciparum* peripheral infection (Table 1).

In the placenta with mixed *P. falciparum* plus *P. vivax* infection detected by qPCR, both IEs and hemozoin in macrophages and fibrin were observed by histology. No *Plasmodium* species were detected in peripheral blood of this woman (Table 1).

Histological examination did not allow discrimination between *P. vivax* and *P. falciparum* IEs (Figure 2). None of the placentas with *P. vivax* mono-infections detected by qPCR showed increased leukocytes (CD45) or macrophages (CD68) (Figure 3A and 3B) compared with uninfected placentas (Figure 4). In contrast, a significant number of *P. falciparum*-mono-infected placentas showed a moderate to marked increase in the number of total leukocytes (n = 5) and macrophages (n = 3) in the intervillous space (Figure 3C and 3D), compared with uninfected placentas (Figure 4).

DISCUSSION

The data presented constitute a detailed molecular and histological characterization of *P. vivax* infection in the placenta.

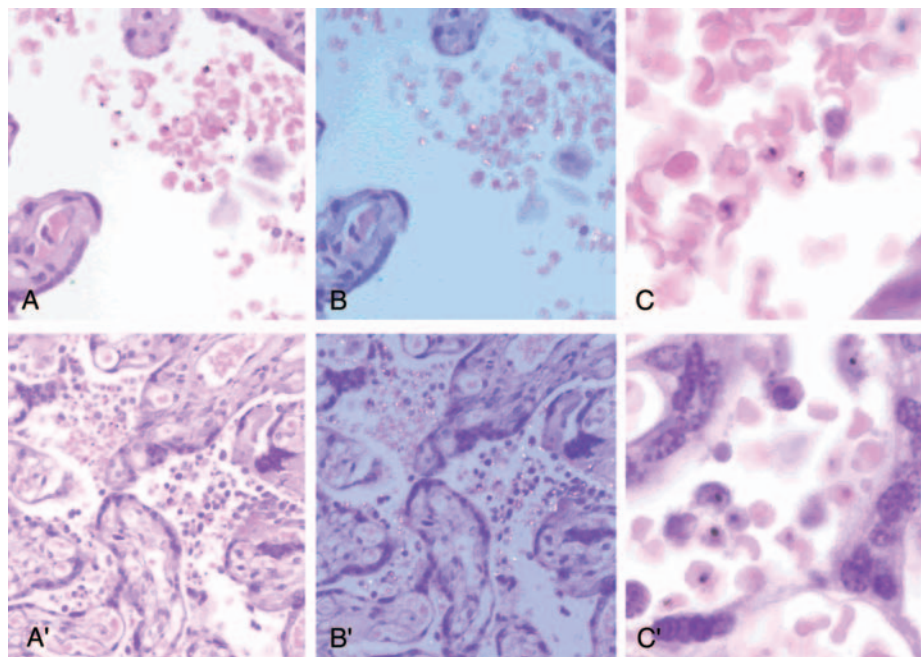


Figure 2. Comparison between *Plasmodium vivax* (A, B, and C) and *Plasmodium falciparum* (A', B', and C') parasitized placentas. A and A' show maternal infected red blood cells in the intervillous space. No inflammatory reaction was observed in *P. vivax*-infected placenta, whereas an increased number of intervillous macrophages were detected in *P. falciparum*-infected placenta. B and B' show the same fields under polarized light showing the birefringence of hemozoin present in the mature forms of the parasites. Birefringent hemozoin in free macrophages was present in the *P. falciparum*-infected placenta. C and C', Higher magnification showing the characteristics of the parasites.

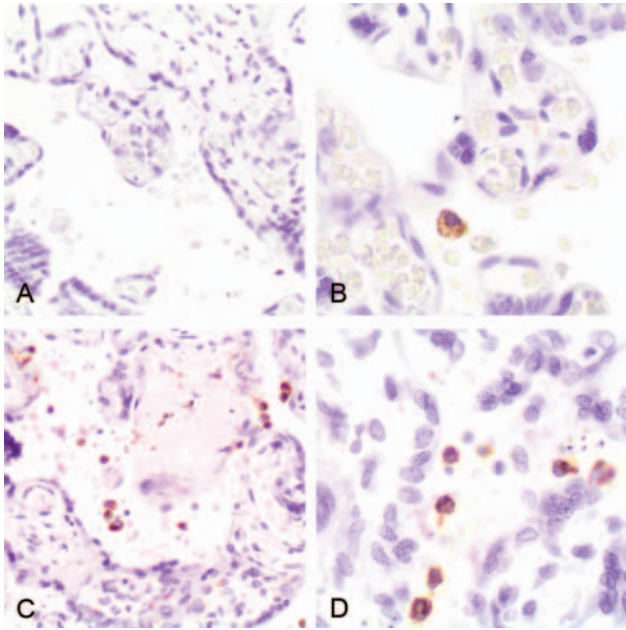


Figure 3. Immunohistochemical staining macrophages (CD68) in *Plasmodium vivax*-infected (A and B) and *Plasmodium falciparum*-infected (C and D) placentas.

Ten percent of placental blood samples (8 of 80) showed *P. vivax* monoinfection by qPCR. Histological examination of 3 of these placentas showed malaria IEs in the intervillous

space. *Plasmodium falciparum* monoinfection was detected in 12% (10 of 80) of the placental blood samples, 9 of which were associated with the presence of malaria IEs by histology. Only 1 placental sample had a mixture of both *P. falciparum* and *P. vivax*. The 3 *P. vivax* placental monoinfections confirmed by histology were not associated with a concomitant infection in peripheral blood, in contrast to 6 of the 9 women with *P. falciparum* placental monoinfections who also presented a qPCR-confirmed *P. falciparum* infection in peripheral blood. Absence of *P. vivax* peripheral infection in women with *P. vivax* placental monoinfection may be explained by low *P. vivax* peripheral densities below or fluctuating around the detection limit of qPCR. Alternatively, the absence of parasites in peripheral blood may suggest that *P. vivax* can persist in the placenta even after parasite clearance in the circulation and that *P. vivax* might be able to selectively sequester in the placenta.

Three of the 8 placentas with qPCR-confirmed *P. vivax* monoinfections showed hemozoin in fibrin but no parasites in the histological examination. Although the presence of DNA in hemozoin complexes [28] may explain these cases positive by PCR but negative by histology, it is not possible to know with certainty whether the hemozoin corresponds to recent *P. vivax* infection or a past *P. falciparum* infection. In this study, parasites and hemozoin deposition in free macrophages and fibrin were detected by histology in 7 of the 9 (78%) women with qPCR-confirmed *P. falciparum* placental

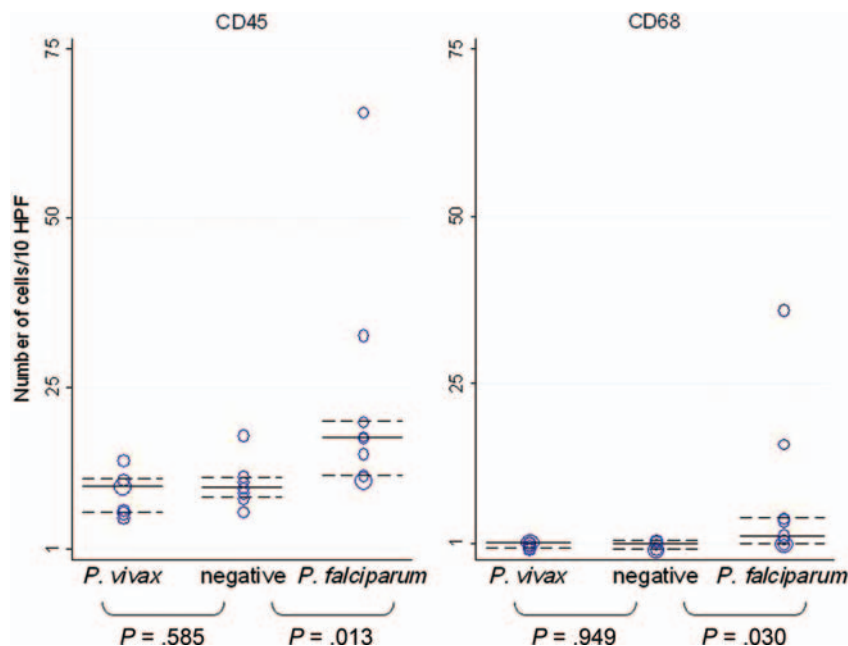


Figure 4. Number of CD45⁺ (leukocytes) and CD68⁺ (macrophages) cells after examination of 10 high-power fields (HPF; ×400) in placentas with *Plasmodium vivax* and *Plasmodium falciparum* monoinfection and uninfected placentas. Median cell counts and interquartile ranges are indicated by horizontal continuous and dashed lines.

infection, but only in 1 of the 4 women with qPCR-confirmed *P. vivax* placental infection. However, the fact that this latter woman was also infected by *P. falciparum* in the peripheral blood means it is not possible to conclude whether the hemozoin resulted from the *P. vivax* or *P. falciparum* infection. Although a previous report showed moderate placental deposition of hemozoin in Karen women with antenatal *P. vivax* infections [20], that study could only confirm by histology the presence of malaria IEs in 1 placenta, probably as a result of the active detection and treatment of women included in that study [20].

The absence of hemozoin deposition and accumulation of inflammatory cells in placentas infected with *P. vivax* observed in the present study may suggest that placental *P. vivax* infections occurred during late pregnancy. Alternatively, *P. vivax* parasites may not remain in the placenta long enough to cause hemozoin deposition and trigger the accumulation of inflammatory cells. Overall, this study suggests that factors other than persistent pathological disturbances of the placenta, such as systemic alterations, may cause the reduction of birth weight associated with *P. vivax* infection [24].

There are 4 main limitations of the current study. First, the small sample size did not allow statistical comparisons of histological findings between *P. vivax*- and *P. falciparum*-infected placentas. Second, it is not possible to exclude the presence of parasites in other sections of the placenta, as only a small section was examined by histology. Third, all the analysis was done with samples at delivery, as blood was not available during pregnancy to assess the presence of *Plasmodium* infection. And fourth, *Plasmodium* parasites, particularly *P. vivax*, which reaches lower densities than *P. falciparum*, may be present at densities below the detection limit of qPCR, making their detection by histology and even qPCR challenging.

In conclusion, this study shows the presence of *P. vivax* parasites in the placenta by histology while excluding infection with other *Plasmodium* species by 2 independent and highly specific molecular methods. This demonstrates for the first time that *P. vivax*, although at a lower frequency than *P. falciparum*, can be associated with placental infection. Importantly, histological examination of placentas with *P. vivax* mono-infections and absence of *P. falciparum* in peripheral blood detected only parasites but not hemozoin in macrophages, in contrast to the observation of both parasites and hemozoin in *P. falciparum* mono-infections. Moreover, the presence of *P. vivax* in the placenta was not associated with an increase of inflammatory cell infiltrates in contrast to *P. falciparum* placental infections [20]. Even though inflammatory changes were not observed with *P. vivax* infections, the parasite or its products may have an adverse effect on placental function. Further studies are under way to establish the clinical consequences of *P. vivax* in pregnant women on pregnancy outcomes.

Notes

Acknowledgments. We express our gratitude to the pregnant women participating in this study; to the field team in Papua New Guinea, particularly to Francesca Baiwog; and to Mireia Piqueras and Laura Puyol, who helped in the management of the study.

Disclaimer. The funding sources did not have any involvement in study design, collection, analysis, and interpretation of data, writing of the report, or in the decision to submit the paper for publication.

Financial support. The research leading to these results has received funding from the European Union's Seventh Framework Programme (FP7-2007-HEALTH) under grant agreement n° 201588 and from the Malaria in Pregnancy Consortium. A. M. receives salary support from the Instituto de Salud Carlos III (CP-04/00220) and C. D. from the Ministerio de Ciencia e Innovación (RYC-2008-02631).

Potential conflicts of interest. All authors: No reported conflicts.

All authors have submitted the ICMJE Form for Disclosure of Potential Conflicts of Interest. Conflicts that the editors consider relevant to the content of the manuscript have been disclosed.

References

1. Miller LH, Baruch DI, Marsh K, Doumbo OK. The pathogenic basis of malaria. *Nature* **2002**; 415:673–9.
2. Costa FT, Lopes SC, Ferrer M, et al. On cytoadhesion of *Plasmodium vivax*: raison d'être? *Mem Inst Oswaldo Cruz* **2011**; 106(suppl 1): 79–84.
3. Carvalho BO, Lopes SC, Nogueira PA, et al. On the cytoadhesion of *Plasmodium vivax*-infected erythrocytes. *J Infect Dis* **2010**; 202: 638–47.
4. Chotivanich K, Udomsangpetch R, Suwanarusk R, et al. *Plasmodium vivax* adherence to placental glycosaminoglycans. *PLoS One* **2012**; 7: e34509.
5. Anstey NM, Russell B, Yeo TW, Price RN. The pathophysiology of vivax malaria. *Trends Parasitol* **2009**; 25:220–7.
6. Ewing J. Contribution to the pathological anatomy of malarial fever. *J Exp Med* **1902**; 6:119–80.
7. Valecha N, Pinto RG, Turner GD, et al. Histopathology of fatal respiratory distress caused by *Plasmodium vivax* malaria. *Am J Trop Med Hyg* **2009**; 81:758–62.
8. Brabin BJ, Romagosa C, Abdelgalil S, et al. The sick placenta—the role of malaria. *Placenta* **2004**; 25:359–78.
9. Bachschmid I, Soro B, Coulibaly A, et al. Malaria infection during childbirth and in newborns in Becedi (Ivory Coast). *Bull Soc Pathol Exot* **1991**; 84:257–65.
10. Benet A, Khong TY, Ura A, et al. Placental malaria in women with South-East Asian ovalocytosis. *Am J Trop Med Hyg* **2006**; 75: 597–604.
11. Bruce-Chwatt LJ. Malaria in African infants and children in southern Nigeria. *Ann Trop Med Parasitol* **1952**; 46:173–200.
12. Garnham P. The placenta in malaria with special reference to reticulo-endothelial immunity. *Trans R Soc Trop Med Hyg* **1938**; 32:13–34.
13. Hamer DH, Singh MP, Wylie BJ, et al. Burden of malaria in pregnancy in Jharkhand State, India. *Malar J* **2009**; 8:210.
14. Jelliffe EF. Low birth-weight and malarial infection of the placenta. *Bull World Health Organ* **1968**; 38:69–78.
15. McGready R, Brockman A, Cho T, et al. Haemozoin as a marker of placental parasitization. *Trans R Soc Trop Med Hyg* **2002**; 96:644–6.
16. Paksoy N. The incidence of placental malaria in Vanuatu in the South Pacific. *Trans R Soc Trop Med Hyg* **1986**; 80:174–5.
17. Singh N, Saxena A, Awadhia SB, Shrivastava R, Singh MP. Evaluation of a rapid diagnostic test for assessing the burden of malaria at delivery in India. *Am J Trop Med Hyg* **2005**; 73:855–8.
18. Singh N, Saxena A, Shrivastava R. Placental *Plasmodium vivax* infection and congenital malaria in central India. *Ann Trop Med Parasitol* **2003**; 97:875–8.

19. Rijken MJ, Boel ME, Russell B, et al. Chloroquine resistant vivax malaria in a pregnant woman on the western border of Thailand. *Malar J* **2010**; 10:113.
20. McGready R, Davison BB, Stepniewska K, et al. The effects of *Plasmodium falciparum* and *P. vivax* infections on placental histopathology in an area of low malaria transmission. *Am J Trop Med Hyg* **2004**; 70:398–407.
21. Parekh FK, Davison BB, Gamboa D, Hernandez J, Branch OH. Placental histopathologic changes associated with subclinical malaria infection and its impact on the fetal environment. *Am J Trop Med Hyg* **2010**; 83:973–80.
22. Carvalho BO, Matsuda JS, Luz SL, et al. Gestational malaria associated to *Plasmodium vivax* and *Plasmodium falciparum* placental mixed-infection followed by foetal loss: a case report from an unstable transmission area in Brazil. *Malar J* **2011**; 10:178.
23. Newman RD, Hailemariam A, Jimma D, et al. Burden of malaria during pregnancy in areas of stable and unstable transmission in Ethiopia during a nonepidemic year. *J Infect Dis* **2003**; 187:1765–72.
24. Nosten F, McGready R, Simpson JA, et al. Effects of *Plasmodium vivax* malaria in pregnancy. *Lancet* **1999**; 354:546–9.
25. Rijken MJ, McGready R, Boel ME, et al. Malaria in pregnancy in the Asia-Pacific region. *Lancet Infect Dis* **2012**; 12:75–88.
26. Ordi J, Ismail MR, Ventura PJ, et al. Massive chronic intervillitis of the placenta associated with malaria infection. *Am J Surg Pathol* **1998**; 22:1006–11.
27. Rosanas-Urgell A, Mueller D, Betuela I, et al. Comparison of diagnostic methods for the detection and quantification of the four sympatric *Plasmodium* species in field samples from Papua New Guinea. *Malar J* **2010**; 9:361.
28. Parroche P, Lauw FN, Goutagny N, et al. Malaria hemozoin is immunologically inert but radically enhances innate responses by presenting malaria DNA to Toll-like receptor 9. *Proc Natl Acad Sci U S A* **2007**; 104:1919–24.