

Expression of the immune checkpoint receptor TIGIT in seminoma

ANDREA HINSCH¹, NICLAS C. BLESSIN¹, RONALD SIMON¹, MARTINA KLUTH¹, KRISTINE FISCHER², CLAUDIA HUBE-MAGG¹, WENCHAO LI¹, GEORGIA MAKRYPIDI-FRAUNE¹, BJÖRN WELLGE³, TIM MANDELKOW¹, NICOLAUS F. DEBATIN¹, DORIS HÖFLMAYER¹, MAXIMILIAN LENNARTZ¹, GUIDO SAUTER¹, JAKOB R. IZBICKI³, SARAH MINNER¹, FRANZISKA BÜSCHECK¹, RIA UHLIG¹, DAVID DUM¹, TILL KRECH¹, ANDREAS M. LUEBKE¹, CORINNA WITTMER¹, FRANK JACOBSEN¹, EIKE BURANDT¹, STEFAN STEURER¹ and WALDEMAR WILCZAK¹

¹Department of Pathology, University Medical Center Hamburg-Eppendorf, D-20246 Hamburg; ²ONCOdianova GmbH, D-20354 Hamburg; ³Department of General, Visceral and Thoracic Surgery, University Medical Center Hamburg-Eppendorf, D-20246 Hamburg, Germany

Received December 20, 2018; Accepted May 10, 2019

DOI: 10.3892/ol.2019.10428

Abstract. A characteristic feature of testicular seminoma is the abundance of immune cells in the tumor microenvironment, raising the possibility that immune checkpoint inhibitors may serve as a therapeutic option in these types of tumors. T cell immunoreceptor with Ig and ITIM domains (TIGIT) is an inhibitory immune checkpoint receptor in analogy to PD-1, and drugs targeting TIGIT are currently being investigated in clinical trials. Little is known about the expression of these proteins in testicular seminomas. Therefore the present study performed immunohistochemical analysis to determine the relative abundance of TIGIT and PD-1 in relation to the total CD3⁺ immune cell infiltration in a tissue microarray (TMA) constructed from 78 seminoma patients. The fraction of TIGIT⁺ and PD-1⁺ lymphocytes was highly variable in individual cancers and ranged from 2.3 to 69.4% (mean: 32.2±14.7%) for TIGIT and from 0.8 to 56.5% (mean: 21.6±13.2%) for PD-1. The same high degree of variability was also identified for the ratio of PD-1 to TIGIT positive cells, which varied from a dominance of TIGIT (PD-1: TIGIT ratio=0.02) in 74% of patients, to a predominance of PD-1 (PD-1: TIGIT ratio=12.5) in 23% of patients. In summary, the immune checkpoint receptors TIGIT and PD-1 are abundantly expressed in human seminomas. Once available, anti-TIGIT antibodies, possibly in combination with anti-PD-1 drugs, may be a reasonable therapeutic strategy for this type of cancer.

Introduction

Testicular seminoma is one of the most common solid cancer types in young men and accounts for almost half of testicular germ cell tumors (1). The vast majority of seminoma patients are cured by current therapy concepts, including orchiectomy, radiotherapy and/or platinum-based chemotherapy (2-4). However, survival is poor in these patients with platinum refractory disease relapsing after high-dose chemotherapy (5). Given the high density of immune cells typically seen in seminomas, it is intuitive, that immune checkpoint inhibitors may represent a therapeutic option in these tumors. Clinical response and non-response of advanced germ cell cancers after therapy with Nivolumab or Pembrolizumab have indeed been reported and clinical trials systematically evaluating these drugs in platinum resistant germ cell tumors are ongoing (6,7).

The clinical success of checkpoint inhibitors targeting the PD-1/PD-L1 system is stunning in many cancers (8-10), and earlier studies reported a prognostic role of PD-L1 expressing tumor infiltrating lymphocytes in seminoma samples (11,12). Moreover, there is much hope that the use of combinatorial drugs targeting not only a single, but several immune checkpoint receptors, might further improve therapeutic results. T cell immunoreceptor with Ig and ITIM domain (TIGIT), a co-inhibitory transmembrane glycoprotein of the poliovirus receptor (PVR)/nectin superfamily, is another interesting candidate for novel checkpoint therapies (13,14). In mouse models and ongoing clinical studies, blockade or ablation of TIGIT, alone or in combination with blockade of PD-1, can restore tumor suppressive effects (15-19). These findings indicate that TIGIT, similar to PD-1, has a crucial role in inhibiting the tumor-directed immune response and, thus, might be a suitable and relevant target for novel immune-modulating therapies. Several drugs targeting TIGIT are currently under development (20). TIGIT expressing lymphocytes have so far been demonstrated in acute myeloid leukemia, non-small cell lung cancer, colorectal carcinoma and melanoma (16,17,21).

Correspondence to: Dr Ronald Simon, Department of Pathology, University Medical Center Hamburg-Eppendorf, Martinistraße 52, D-20246 Hamburg, Germany
E-mail: r.simon@uke.de

Key words: T cell immunoreceptor with Ig and ITIM domains, Programmed Cell Death 1, immune checkpoint, seminoma, tissue microarray, infiltrating lymphocytes, immunotherapy

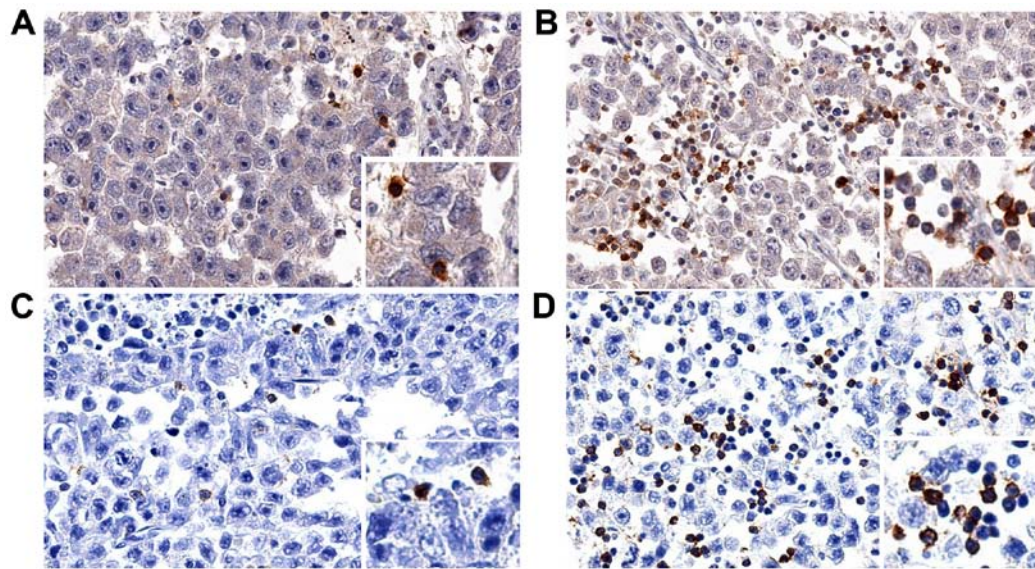


Figure 1. (A and B) TIGIT and (C and D) PD-1 staining in seminomas. Examples of cases with low-level infiltration of (A) TIGIT⁺ and (C) PD-1⁺ immune cells and cases with high level of infiltration of (B) TIGIT⁺ and (D) PD-1⁺ immune cells. TIGIT, T cell immunoreceptor with Ig and ITIM domains; PD-1, Programmed Cell Death 1.

While it appears possible that the selection of the optimal immune checkpoint inhibitor may depend on the role of the respective target in a cancer's associated immune cells, we were interested in the expression of TIGIT and PD-1 on lymphocytes in seminomas. In this study, the patterns of TIGIT and PD-1 were analyzed by immunohistochemistry in 78 seminomas in a tissue microarray (TMA) format.

Materials and methods

Patients and tissues. Formalin-fixed paraffin embedded tissue samples from 78 anonymized patients with seminoma were retrieved from the archives of the Institute of Pathology of the University Medical Center, Hamburg Eppendorf. On average, the mean age was 38±9 years and the median and mean tumor sizes were 30 mm (range:10 to 70 mm) and 33±14 mm. This patient cohort contained two 0.6 mm tumor punches per patient were assembled in a TMA. The TMA manufacturing process has been described earlier (22).

Immunohistochemistry. Three freshly cut consecutive TMA sections were immunoassayed for CD3, TIGIT and PD-1. Slides were deparaffinized and exposed to heat-induced antigen retrieval for 5 min in an autoclave at 121°C in pH 6 buffer for PD-1, pH 7.8 buffer for TIGIT and pH 9 buffer for CD3. Primary antibody specific for CD3 (rabbit polyclonal antibody, undiluted, cat. no. IR503; Dako; Agilent Technologies, Inc., Santa Clara, CA, USA), TIGIT (mouse monoclonal antibody, Dianova GmbH, Hamburg, Germany; cat. no. DIA-TG1; 1:70) and PD-1 [mouse monoclonal (NAT105) antibody, Abcam, Cambridge, UK; cat. no. ab52587; 1:50] was applied at 37°C for 60 min. Bound antibody was then visualized using the EnVision Kit (Dako; Agilent Technologies, Inc.) according to the manufacturer's directions.

Scoring of CD3, TIGIT and PD-1 immunostaining. To assure that the quantity of tissue analyzed per patient was identical,

only the first spot per patient that was interpretable for all three markers was analyzed. The total number of CD3⁺, TIGIT⁺ and PD-1⁺ cells was manually counted in each TMA slide and tissue spot. The TIGIT:CD3 and PD-1:CD3 ratio was calculated for each tissue spot to determine the fraction of TIGIT and PD-1 positive T lymphocytes.

Statistical analysis. The JMP 12.0 software package (23) (SAS Institute Inc., NC, USA) was used to calculate the mean and standard deviation of the fraction of TIGIT and PD-1 positive cells.

Results

All 78 seminomas included in this study harbored tumor infiltrating CD3⁺ T lymphocytes. Their number was variable between individual cancers and ranged from 16 to 2,113 (mean: 623, standard deviation: 509). All tumors also showed TIGIT and PD-1 staining in a variable number of immune cells. This number was overall somewhat higher for TIGIT than for PD-1: The number of TIGIT⁺ lymphocytes per 0.6 mm tissue spot ranged from 2 to 1,147 (mean: 194, standard deviation: 185), the number of PD-1⁺ lymphocytes ranged from 2 to 424 (mean: 107, standard deviation: 93). Representative images of immunostainings are shown in Fig. 1.

To compare the relative abundance of TIGIT and PD-1 expressing T cells in individual tumor samples, we used the number of CD3⁺ T cells per tissue spot as a reference. It showed that both the fraction of TIGIT⁺ T cells and of PD-1⁺ T cells was variable among the 78 seminoma patients. The fraction of TIGIT⁺ T cells (mean: 32.2±14.7%) ranged from 2.3 to 69.4% and that of PD-1 (mean: 21.6±13.2%) from 0.8 to 56.5% (Fig. 2).

In individual cancers, TIGIT expression largely but not fully paralleled that of PD-1. However, the relative importance of PD-1 and TIGIT appeared to be rather variable. TIGIT expression exceeded that of PD-1 in 58 cancers while 18

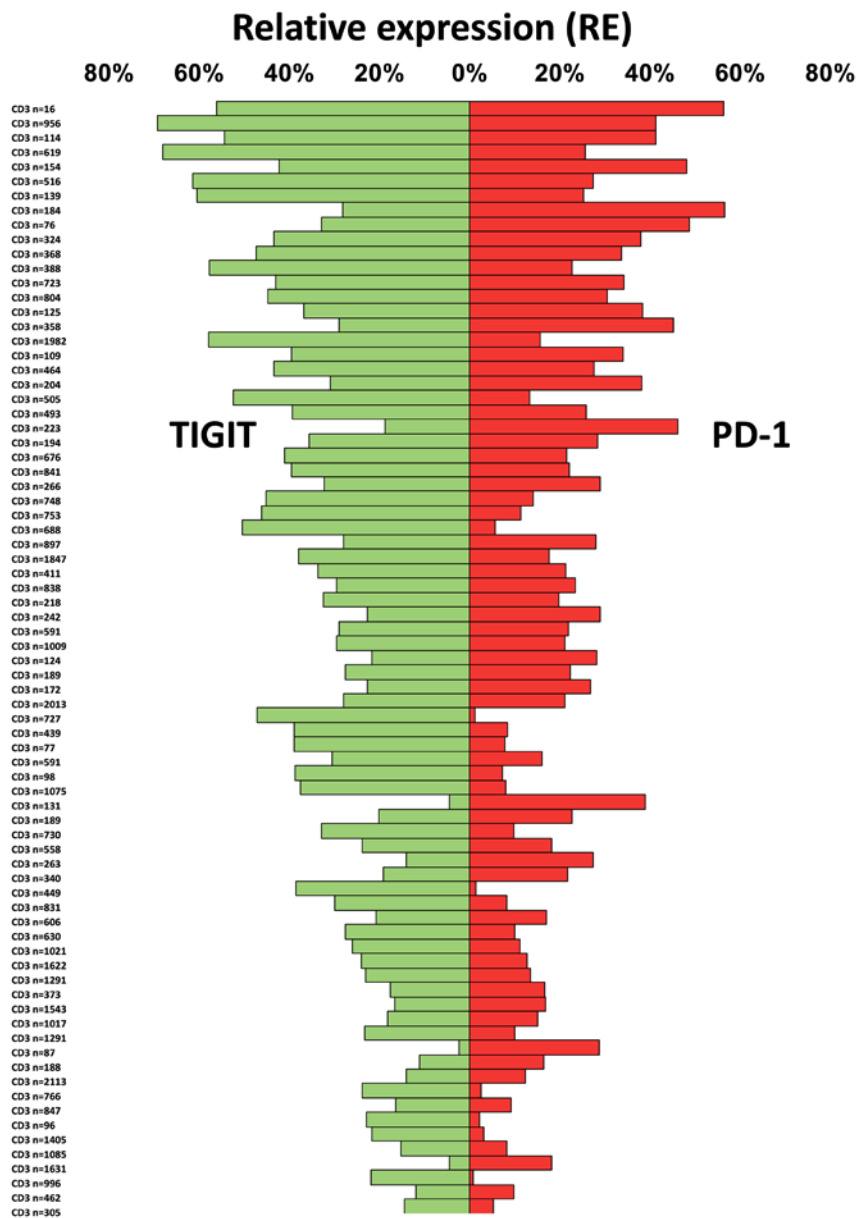


Figure 2. The inter-individual fraction of TIGIT (green) and PD-1 (red) positive CD3⁺ immune cells in 78 seminoma patients. The absolute number of CD3 positive cells is indicated at the left-hand side. TIGIT, T cell immunoreceptor with Ig and ITIM domains.

tumors had PD-1 levels beyond that of TIGIT. In these cancers, the PD-1: TIGIT ratio ranged from 0.02 to 12.5 (Fig. 3).

Discussion

The data from the present study demonstrate that not only the fraction of TIGIT⁺ and/or PD-1⁺ T cells, but also their relative abundance, is highly variable between individual seminomas.

TIGIT⁺ T lymphocytes were detected in all tumors in our study. This was expected because in an earlier study using a comparable experimental set-up, we had also regularly found TIGIT expression in a considerable fraction of lymphocytic cells in healthy lymphatic organs, various inflammatory diseases and in samples of lung and colorectal cancers (19). Taken together, these findings strongly support the concept that TIGIT expression is an inherent feature of T cell lymphocytic infiltrations in normal, inflammatory

and cancerous tissues (19). Earlier studies using flow cytometry have also described regular presence of TIGIT⁺ T cells in these immune microenvironments (13,17,21,24,25). For example, Johnston *et al* (16), detected TIGIT expression among CD8⁺ cytotoxic T cells in colon and breast cancer. Josefsson *et al* (24), described TIGIT expressing cells in follicular lymphomas. Luo *et al* (25), showed increased TIGIT expression in the autoimmune environment of rheumatoid arthritis (26). Drugs targeting TIGIT are currently developed by various companies (15,20). Although there is some evidence for a lack of response to PD-L1 inhibitory drugs in more than 90% of the treated patients (27), further therapy attempts using combined or single anti-TIGIT and/or anti-PD-1 therapies are still lacking in testicular seminoma.

Overall, the existing data on the prevalence of TIGIT expression seems to suggest that such drugs may potentially be applicable to a very broad range of different tumor types.

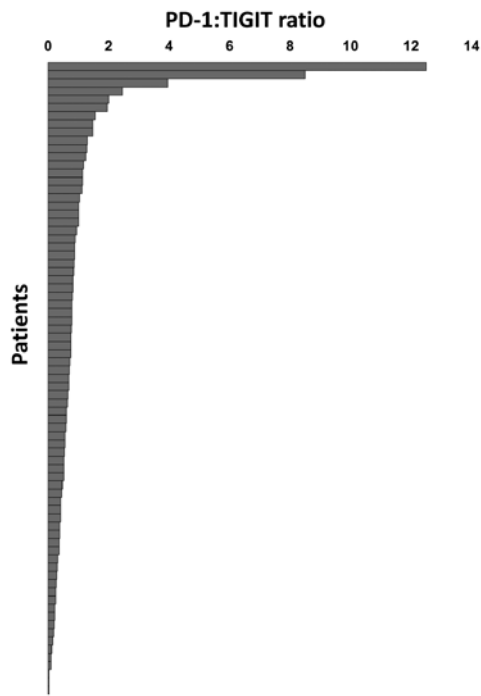


Figure 3. Distribution of the PD-1: TIGIT ratio. Each bar represents a single patient. TIGIT, T cell immunoreceptor with Ig and ITIM domains; PD-1, Programmed Cell Death 1.

The high interest in TIGIT emanates from its analogy to PD-1, which has become a major therapeutic ‘host target’ in a multitude of human tumor types (8,28,29). That PD-1 expression was seen in a fraction of T lymphocytes in all analyzed seminomas is in line with a recent study using multiplex fluorescence immunohistochemistry (30). In this study, Siska *et al* found a variable T cell infiltration and immune checkpoint expression in almost all analyzed large sections of seminomas and non-seminomas. That comparable absolute and relative numbers were found in our study using brightfield immunohistochemistry represents an indirect validation of our experimental approach.

The high numbers of intratumoral CD3⁺, TIGIT⁺ and PD-1⁺ cells per 0.6 mm tissue spot (0.28 mm²) demonstrate that immune cells play a particularly strong role in seminoma. Adjusted numbers per square millimeter (CD3: Average 2,203±1,799 per mm²) are higher than what we found in urinary bladder cancer (CD3: 625±800, cells/mm²) (31) or what was earlier described in breast (150 to 300 CD3⁺ cells/mm²) (32) or colorectal cancer (400 to 700 CD3⁺ cells/mm²) (33). The potential significance of these immune cells for anti-tumor activity is best demonstrated by cases of ‘burned out seminomas’ (34). In these patients-sometimes extensive-metastatic seminoma spread occurs in the absence of vital tumor tissue in the testis. Instead, circumscribed scar formation indicates the location of a ‘self-healed’ testicular seminoma. Based on this, it is tempting to speculate that treatment with immune checkpoint inhibitors-perhaps even first line-might be particularly successful in testicular germ cell tumors. Currently used platinum-based therapies are highly efficient (35) but there are only inadequate treatment options available for chemotherapy refractory or relapsed metastatic testicular seminomas (36). However, because of the young age, patients often develop long-term

sequelae of treatment, such as cardiovascular disease, renal insufficiency or secondary malignancies (35,37,38). Therapies targeting immune checkpoint receptors may exert comparable little long-term side effects (39,40).

The most striking observation in our study was the high variability of the relative fraction of TIGIT⁺ and PD-1⁺ lymphocytes in seminomas. We earlier reported a similar diversity of the relative role of TIGIT and PD-1 in a cohort of 40 Hodgkin's lymphomas (41). If it holds true that the different checkpoint receptors are so variably expressed in individual cancer patients, the analysis of the inflammatory cells may prove instrumental to select the optimal immune checkpoint inhibitor for a given patient.

In conclusion, the results of our study demonstrate frequent expression of immune checkpoint receptors in human seminomas. This argues for a potential benefit of drugs targeting immune checkpoint molecules in these tumors. The high variability of the relative prevalence of TIGIT⁺ and PD-1⁺ cells between patients raises the hypothesis that a thorough analysis of checkpoint proteins in tumor infiltrating lymphocytes may in the future assist the choice of therapy.

Acknowledgements

The authors would like to thank Mrs Christina Möller-Koop, Mrs Inge Brandt, Mrs Melanie Witt and Mrs Janett Lüttgens from the Department of Pathology, University Medical Centre Hamburg-Eppendorf, for their technical assistance.

Funding

No funding was received.

Availability of data and materials

The datasets used and/or analyzed during the present study are available from the corresponding author on reasonable request.

Authors' contributions

WW, GS, RS, NB and KF undertook study conception and design. AH, NB, WL, RS, GS, KF were responsible for development of the methodology. Acquisition of data, including providing animals, acquiring and managing patients, providing facilities, was the responsibility of AH, WL, NB, TM, BW, ND, WW, DH, ML, JI, SM, FB, RU, DD, TK, AL, CW, FJ, EB and SS. Analysis and interpretation of data, including statistical analysis, biostatistics, computational analysis was performed by AH, WW, WL, NB, RS and GS. Writing, review, and/or revision of the manuscript was performed by RS, GS, WW and NB. Administrative, technical, or material support (i.e., reporting or organizing data, tissue processing, antibody development) was performed by MK, CHM, GMF, DH, ML, JI, SM, FB, RU, DD, TK, AL, CW, FJ, EB, SS and WW. GS, RS, WW and AH supervised the study.

Ethics approval and consent to participate

Archived diagnostic leftover tissues for manufacturing of TMAs was pseudo-anonymized and used without informed

consent according to the local law (HmbKHG, §12a). The study was approved by the local ethic committee (Ethics commission of the Ärztekammer Hamburg no. WF-049/09) and in line with the Declaration of Helsinki.

Patient consent for publication

Not applicable.

Competing interests

The authors declare that they have no competing interests.

References

- Hayes-Lattin B and Nichols CR: Testicular cancer: A prototypic tumor of young adults. *Semin Oncol* 36: 432-438, 2009.
- Krege S, Beyer J, Souchon R, Albers P, Albrecht W, Algaba F, Bamberg M, Bodrogi I, Bokemeyer C, Cavallin-Stahl E, *et al*: European consensus conference on diagnosis and treatment of germ cell cancer: A report of the second meeting of the European Germ Cell Cancer Consensus group (EGCCCG): Part I. *Eur Urol* 53: 478-496, 2008.
- Hanna N and Einhorn LH: Testicular cancer: A reflection on 50 years of discovery. *J Clin Oncol* 32: 3085-3092, 2014.
- Adra N and Einhorn LH: Salvage therapy for relapsed testicular cancer. *Oncotarget* 8: 69200-69201, 2017.
- Oing C, Alsdorf WH, von Amsberg G, Oechsle K and Bokemeyer C: Platinum-refractory germ cell tumors: An update on current treatment options and developments. *World J Urol* 35: 1167-1175, 2017.
- Zschäbitz S, Lasitschka F, Hadaschik B, Hofheinz RD, Jentsch-Ullrich K, Grüner M, Jäger D and Grüllich C: Response to anti-programmed cell death protein-1 antibodies in men treated for platinum refractory germ cell cancer relapsed after high-dose chemotherapy and stem cell transplantation. *Eur J Cancer* 76: 1-7, 2017.
- Adra N, Einhorn LH, Althouse SK, Ammakkanavar NR, Musapatika D, Albany C, Vaughn D and Hanna NH: Phase II trial of pembrolizumab in patients with platinum refractory germ-cell tumors: A hoosier cancer research network study GU14-206. *Ann Oncol* 29: 209-214, 2018.
- Ansell SM, Lesokhin AM, Borrello I, Halwani A, Scott EC, Gutierrez M, Schuster SJ, Millenson MM, Cattry D, Freeman GJ, *et al*: PD-1 blockade with nivolumab in relapsed or refractory Hodgkin's lymphoma. *N Engl J Med* 372: 311-319, 2015.
- Wolchok JD, Kluger H, Callahan MK, Postow MA, Rizvi NA, Lesokhin AM, Segal NH, Ariyan CE, Gordon RA, Reed K, *et al*: Nivolumab plus ipilimumab in advanced melanoma. *N Engl J Med* 369: 122-133, 2013.
- Alsaab HO, Sau S, Alzhrani R, Tatiparti K, Bhise K, Kashaw SK and Iyer AK: PD-1 and PD-L1 checkpoint signaling inhibition for cancer immunotherapy: Mechanism, combinations, and clinical outcome. *Front Pharmacol* 8: 561, 2017.
- Chovanec M, Cierna Z, Miskovska V, Machalekova K, Svetlovska D, Kalavska K, Rejlekova K, Spanik S, Kajo K, Babal P, *et al*: Prognostic role of programmed-death ligand 1 (PD-L1) expressing tumor infiltrating lymphocytes in testicular germ cell tumors. *Oncotarget* 8: 21794-21805, 2017.
- Cierna Z, Mego M, Miskovska V, Machalekova K, Chovanec M, Svetlovska D, Hainova K, Rejlekova K, Macak D, Spanik S, *et al*: Prognostic value of programmed-death-1 receptor (PD-1) and its ligand 1 (PD-L1) in testicular germ cell tumors. *Ann Oncol* 27: 300-305, 2016.
- Liu XG, Hou M and Liu Y: TIGIT, a novel therapeutic target for tumor immunotherapy. *Immunol Invest* 46: 172-182, 2017.
- Manieri NA, Chiang EY and Grogan JL: TIGIT: A key inhibitor of the cancer immunity cycle. *Trends Immunol* 38: 20-28, 2017.
- Dougall WC, Kurtulus S, Smyth MJ and Anderson AC: TIGIT and CD96: New checkpoint receptor targets for cancer immunotherapy. *Immunol Rev* 276: 112-120, 2017.
- Johnston RJ, Comps-Agrar L, Hackney J, Yu X, Huseni M, Yang Y, Park S, Javinal V, Chiu H, Irving B, *et al*: The immunoreceptor TIGIT regulates antitumor and antiviral CD8(+) T cell effector function. *Cancer Cell* 26: 923-937, 2014.
- Chauvin JM, Pagliano O, Fourcade J, Sun Z, Wang H, Sander C, Kirkwood JM, Chen TH, Maurer M, Korman AJ and Zarour HM: TIGIT and PD-1 impair tumor antigen-specific CD8⁺ T cells in melanoma patients. *J Clin Invest* 125: 2046-2058, 2015.
- Kurtulus S, Sakuishi K, Ngiow SF, Joller N, Tan DJ, Teng MW, Smyth MJ, Kuchroo VK and Anderson AC: TIGIT predominantly regulates the immune response via regulatory T cells. *J Clin Invest* 125: 4053-4062, 2015.
- Blessin NC, Simon R, Kluth M, Fischer K, Hube-Magg C, Li W, Makrypidi-Fraune G, Wellge B, Mandelkow T, Debatin NF, *et al*: Patterns of TIGIT expression in normal lymphatic tissue, inflammation, and cancer. *Dis Markers* 2019: 5160565, 2019.
- Garber K: Industry 'road tests' new wave of immune checkpoints. *Nat Biotechnol* 35: 487-488, 2017.
- Kong Y, Zhu L, Schell TD, Zhang J, Claxton DF, Ehmann WC, Rybka WB, George MR, Zeng H and Zheng H: T-cell immunoglobulin and ITIM domain (TIGIT) associates with CD8+ T-Cell exhaustion and poor clinical outcome in AML patients. *Clin Cancer Res* 22: 3057-3066, 2016.
- Kononen J, Bubendorf L, Kallioniemi A, Bärklund M, Schraml P, Leighton S, Torhorst J, Mihatsch MJ, Sauter G and Kallioniemi OP: Tissue microarrays for high-throughput molecular profiling of tumor specimens. *Nat Med* 4: 844-847, 1998.
- JMP® V: SAS Institute Inc., Cary, NC, <https://www.jmp.com/1989-2019>.
- Josefsson SE, Huse K, Kolstad A, Beiske K, Pende D, Steen CB, Inderberg EM, Lingjærde OC, Østenstad B, Smeland EB, *et al*: T cells expressing checkpoint receptor TIGIT are enriched in follicular lymphoma tumors and characterized by reversible suppression of T-cell receptor signaling. *Clin Cancer Res* 24: 870-881, 2018.
- Luo Q, Deng Z, Xu C, Zeng L, Ye J, Li X, Guo Y, Huang Z and Li J: Elevated expression of immunoreceptor tyrosine-based inhibitory motif (TIGIT) on T lymphocytes is correlated with disease activity in rheumatoid arthritis. *Med Sci Monit* 23: 1232-1241, 2017.
- Yu X, Harden K, Gonzalez LC, Francesco M, Chiang E, Irving B, Tom I, Ivelja S, Refino CJ, Clark H, *et al*: The surface protein TIGIT suppresses T cell activation by promoting the generation of mature immunoregulatory dendritic cells. *Nat Immunol* 10: 48-57, 2009.
- Necchi A, Giannatempo P, Raggi D, Mariani L, Colecchia M, Farè E, Monopoli F, Calareso G, Ali SM, Ross JS, *et al*: An open-label randomized phase 2 study of durvalumab alone or in combination with tremelimumab in patients with advanced germ cell tumors (APACHE): Results from the first planned interim analysis. *Eur Urol* 75: 201-203, 2019.
- Topalian SL, Hodi FS, Brahmer JR, Gettinger SN, Smith DC, McDermott DF, Powderly JD, Carvajal RD, Sosman JA, Atkins MB, *et al*: Safety, activity, and immune correlates of anti-PD-1 antibody in cancer. *N Engl J Med* 366: 2443-2454, 2012.
- Farkona S, Diamandis EP and Blasutig IM: Cancer immunotherapy: The beginning of the end of cancer? *BMC Med* 14: 73, 2016.
- Siska PJ, Johnpulle RAN, Zhou A, Bordeaux J, Kim JY, Dabbas B, Dakappagari N, Rathmell JC, Rathmell WK, Morgans AK, *et al*: Deep exploration of the immune infiltrate and outcome prediction in testicular cancer by quantitative multiplexed immunohistochemistry and gene expression profiling. *Oncoimmunology* 6: e1305535, 2017.
- Mandelkow T, Blessin NC, Lueerss E, Pott L, Simon R, Li W, Wellege B, Debatin NF, Hoffmayer D, Izbicki JR, *et al*: Immune exclusion is frequent in small cell carcinoma of the bladder. *Dissemination Markers: Article ID 2532518*, 2019.
- Garcia-Martinez E, Gil GL, Benito AC, González-Billalabeitia E, Conesa MA, García García T, García-Garre E, Vicente V and Ayala de la Peña F: Tumor-infiltrating immune cell profiles and their change after neoadjuvant chemotherapy predict response and prognosis of breast cancer. *Breast Cancer Res* 16: 488, 2014.
- Galon J, Costes A, Sanchez-Cabo F, Kirilovsky A, Mlecnik B, Lagorce-Pagès C, Tosolini M, Camus M, Berger A, Wind P, *et al*: Type, density, and location of immune cells within human colorectal tumors predict clinical outcome. *Science* 313: 1960-1964, 2006.
- Fabre E, Jira H, Izard V, Ferlicot S, Hammoudi Y, Theodore C, Di Palma M, Benoit G and Droupy S: 'Burned-out' primary testicular cancer. *BJU Int* 94: 74-78, 2004.
- Hanna NH and Einhorn LH: Testicular cancer-discoveries and updates. *N Engl J Med* 371: 2005-2016, 2014.

36. Feldman DR, Patil S, Trinos MJ, Carouso M, Ginsberg MS, Sheinfeld J, Bajorin DF, Bosl GJ and Motzer RJ: Progression-free and overall survival in patients with relapsed/refractory germ cell tumors treated with single-agent chemotherapy: Endpoints for clinical trial design. *Cancer* 118: 981-986, 2012.
37. Abouassaly R, Fossa SD, Giwercman A, Kollmannsberger C, Motzer RJ, Schmoll HJ and Sternberg CN: Sequelae of treatment in long-term survivors of testis cancer. *Eur Urol* 60: 516-526, 2011.
38. Wethal T, Kjekshus J, Røislien J, Ueland T, Andreassen AK, Wergeland R, Aukrust P and Fosså SD: Treatment-related differences in cardiovascular risk factors in long-term survivors of testicular cancer. *J Cancer Surviv* 1: 8-16, 2007.
39. Ribas A, Puzanov I, Dummer R, Schadendorf D, Hamid O, Robert C, Hodi FS, Schachter J, Pavlick AC, Lewis KD, *et al*: Pembrolizumab versus investigator-choice chemotherapy for ipilimumab-refractory melanoma (KEYNOTE-002): A randomised, controlled, phase 2 trial. *Lancet Oncol* 16: 908-918, 2015.
40. Brahmer J, Reckamp KL, Baas P, Crinò L, Eberhardt WE, Poddubskaya E, Antonia S, Pluzanski A, Vokes EE, Holgado E, *et al*: Nivolumab versus docetaxel in advanced squamous-cell non-small-cell lung cancer. *N Engl J Med* 373: 123-135, 2015.
41. Li W, Blessin NC, Simon R, Kluth M, Fischer K, Hube-Magg C, Makrypidi-Fraune G, Wellge B, Mandelkow T, Debatin NF, *et al*: Expression of the immune checkpoint receptor TIGIT in Hodgkin's lymphoma. *BMC Cancer* 18: 1209, 2018.



This work is licensed under a Creative Commons Attribution-NonCommercial-NoDerivatives 4.0 International (CC BY-NC-ND 4.0) License.