



Comparison of different impression techniques for edentulous jaws using three-dimensional analysis

Sua Jung⁺, Chan Park⁺, Hong-So Yang, Hyun-Pil Lim, Kwi-Dug Yun, Zhai Ying, Sang-Won Park*

Department of Prosthodontics, School of Dentistry, Chonnam National University, Gwangju, Republic of Korea

PURPOSE. The purpose of this study was to compare two novel impression methods and a conventional impression method for edentulous jaws using 3-dimensional (3D) analysis software. **MATERIALS AND METHODS.** Five edentulous patients (four men and one woman; mean age: 62.7 years) were included. Three impression techniques were used: conventional impression method (CI; control), simple modified closed-mouth impression method with a novel tray (SI), and digital impression method using an intraoral scanner (DI). Subsequently, a gypsum model was made, scanned, and superimposed using 3D analysis software. Mean area displacement was measured using CI method to evaluate differences in the impression surfaces as compared to those values obtained using SI and DI methods. The values were confirmed at two to five areas to determine the differences. CI and SI were compared at all areas, while CI and DI were compared at the supporting areas. Kruskal-Wallis test was performed for all data. Statistical significance was considered at P value $<.05$. **RESULTS.** In the comparison of the CI and SI methods, the greatest difference was observed in the mandibular vestibule without statistical significance ($P>.05$); the difference was < 0.14 mm in the maxilla. The difference in the edentulous supporting areas between the CI and DI methods was not significant ($P>.05$). **CONCLUSION.** The CI, SI, and DI methods were effective in making impressions of the supporting areas in edentulous patients. The SI method showed clinically applicability. [*J Adv Prosthodont 2019;11:179-86*]

KEYWORDS: 3-Dimensional (3D) analysis; Simple modified impression; Digital impression; Jaw; Edentulous

INTRODUCTION

Digital dentistry is a hot topic in the dental field, in which digital data are used in all processes.¹⁻⁸ Conventional treatments were limited to provisional and single-unit crowns.^{9,10} However, digital dentistry has a growing potential and is currently used in the fabrication of long-span crown and

bridges, implant prostheses, dentures, and total dentistry.¹¹⁻¹⁷ Rehabilitation with complete denture is a treatment for edentulous patients and includes several stages such as diagnosis, preliminary impression followed by definitive impression, measurement of the centric relation (CR) and vertical dimension (VD), wax denture try-in, and delivery of definitive denture.¹⁸ Digitization of the procedure could simplify the complex process of fabricating the prosthesis and also shorten the time required.¹³ Computer-aided design (CAD) files can be stored permanently; this enables the manufacture of materials without the need for additional impressions. In addition, various types of articulations can be achieved, allowing applicability as an educational tool. Several techniques for fabrication of complete dentures and outcome of patient satisfaction have been reported.^{19,20}

However, digitization of complete dentures is a challenging process,²¹ considering that total dentistry is performed in edentulous areas where it is difficult to obtain the surface impressions, and VD and CR values using digital methods. Therefore, many studies have used the existing analog method.¹¹⁻¹⁵ Digital dentures are often limited to fab-

Corresponding author:
Sang-Won Park
Department of Prosthodontics, School of Dentistry, Chonnam National University
33 Yongbong-ro, Buk-gu, Gwangju 61186, Republic of Korea
Tel. +82625305842; e-mail, psw320@naver.com
Received November 12, 2018 / Last Revision February 19, 2019 /
Accepted April 9, 2019

© 2019 The Korean Academy of Prosthodontics
This is an Open Access article distributed under the terms of the Creative Commons Attribution Non-Commercial License (<http://creativecommons.org/licenses/by-nc/4.0>) which permits unrestricted non-commercial use, distribution, and reproduction in any medium, provided the original work is properly cited.

⁺Sua Jung and Chan Park contributed equally to this work.
This research was supported by the Ministry of Trade, Industry & Energy (MOTIE), Korea Institute for Advancement of Technology (KIAT) through the Encouragement Program for The Industries of Economic Cooperation Region.

rication of the prostheses and not used in the clinical setting.¹³ The impression of the surface, and VD and CR acquisitions are difficult to digitize with the current technology in complete denture treatment.

Digitization as a protocol for use in total dentistry can be completed in a short time-period. It involves newly developed concepts, materials, and techniques as well as prosthetic manufacturing. The conventional open-mouth technique of impression-making is validated and widely used in fabricating the complete denture,¹⁵ but it is time consuming and requires additional information of the VD, CR, and anterior tooth position; therefore, it is advantageous to apply a closed-mouth impression technique for the digitization of complete dentures. The closed-mouth impression technique involves making an individual tray containing an occlusal rim in the preliminary model and, subsequently, the definitive impression in which the maxillary and mandible occlusal rims are in contact with each other; provisional VD and CR are simultaneously determined. This method has the advantage of reducing the number of clinic visits since definitive impression can be achieved through definitive intermaxillary relationship.^{16,17} Closed-mouth technique with digital device, as the method of choice for making the impression, allows the achievement of more accurate impression surface and VD and CR values at a shorter time-period compared to existing conventional techniques. We combined our new approach and the average VD values in edentulous patients in the production of the digital device with 3D printing.

However, a closed-mouth impression method performed with a digital device would have poor reliability if there are significant differences in the impression as compared to that through existing conventional techniques. Therefore, a comparative study on the differences between impressions obtained through the various techniques is needed. Studies including a digitized device and software have been reported;²²⁻²⁵ the method employed was to scan the target objects using a scanner and overlay the acquired images using software in order to compare the differences.²⁵ The technique of superimposition is simple, reliable, and has been used in several recent studies.^{26,27} In this study, superimposition technology of a surface-matching software was used to compare the effectiveness of the conventional impression method (CI) versus simple modified closed-mouth impression method with a novel tray (SI), and the impressions acquired with the digital impression method using an intraoral scanner (DI) were compared to determine the capability to capture the complete edentulous surface. The null hypothesis of the study is that there is no difference among the three impression techniques in all areas of maxillary and mandibular edentulism.

MATERIALS AND METHODS

Five volunteers (four men and one woman; mean age, 62.7 years) with maxillary and mandibular edentulous jaws were included. Power analysis with effect size of 2.2, alpha of

0.05, and power of 0.80 revealed that five people per group would be needed to detect the postulated effect size. Ethical approval was obtained from the Institutional Review Board of Chonnam National University Dental Hospital (IRB no. CNUDH-2017-015). All volunteers who underwent conventional or digital impression in the study signed informed consents form prior to participation. The inclusion criteria were as follows²⁵: fully edentulous patients requiring fabrication of complete dentures at least three months after extraction, absence of masticatory or motor system disorder, and ability to understand and respond to spoken Korean.

The entire process was carried out by a single prosthodontist with thirty years of experience. Impressions were made using each of the three methods of CI, SI, and DI in every volunteer, amounting to a total of fifteen impressions.

For each volunteer, prior to performing the CI method, a preliminary impression was made using irreversible hydrocolloid (Cavex Impressional, Cavex Holland BV, Haarlem, The Netherlands) and an edentulous impression metal tray (Schreinemakers metal edentulous impression trays, Clan Dental Products, Maarheeze, The Netherlands); subsequently, an individual tray was made with acrylic resin (Quicky, Nissin Dental Products Inc., Kyoto, Japan) using conventional methods, and definitive impressions were made with the open-mouth technique.²⁸ Modeling compound (Peri Compound, GC Corporation, Tokyo, Japan) and vinylpolysiloxane (Exadenture, GC Corporation, Tokyo, Japan) were used as materials for the definitive impression.

In the SI method of the present study, a new tray was designed to facilitate efficient, simultaneous determination of the VD, CR, and anterior tooth positions in a preliminary impression model as follows. First, the preliminary cast was scanned using a model scanner (D700, 3Shape, Copenhagen, Denmark), and the scan file was transferred to a dental CAD software (3Shape's CAD Design software, 3Shape, Copenhagen, Denmark). The tray was designed using the individual tray module of the software. For the space occupied by the modeling compound under non-selected pressure, the inner space of the tray was set to 4 mm. The handle of the maxillary tray was omitted, and the VD and position of the maxillary anterior teeth were set by making the plate detachable instead of with occlusal rim (Fig. 1A). The handle of the mandibular tray was also omitted, a short rim was created at the anterior position, and the CR was set by biting down with the maxillary plate. Subsequently, a rim with an undercut was made on the posterior aspect of the mandibular tray to ensure stability of the silicone bite-material (Regisil, Dentsply International Inc., Milford, DE, USA) (Fig. 1B).

Modeling compound was applied to the maxillary tray using a molding machine with an automatic border,²⁹ which was then placed at the correct position within the oral cavity. The plate of the maxillary tray was moved to the anterior, posterior, superior, and inferior positions of the maxillary anterior teeth and subsequently fixed with resin (Revotek LC, GC Corporation, Tokyo, Japan); a definitive impression was obtained using the conventional method.²⁸

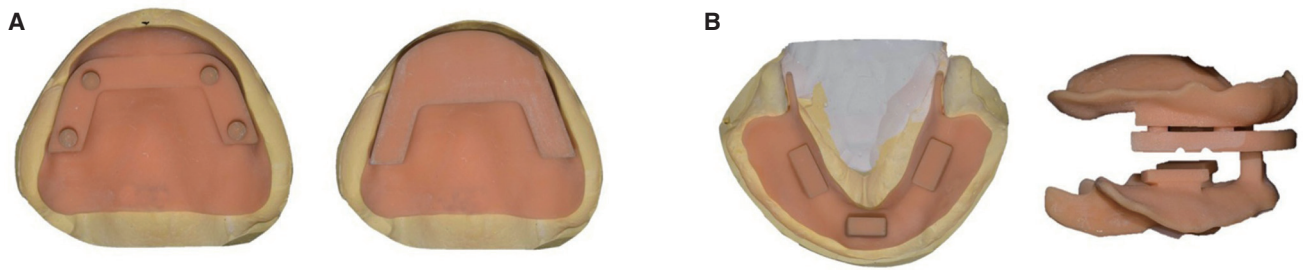


Fig. 1. (A) A novel maxillary tray for a simple modified impression method. (left) Not containing an occlusal rim; four-point support may be connected to the occlusal plate, but allowing slight movement of the plate to aid in locating the maxillary anterior teeth. (right) Occlusal plate with applied rim; unlike the conventional occlusal rim, this is designed to be easy to use with a large surface area to record the bite or for gothic arch tracing. (B) A novel mandibular tray for a simple modified impression method. (left) Occlusal view, (right) lateral view of both the novel maxillary and mandibular trays; the closed-mouth technique is performed by biting the maxillary occlusal plate and the mandibular anterior short occlusal rim using the bimanual method. The plate and mandibular occlusal rim have indentations so that the silicone bite registration material is precisely positioned between the two trays.

The mandibular tray was applied to the edentulous mandibular ridge while the maxillary impression was positioned in the mouth. After determining the CR position using the bimanual method,³⁰ the volunteers were instructed to close their mouth such that the anterior rim and maxillary plate were in contact. The plate or anterior rim was removed (as required) to ensure accurate determination of the VD. The preset CR and VD were rechecked after molding of the mandibular border, and a definitive impression was made using the closed-mouth technique.³¹

Digital impressions of the edentulous jaws (DI method) were made using an intraoral scanner (CS3500, Carestream Dental LLC, Atlanta, GA, USA) and individual retractor (Scan retractor, DIO Corporation, Busan, Korea) as follows. First, the edentulous jaws were cleaned, saliva was wiped dry, and retractor was adjusted according to the size of the arch. Scanning was performed by retracting the lip and cheek with the scanner head while stretching and fixing the vestibular area with the retractor. The maxilla was scanned from the left to the right maxillary tuberosity along the posterior palatal seal; next, the vestibule and palate were sequentially scanned to overlap with the scanned residual ridge. In a similar manner, the mandible was scanned from the retromolar pad on one side to the contralateral side along the residual ridge, followed by buccal vestibular scanning with retraction of the lip and cheek; finally, the lingual vestibule was scanned with retraction of the tongue. The scanned data were confirmed visually and saved in Standard Tessellation Language (STL) format.

CI and SI methods were used to obtain dental stone models (Zostone, Shimomura Gypsum Co., Ltd., Saitama, Japan) following conventional procedure, and the STL-model cast file was obtained using a model scanner.

The STL files of each edentulous surface from the CI method were superimposed onto those from the SI and DI methods using surface-matching software (Geomagic

Control 2014, 3D Systems, Rock Hill, SC, USA);³¹ specifically, the best-fit algorithm of the software was used. Comparisons of the CI and SI methods were made at five different regions of the maxilla and mandible.³² Due to limitations of the DI method in making the impression of movable tissue, the CI and DI methods were compared at four areas of the maxilla and two areas of the mandible. Comparisons of the CI and SI methods, and the CI and DI methods are shown in Fig. 2. The overall study workflow is shown in Fig. 3.

Statistical analysis was performed using Statistics Package for the Social Sciences software (SPSS version 23.0, SPSS Inc., Chicago, IL, USA). Kruskal-Wallis test was used to compare the impression techniques among multiple areas in the five volunteers.³² $P < .05$ was considered to indicate statistical significance.

RESULTS

The results of SI superimposed on those of CI are shown in Fig. 4, Fig. 5 and Fig. 6. CI achieved less depressed values overall with a mean difference of 0.03 ± 0.01 mm in the maxilla; the soft palate had the greatest difference of about 0.14 ± 0.02 mm, and the variations in the other areas were -0.10 ± 0.03 mm (medial palatine raphe), 0.04 ± 0.01 mm (hard palate), 0.01 ± 0.05 mm (residual ridge), and 0.07 ± 0.02 mm (buccal vestibule). The average difference was -0.27 ± 0.56 mm in the mandible, and the CI method achieved more depressed values in this region. Moreover, there was the greatest difference in the lingual vestibule (about -1.2 ± 1.40 mm), and the differences in the other areas were -0.25 ± 0.04 mm (residual ridge), -0.34 ± 0.08 mm (buccal shelf), -0.26 ± 0.17 mm (retromolar pad), and 0.53 ± 0.09 mm (buccal vestibule). The results of superimposition for the SI and the DI methods are shown in Fig. 5, Fig. 6 and Fig. 7. DI achieved more depressed values and

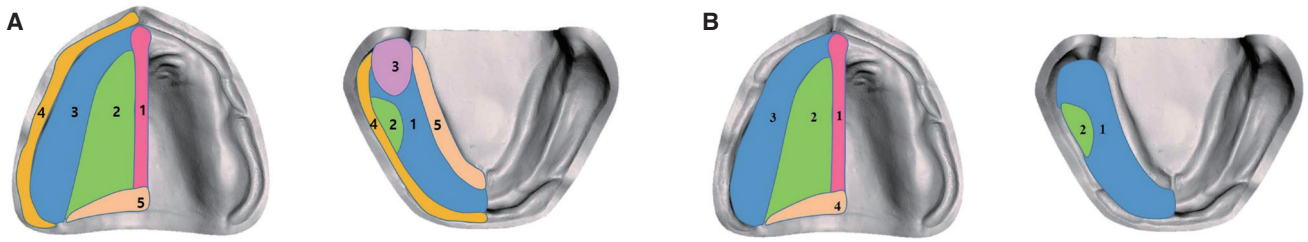


Fig. 2. (A) Areas compared by the CI and SI methods; (left) 1. Medial palatine raphe, 2. Hard palate, 3. Residual ridge, 4. Buccal vestibule, 5. Soft palate, (right) 1. Residual ridge, 2. Buccal shelf, 3. Retromolar pad, 4. Buccal vestibule, 5. Labial vestibule. (B) Areas compared by the CI and DI methods; (left) 1. Medial palatine raphe, 2. Hard palate, 3. Residual ridge, 4. Soft palate, (right) 1. Residual ridge, 2. Buccal shelf.

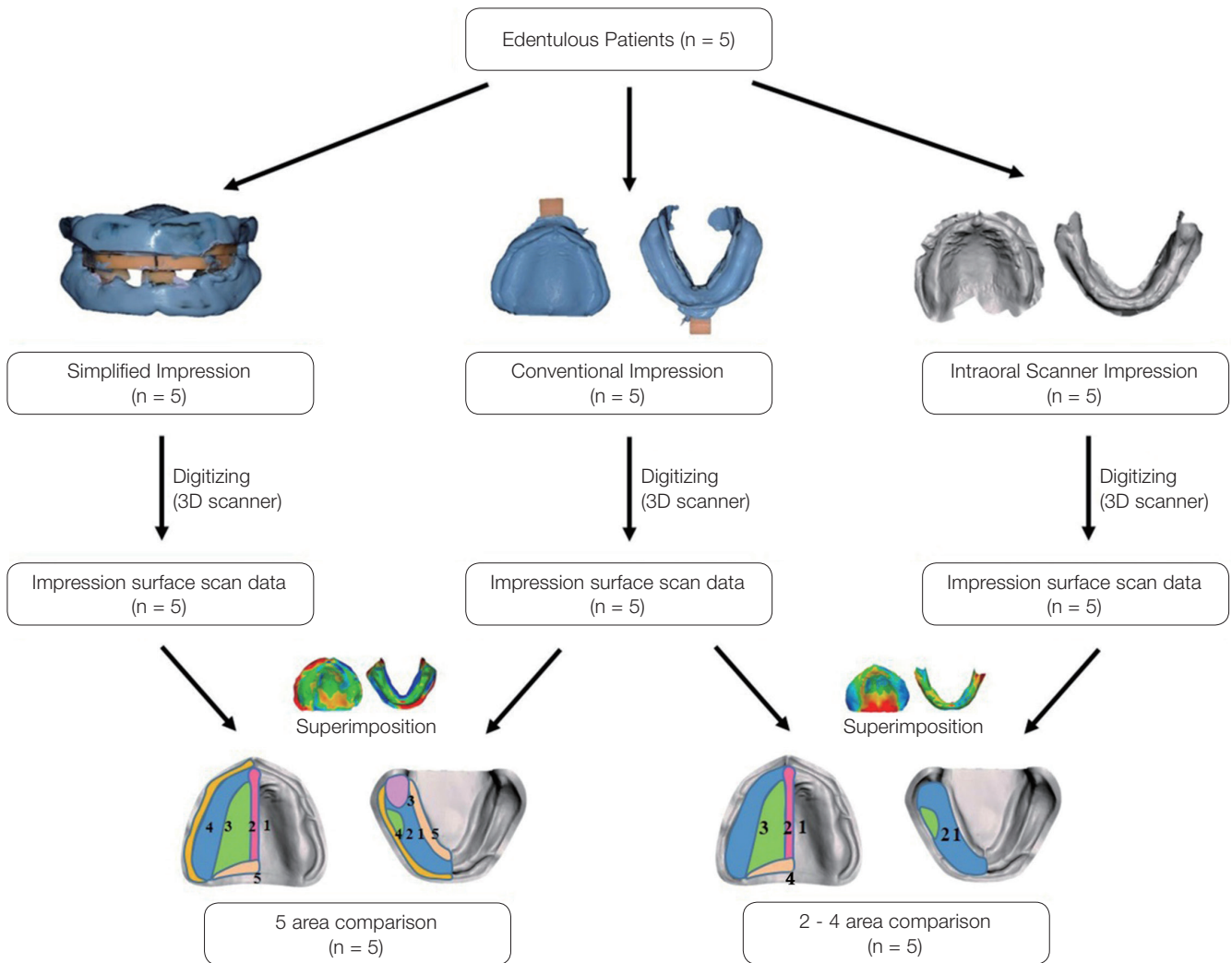


Fig. 3. Protocol of this experiment.

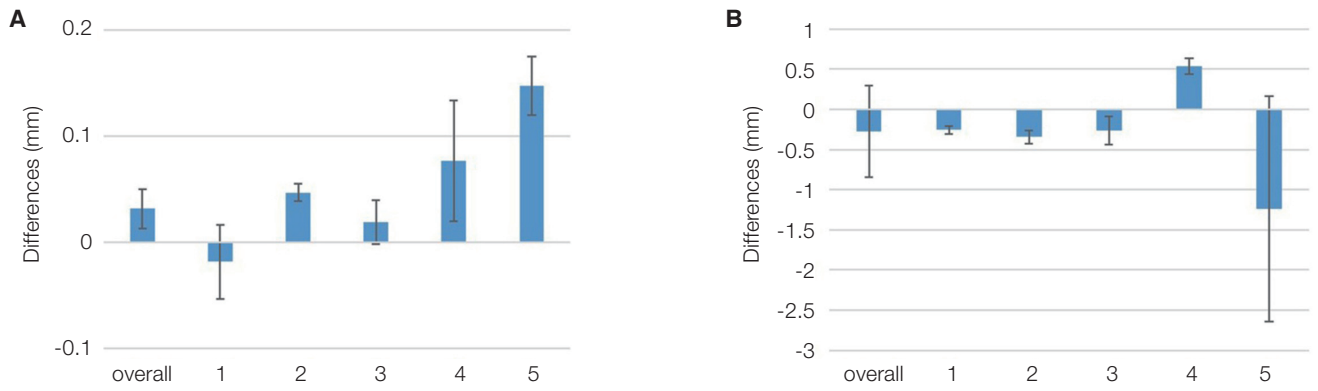


Fig. 4. Results from the comparison between the CI and SI methods; (A) Maxilla: 1-Medial palatine raphe, 2-Hard palate, 3-Residual ridge, 4-Buccal vestibule, 5-Soft palate; (B) Mandible: 1-Residual ridge, 2-Buccal shelf, 3-Retromolar pad, 4-Buccal vestibule, 5-Labial vestibule. None of the values showed statistically significant differences.

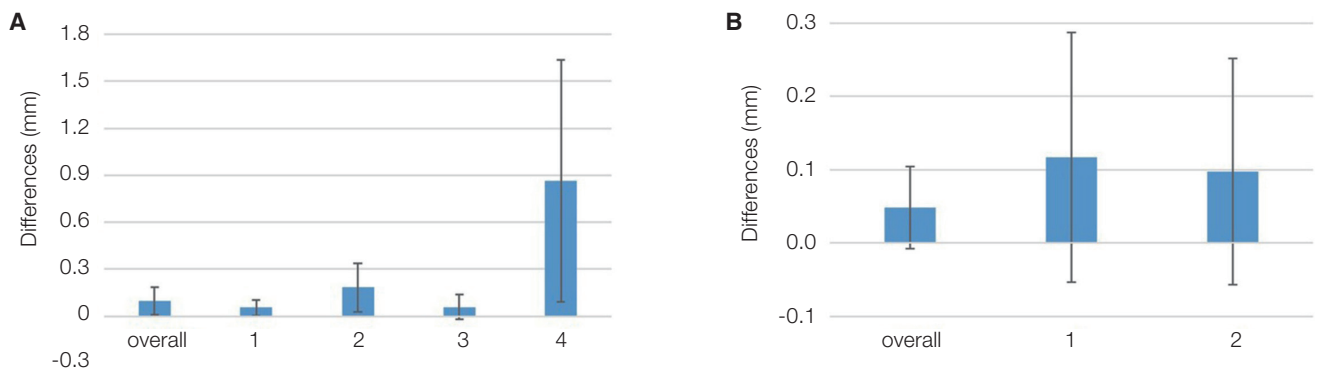


Fig. 5. Results from the comparison between the CI and DI methods; (A) Maxilla: 1-Medial palatine raphe, 2-Hard palate, 3-Residual ridge, 4-Soft palate; (B) Mandible: 1-Residual ridge, 2-Buccal shelf. None of the values showed statistically significant differences.

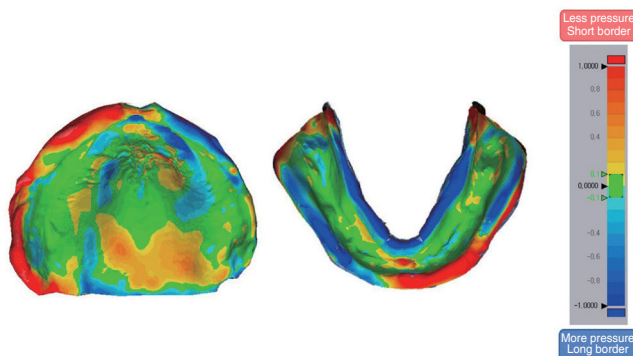


Fig. 6. Color deviation map of superimposition of the areas recorded by the CI and SI methods; 'Red' or 'Yellow' color means less depressed CI impression technique, and 'Blue' color means more depressed CI impression technique. Notice the border of the maxilla (especially left), soft palate, and lingual border of the mandible.

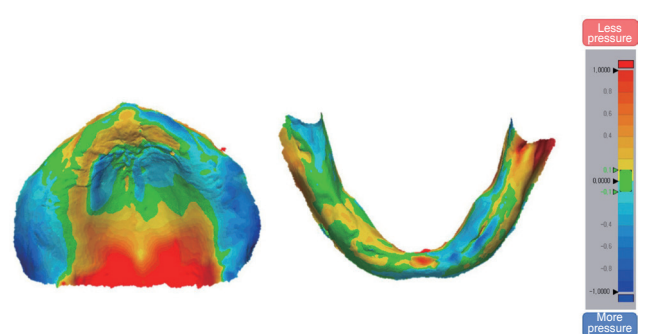


Fig. 7. Color deviation map of superimposition of the areas recorded by the CI and DI methods; 'Red' or 'Yellow' color means less depressed CI impression technique, and 'Blue' color means more depressed CI impression technique. There was a large difference only on the soft palate in the maxilla. That is, the CI method pressed the soft palate less than the DI method.

showed an average difference of 0.09 ± 0.08 mm in the maxilla. The soft palate had a much greater difference of 0.86 ± 0.77 mm, and the variations in the other areas were 0.05 ± 0.05 mm (medial palatine raphe), 0.18 ± 0.15 mm (hard palate), and 0.05 ± 0.07 mm (residual ridge). The mandible was subjected to less pressure under the DI method and had a difference of 0.04 ± 0.05 mm. A difference in the value of the residual ridge was 0.11 ± 0.17 mm and that of the buccal shelf was 0.09 ± 0.15 mm. There was no statistically significant difference among the values.

DISCUSSION

This study compared the performances of the CI, SI, and DI methods in edentulous jaws. Compared with the CI method, the SI method achieved somewhat different results; however, the overall difference was not significant. There was no difference between the results obtained through the CI and DI methods in the supporting areas. Based on these findings, the null hypothesis of this study was rejected.

The workflow for digital denture requires an efficient method for delivery of patient information in the clinic and production of digital prostheses in the laboratory. In this study, the VD and CR values were obtained on the same day of making the definitive impression by using a newly designed tray to enhance efficiency of the closed-mouth technique. The experimental results revealed a difference of 0.03 mm, which is clinically acceptable.³³ Therefore, the proposed method can be applied to a digital denture protocol in the clinical setting.

The conventional individual tray for complete dentures was produced in three steps of making the preliminary impression, stone model, and tray comprising auto-polymerized resin and required an extended amount of time. In this study, the proposed new tray was produced by 3D printing of a CAD file in approximately an hour, without making of a stone cast after the preliminary impression. The individual tray was fabricated from an impression through intraoral scanning; therefore, it was easy to use. Moreover, since the occlusal rim was constructed based of the average VD,^{34,35} measurement of the VD was possible with minor adjustment. Additionally, the mandibular occlusal rim was constructed based only on the anterior part of the tray; hence, it was possible to obtain the CR position rapidly. Automatic border modeling used in this method enabled a technique to increase the speed of locating the trays.²⁹ The maxillary tray was first fixed with a modeling compound gun and then positioned according to the CR through bimanual method,³⁰ and the rim of the mandibular tray was adjusted to the VD. Since the trays could be easily fixed using modeling compound, the process of making a definitive impression with polyvinylsiloxane impression material was also simple.

There was no clinically significant difference between the CI and SI methods in capturing the impression in edentulous individuals, which is consistent with the results of a previous report.³⁶ However, the statistical values of the

present results may represent difficulties when considering clinicians' viewpoint. In particular, the soft palate presented the largest difference, due to not only the presence of movable tissue, but also limitations of the location. However, in the case of edentulous mandibular impressions, the SI method could be the causal factor for the impression results because the patient's mouth is closed and the impression is made to withstand the patients' muscle strength and tongue movement; the tongue movement resulted in extension of the border of the impression in the lingual vestibule area. The results of this study are consistent with those of previous studies on impression using the closed-mouth functional technique.³⁷ Clinically acceptable extension of the lingual border is a key factor to enhance the retention of the mandibular complete denture.³⁶ Our results demonstrated that the SI method can improve retention of the mandibular denture.

Impression acquisition methods using an intraoral scanner are gradually gaining popularity in the dental field.¹ These techniques are commonly used in the partially edentulous jaw; in case of completely edentulous, several errors may occur due to lack of anatomical indicators. In addition, obtaining an impression of the complete edentulous arch has several challenges due to inappropriate shape and size of the scanner. Despite the incapability of an intraoral scanner to make a definitive impression of complete dentures, we compared the DI method to the existing CI method to provide basic information that may enable future study on digital denture. Movable tissues such as the vestibule and soft palate were extremely unstable in some cases; therefore, the performances of the DI and CI methods were compared only in the supporting areas.

Our results indicated that there was no difference between the CI and DI methods in the supporting areas. Other studies have suggested several complementary measures to overcome the accuracy limitation.^{38,39} However, since only the supporting areas with limited movable tissues were compared, the results are considered almost similar. Recently, in the field of digital dentistry, several advances have been made in the intraoral scanner,⁴⁰ and its accuracy has been proven in many studies.⁴¹⁻⁴⁴ Our study demonstrated that intraoral scanners can be used in soft tissues. The results obtained by scanning of the soft tissues were different from those of the teeth, since the shape and size of the scanner are optimized for scanning of the teeth. Improved results may be obtained using a scanner developed with specialized shape for targeting soft tissues.

In the present study, we newly attempted 3D analysis of edentulous patients. However, the study was limited to five patients. Additionally, there is uncertainty regarding the best-fit algorithm for appropriate comparisons in the dental field. Future studies on the fabrication of digital dentures with a larger-sized sample are needed. Our study highlights that it is possible to fabricate complete dentures in a single day in the near future.

CONCLUSION

Within the limits of this study, the following conclusions were drawn. First, there was no significant difference between the open-mouth CI method and closed-mouth SI method in maxillary and mandibular edentulous patients. Second, there was no significant difference in the supporting areas between the DI method and CI method in edentulous patients.

ORCID

Sua Jung <https://orcid.org/0000-0001-6728-0295>
 Chan Park <https://orcid.org/0000-0001-5729-5127>
 Hong-So Yang <https://orcid.org/0000-0002-9138-4817>
 Hyun-Pil Lim <https://orcid.org/0000-0001-5586-1404>
 Kwi-Dug Yun <https://orcid.org/0000-0002-2965-3967>
 Zhai Ying <https://orcid.org/0000-0002-4235-3061>
 Sang-Won Park <https://orcid.org/0000-0002-9376-9104>

REFERENCES

1. Beuer F, Schweiger J, Edelhoff D. Digital dentistry: an overview of recent developments for CAD/CAM generated restorations. *Br Dent J* 2008;204:505-11.
2. Zandinejad A, Lin WS, Atarodi M, Abdel-Azim T, Metz MJ, Morton D. Digital workflow for virtually designing and milling ceramic lithium disilicate veneers: a clinical report. *Oper Dent* 2015;40:241-6.
3. Wee AG, Lindsey DT, Kuo S, Johnston WM. Color accuracy of commercial digital cameras for use in dentistry. *Dent Mater* 2006;22:553-9.
4. Brennan J. An introduction to digital radiography in dentistry. *J Orthod* 2002;29:66-9.
5. Koch GK, Gallucci GO, Lee SJ. Accuracy in the digital workflow: From data acquisition to the digitally milled cast. *J Prosthet Dent* 2016;115:749-54.
6. Neumeier TT, Neumeier H. Digital immediate dentures treatment: A clinical report of two patients. *J Prosthet Dent* 2016; 116:314-9.
7. Alhassani AA, AlGhamdi AS. Inferior alveolar nerve injury in implant dentistry: diagnosis, causes, prevention, and management. *J Oral Implantol* 2010;36:401-7.
8. Wenzel A. A review of dentists' use of digital radiography and caries diagnosis with digital systems. *Dentomaxillofac Radiol* 2006;35:307-14.
9. Brawek PK, Wolfart S, Endres L, Kirsten A, Reich S. The clinical accuracy of single crowns exclusively fabricated by digital workflow-the comparison of two systems. *Clin Oral Investig* 2013;17:2119-25.
10. Payer M, Arnetzl V, Kirmeier R, Koller M, Arnetzl G, Jakse N. Immediate provisional restoration of single-piece zirconia implants: a prospective case series - results after 24 months of clinical function. *Clin Oral Implants Res* 2013;24:569-75.
11. Joo HS, Park SW, Yun KD, Lim HP. Complete-mouth rehabilitation using a 3D printing technique and the CAD/CAM double scanning method: A clinical report. *J Prosthet Dent* 2016; 116:3-7.
12. Ohkubo C, Shimpo H, Tokue A, Park EJ, Kim TH. Complete denture fabrication using piezography and CAD-CAM: A clinical report. *J Prosthet Dent* 2018;119:334-8.
13. Wimmer T, Gallus K, Eichberger M, Stawarczyk B. Complete denture fabrication supported by CAD/CAM. *J Prosthet Dent* 2016;115:541-6.
14. McLaughlin JB, Ramos V Jr. Complete denture fabrication with CAD/CAM record bases. *J Prosthet Dent* 2015;114:493-7.
15. AlHelal A, AlRumaih HS, Kattadiyil MT, Baba NZ, Goodacre CJ. Comparison of retention between maxillary milled and conventional denture bases: A clinical study. *J Prosthet Dent* 2017;117:233-8.
16. Felton DA, Cooper LF, Scurria MS. Predictable impression procedures for complete dentures. *Dent Clin North Am* 1996;40:39-51.
17. Collett HA. Final impressions for complete dentures. *J Prosthet Dent* 1970;23:250-64.
18. Goodacre BJ, Goodacre CJ, Baba NZ, Kattadiyil MT. Comparison of denture tooth movement between CAD-CAM and conventional fabrication techniques. *J Prosthet Dent* 2018;119:108-15.
19. Schweiger J, Güth JF, Edelhoff D, Stumbaum J. Virtual evaluation for CAD-CAM-fabricated complete dentures. *J Prosthet Dent* 2017;117:28-33.
20. Jacob RF. The traditional therapeutic paradigm: complete denture therapy. *J Prosthet Dent* 1998;79:6-13.
21. Ceruti P, Mobilio N, Bellia E, Borracchini A, Catapano S, Gassino G. Simplified edentulous treatment: A multicenter randomized controlled trial to evaluate the timing and clinical outcomes of the technique. *J Prosthet Dent* 2017;118:462-7.
22. Kattadiyil MT, AlHelal A, Goodacre BJ. Clinical complications and quality assessments with computer-engineered complete dentures: A systematic review. *J Prosthet Dent* 2017; 117:721-8.
23. Fang JH, An X, Jeong SM, Choi BH. Development of complete dentures based on digital intraoral impressions-Case report. *J Prosthodont Res* 2018;62:116-20.
24. Alsharbaty MHM, Alikhasi M, Zarrati S, Shamshiri AR. A clinical comparative study of 3-dimensional accuracy between digital and conventional implant impression techniques. *J Prosthodont* 2019;28:e902-8.
25. Gan N, Xiong Y, Jiao T. Accuracy of intraoral digital impressions for whole upper jaws, including full dentitions and palatal soft tissues. *PLoS One* 2016;11:e0158800.
26. Sharma S, Agarwal S, Sharma D, Kumar S, Glodha N. Impression; Digital vs. conventional: A review. *Ann Dent Spec* 2014;2:9-10.
27. Birnbaum NS, Aaronson HB. Dental impressions using 3D digital scanners: virtual becomes reality. *Compend Contin Educ Dent* 2008;29:494, 496, 498-505.
28. Heo YR, Kim HJ, Son MK, Chung CH. Contour of lingual surface in lower complete denture formed by polished surface impression. *J Adv Prosthodont* 2016;8:472-8.
29. Park C, Yang HS, Lim HP, Yun KD, Oh GJ, Park SW. A new fast and simple border molding process for complete den-

- tures using a compound stick gun. *Int J Prosthodont* 2016;29:559-60.
30. Dawson PE. Evaluation, diagnosis and treatment of occlusal problems. 3rd ed. St. Louis; Mosby; 1989. p. 41-7.
 31. Collett HA. Complete denture impressions. *J Prosthet Dent* 1965;15:603-14.
 32. Matsuda T, Goto T, Kurahashi K, Kashiwabara T, Watanabe M, Tomotake Y, Nagao K, Ichikawa T. Digital assessment of preliminary impression accuracy for edentulous jaws: Comparisons of 3-dimensional surfaces between study and working casts. *J Prosthodont Res* 2016;60:206-12.
 33. Yoon HI, Hwang HJ, Ohkubo C, Han JS, Park EJ. Evaluation of the trueness and tissue surface adaptation of CAD-CAM mandibular denture bases manufactured using digital light processing. *J Prosthet Dent* 2018;120:919-26.
 34. Pinelli LA, Fais LM, Ricci WA, Reis JM. In vitro comparisons of casting retention on implant abutments among commercially available and experimental castor oil-containing dental luting agents. *J Prosthet Dent* 2013;109:319-24.
 35. Koller MM, Merlini L, Spandre G, Palla S. A comparative study of two methods for the orientation of the occlusal plane and the determination of the vertical dimension of occlusion in edentulous patients. *J Oral Rehabil* 1992;19:413-25.
 36. Kawai Y, Murakami H, Shariati B, Klemetti E, Blomfield JV, Billette L, Lund JP, Feine JS. Do traditional techniques produce better conventional complete dentures than simplified techniques? *J Dent* 2005;33:659-68.
 37. Chaware SH, Fernandes F. Tissue stress evaluation at border seal area using patient-manipulated custom tray-modified closed-mouth functional technique for flat mandibular ridges. *J Int Oral Health* 2018;10:77-82.
 38. Azzam MK, Yurkstas AA, Kronman J. The sublingual crescent extension and its relation to the stability and retention of mandibular complete dentures. *J Prosthet Dent* 1992;67:205-10.
 39. Kim JE, Amelya A, Shin Y, Shim JS. Accuracy of intraoral digital impressions using an artificial landmark. *J Prosthet Dent* 2017;117:755-61.
 40. Logozzo S, Zanetti EM, Franceschini G, Kilpela A, Makynen A. Recent advances in dental optics - Part I: 3D intraoral scanners for restorative dentistry. *Opt Lasers Eng* 2014;54:203-21.
 41. Patzelt SB, Bishti S, Stampf S, Att W. Accuracy of computer-aided design/computer-aided manufacturing-generated dental casts based on intraoral scanner data. *J Am Dent Assoc* 2014;145:1133-40.
 42. Flügge TV, Schlager S, Nelson K, Nahles S, Metzger MC. Precision of intraoral digital dental impressions with iTero and extraoral digitization with the iTero and a model scanner. *Am J Orthod Dentofacial Orthop* 2013;144:471-8.
 43. Ender A, Mehl A. Accuracy of complete-arch dental impressions: a new method of measuring trueness and precision. *J Prosthet Dent* 2013;109:121-8.
 44. Patzelt SB, Emmanouilidi A, Stampf S, Strub JR, Att W. Accuracy of full-arch scans using intraoral scanners. *Clin Oral Investig* 2014;18:1687-94.