

Limping Following Primary Total Hip Replacement

Comparison of 3 Surgical Approaches

Boonchana Pongcharoen, MD, and Kittisak Chaichubut, MD

Investigation performed at the Department of Orthopaedic Surgery, Thammasat University, Pathumthani, Thailand

Background: Limping following total hip replacement affects clinical outcome and patient satisfaction. The purpose of the present study was to determine the prevalence of limping following the posterior approach, the direct lateral approach, and the modified anterolateral Watson-Jones approach for primary total hip replacement, performed by 1 surgeon.

Methods: We retrospectively reviewed the records for 152 patients who had undergone unilateral primary total hip replacement and assessed the prevalence of limping ≥ 2 years after surgery as a function of the surgical approach. Patients were divided into 3 groups, according to the surgical approach: (1) 43 patients, posterior approach; (2) 53 patients, direct lateral approach; and (3) 56 patients, modified anterolateral Watson-Jones approach. The mean duration of follow-up was 65.04 months (range, 24 to 117 months). No patients were lost to follow-up.

Results: There were no significant differences between the groups in terms of the limping rates (6.98%, 7.55%, and 3.57% for the posterior approach, direct lateral approach, and modified anterolateral Watson-Jones approach, respectively; $p = 0.64$). No patient had severe limping. The Harris hip score, the alignment of the acetabular component, and blood loss were not significantly different between the 3 groups. However, operative time was significantly longer for the modified anterolateral Watson-Jones approach ($p = 0.001$).

Conclusions: The prevalence of limping was similar ≥ 2 years after primary total hip replacement, irrespective of the surgical approach.

Level of Evidence: Therapeutic Level III. See Instructions for Authors for a complete description of levels of evidence.

Limping following total hip replacement is an adverse clinical outcome that affects patient satisfaction^{1,2}. The posterior approach results in a low rate of limping²⁻⁵ but is associated with hip dislocation^{2,6}. The modified anterolateral Watson-Jones approach has been increasingly adopted as a means of reducing postoperative limping and early recovery, but this approach is difficult for inexperienced surgeons⁷. The direct lateral approach allows for good exposure for the purpose of reconstructing the femur and acetabulum but may be associated with limping because it involves cutting the anterior part of the gluteus medius muscle^{4,8-11}. The purpose of the present study was to determine the rates of limping following primary total hip replacement with use of the posterior approach, direct lateral approach, and modified

anterolateral Watson-Jones approach when performed by 1 surgeon.

Materials and Methods

This study was approved by the Human Research Ethical Committee of the Faculty of Medicine, Thammasat University. We retrospectively reviewed the records for 168 consecutive patients who had undergone a unilateral primary total hip replacement between December 2005 and August 2015 at Thammasat University Hospital, Pathumthani, Thailand. The implants that were used included VerSys and Trilogy (Zimmer) ($n = 46$), ML Taper and Trilogy (Zimmer) ($n = 68$), Taperloc and RingLoc (Biomet) ($n = 43$), Synergy and Reflection (Smith & Nephew) ($n = 5$), and Corail and Pinnacle (DePuy) ($n = 6$).

Disclosure: The authors indicated that no external funding was received for any aspect of this work. The **Disclosure of Potential Conflicts of Interest** forms are provided with the online version of the article (<http://links.lww.com/JBJSOA/A88>).

Copyright © 2019 The Authors. Published by The Journal of Bone and Joint Surgery, Incorporated. All rights reserved. This is an open-access article distributed under the terms of the [Creative Commons Attribution-Non Commercial-No Derivatives License 4.0](https://creativecommons.org/licenses/by-nc-nd/4.0/) (CCBY-NC-ND), where it is permissible to download and share the work provided it is properly cited. The work cannot be changed in any way or used commercially without permission from the journal.

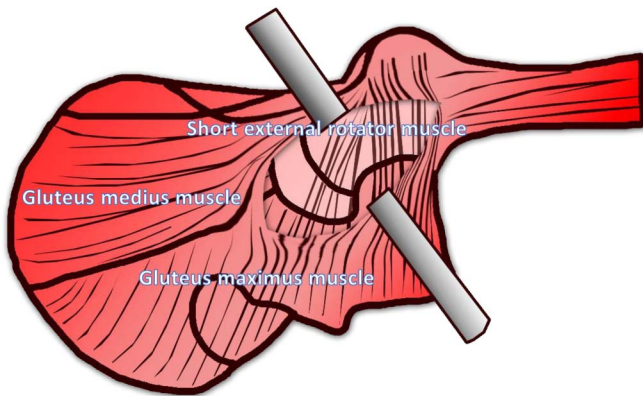


Fig.1-A

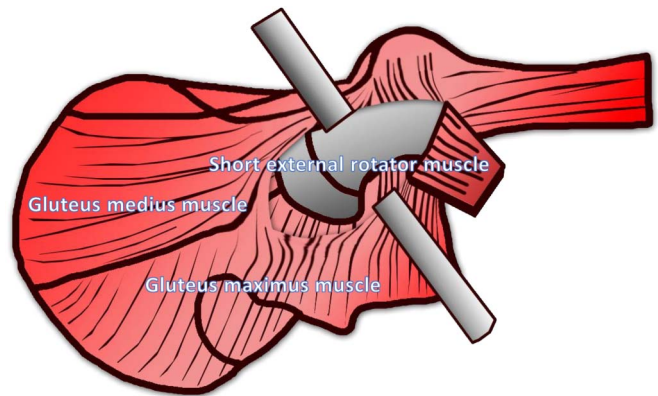


Fig.1-B

Figs. 1-A and 1-B The gluteus maximus muscle was cut along the length of its fibers (**Fig. 1-A**). The short external rotator and piriformis muscles were identified and cut on the femur (**Figs. 1-A and 1-B**).

We included patients with any one of several diagnoses: osteonecrosis of the femoral head (n = 56), osteoarthritis of the hip (n = 44), inflammatory joint disease (n = 18), and femoral neck fracture (n = 50). Of these, patients were excluded if they had infectious arthritis of the hip (n = 2), hip arthrodesis (n = 2), a neglected femoral neck fracture (n = 4), posttraumatic arthritis (n = 4), or limping due to abnormal hip biomechanics (e.g., high hip center, limb-length discrepancy of >1 cm, or decrease in horizontal offset by >15%) (n = 4).

Data were collected with use of a standardized case report form and included age, sex, site, Harris hip score¹², body mass index (BMI), and preoperative hip abductor muscle strength using the Medical Research Council (MRC) scale. Patients were classified into 3 groups according to the surgical approach: (1) Group I (posterior approach), (2) Group II (direct lateral approach), and (3) Group III (modified anterolateral Watson-Jones approach). All procedures were performed by the same surgeon (B.P.) as follows. The modified anterolateral Watson-Jones approach was used for non-obese patients (BMI <30 kg/m²) and/or non-muscular patients, the posterior approach was used for obese and/or muscular patients, and the direct lateral approach was used for patients with femoral neck fractures (to prevent hip dislocation) and for patients who were

intraoperatively unsuitable to undergo a modified anterolateral Watson-Jones approach because of difficulties in preparing the femur. All limping assessments were performed by research assistants with use of the limping subscore of the Harris hip score (range, 0 to 11 points) to grade limping severity: (1) level 0 (no limp, 11 points), (2) level 1 (slight limp detected by the research assistants and unnoticed by the patient, 8 points), (3) level 2 (moderate limp [e.g., abnormal pelvic motion such as pelvic drop] noticed by the patient, 5 points), and (4) level 3 (severe limp [pronounced lateral sway of body and trunk], 0 points)¹².

The inclination and anteversion of the acetabular component were assessed according to the method described by Lewinnek et al.¹³. Operative times, postoperative Harris hip scores, blood loss, complications (hip dislocation, groin pain, thigh pain, infections, fractures, pseudotumors, squeaks, ceramic fractures), hip abductor muscle strength, and revision rates were also recorded at the latest follow-up visit. The duration of follow-up was ≥2 years.

Operative Procedure

All patients received 1 g of cefazolin and 750 mg of tranexamic acid intravenously prior to the start of the procedure and were

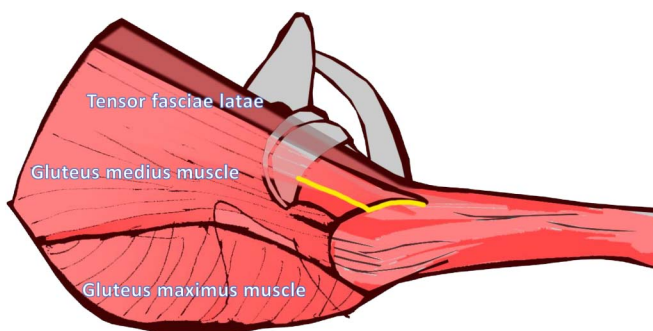


Fig.2-A

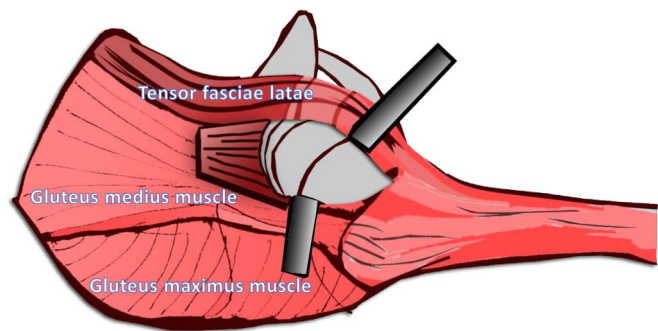


Fig.2-B

Figs. 2-A and 2-B The gluteus medius muscle was identified, and the anterior one-third of the muscle was cut from its insertion on the greater trochanter, allowing entry into the hip joint. (The fibers of the gluteus medius muscle lie anteriorly [yellow line].)

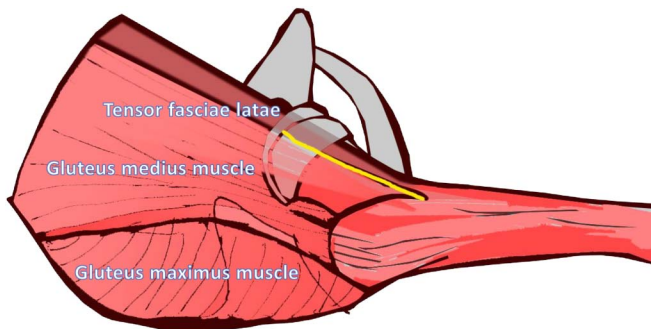


Fig.3-A

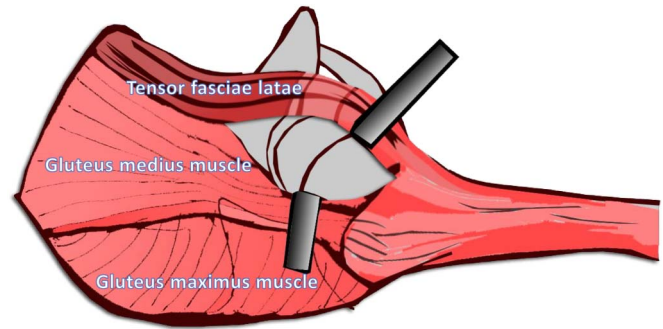


Fig.3-B

Figs. 3-A and 3-B The anterior border of the gluteus medius muscle and the posterior border of the tensor fasciae latae were identified and separated from each other along the yellow line. **Fig. 3-B** The gluteus medius muscle was retracted posteriorly, and the tensor fasciae latae was retracted anteriorly to allow entry into the hip joint.

then placed in the lateral decubitus position on the operating table.

Posterior approach: The skin incision for the posterior approach extended 5 cm above and below the tip of the greater trochanter. The gluteus maximus muscle was identified and was cut along the length of its fibers (Fig. 1-A). The short external rotator and piriformis muscles were identified and were cut from their insertion points on the femur before the hip joint was entered (Figs. 1-A and 1-B). The posterior capsule was identified and was incised in a T shape to allow the femoral head to be dislocated. The femoral neck was excised as per the preoperative template¹⁴.

Direct lateral approach: The skin incision for the direct lateral approach was curved from the anterior superior iliac spine (ASIS) to the greater trochanter and down along the femoral shaft. The sheath of tensor fasciae latae was cut along its fibers, and the anterior border of the gluteus medius muscle was identified (Fig. 2-A) and was cut from its insertion on the greater trochanter (Fig. 2-B). The anterior capsule was identified and was incised in a T shape to allow the femoral head to be dislocated. The femoral neck was excised as per the preoperative template¹⁵.

Modified anterolateral Watson-Jones approach: The skin incision for the modified anterolateral Watson-Jones approach

extended from the tip of the greater trochanter to the ASIS. The tensor fasciae latae and the anterior border of the gluteus medius muscle were identified before the hip joint was entered (Figs. 3-A and 3-B). The anterior capsule was identified and was cut in a T shape. The femoral neck was identified and was cut as per the preoperative template⁷.

We began with reconstruction of the femur first so that we were able to test the impingement immediately after completing the insertion of the trial acetabular component. If impingement of the acetabular cup and femoral neck was identified, we modified the anteversion of the acetabular cup until there was no impingement.

For the posterior approach, the posterior capsule and short external rotator were reattached to their insertion points. For the direct lateral approach, the anterior aspect of the gluteus medius muscle was repaired to the point of its insertion. For the modified anterolateral Watson-Jones approach, it was necessary to repair only the anterior capsule.

Patients were encouraged to walk on the first postoperative day, and they were discharged when they were walking with walking aids and did not need intravenous pain medication. Follow-up evaluations were performed at 2 and 6 weeks; at 3, 6, and 12 months; and annually thereafter.

TABLE I Demographic Data

	Posterior Approach (N = 43)	Direct Lateral Approach (N = 53)	Modified Anterolateral Watson-Jones Approach (N = 56)	P Value
Age* (yr)	49.96 ± 11.12 (22-65)	50.67 ± 8.26 (25-68)	47.91 ± 9.72 (24-65)	0.25
Sex (female:male) (no. of hips)	19:24	18:35	36:20	0.006
Side (right:left) (no. of hips)	20:23	21:32	30:26	0.35
Preoperative total Harris hip score* (points)	34.69 ± 5.30 (21-41.9)	35.20 ± 7.49 (21-45.9)	35.22 ± 5.34 (21-41.9)	0.89
BMI* (kg/cm ²)	27.24 ± 4.31 (21.40-42.22)	25.91 ± 3.68 (22.22-41.62)	25.83 ± 3.07 (20.81-33.20)	0.12

*The values are given as a mean and the standard deviation, with the range in parentheses.

TABLE II Prevalence of Limping

Limping	Posterior Approach (N = 43)	Direct Lateral Approach (N = 53)	Modified Anterolateral Watson-Jones Approach (N = 56)	P Value
Limping				
None	93.02%	92.45%	96.43%	0.64
Slight	4.65% (2 hips)	3.77% (2 hips)	0%	0.71
Moderate	2.33% (1 hip)	3.77% (2 hips)	3.57% (2 hips)	0.80
Severe	0%	0%	0%	NS†
Any	6.98% (3 hips)	7.55% (4 hips)	3.57% (2 hips)	0.64
Harris hip subscore* (<i>points</i>)	10.72 ± 1.09 (5-11)	10.66 ± 1.27 (5-11)	10.79 ± 1.12 (5-11)	0.33

*The values are given as the mean and the standard deviation, with the range in parentheses. †NS = not significant.

Anteroposterior and lateral cross-table radiographs of both hips were made at each follow-up.

Statistical Analysis

We calculated the sample size on the basis of reported rates of postoperative limping, with a risk difference of 25% (based on a limping rate of 30% for the direct lateral approach and 5% for the modified anterolateral Watson-Jones approach^{1,16}); the calculation showed that 43 patients in each group would yield 80% power to detect such a difference at the 5% significance level. We computed the differences in the rates of limping, sex, operative site, and dislocation with use of the chi-square test. Continuous data (e.g., Harris hip score, acetabular inclination, acetabular anteversion, operative time, blood loss, and BMI) were compared with use of analysis of variance (ANOVA) and the Tukey post hoc test.

Results

We identified 152 patients who underwent a primary total hip replacement: (1) Group I (43 patients, posterior approach), (2) Group II (53 patients, direct lateral

approach), and (3) Group III (56 patients, modified anterolateral Watson-Jones approach). The mean duration of follow-up was 65.04 months (range, 24 to 117 months). No patient was lost to follow-up.

Baseline characteristics were similar across the 3 groups (except for a higher female:male ratio in the modified anterolateral Watson-Jones approach group [$p = 0.006$]) (Table I).

Overall, limping rates were low and were not significantly different: 6.98% (3 of 43) for the posterior approach group, 7.55% (4 of 53) for the direct lateral approach group, and 3.57% (2 of 56) for the modified anterolateral Watson-Jones approach group ($p = 0.64$) (Table II). The limping scores were also not significantly different between the 3 groups ($p = 0.33$), and no patient had severe limping (Table II). The Harris hip score, alignment of the acetabular component, and blood loss were not significantly different between the 3 groups, but the modified anterolateral Watson-Jones approach was associated with the longest mean operative time (Table III).

The preoperative and postoperative hip abductor muscle strength was not significantly different between the 3 groups

TABLE III Secondary Outcomes

Variable	Posterior Approach (N = 43)	Direct Lateral Approach (N = 53)	Modified Anterolateral Watson-Jones Approach (N = 56)	P Value
Total Harris hip score* (<i>points</i>)	96.67 ± 4.04 (86-100)	98.01 ± 3.26 (86-100)	97.65 ± 3.08 (88-100)	0.15
Inclination of acetabular component* (°)	42.72 ± 7.01 (29-55)	42.13 ± 6.51 (30-55)	40.34 ± 4.48 (30-52)	0.12
Anteversion of acetabular component* (°)	15.92 ± 5.19 (10-31)	17.29 ± 4.82 (10-28)	17.87 ± 4.65 (13-33)	0.15
Total blood loss* (<i>mL</i>)	718.60 ± 113.40 (500-950)	763.77 ± 116.62 (550-1,050)	774.11 ± 158.01 (600-1,570)	0.10
Operative time* (<i>min</i>)	109.88 ± 10.55 (100-180)	117.55 ± 10.03 (90-140)	124.38 ± 8.04 (110-150)	0.001

*The values are given as the mean and the standard deviation, with the range in parentheses.

TABLE IV Preoperative and Postoperative Hip Abductor Muscle Strength

Strength	Posterior Approach		Direct Lateral Approach		Modified Anterolateral Watson-Jones Approach		P Value*	
	Preop. (N = 43)	Postop. (N = 43)	Preop. (N = 7)	Postop. (N = 53)	Preop. (N = 56)	Postop. (N = 56)	Preop.	Postop.
Grade 5	53.49% (23 hips)	93.02% (40 hips)	57.14% (4 hips)	92.45% (49 hips)	64.29% (36 hips)	96.43% (54 hips)	0.43	0.64
Grade 4	46.51% (20 hips)	6.98% (3 hips)	42.86% (3 hips)	7.55% (4 hips)	35.71% (20 hips)	3.57% (2 hips)	0.41	0.62
Grade 3	0%	0%	0%	0%	0%	0%	NS	NS
Grade 2	0%	0%	0%	0%	0%	0%	NS	NS
Grade 1	0%	0%	0%	0%	0%	0%	NS	NS
Grade 0	0%	0%	0%	0%	0%	0%	NS	NS

*NS = not significant.

(Table IV). The preoperative hip abductor muscle strength of patients with femoral neck fractures was excluded because pain precluded its assessment; therefore, preoperative strength was only assessed for 7 hips that were treated with the direct lateral approach. Patients with femoral neck fractures had the highest rate of limping, but the limping rates and Harris hip scores were not significantly different from those for patients with osteonecrosis, osteoarthritis, and other inflammatory joint diseases ($p = 0.69$ and 0.79 , respectively) (Table V). No postoperative complications such as groin pain, pseudotumors, squeaks, ceramic fractures, pulmonary embolism, deep vein thrombosis, or aseptic loosening of the femoral or acetabular component were seen. However, 2 patients (1 who had had the posterior approach and 1 who had had the direct lateral approach) had infections at the operative site following urinary tract infections and required a 2-stage revision total hip replacement.

Discussion

The prevalence of limping following primary total hip replacement is a controversial topic. Some studies have shown the same prevalence in association with the direct lateral and posterior approaches³⁻⁵, whereas others have shown higher rates in association with the direct lateral approach (range, 11.6%

to 30%)^{1,8,10,16,17} than the posterior approach (0% to 16%)^{1,3,18,19} and the modified anterolateral Watson-Jones approach (0% to 10%)^{2,20}. In the present study, the rate of limping associated with the direct lateral approach (<8%) was similar to that associated with the posterior approach (<7%) and was not significantly different from that associated with the modified anterolateral Watson-Jones approach (<4%).

This study has different results from previous studies for several reasons. First, the procedure described in the present study involved cutting less of the gluteus medius muscle than is the case with the original Hardinge approach¹⁵; therefore, the strength of the gluteus medius would be expected to revert to normal or nearly normal after the operation (Table IV). Second, we excluded patients who had other causes of postoperative limping, including decreased horizontal offset, non-restoration of the center of rotation, limb-length discrepancy, and superior placement of the acetabular component²¹⁻²⁶. Therefore, our data on postoperative limping are specific to the surgical approach.

The present study had some limitations. First, it was a retrospective cohort study, and, as the patients were not randomized, there may have been selection bias. Second, patients with femoral neck fractures were managed with the direct lateral approach, which is associated with postoperative

TABLE V Limping Rate as a Function of Clinical Diagnosis

Limping	Femoral Neck Fracture (N = 46)	Osteoarthritis (N = 40)	Osteonecrosis (N = 56)	Inflammatory Joint Disease (N = 10)	P Value
Limping					
None	91.30% (42 hips)	95% (38 hips)	96.43% (54 hips)	90% (9 hips)	0.78
Slight	4.35% (2 hips)	0%	1.79% (1 hip)	10% (1 hip)	0.23
Moderate	4.35% (2 hips)	5% (2 hips)	1.79% (1 hip)	0%	0.17
Severe	0%	0%	0%	0%	NS†
Any	8.70% (4 hips)	5% (2 hips)	3.57% (2 hips)	10% (1 hip)	0.69
Harris hip subscore* (points)	10.61 ± 1.36 (5-11)	10.69 ± 1.34 (5-11)	10.84 ± 0.89 (5-11)	10.73 ± 0.90 (8-11)	0.79

*The values are given as the mean and the standard deviation, with the range in parentheses. †NS = not significant.

limping. Müller et al. reported higher rates of limping for patients with femoral neck fractures who were managed with a direct lateral approach and also showed that older age appears to be an important factor for limping²⁷. Third, we did not perform magnetic resonance imaging (MRI) or electromyography (EMG) to detect degeneration or rupture of the abductor muscle, although all patients had only mild to moderate limping and no lateral hip pain. The postoperative hip abductor muscle strength was also similar between the 3 groups.

In conclusion, the present study did not reveal significant differences between the 3 approaches in terms of the prevalence of postoperative limping. The direct lateral approach was associated with a low rate of postoperative limping despite

the necessity of cutting the anterior part of the gluteus medius muscle. ■

Boonchana Pongcharoen, MD¹
Kittisak Chaichubut, MD¹

¹Department of Orthopaedic Surgery, Thammasat University, Pathumthani, Thailand

Email address for B. Pongcharoen: boonbigbear@hotmail.com

ORCID iD for B. Pongcharoen: [0000-0001-6907-0224](https://orcid.org/0000-0001-6907-0224)

ORCID iD for K. Chaichubut: [0000-0002-2121-2796](https://orcid.org/0000-0002-2121-2796)

References

- Amlie E, Havelin LI, Furnes O, Baste V, Nordsletten L, Hovik O, Dimmen S. Worse patient-reported outcome after lateral approach than after anterior and posterolateral approach in primary hip arthroplasty. A cross-sectional questionnaire study of 1,476 patients 1-3 years after surgery. *Acta Orthop*. 2014 Sep;85(5):463-9. Epub 2014 Jun 23.
- Masonis JL, Bourne RB. Surgical approach, abductor function, and total hip arthroplasty dislocation. *Clin Orthop Relat Res*. 2002 Dec;405:46-53.
- Barber TC, Roger DJ, Goodman SB, Schurman DJ. Early outcome of total hip arthroplasty using the direct lateral vs the posterior surgical approach. *Orthopedics*. 1996 Oct;19(10):873-5.
- Downing ND, Clark DI, Hutchinson JW, Colclough K, Howard PW. Hip abductor strength following total hip arthroplasty: a prospective comparison of the posterior and lateral approach in 100 patients. *Acta Orthop Scand*. 2001 Jun;72(3):215-20.
- Ritter MA, Harty LD, Keating ME, Faris PM, Meding JB. A clinical comparison of the anterolateral and posterolateral approaches to the hip. *Clin Orthop Relat Res*. 2001 Apr;385:95-9.
- Berry DJ, von Knoch M, Schleck CD, Harmsen WS. Effect of femoral head diameter and operative approach on risk of dislocation after primary total hip arthroplasty. *J Bone Joint Surg Am*. 2005 Nov;87(11):2456-63.
- Bertin KC, Röttinger H. Anterolateral mini-incision hip replacement surgery: a modified Watson-Jones approach. *Clin Orthop Relat Res*. 2004 Dec;429:248-55.
- Horwitz BR, Rockowitz NL, Goll SR, Booth RE Jr, Balderston RA, Rothman RH, Cohn JC. A prospective randomized comparison of two surgical approaches to total hip arthroplasty. *Clin Orthop Relat Res*. 1993 Jun;291:154-63.
- Ji HM, Kim KC, Lee YK, Ha YC, Koo KH. Dislocation after total hip arthroplasty: a randomized clinical trial of a posterior approach and a modified lateral approach. *J Arthroplasty*. 2012 Mar;27(3):378-85. Epub 2011 Jul 28.
- Mukka SS, Sayed-Noor AS. An update on surgical approaches in hip arthroplasty: lateral versus posterior approach. *Hip Int*. 2014 Oct 2;24(24)(Suppl 10):S7-11.
- Baker AS, Bitounis VC. Abductor function after total hip replacement. An electromyographic and clinical review. *J Bone Joint Surg Br*. 1989 Jan;71(1):47-50.
- Harris WH. Traumatic arthritis of the hip after dislocation and acetabular fractures: treatment by mold arthroplasty. An end-result study using a new method of result evaluation. *J Bone Joint Surg Am*. 1969 Jun;51(4):737-55.
- Lewinnek GE, Lewis JL, Tarr R, Compere CL, Zimmerman JR. Dislocations after total hip-replacement arthroplasties. *J Bone Joint Surg Am*. 1978 Mar;60(2):217-20.
- Gibson A. Posterior exposure of the hip joint. *J Bone Joint Surg Br*. 1950 May;32-B(2):183-6.
- Hardinge K. The direct lateral approach to the hip. *J Bone Joint Surg Br*. 1982; 64(1):17-9.
- Ilchmann T, Gersbach S, Zwicky L, Clauss M. Standard Transgluteal versus minimal invasive anterior approach in hip arthroplasty: a prospective, consecutive cohort study. *Orthop Rev (Pavia)*. 2013 Nov 6;5(4):e31.
- Moskal JT, Mann JW 3rd. A modified direct lateral approach for primary and revision total hip arthroplasty. A prospective analysis of 453 cases. *J Arthroplasty*. 1996 Apr;11(3):255-66.
- Ilchmann T. Approaches for primary total hip replacement. *Hip Int*. 2014 Oct 2; 24(24)(Suppl 10):S2-6.
- Vicar AJ, Coleman CR. A comparison of the anterolateral, transtrochanteric, and posterior surgical approaches in primary total hip arthroplasty. *Clin Orthop Relat Res*. 1984 Sep;188:152-9.
- Moore AT. The Moore self-locking vitallium prosthesis in fresh femoral neck fractures: a new low posterior approach (the southern exposure). *Instr Course Lect*. 1959;16:309-21.
- Charles MN, Bourne RB, Davey JR, Greenwald AS, Morrey BF, Rorabeck CH. Soft-tissue balancing of the hip: the role of femoral offset restoration. *Instr Course Lect*. 2005;54:131-41.
- Clark CR, Huddleston HD, Schoch EP 3rd, Thomas BJ. Leg-length discrepancy after total hip arthroplasty. *J Am Acad Orthop Surg*. 2006 Jan;14(1):38-45.
- Fackler CD, Poss R. Dislocation in total hip arthroplasties. *Clin Orthop Relat Res*. 1980 Sep;151:169-78.
- Maloney WJ, Keeney JA. Leg length discrepancy after total hip arthroplasty. *J Arthroplasty*. 2004 Jun;19(4)(Suppl 1):108-10.
- Pellicci PM, Bostrom M, Poss R. Posterior approach to total hip replacement using enhanced posterior soft tissue repair. *Clin Orthop Relat Res*. 1998 Oct;355: 224-8.
- Licini DJ, Burnikel DJ, Meneghini RM, Ochsner JL. Comparison of limb-length discrepancy after THA: with and without computer navigation. *Orthopedics*. 2013 May;36(5):e543-7.
- Müller M, Tohtz S, Dewey M, Springer I, Perka C. Age-related appearance of muscle trauma in primary total hip arthroplasty and the benefit of a minimally invasive approach for patients older than 70 years. *Int Orthop*. 2011 Feb;35(2):165-71. Epub 2010 Dec 2.