



Management of afferent limb obstruction by use of EUS-guided creation of a jejunojejunostomy and placement of a lumen-apposing metal stent

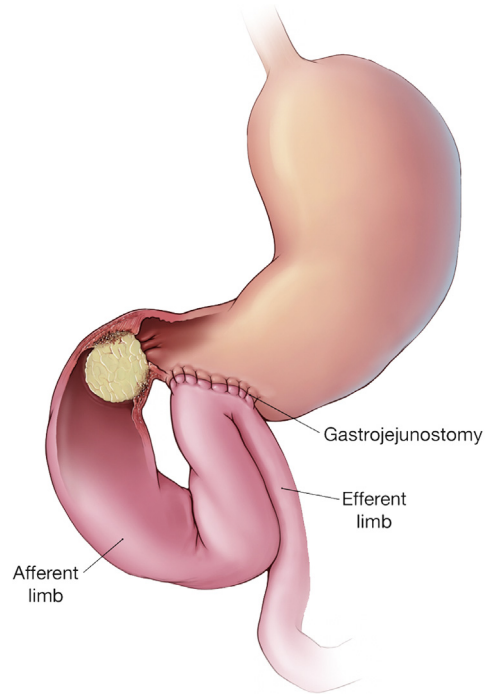
Hassan Ghoz, MD,¹ Carla Foulks, MD,² Victoria Gómez, MD¹

A 49-year-old woman presented with nausea, vomiting, and abdominal pain. Her medical history consisted of a diverting loop gastrojejunostomy performed because of an obstructing mesenteric desmoid tumor and a recent diagnosis of metastatic adenocarcinoma (Fig. 1). Treatment with different chemotherapy regimens had failed.

CT of the abdomen and pelvis revealed an increase in the size of the central mesenteric mass, encasing the superior mesenteric artery branches and occluding the superior mesenteric vein. A resulting dilation of the duodenum, proximal jejunum (Fig. 2), and common bile duct (CBD) (Fig. 3) were noted. Laboratory values were significant for normal total bilirubin, elevated alanine aminotransferase (102 u/L), aspartate aminotransferase (105 u/L), and alkaline phosphatase (404 u/L). The findings were consistent with afferent limb obstruction (ALO).

Treatment options were discussed in a multidisciplinary fashion. Surgery was not an option, given the vascular encasement of the mass. The oncology team and the patient elected for palliative measures. The decision was made to proceed with endoscopic management by use of a lumen-apposing metal stent (LAMS).

On endoscopy, severe mucosal changes were found in the gastric antrum with pyloric obstruction. The



© MAYO CLINIC

Figure 1. Patient's anatomy. © Mayo Foundation for Medical Education and Research. All rights reserved.

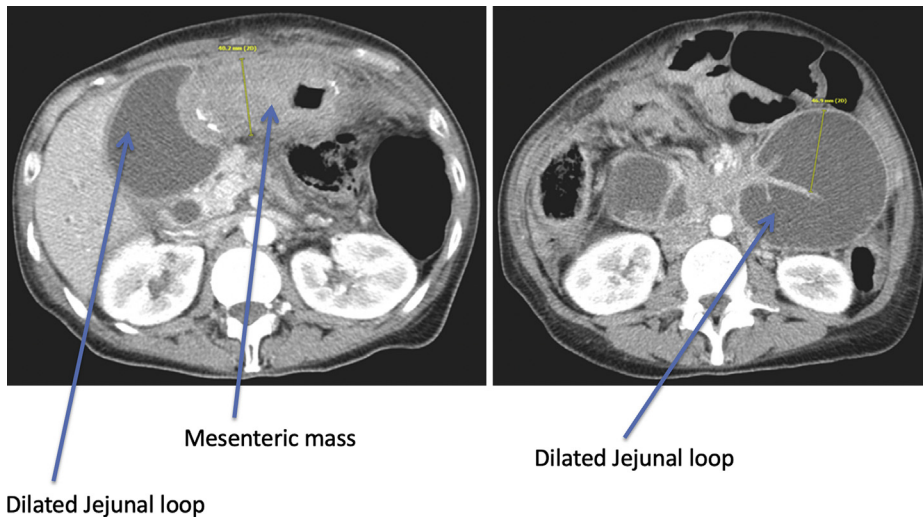


Figure 2. CT scan showing mesenteric soft-tissue mass causing significant obstruction and dilatation of the duodenum and proximal jejunum.

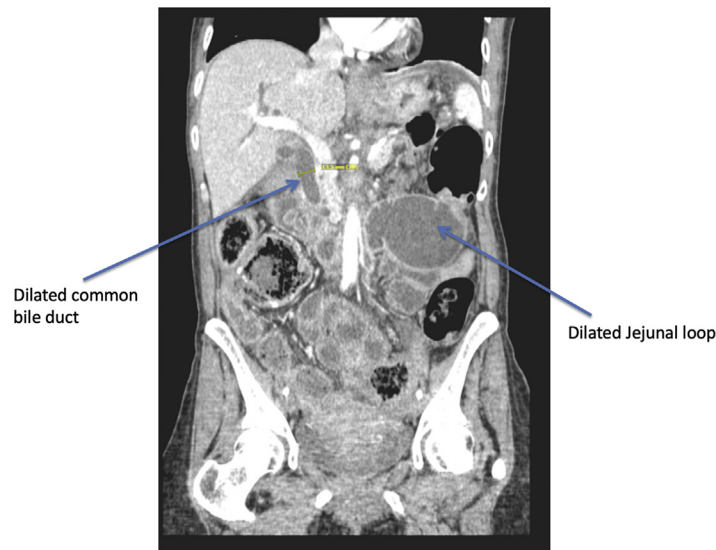


Figure 3. CT scan showing common bile duct measuring 13.5 mm.

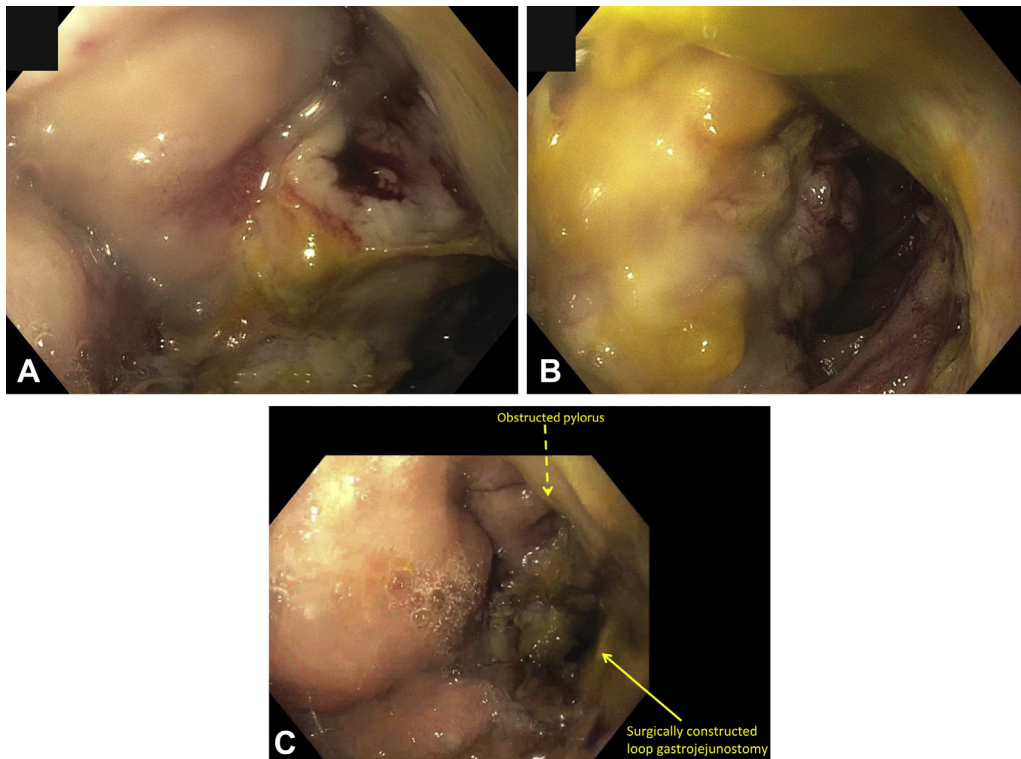


Figure 4. Endoscopic findings of diffuse severe mucosal changes in the gastric antrum. **A**, Blocked afferent limb. **B**, Patent efferent limb. **C**, Obstructed pylorus and surgically constructed gastrojejunostomy.

gastrojejunal anastomosis was congested yet patent and was traversed (Fig. 4). A patent efferent jejunal limb was seen, whereas the afferent limb was obstructed. The decision was made to create a jejunojejunosomy by use of a hybrid technique using EUS, fluoroscopy, and LAMS (Video 1, available online at www.VideoGIE.org).

An appropriate position in the proximal end of the efferent limb was identified, and the common wall

between the jejunum and obstructed jejunum was interrogated with EUS to identify interposing vessels. The jejunum was punctured with a 19-gauge EUS needle. Billious fluid was aspirated, confirming puncture into the afferent limb. A stiff wire was inserted through the needle and into the afferent limb to secure access. The LAMS and electrocautery-enhanced delivery were introduced through the working channel of the echoendoscope and advanced

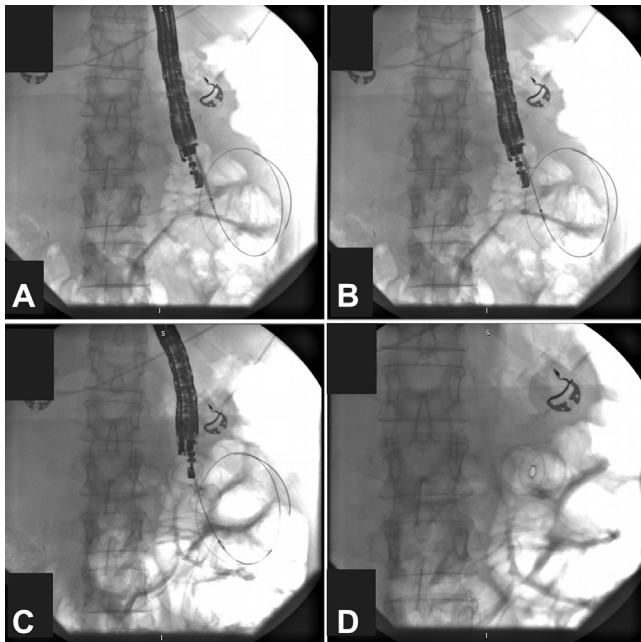


Figure 5. **A**, Advancement of lumen-apposing metal stent (LAMS) into the obstructed limb. **B, C, D**, Placement of 15- × 10-mm LAMS with the flanges in close approximation to the walls of the bowel.

over the guidewire. Under fluoroscopic and EUS guidance, a 15 diameter by 10-mm length LAMS (Axios stent; Boston Scientific, Marlborough, Mass, USA) was deployed to create a jejunojejunostomy (Fig. 5). Biliary fluid extruded into the stomach (Fig. 6). The anatomy after LAMS placement is illustrated in Figure 7.

After the procedure, the patient improved symptomatically, and repeated CT scan confirmed placement of the stent with improvement of duodenal, jejunal, and CBD dilatation (Fig. 8). The patient's diet was advanced, and she was discharged home. She elected not to undergo further treatment for the gastric adenocarcinoma and eventually expired 1 month later.

ALO can occur in both benign and malignant conditions. Often, in patients with extensive malignancy and poor performance status, surgical correction is not a viable option. Endoscopic treatment strategy for ALO needs to be individualized on the basis of anatomy and extent of obstruction. Available treatment options include enteral placement of a self-expanding metallic stent by endoscopic, percutaneous transhepatic, and direct percutaneous approaches.¹ These approaches were not optimal for our patient, given her anatomy and extensive disease burden. Data on the EUS-guided creation of gastroenteric and interenteric anastomoses by the use of self-expanding LAMSs in the treatment of ALO have been emerging.²⁻⁴ EUS-guided enteroenterostomies have multiple advantages, including a relatively short time of deployment and no external drainage material. A multicenter study showed that patients treated with EUS-guided enteroenterostomies required fewer

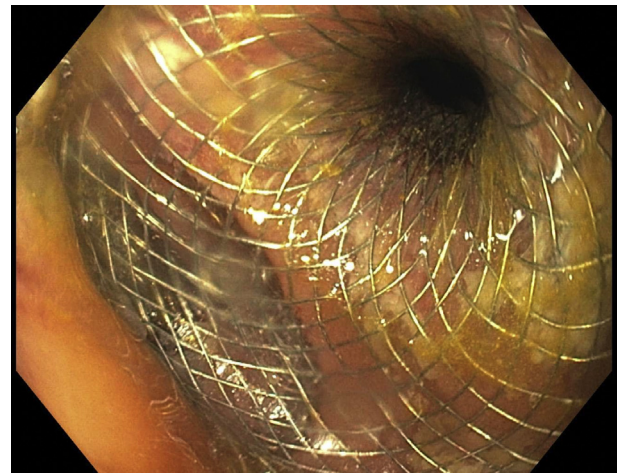
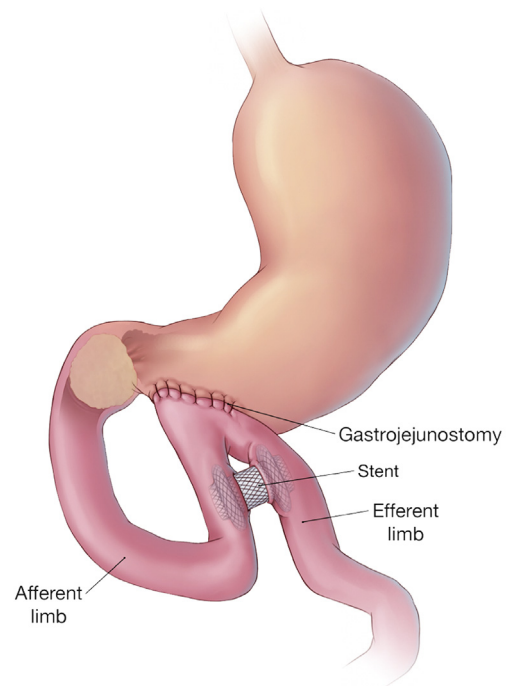


Figure 6. Endoscopic view of lumen-apposing metal stent with bilious fluid extruding into the stomach.



© MAYO CLINIC

Figure 7. Patient's anatomy after placement of lumen-apposing metal stent. © Mayo Foundation for Medical Education and Research. All rights reserved.

reinterventions than did those who had enteroscopy-assisted luminal stent placement.⁵ In that study, EUS-guided gastrojejunostomy was more common than jejunojejunostomy in treating ALO, although it must be borne in mind that 70% of the patients had a prior pancreaticoduodenectomy.

Our case is unique in that we have demonstrated palliation of ALO through a loop gastrojejunostomy using EUS-guided creation of a jejunojejunostomy with a LAMS.

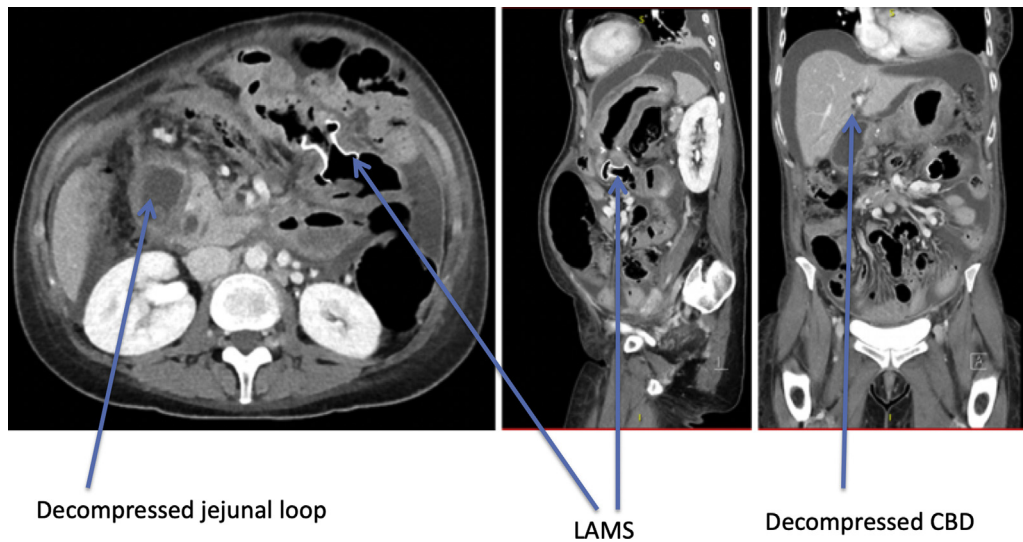


Figure 8. CT scan showing placement of lumen-apposing metal stent (LAMS) with interval improvement of jejunal dilatation and of common bile duct (CBD) dilation.

DISCLOSURE

All authors disclosed no financial relationships relevant to this publication.

Abbreviations: ALO, afferent limb obstruction; CBD, common bile duct; LAMS, lumen-apposing metal stent.

REFERENCES

1. Blouhos K, Boulas KA, Tsalis K, et al. Management of afferent loop obstruction: reoperation or endoscopic and percutaneous interventions? *World J Gastrointest Surg* 2015;7:190-5.
2. Ikeuchi N, Itoi T, Tsuchiya T, et al. One-step EUS-guided gastrojejunostomy with use of lumen-apposing metal stent for afferent loop syndrome treatment. *Gastrointest Endosc* 2015;82:166.
3. Jurgensen C, Wentrup R, Zeitz M. Endoscopic ultrasound (EUS)-guided transduodenal drainage of an obstructed jejunal loop after

hepaticojejunostomy as treatment for recurrent biliary sepsis. *Endoscopy* 2013;45:E40-1.

4. Matsumoto K, Kato H, Tomoda T, et al. A case of acute afferent loop syndrome treated by transgastric drainage with EUS. *Gastrointest Endosc* 2013;77:132-3.
5. Brewer Gutierrez OI, Irani SS, Ngamruengphong S, et al. Endoscopic ultrasound-guided entero-enterostomy for the treatment of afferent loop syndrome: a multicenter experience. *Endoscopy* 2018;50:891-5.

Division of Gastroenterology and Hepatology, Section of Advanced Endoscopy, Mayo Clinic, Jacksonville, Florida, USA (1); Division of General Internal Medicine, Mayo Clinic, Jacksonville, Florida, USA (2).

Copyright © 2019 American Society for Gastrointestinal Endoscopy. Published by Elsevier Inc. This is an open access article under the CC BY-NC-ND license (<http://creativecommons.org/licenses/by-nc-nd/4.0/>).

<https://doi.org/10.1016/j.vgie.2019.05.001>