



REVIEW

# Merging into the mainstream: the evolution of the role of point-of-care musculoskeletal ultrasound in hemophilia [version 1; peer review: 2 approved]

Nihal Bakeer , Amy D Shapiro 

Indiana Hemophilia and Thrombosis Center, 8326 Naab Road, Indianapolis, IN, 46260, USA

**v1** **First published:** 09 Jul 2019, 8(F1000 Faculty Rev):1029 (<https://doi.org/10.12688/f1000research.16039.1>)  
**Latest published:** 09 Jul 2019, 8(F1000 Faculty Rev):1029 (<https://doi.org/10.12688/f1000research.16039.1>)

**Abstract**

Bleeding with resultant hemophilic arthropathy constitutes the largest cause of morbidity in patients with hemophilia. It results from repeated bleeding episodes in the joint and is characterized by synovial hypertrophy and cartilage and bony destruction. Hemophilic arthropathy assessment is a continually evolving process and is particularly challenging in children and young adults in whom joint disease may be missed or underestimated as obtaining serial “baseline” magnetic resonance imaging scans of multiple clinically asymptomatic or nearly asymptomatic joints may be unjustifiable and cost-ineffective. Musculoskeletal ultrasound—particularly, point-of-care musculoskeletal ultrasound—has emerged as a promising imaging modality for the early detection and management of hemophilic arthropathy, and for the evaluation of hemarthrosis and painful musculoskeletal episodes in patients with hemophilia. This review summarizes currently available data on the emerging role of this new imaging modality, its limitations, and gaps in knowledge. The review also raises unanswered questions, highlights the need for consolidated research efforts, and delineates future directions expected to advance this technology and optimize its use in this patient population.

**Keywords**

Hemophilic arthropathy, joint disease, hemophilia, musculoskeletal ultrasound, point-of-care ultrasound, hemarthrosis, synovitis

**Open Peer Review**

**Reviewer Status**  

	Invited Reviewers	
	1	2
<b>version 1</b> published 09 Jul 2019		

F1000 Faculty Reviews are written by members of the prestigious F1000 Faculty. They are commissioned and peer reviewed before publication to ensure that the final, published version is comprehensive and accessible. The reviewers who approved the final version are listed with their names and affiliations.

- 1 **Alok Srivastava**, Christian Medical College, Vellore, India
- 2 **Felipe Querol**, University of Valencia, Valencia, Spain

Any comments on the article can be found at the end of the article.

**Corresponding author:** Nihal Bakeer ([nbakeer@ihtc.org](mailto:nbakeer@ihtc.org))

**Author roles:** **Bakeer N:** Writing – Original Draft Preparation; **Shapiro AD:** Writing – Review & Editing

**Competing interests:** No competing interests were disclosed.

**Grant information:** The author(s) declared that no grants were involved in supporting this work.

**Copyright:** © 2019 Bakeer N and Shapiro AD. This is an open access article distributed under the terms of the [Creative Commons Attribution Licence](#), which permits unrestricted use, distribution, and reproduction in any medium, provided the original work is properly cited.

**How to cite this article:** Bakeer N and Shapiro AD. **Merging into the mainstream: the evolution of the role of point-of-care musculoskeletal ultrasound in hemophilia [version 1; peer review: 2 approved]** F1000Research 2019, 8(F1000 Faculty Rev):1029 (<https://doi.org/10.12688/f1000research.16039.1>)

**First published:** 09 Jul 2019, 8(F1000 Faculty Rev):1029 (<https://doi.org/10.12688/f1000research.16039.1>)

## Introduction

Hemophilia A and B are X-linked congenital bleeding disorders characterized by reduced or absent levels of coagulation factors VIII or IX, respectively. The disease is classified, on the basis of residual coagulation factor activity level, as severe (<1%), moderate (1–5%), or mild (5–40%). Spontaneous hemarthrosis is the hallmark of severe hemophilia, and hemophilic arthropathy (HA), characterized by synovial hypertrophy and cartilage and bony destruction, which ultimately results from repeated joint bleeding episodes<sup>1</sup>. The musculoskeletal consequences of hemophilia constitute the largest cause of morbidity in persons with hemophilia (PwH)<sup>2</sup>; musculoskeletal disease may be minimized by early initiation of prophylaxis yet has continued to occur<sup>3–9</sup>, and a single episode of hemarthrosis can impact long-term joint outcomes<sup>10,11</sup>. There is evidence that the key processes involved in the pathogenesis of HA include intra-articular inflammation, mediated by hemoglobin release, iron deposition, cytokines, hydroxyl radicals, and the “inflammasome”, and neo-angiogenesis, mediated by pro-angiogenic factors such as vascular endothelial growth factor<sup>12,13</sup>. However, the pathophysiology of HA remains incompletely understood, and the pathways are yet to be fully elucidated. HA remains a critical focus of research and study as this debilitating disease negatively impacts quality of life, physical activity, and bone health of the aging PwH population, whose life span is now comparable to that of the normal population<sup>3,4,14–16</sup>. A gap continues to exist in our ability to detect and impact this sequela at the pre-clinical or asymptomatic phase when the disease process is early and potentially reversible.

## Evaluation of hemophilic arthropathy

Evaluation of HA is a dynamic, multi-dimensional process which employs clinical outcome assessment tools, including the World Federation of Hemophilia Physical Examination Score (Gilbert score), the hemophilia joint health score (HJHS)<sup>17–19</sup>, and a number of imaging modalities<sup>20,21</sup>. X-ray grading systems/scores include the Arnold–Hilgartner score (progressive, soft tissue assessment included)<sup>22</sup> and the World Federation of Hemophilia–recommended and widely used Pettersson score (additive, soft tissue excluded)<sup>23</sup>. X-rays are widely available and may capture advanced joint changes but are insensitive to early change and unreliable for cartilage and soft tissue evaluation<sup>1</sup>. These limitations necessitated the development of a number of HA scoring systems using joint magnetic resonance imaging (MRI)<sup>24–26</sup>. The most widely used, developed in 2012 by the International Prophylactic Study Group (IPSG), merges two scales of a combined MRI scoring scheme into a single scale<sup>27</sup>. This scale, which includes soft tissue and osteochondral sub-scores, proved useful for the analysis of both early and moderate stages of arthropathy, comparison among different studies and patient populations, and the evaluation of prophylactic factor infusion regimens. To date, joint MRI remains the gold standard for the evaluation of HA, providing a comprehensive multi-tissue evaluation with sensitivity to detect early joint pathology and changes over time<sup>26–29</sup>. However, MRI is time-consuming, expensive, not consistently readily accessible, and may require sedation in young children. MRI also detects a large number of minor changes over time, not all of which are necessarily

clinically meaningful, and their impact on joint outcomes has yet to be determined<sup>29,30</sup>. Therefore, obtaining serial “baseline” MRI scans of multiple clinically asymptomatic or nearly asymptomatic joints of children and young adults, may be unjustifiable and rather cost-ineffective. Conversely, if joint evaluation is restricted to clinically manifest joint disease, early arthropathic changes in this patient population will be missed without consistent sensitive monitoring.

## Musculoskeletal ultrasound in hemophilia

It is not surprising—given its accessibility, wide availability, safety, efficiency, low cost of examination, and lack of interference of susceptibility artifacts on gradient-echo MRI sequences in joints with hemosiderin deposition, including the “blooming” effect<sup>28</sup>—that musculoskeletal ultrasound (MSKUS), particularly point-of-care MSKUS (POC-MSKUS), has emerged as a promising imaging modality for the early detection and management of HA<sup>19,30–36</sup> and for the evaluation of hemarthrosis and painful musculoskeletal episodes in PwH<sup>37–40</sup>. MSKUS can provide a detailed and dynamic assessment of synovial joints and periarticular structures, including tendons, ligaments, and muscles, using high-resolution, high-frequency transducers (3.5–15 MHz) with power Doppler (PD) imaging. As this imaging modality gained attention, so did the debate and controversy about its reliability, diagnostic accuracy, and ultimately impact on joint outcomes in PwH<sup>1,33,41,42</sup>, but an important distinction to make prior to critically reviewing the role of MSKUS in the evaluation of HA is that between full-joint MSKUS and POC-MSKUS. Full-joint MSKUS is a 360° assessment of the joint, using all standard scanning planes, and is performed by expert radiologists and ultrasonographers. POC-MSKUS is a focused evaluation of the joint, using limited scanning planes or an abbreviated scanning protocol, and is usually carried out by trained clinicians at the patient’s bedside to answer specific yes–no questions about the status of the joint.

Compared with conventional MRI in the evaluation of hemarthrosis, MSKUS was found to be extremely sensitive in detecting low concentrations of intra-articular blood (as low as 5%) and in discriminating between bloody and non-bloody (serous/simple) fluid<sup>43</sup>, making it useful in determining the etiology of acute painful musculoskeletal episodes in PwH as arthritis-mediated or bleed-related<sup>37,38</sup>. Radiographic biomarkers of HA include both soft tissue changes and osteochondral abnormalities, both of which can be detected with variable accuracy by MSKUS<sup>32,33,42,44,45</sup>. In 2014, in an observational descriptive study, Sierra Aisa *et al.* showed that MSKUS is useful in detecting joint bleeds, synovial hyperplasia, and joint erosions, and the results were comparable to those of joint MRI, but MRI better detected bone cysts and cartilage loss<sup>42</sup>. Similarly, in 2015, Doria *et al.* conducted a cross-sectional study to assess the reliability of interpretation of MSKUS findings according to data blinding in maturing hemophilic joints (knees and ankles) and to determine the diagnostic accuracy of MSKUS compared with MRI for assessing joint components<sup>41</sup>. The authors concluded that, if performed by experienced radiologists using a standardized protocol, MSKUS is highly reliable to assess soft tissue abnormalities (synovial hypertrophy and hemosiderin deposition)

in ankles and knees, and substantially to highly reliable to assess osteochondral changes in these joints, with high sensitivity to diagnose erosions and cartilage loss, regardless of the severity of arthropathy, and poor sensitivity and negative predictive values for depicting subchondral cysts in advanced disease.

Unique to MSKUS, PD imaging allows the evaluation of synovitis by measuring synovial thickness and hypervascularity, which correlates well with the significantly more expensive dynamic contrast-enhanced MRI in hemophilic joints<sup>13,46</sup>. PD imaging is valuable as vascular remodeling and angiogenesis are known to contribute significantly to bleed propagation and development of HA as shown in human and mouse studies<sup>46–50</sup>. There is evidence that increased PD signals at baseline correlate with acute pain and more bleeding episodes and that PD signals significantly increase at the time of acute bleeding<sup>38</sup>.

The most comprehensive systematic review and semi-quantitative assessment of currently available evidence on the value of MSKUS in the assessment and management of HA in children and adults with hemophilia and von Willebrand disease were provided by Ligocki *et al.* in 2017<sup>51</sup>. The review included 20 articles investigating either the diagnostic accuracy of MSKUS and/or MSKUS scanning protocols and scoring systems for the assessment of HA. Two independent reviewers evaluated 14 retrospective cross-sectional studies examining the diagnostic accuracy of MSKUS in the assessment of HA in children and adults<sup>10,37,38,41,42,44,46,52–58</sup>, both for reporting quality using the Standards for Reporting of Diagnostic Accuracy (STARD) tool and for methodological quality using the Quality Assessment of Diagnostic Accuracy Studies 2 (QUADAS-2) tool. With STARD, 1 out of 14 and 8 out of 14 studies were scored to be

of high and moderate reporting quality, respectively. Assessment with QUADAS-2 reported 2 out of 14 and 6 out of 14 studies as having high and moderate methodological quality, respectively. The remainder of the studies were scored as low or very low. These studies were also assessed for outcome measures from three clinimetric constructs (construct validity, criterion validity, and reliability) as follows: (1) clinical joint assessment tools: Gilbert and IPSP scores<sup>17,24,59</sup>; (2) radiographic scores: Arnold and Hilgartner<sup>22</sup> and Pettersson<sup>23</sup>; and (3) MSKUS measures: Muça-Perja *et al.* progressive score<sup>31</sup> and five other additive scores by Klukowska *et al.*<sup>53</sup>, Querol *et al.*<sup>60</sup>, Melchiorre *et al.*<sup>10</sup>, Martinoli *et al.*<sup>45</sup>, and Doria *et al.*<sup>41</sup>.

Six studies that described MSKUS scoring systems<sup>10,31,41,45,53,60</sup> were included in the review and the authors divided the parameters of the ultrasound scoring systems into soft tissue changes (hemarthrosis/effusion, hemosiderin deposition, synovial hypertrophy and/or reaction and fibrotic septa) and osteochondral abnormalities (bone erosion, osteophytes, subchondral cysts, bone remodeling, and cartilage damage). The only parameter proposed in all scoring systems was synovial hypertrophy.

Five grey-scale ultrasound scanning protocols were included in this review<sup>45,60–63</sup>. With the exception of Martinoli's POC protocol<sup>64</sup>, PD evaluation of soft tissue vascularity was suggested by all remaining full-joint diagnostic protocols. The only other POC protocol evaluated in this review was that of Ceponis *et al.*<sup>38</sup>. The protocols of both Martinoli *et al.* and Ceponis *et al.* aim to simplify the scanning technique for elbows, ankles, and knees so they can be applied by clinical providers at the bedside without requiring radiologists or radiology technicians. Items included in a number of MSKUS scanning protocols and scoring systems used in the assessment of HA are shown in Table 1<sup>33</sup>.

**Table 1. Items included in different scanning protocols and scoring systems for ultrasound assessment of hemophilic arthropathy.**

Authors	Effusion (synovial fluid or hemarthrosis)	Synovial hypertrophy	Synovial hyperemia	Hemosiderin deposition	Cartilage abnormalities (cartilage loss, hyperechogenicity, thinning)	Bone abnormalities (erosion, subchondral cysts, osteophytes)	Evaluated joints
Klukowska <i>et al.</i> <sup>53</sup> (2001)	Yes	Yes	Yes	No	Yes	Yes	Knee
Zukotynski <i>et al.</i> <sup>61</sup> (2007)	Yes	Yes	No	Yes	Yes	Yes	Knee, ankle
Melchiorre <i>et al.</i> <sup>10</sup> (2011)	Yes	Yes	No	Yes	Yes	Yes	Elbow, knee, ankle
Muça-Perja <i>et al.</i> <sup>31</sup> (2012)	No	Yes	Yes	No	Yes	Yes	Knee, ankle
Martinoli <i>et al.</i> <sup>45</sup> (2013)	Yes <sup>a</sup>	Yes	No	No	Yes	Yes	Elbow, knee, ankle
Kidder <i>et al.</i> <sup>37</sup> (2015)	No	Yes	Yes	No	Yes	Yes	Elbow, knee, ankle, hip, shoulder

<sup>a</sup>The presence of intra-articular effusion is included in the scanning protocol but owing to its fluctuating nature is not considered in the scoring system. Reproduced with permission from Thieme<sup>33</sup>.

The score proposed by Doria *et al.*<sup>41</sup>, not shown in the table but included in the systematic review, is an ultrasound-based imaging scale with an additive score (0–14) that was adjusted to the subscores of the IPSPG MRI scale (0–17)<sup>27</sup>. To enable correspondence between ultrasound and IPSPG MRI scores, items that are not technically feasible by ultrasound, including surface erosions, subchondral cysts, and full-thickness loss of joint cartilage in at least half of the joint surface were excluded<sup>41,65</sup>.

The authors of this very valuable systematic review<sup>51</sup> concluded that there is currently fair evidence (grade B) to recommend MSKUS as an accurate technique for the early diagnosis of HA (with particular regard to soft tissue abnormalities), to demonstrate that MSKUS scores correlate with clinical/ultrasound constructs, and to prove an association between MSKUS findings and functional joint status. However, there is still insufficient evidence (grade I) to conclude that MSKUS-detectable findings are responsive or sensitive to changes in prophylactic therapy in children or adults with HA. The evidence was insufficient in both quality and quantity.

### A new wave in the evaluation of hemophilic arthropathy

Over the last decade, POC-MSKUS has emerged as a critical tool in the evaluation of hemarthrosis and painful musculoskeletal episodes in PwH<sup>32,37–40,66,67</sup>. One group, Ceponis *et al.*, demonstrated that hemarthrosis was present in only one third of acute painful joints<sup>38</sup> and that disappointingly about two thirds of painful musculoskeletal episodes were judged incorrectly by either the patient or physician. POC-MSKUS findings changed the management in more than 70% of episodes, which resulted in symptom improvement in more than two thirds of the cases. Wider use of POC-MSKUS may serve to substantiate these data. Furthermore, with appropriate training, POC-MSKUS has been increasingly used as part of the bedside evaluation of muscle hematomas in PwH<sup>68,69</sup> and for ultrasound-guided joint aspiration and intra-articular corticosteroid injection for symptomatic relief and pain control in PwH and chronic joint pain secondary to advanced HA<sup>70,71</sup>. A very recent article by De la Corte-Rodríguez *et al.* showed that arthrocentesis carried out immediately after the diagnosis of acute hemarthrosis in strictly aseptic conditions and under hemostatic coverage was well tolerated and accelerated joint recovery<sup>72</sup>. Lastly, Rezende *et al.* demonstrated that joint lavage followed by injections of triamcinolone and Hylan G-F 20 (viscosupplement) improved balance, function, and bleeding events in patients with severe HA<sup>73</sup>, and Li *et al.* suggest that a single intra-articular platelet-rich plasma injection results in better improvement in pain relief, joint function, and reduced synovial hyperemia when compared with five weekly intra-articular injections of hyaluronic acid in patients with HA of the knee<sup>74</sup>.

Since the systematic review by Ligocki *et al.*<sup>51</sup>, the “Joint Activity and Damage Exam” (JADE) POC scanning and scoring protocol has been developed and validated by Volland *et al.*<sup>75</sup> as the first quantitative POC-MSKUS algorithm for precise measurements in hemophilic joints of adult PwH. The protocol evaluates for effusions and measures osteochondral surface defects,

cartilage thickness, soft tissue expansion, and microvascular perfusion abnormalities on PD for ankles, elbows, and knees. Validation studies showed high intra-/inter-rater reliability, which the authors hope would allow easy quantification of the progression of HA. To date, a similar quantitative POC-MSKUS protocol for children with hemophilia has not been proposed, and the semi-quantitative Hemophilia Early Arthropathy Detection with UltraSound (HEAD-US) POC protocol of Martinoli *et al.*<sup>64</sup> remains the most widely used in this patient population for the early detection of HA<sup>45,64,76</sup>. The protocol has an additive score to a maximum score of 8 for synovial hypertrophy and cartilage and bony changes. Joint effusions are excluded from the HEAD-US score, and PD imaging is not carried out as part of the scanning protocol; validation studies of the additive HEAD-US score have not yet been published. Although the protocol has its limitations, its few to no measurements, short learning curve, and proposed examination times of less than 2 to 5 minutes per joint are attractive to busy clinicians and physical therapists in the outpatient setting. The authors propose that a six-joint baseline scan of bilateral elbows, knees, and ankles can be completed within 30 minutes and this protocol has demonstrated good reliability when performed by clinicians and non-radiologists after only limited training<sup>77–79</sup>. Furthermore, HEAD-US scores correlated well with HJHS for the elbows, knees, and ankles, and the correlation coefficient was as high as  $r = 0.70$  ( $P < 0.01$ ) in one study<sup>56</sup>. In a more recent series by De la Corte-Rodríguez *et al.*<sup>80</sup>, 14% of patients exhibited HEAD-US signs of early HA in joints without reported bleeds and an HJHS 2.1 score of 0. The authors concluded that, in their experience, the HEAD-US scanning and scoring protocol was superior to bleeding history and HJHS 2.1 score in the early detection of HA. The right ankle was the most severely involved joint in this report. These findings were supported by several other studies highlighting the sensitivity and utility of HEAD-US score in the early detection of HA as compared with HJHS or physical exam alone<sup>64,81–83</sup>.

The diagnostic accuracy of the HEAD-US, POC-MSKUS protocol for the detection of HA biomarkers, compared with joint MRI, was recently evaluated by Foppen *et al.*<sup>84</sup>. HEAD-US was found to be able to accurately assess the presence/absence of synovial hypertrophy in joints of PwH with a positive predictive value of 94% (confidence interval (CI) 73–100%) and a negative predictive value of 97% (CI 91–100%). The HEAD-US and IPSPG MRI scores had a strong correlation of  $r = 0.90$  ( $P < 0.01$ ) for the severity of synovial hypertrophy as well. These findings are very promising since synovial hypertrophy is associated with an increased risk of bleeding<sup>85</sup> and may be responsive to treatment<sup>86</sup>; early detection with POC-MSKUS may allow customization and personalization of treatment regimens for PwH in the clinic as they actively participate in the scanning process and review findings in “real time” with their clinical providers.

The overall diagnostic accuracy of HEAD-US for synovial hypertrophy detection was 97% but was not as high for osteochondral surface abnormalities and this is similar to what was described for full-joint MSKUS in the past<sup>41,42</sup>. Limited



penetration power of the ultrasound beam means that most of it is reflected over the bony surfaces and the evaluation is limited primarily to peripheral joint surfaces; POC-MSKUS can provide only a general idea of the osteochondral surface and whether cartilage and bony alterations are present or absent. MRI is still the best imaging modality for the detailed evaluation of osteochondral derangements in HA, particularly those pertaining to the central aspect of the cartilage and subchondral bone evaluation<sup>33,41,61,65,87</sup>.

### Gaps in knowledge and Future directions

POC-MSKUS promises to improve our workflow, eliminating the need for sedation in children and allowing the early detection of HA in its subclinical stage; several gaps in knowledge continue to exist and questions remain unanswered. A number of scanning/scoring protocols<sup>10,31,33,41,45,53,60,75</sup> have become available, but they have not been globally standardized or validated, limiting their widespread use and implementation for that purpose. To achieve this goal, we need to reach a consensus regarding which sonographic biomarkers of HA should be included in the POC-MSKUS score(s) and what the POC-MSKUS definitions of pathologic conditions are<sup>88</sup>. POC-MSKUS and full-joint MSKUS scanning and scoring protocols should be compared, standardized, and evaluated against the reference standard (MRI) before they are globalized. As POC-MSKUS has long been used in rheumatology, following Outcome Measures in Rheumatology (OMERACT) guidelines when developing new imaging modalities for arthritic conditions would prove beneficial<sup>88-90</sup>. Well-designed longitudinal cohort studies to evaluate the value of ultrasound in the early detection of HA and its clinical impact on treatment strategies and prophylactic regimens are urgently needed<sup>51</sup>, as are guidelines and recommendations for necessary training and appropriate use and implementation of POC-MSKUS as a diagnostic tool in PwH<sup>91</sup>.

The highly operator-dependent nature of ultrasound justifies the initial skepticism it was met with and necessitates rigorous operator training to avoid misuse and misdiagnosis<sup>69,91</sup>. Currently, formal certification in MSKUS scanning is not required to implement POC-MSKUS in clinical practice, but resources are available and could be used to achieve this end. The need for additional and/or special training in POC-MSKUS scanning becomes evident when evaluating pediatric patients, muscle injuries, and other joints (hips and shoulders). When a pediatric joint is scanned, a sophisticated understanding of the immature skeleton, appearance of growth plates, secondary ossification centers, and areas with abundant normal periarticular fat is key<sup>65</sup>. The paucity of available literature coupled with the need for specialized training and challenges in image acquisition in the more active and often less cooperative pediatric patient contributed to the underutilization of this technique for assessing pediatric joints in both research and clinical practice. Atlases on expected soft tissue and epiphyseal cartilage thickness and vascularization, and normal ossification of the joints of maturing healthy children are needed<sup>92-95</sup>. Awareness of normal variation and contralateral comparison with the other joint, if normal, are helpful. If POC-MSKUS does not provide an answer, referral for a full-joint MSKUS or other imaging modalities such as MRI and plain x-ray should be made<sup>65,87,91</sup>.

Additionally, it is important to note that although MSKUS can readily distinguish between fluid and soft tissue<sup>10,32,37,38,43</sup>, MSKUS remains less sensitive in soft tissue discrimination (fat versus synovium) and in detecting hemosiderin, which remains debatable and controversial<sup>49,96</sup>; some studies describe distinctive echotextural features distinguishing hemosiderin from synovium<sup>10,41,61</sup> and others do not find a difference in the sonographic appearance of hemosiderin-laden and hemosiderin-free synovium<sup>96,97</sup>. MSKUS unreliability/inability to detect hemosiderin deposition in the synovium of PwH will compromise its ability to detect “microbleeds”, an almost decade-old concept that refers to asymptomatic or subclinical leakage of microscopic amounts of blood into a joint hypothesized to contribute to deterioration of the joint without clinical evidence of hemarthrosis<sup>2,44,56,80,81,98</sup>. Although we do not currently have direct evidence that joint microbleeding occurs in PwH, this does not mean that it does not exist! In a very recent review, Puetz<sup>98</sup> sheds some light on this topic and argues that medical imaging findings in joints free of clinically evident bleeds and symptoms (MIFFS) constitute a significant clinical issue that deserves appropriate investigation; assuming that MIFFS in PwH are directly related to or caused by microbleeds (or vice versa) can lead to unnecessary, or ineffective medical treatment.

Lastly, the value of three-dimensional ultrasound and the newer advances in ultrasound technology in the evaluation of HA has yet to be determined. Currently, most scoring protocols are semi-quantitative. Do we foresee a future where artificial intelligence algorithms automate the quantification and assessment of soft tissue proliferation, cartilage thickness loss, degree of bony derangement, and hypervascularity making the process less operator-dependent and time-consuming?

### Closing remarks

Continued innovative development and widespread utilization of POC-MSKUS are expected over the next few years. The dynamic, timely, beneath-the-surface evaluation of hemophilic joints at the bedside using POC-MSKUS as an adjunct to physical examination is invaluable and ultimately will not only result in a more refined understanding of the pathophysiology of HA and natural course of the disease but also enhance patient/parent compliance and adherence to treatment regimens for both acute injuries and prophylaxis. POC-MSKUS can provide visual evidence of joint health which can be used as a motivational tool for prophylaxis-reluctant or non-adherent patients at visits to their hemophilia treatment centers<sup>4,99-101</sup>.

In the recently published IPSPG survey of the use of ultrasound for assessment of musculoskeletal disease in PwH<sup>102</sup>, POC-MSKUS was most often performed by a physiotherapist (53%) or a hematologist (43%) and was perceived as most useful to confirm an acute joint bleed and the presence of synovial hypertrophy. The greatest perceived barriers to the implementation were lack of trained health-care professionals and the overall time commitment required to perform the exam<sup>102</sup>.

Recently, Zhou *et al.* explored the potential of a pocket-sized handheld ultrasound device for the evaluation of joint

effusions and hemarthrosis in hemophilia<sup>103</sup>. The image quality of the handheld ultrasound device was deemed sufficient to identify joint landmarks necessary to accurately localize effusions, and the device was promising to be both feasible and reliable even when performed by non-experts (such as medical students) after a brief training period<sup>103</sup>. Perhaps it is possible to envision a future where patients are equipped with handheld ultrasound devices, but important questions remain to be resolved. Would this allow more efficient use of factor products and improved adherence to prophylactic regimens or false reassurance by false-negative scans and subsequent undertreatment? Will POC-MSKUS finally provide us with an objective rather than subjective annualized bleeding rate, allowing a more accurate comparison of the hemostatic effect of different factor products and newer non-factor therapies, or will it leave our patients feeling unheard? Is POC-MSKUS going to fuel the microbleed debate? Can POC-MSKUS accurately detect microbleeding and differentiate acute on top of chronic bleeding episodes in persistently hemorrhagic target joints? Where do POC-MSKUS and pocket handheld devices fit into personalized treatment strategies and outcome measures<sup>104,105</sup>? Finally, will ultrasounds bridge the physical distance between patients and their hemophilia treatment centers, allowing them to have a more objective evaluation of their acute musculoskeletal painful episodes remotely, or will it result in non-compliance with poor follow-up when the home scans reassure against progressive joint disease and the perceived role of the clinical exam is lost?

POC-MSKUS is very promising, yet we should acknowledge the need for formal training, attaining and maintaining competence, quality assurance, and understanding its appropriate use<sup>91</sup>. International consensus guidelines and recommendations for use should be established to allow the effective implementation and utilization of this imaging modality in hemophilia. Studies to evaluate the feasibility of implementation and time needed to complete scans for both the evaluation of acute musculoskeletal concerns and longitudinal joint disease monitoring are needed. Frequency of six-joint surveillance ultrasound needs to be established for asymptomatic, near-asymptomatic, and target joints. Objective evidence highlighting the limitations of POC-MSKUS should be provided. What POC-MSKUS can and cannot do should be clearly disclosed to patients/parents, and when the question posed is not answered, the referral to a diagnostic imaging department and an experienced musculoskeletal radiologist for either a full-joint MSKUS or a different imaging modality should be made. As beautifully stated by Lawson *et al.*, “point-of-care ultrasound should be respected for the complexity of the technology and the skill required to interpret it”<sup>91</sup>. Only then will we avoid misdiagnosis and misuse.

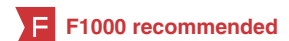#### Author contributions

NB prepared the original review and AS reviewed and edited it.

#### Grant information

The author(s) declared that no grants were involved in supporting this work.

## References




- Wyseure T, Mosnier LO, von Drygalski A: **Advances and challenges in hemophilic arthropathy**. *Semin Hematol*. 2016; **53**(1): 10–9.  
[PubMed Abstract](#) | [Publisher Full Text](#) | [Free Full Text](#)
- Manco-Johnson MJ, Abshire TC, Shapiro AD, *et al.*: **Prophylaxis versus episodic treatment to prevent joint disease in boys with severe hemophilia**. *N Engl J Med*. 2007; **357**(6): 535–44.  
[PubMed Abstract](#) | [Publisher Full Text](#)
- F** Mazepa MA, Monahan PE, Baker JR, *et al.*: **Men with severe hemophilia in the United States: birth cohort analysis of a large national database**. *Blood*. 2016; **127**(24): 3073–81.  
[PubMed Abstract](#) | [Publisher Full Text](#) | [Free Full Text](#) | **F1000 Recommendation**
- Young G: **New challenges in hemophilia: long-term outcomes and complications**. *Hematology Am Soc Hematol Educ Program*. 2012; **2012**: 362–8.  
[PubMed Abstract](#)
- Schramm W, Gringeri A, Ljung R, *et al.*: **Haemophilia care in Europe: the ESCHQoL study**. *Haemophilia*. 2012; **18**(5): 729–37.  
[PubMed Abstract](#) | [Publisher Full Text](#)
- Kumar R, Dunn A, Carcao M: **Changing Paradigm of Hemophilia Management: Extended Half-Life Factor Concentrates and Gene Therapy**. *Semin Thromb Hemost*. 2016; **42**(1): 18–29.  
[PubMed Abstract](#) | [Publisher Full Text](#)
- Arruda VR, Doshi BS, Samelson-Jones BJ: **Emerging therapies for hemophilia: controversies and unanswered questions [version 1; peer review: 4 approved]**. *F1000Res*. 2018; **7**(F1000 Faculty Rev): 489.  
[PubMed Abstract](#) | [Publisher Full Text](#) | [Free Full Text](#)
- Iorio A, Marchesini E, Marcucci M, *et al.*: **Clotting factor concentrates given to prevent bleeding and bleeding-related complications in people with hemophilia A or B**. *Cochrane Database Syst Rev*. 2011; **33**(9): CD0003429.  
[PubMed Abstract](#) | [Publisher Full Text](#)
- Srivastava A, Brewer AK, Mauser-Bunschoten EP, *et al.*: **Guidelines for the management of hemophilia**. *Haemophilia*. 2013; **19**(1): e1–e47.  
[PubMed Abstract](#) | [Publisher Full Text](#)
- Melchiorre D, Linari S, Innocenti M, *et al.*: **Ultrasound detects joint damage and bleeding in hemophilic arthropathy: a proposal of a score**. *Haemophilia*. 2011; **17**(1): 112–7.  
[PubMed Abstract](#) | [Publisher Full Text](#)
- Rodríguez-Merchan EC: **Cartilage damage in the hemophilic joints: pathophysiology, diagnosis and management**. *Blood Coagul Fibrinolysis*. 2012; **23**(3): 179–83.  
[PubMed Abstract](#) | [Publisher Full Text](#)
- Melchiorre D, Manetti M, Maticucci-Cerinic M: **Pathophysiology of Hemophilic Arthropathy**. *J Clin Med*. 2017; **6**(7): pii: E63.  
[PubMed Abstract](#) | [Publisher Full Text](#) | [Free Full Text](#)
- Acharya SS, Kaplan RN, Macdonald D, *et al.*: **Neoangiogenesis contributes to the development of hemophilic synovitis**. *Blood*. 2011; **117**(8): 2484–93.  
[PubMed Abstract](#) | [Publisher Full Text](#) | [Free Full Text](#)
- Baumgardner J, Elon L, Antun A, *et al.*: **Physical activity and functional abilities in adult males with haemophilia: a cross-sectional survey from a single US haemophilia treatment centre**. *Haemophilia*. 2013; **19**(4): 551–7.  
[PubMed Abstract](#) | [Publisher Full Text](#)
- Khawaji M, Astermark J, Von Mackensen S, *et al.*: **Bone density and health-related quality of life in adult patients with severe haemophilia**. *Haemophilia*. 2011; **17**(2): 304–11.  
[PubMed Abstract](#) | [Publisher Full Text](#)
- Torres-Ortuño A, Cid-Sabatel R, Barbero J, *et al.*: **Life experience of the adult and ageing patient with haemophilia. Practical aspects for psychological support**. *Vox Sang*. 2017; **112**(4): 301–9.  
[PubMed Abstract](#) | [Publisher Full Text](#)

17. Gilbert MS: **Prophylaxis: musculoskeletal evaluation.** *Semin Hematol.* 1993; **30**(3 Suppl 2): 3–6. [PubMed Abstract](#)
18. van den Berg HM, Feldman BM, Fischer K, *et al.*: **Assessments of outcome in haemophilia - what is the added value of QoL tools?** *Haemophilia.* 2015; **21**(4): 430–5. [PubMed Abstract](#) | [Publisher Full Text](#)
19. Blanchette VS, O'Mahony B, McJames L, *et al.*: **Assessment of outcomes.** *Haemophilia.* 2014; **20** Suppl 4: 114–20. [PubMed Abstract](#) | [Publisher Full Text](#)
20. van Vulpen LFD, Holstein K, Martinoli C: **Joint disease in haemophilia: Pathophysiology, pain and imaging.** *Haemophilia.* 2018; **24** Suppl 6: 44–9. [PubMed Abstract](#) | [Publisher Full Text](#)
21. Seuser A, Djambas Khayat C, Negrier C, *et al.*: **Evaluation of early musculoskeletal disease in patients with haemophilia: results from an expert consensus.** *Blood Coagul Fibrinolysis.* 2018; **29**(6): 509–20. [PubMed Abstract](#) | [Publisher Full Text](#) | [Free Full Text](#)
22. Arnold WD, Hilgartner MW: **Hemophilic arthropathy. Current concepts of pathogenesis and management.** *J Bone Joint Surg Am.* 1977; **59**(3): 287–305. [PubMed Abstract](#) | [Publisher Full Text](#)
23. Pettersson H, Ahlberg A, Nilsson IM: **A radiologic classification of hemophilic arthropathy.** *Clin Orthop Relat Res.* 1980; (149): 153–9. [PubMed Abstract](#) | [Publisher Full Text](#)
24. Feldman BM, Funk S, Lundin B, *et al.*: **Musculoskeletal measurement tools from the International Prophylaxis Study Group (IPSG).** *Haemophilia.* 2008; **14** Suppl 3: 162–9. [PubMed Abstract](#) | [Publisher Full Text](#)
25. Jelbert A, Vaidya S, Fotiadis N: **Imaging and staging of haemophilic arthropathy.** *Clin Radiol.* 2009; **64**(11): 1119–28. [PubMed Abstract](#) | [Publisher Full Text](#)
26. Chan MW, Leckie A, Xavier F, *et al.*: **A systematic review of MR imaging as a tool for evaluating haemophilic arthropathy in children.** *Haemophilia.* 2013; **19**(6): e324–34. [PubMed Abstract](#) | [Publisher Full Text](#)
27. Lundin B, Manco-Johnson ML, Ignas DM, *et al.*: **An MRI scale for assessment of haemophilic arthropathy from the International Prophylaxis Study Group.** *Haemophilia.* 2012; **18**(6): 962–70. [PubMed Abstract](#) | [Publisher Full Text](#)
28. Doria AS: **State-of-the-art imaging techniques for the evaluation of haemophilic arthropathy: present and future.** *Haemophilia.* 2010; **16** Suppl 5: 107–14. [PubMed Abstract](#) | [Publisher Full Text](#)
29. Hong W, Raunig D, Lundin B: **SPINART study: validation of the extended magnetic resonance imaging scale for evaluation of joint status in adult patients with severe haemophilia A using baseline data.** *Haemophilia.* 2016; **22**(6): e519–e526. [PubMed Abstract](#) | [Publisher Full Text](#)
30. Boehlen F, Graf L, Berntorp E: **Outcome measures in haemophilia: a systematic review.** *Eur J Haematol Suppl.* 2014; **76**: 2–15. [PubMed Abstract](#) | [Publisher Full Text](#)
31. Muca-Perja M, Riva S, Grochowaska B, *et al.*: **Ultrasonography of haemophilic arthropathy.** *Haemophilia.* 2012; **18**(3): 364–8. [PubMed Abstract](#) | [Publisher Full Text](#)
32. Querol F, Rodríguez-Merchan EC: **The role of ultrasonography in the diagnosis of the musculo-skeletal problems of haemophilia.** *Haemophilia.* 2012; **18**(3): e215–26. [PubMed Abstract](#) | [Publisher Full Text](#) | [F1000 Recommendation](#)
33. Di Minno MN, Ambrosio P, Quintavalle G, *et al.*: **Assessment of Hemophilic Arthropathy by Ultrasound: Where Do We Stand?** *Semin Thromb Hemost.* 2016; **42**(5): 541–9. [PubMed Abstract](#) | [Publisher Full Text](#)
34. Zhang CM, Zhang JF, Xu J, *et al.*: **Musculoskeletal ultrasonography for arthropathy assessment in patients with hemophilia: A single-center cross-sectional study from Shanxi Province, China.** *Medicine (Baltimore).* 2018; **97**(46): e13230. [PubMed Abstract](#) | [Publisher Full Text](#) | [Free Full Text](#)
35. Nag A, Ghosh S, Sinha D, *et al.*: **Ultrasonography of Knee Joint in Hemophilia A: What the Eyes Cannot See.** *Indian J Hematol Blood Transfus.* 2019; **35**(1): 149–54. [PubMed Abstract](#) | [Publisher Full Text](#) | [Free Full Text](#)
36. De la Corte-Rodríguez H, Rodríguez-Merchan EC, Jimenez-Yuste V: **Point-of-care Ultrasonography in Orthopedic Management of Hemophilia: Multiple Uses of an Effective Tool.** *HSS J.* 2018; **14**(3): 307–13. [PubMed Abstract](#) | [Publisher Full Text](#) | [Free Full Text](#) | [F1000 Recommendation](#)
37. Kidder W, Nguyen S, Larios J, *et al.*: **Point-of-care musculoskeletal ultrasound is critical for the diagnosis of hemarthroses, inflammation and soft tissue abnormalities in adult patients with painful haemophilic arthropathy.** *Haemophilia.* 2015; **21**(4): 530–7. [PubMed Abstract](#) | [Publisher Full Text](#)
38. Ceponis A, Wong-Sefidan I, Glass CS, *et al.*: **Rapid musculoskeletal ultrasound for painful episodes in adult haemophilia patients.** *Haemophilia.* 2013; **19**(5): 790–8. [PubMed Abstract](#) | [Publisher Full Text](#) | [F1000 Recommendation](#)
39. Aznar JA, Abad-Franch L, Perez-Alenda S, *et al.*: **Ultrasonography in the monitoring of management of haemarthrosis.** *Haemophilia.* 2011; **17**(5): 826–8. [PubMed Abstract](#) | [Publisher Full Text](#)
40. Wilson DJ, McLardy-Smith PD, Woodham CH, *et al.*: **Diagnostic ultrasound in haemophilia.** *J Bone Joint Surg Br.* 1987; **69**(1): 103–7. [PubMed Abstract](#) | [Publisher Full Text](#)
41. Doria AS, Keshava SN, Mohanta A, *et al.*: **Diagnostic accuracy of ultrasound for assessment of hemophilic arthropathy: MRI correlation.** *AJR Am J Roentgenol.* 2015; **204**(3): W336–47. [PubMed Abstract](#) | [Publisher Full Text](#)
42. Sierra Aisa C, Lucía Cuesta JF, Rubio Martínez A, *et al.*: **Comparison of ultrasound and magnetic resonance imaging for diagnosis and follow-up of joint lesions in patients with haemophilia.** *Haemophilia.* 2014; **20**(1): e51–e57. [PubMed Abstract](#) | [Publisher Full Text](#)
43. Nguyen S, Lu X, Ma Y, *et al.*: **Musculoskeletal ultrasound for intra-articular bleed detection: a highly sensitive imaging modality compared with conventional magnetic resonance imaging.** *J Thromb Haemost.* 2018; **16**(3): 490–9. [PubMed Abstract](#) | [Publisher Full Text](#) | [Free Full Text](#) | [F1000 Recommendation](#)
44. Di Minno MND, Iervolino S, Soscia E, *et al.*: **Magnetic resonance imaging and ultrasound evaluation of “healthy” joints in young subjects with severe haemophilia A.** *Haemophilia.* 2013; **19**(3): e167–e173. [PubMed Abstract](#) | [Publisher Full Text](#)
45. Martinoli C, Della Casa Alberighi O, Di Minno G, *et al.*: **Development and definition of a simplified scanning procedure and scoring method for Haemophilia Early Arthropathy Detection with Ultrasound (HEAD-US).** *Thromb Haemost.* 2013; **109**(6): 1170–9. [PubMed Abstract](#) | [Publisher Full Text](#) | [F1000 Recommendation](#)
46. Acharya SS, Schloss R, Dyke JP, *et al.*: **Power Doppler sonography in the diagnosis of hemophilic synovitis—a promising tool.** *J Thromb Haemost.* 2008; **6**(12): 2055–61. [PubMed Abstract](#) | [Publisher Full Text](#)
47. Bhat V, Olmer M, Joshi S, *et al.*: **Vascular remodeling underlies rebleeding in hemophilic arthropathy.** *Am J Hematol.* 2015; **90**(11): 1027–35. [PubMed Abstract](#) | [Publisher Full Text](#) | [Free Full Text](#)
48. Kidder W, Chang EY, Moran C, *et al.*: **Persistent Vascular Remodeling and Leakiness are Important Components of the Pathobiology of Re-bleeding in Hemophilic Joints: Two Informative Cases.** *Microcirculation.* 2016; **23**(5): 373–8. [PubMed Abstract](#) | [Publisher Full Text](#)
49. Cooke EJ, Zhou JY, Wyseure T, *et al.*: **Vascular Permeability and Remodelling Coincide with Inflammatory and Reparative Processes after Joint Bleeding in Factor VIII-Deficient Mice.** *Thromb Haemost.* 2018; **118**(6): 1036–47. [PubMed Abstract](#) | [Publisher Full Text](#) | [Free Full Text](#)
50. Rodríguez-Merchán EC: **Pathogenesis, early diagnosis, and prophylaxis for chronic hemophilic synovitis.** *Clin Orthop Relat Res.* 1997; (343): 6–11. [PubMed Abstract](#)
51. Ligocki CC, Abadeh A, Wang KC, *et al.*: **A systematic review of ultrasound imaging as a tool for evaluating haemophilic arthropathy in children and adults.** *Haemophilia.* 2017; **23**(4): 598–612. [PubMed Abstract](#) | [Publisher Full Text](#) | [F1000 Recommendation](#)
52. Merchan EC, De Orbe A, Gago J: **Ultrasound in the diagnosis of the early stages of hemophilic arthropathy of the knee.** *Acta Orthop Belg.* 1992; **58**(2): 122–5. [PubMed Abstract](#)
53. Klukowska A, Czynny Z, Laguna P, *et al.*: **Correlation between clinical, radiological and ultrasonographical image of knee joints in children with haemophilia.** *Haemophilia.* 2001; **7**(3): 286–92. [PubMed Abstract](#) | [Publisher Full Text](#)
54. Chen YC, Chen LC, Cheng SN, *et al.*: **Hemophilic arthropathy of shoulder joints: clinical, radiographic, and ultrasonographic characteristics of seventy patients.** *J Bone Joint Surg Am.* 2013; **95**(7): e43. [PubMed Abstract](#) | [Publisher Full Text](#)
55. Sigl-Kraetzig M SA: **Ultrasonography of joints and correlation with function in Hemophilic Arthropathy - interim results of a clinical pilot trial.** *Presented at ECR 2015 European Congress of Radiology;* March 4–8; Vienna, Austria. 2015. [Publisher Full Text](#)
56. Foppen W, van der Schaaf IC, Fischer K: **Value of routine ultrasound in detecting early joint changes in children with haemophilia using the 'Haemophilia Early Arthropathy Detection with UltraSound' protocol.** *Haemophilia.* 2016; **22**(1): 121–5. [PubMed Abstract](#) | [Publisher Full Text](#)
57. Barragan-Garfias JA, Pérez-Cristóbal M, Camargo-Coronel A, *et al.*: **Evaluación clínica, radiográfica y ultrasonográfica de pacientes con artropatía hemofílica y su correlación con la gravedad de la enfermedad.** *Med Int Mex.* 2013; **29**: 356–62. [Reference Source](#)
58. Li J, Ding X, Lyu B, *et al.*: **[Ultrasonographic characteristics of hemophilic arthropathy in the knee joints].** *Zhonghua Xue Ye Xue Za Zhi.* 2014; **35**(5): 434–7. [PubMed Abstract](#)
59. Hilliard P, Funk S, Zourikian N, *et al.*: **Hemophilia joint health score reliability study.** *Haemophilia.* 2006; **12**(5): 518–25. [PubMed Abstract](#) | [Publisher Full Text](#)
60. Querol F, Cortina V, Cid AR, *et al.*: **Clinical and echographical control protocol of haemarthrosis in haemophilia patients with inhibitors: evaluation of the**



- efficacy of recombinant factor VIIa in the evolution process (EFFISEVEN protocol). *Haemophilia*. 2008; 14 Suppl 6: 36–44.  
[PubMed Abstract](#) | [Publisher Full Text](#)
61. Zukotynski K, Jarrin J, Babyn PS, *et al.*: Sonography for assessment of haemophilic arthropathy in children: a systematic protocol. *Haemophilia*. 2007; 13(3): 293–304.  
[PubMed Abstract](#) | [Publisher Full Text](#)
62. Xavier F, Zhang N, Mohanta A: Sonography for Assessment of Elbows in Hemophilic Children: A Systematic Protocol. *Rheumatology*. 2012; 01.  
[Publisher Full Text](#)
63. Keshava S, Gibikote S, Mohanta A, *et al.*: Refinement of a sonographic protocol for assessment of haemophilic arthropathy. *Haemophilia*. 2009; 15(5): 1168–71.  
[PubMed Abstract](#) | [Publisher Full Text](#)
64. Martinoli C, Di Minno MN, Pasta G, *et al.*: Point-of-care ultrasound in haemophilic arthropathy: will the HEAD-US system supplement or replace physical examination? *Haemophilia*. 2016; 22(1): 20–1.  
[PubMed Abstract](#) | [Publisher Full Text](#)
65. Soliman M, Daruge P, Dertkigil SSJ, *et al.*: Imaging of haemophilic arthropathy in growing joints: pitfalls in ultrasound and MRI. *Haemophilia*. 2017; 23(5): 660–72.  
[PubMed Abstract](#) | [Publisher Full Text](#) | [F1000 Recommendation](#)
66. Aznar JA, Pérez-Alenda S, Jaca M, *et al.*: Home-delivered ultrasound monitoring for home treatment of haemarthrosis in haemophilia A. *Haemophilia*. 2015; 21(2): e147–50.  
[PubMed Abstract](#) | [Publisher Full Text](#)
67. Berro M, Elichiry M, Wasen K, *et al.*: Use of ultrasound for evaluation of painful joint episodes perceived as haemarthrosis in adult patients with severe haemophilia. *Haemophilia*. 2018; 24(3): e124–e125.  
[PubMed Abstract](#) | [Publisher Full Text](#)
68. Strike K, Uy M, Lawson W, *et al.*: Point-of-care ultrasonography in haemophilia care: Training and competency for muscular haematomas. *Haemophilia*. 2018; 24(3): 335–7.  
[PubMed Abstract](#) | [Publisher Full Text](#) | [F1000 Recommendation](#)
69. Strike KL, Iorio A, Jackson S, *et al.*: Point of care ultrasonography in haemophilia care: recommendations for training and competency evaluation. *Haemophilia*. 2015; 21(6): 828–31.  
[PubMed Abstract](#) | [Publisher Full Text](#)
70. Martin EJ, Cooke EJ, Ceponis A, *et al.*: Efficacy and safety of point-of-care ultrasound-guided intra-articular corticosteroid joint injections in patients with haemophilic arthropathy. *Haemophilia*. 2017; 23(1): 135–43.  
[PubMed Abstract](#) | [Publisher Full Text](#) | [F1000 Recommendation](#)
71. Rodríguez-Merchan EC: Intra-articular corticosteroid injections in haemophilic arthropathy: are they recommended? *Hosp Pract (1995)*. 2017; 46(1): 1–4.  
[PubMed Abstract](#) | [Publisher Full Text](#) | [F1000 Recommendation](#)
72. De la Corte-Rodríguez H, Rodríguez-Merchan EC, Alvarez-Roman MT, *et al.*: Accelerating recovery from acute hemarthrosis in patients with hemophilia: the role of joint aspiration. *Blood Coagul Fibrinolysis*. 2019; 30(3): 111–9.  
[PubMed Abstract](#) | [Publisher Full Text](#) | [F1000 Recommendation](#)
73. Rezende MU, Andrusaitis FR, Silva RT, *et al.*: Joint lavage followed by viscosupplementation and triamcinolone in patients with severe haemophilic arthropathy: objective functional results. *Haemophilia*. 2017; 23(2): e105–e115.  
[PubMed Abstract](#) | [Publisher Full Text](#) | [F1000 Recommendation](#)
74. Li TY, Wu YT, Chen LC, *et al.*: An exploratory comparison of single intra-articular injection of platelet-rich plasma vs hyaluronic acid in treatment of haemophilic arthropathy of the knee. *Haemophilia*. 2019; 25(3): 484–492.  
[PubMed Abstract](#) | [Publisher Full Text](#) | [F1000 Recommendation](#)
75. Volland LM, Zhou JY, Barnes RFW, *et al.*: Development and Reliability of the Joint Tissue Activity and Damage Examination for Quantitation of Structural Abnormalities by Musculoskeletal Ultrasound in Hemophilic Joints. *J Ultrasound Med*. 2019; 38(6): 1569–1581.  
[PubMed Abstract](#) | [Publisher Full Text](#) | [F1000 Recommendation](#)
76. Jiménez-Yuste V, Álvarez-Román MT, Martín-Salces M, *et al.*: Joint status in Spanish haemophilia B patients assessed using the Haemophilia Early Arthropathy Detection with Ultrasound (HEAD-US) score. *Haemophilia*. 2019; 25(1): 144–53.  
[PubMed Abstract](#) | [Publisher Full Text](#)
77. Foppen W, van der Schaaf IC, Beek FJ, *et al.*: Scoring haemophilic arthropathy on X-rays: improving inter- and intra-observer reliability and agreement using a consensus atlas. *Eur Radiol*. 2016; 26(6): 1963–70.  
[PubMed Abstract](#) | [Publisher Full Text](#) | [Free Full Text](#)
78. Lisi C, Di Natali G, Sala V, *et al.*: Interobserver reliability of ultrasound assessment of haemophilic arthropathy: radiologist vs. non-radiologist. *Haemophilia*. 2016; 22(3): e211–4.  
[PubMed Abstract](#) | [Publisher Full Text](#)
79. Stephensen D, Classey S, Harbidge H, *et al.*: Physiotherapist inter-rater reliability of the Haemophilia Early Arthropathy Detection with Ultrasound protocol. *Haemophilia*. 2018; 24(3): 471–6.  
[PubMed Abstract](#) | [Publisher Full Text](#) | [F1000 Recommendation](#)
80. De la Corte-Rodríguez H, Rodríguez-Merchan EC, Alvarez-Roman MT, *et al.*: The value of HEAD-US system in detecting subclinical abnormalities in joints of patients with hemophilia. *Expert Rev Hematol*. 2018; 11(3): 253–61.  
[PubMed Abstract](#) | [Publisher Full Text](#) | [F1000 Recommendation](#)
81. Altisent C, Martorell M, Crespo A, *et al.*: Early prophylaxis in children with severe haemophilia A: clinical and ultrasound imaging outcomes. *Haemophilia*. 2016; 22(2): 218–24.  
[PubMed Abstract](#) | [Publisher Full Text](#)
82. Timmer MA, Foppen W, Schutgens RE, *et al.*: Comparing findings of routine Haemophilia Joint Health Score and Haemophilia Early Arthropathy Detection with UltraSound assessments in adults with haemophilia. *Haemophilia*. 2017; 23(2): e141–e143.  
[PubMed Abstract](#) | [Publisher Full Text](#) | [F1000 Recommendation](#)
83. Di Minno MND, Pasta G, Airaldi S, *et al.*: Ultrasound for Early Detection of Joint Disease in Patients with Hemophilic Arthropathy. *J Clin Med*. 2017; 6(8): pii: E77.  
[PubMed Abstract](#) | [Publisher Full Text](#) | [Free Full Text](#) | [F1000 Recommendation](#)
84. Foppen W, van der Schaaf IC, Beek FJA, *et al.*: Diagnostic accuracy of point-of-care ultrasound for evaluation of early blood-induced joint changes: Comparison with MRI. *Haemophilia*. 2018; 24(6): 971–9.  
[PubMed Abstract](#) | [Publisher Full Text](#) | [F1000 Recommendation](#)
85. Foppen W FK: Prognostic value of MRI synovial changes in haemophilia patients: preliminary results. *Haemophilia*. 2015; 21: 41–2.
86. Pergantou H, Platakouki H, Matsinos G, *et al.*: Assessment of the progression of haemophilic arthropathy in children. *Haemophilia*. 2010; 16(1): 124–9.  
[PubMed Abstract](#) | [Publisher Full Text](#)
87. Foppen W, Fischer K, van der Schaaf IC: Imaging of haemophilic arthropathy: Awareness of pitfalls and need for standardization. *Haemophilia*. 2017; 23(5): 645–7.  
[PubMed Abstract](#) | [Publisher Full Text](#) | [F1000 Recommendation](#)
88. von Drygalski A, Moore RE, Nguyen S, *et al.*: Advanced Hemophilic Arthropathy: Sensitivity of Soft Tissue Discrimination With Musculoskeletal Ultrasound. *J Ultrasound Med*. 2018; 37(8): 1945–56.  
[PubMed Abstract](#) | [Publisher Full Text](#) | [Free Full Text](#) | [F1000 Recommendation](#)
89. D'Agostino MA, Terslev L, Aegerter P, *et al.*: Scoring ultrasound synovitis in rheumatoid arthritis: a EULAR-OMERACT ultrasound taskforce-Part 1: definition and development of a standardised, consensus-based scoring system. *RMD Open*. 2017; 3(1): e000428.  
[PubMed Abstract](#) | [Publisher Full Text](#) | [Free Full Text](#)
90. Terslev L, Naredo E, Aegerter P, *et al.*: Scoring ultrasound synovitis in rheumatoid arthritis: a EULAR-OMERACT ultrasound taskforce-Part 2: reliability and application to multiple joints of a standardised consensus-based scoring system. *RMD Open*. 2017; 3(1): e000427.  
[PubMed Abstract](#) | [Publisher Full Text](#) | [Free Full Text](#)
91. Lawson W, Uy M, Strike K, *et al.*: Point of care ultrasound in haemophilia: Building a strong foundation for clinical implementation. *Haemophilia*. 2017; 23(5): 648–51.  
[PubMed Abstract](#) | [Publisher Full Text](#) | [F1000 Recommendation](#)
92. Spannow AH, Pfeiffer-Jensen M, Andersen NT, *et al.*: Ultrasonographic measurements of joint cartilage thickness in healthy children: age- and sex-related standard reference values. *J Rheumatol*. 2010; 37(12): 2595–601.  
[PubMed Abstract](#) | [Publisher Full Text](#)
93. Spannow AH, Stenboeg E, Pfeiffer-Jensen M, *et al.*: Ultrasound and MRI measurements of joint cartilage in healthy children: a validation study. *Ultraschall Med*. 2011; 32 Suppl 1: S110–6.  
[PubMed Abstract](#) | [Publisher Full Text](#)
94. Panghaal V, Janow G, Trinh A, *et al.*: Normal epiphyseal cartilage measurements in the knee in children: an alternative sonographic approach. *J Ultrasound Med*. 2012; 31(1): 49–53.  
[PubMed Abstract](#) | [Publisher Full Text](#)
95. Windschall D, Collado P, Vojinovic J, *et al.*: Age-related vascularization and ossification of joints in children: an international pilot study to test multi-observer ultrasound reliability. *Arthritis Care Res (Hoboken)*. 2017.  
[PubMed Abstract](#) | [Publisher Full Text](#)
96. Martinoli C, Di Minno MN, Pasta G, *et al.*: Hemosiderin Detection With Ultrasound: Reality or Myth? *AJR Am J Roentgenol*. 2016; 206(1): W30.  
[PubMed Abstract](#) | [Publisher Full Text](#)
97. Roosendaal G, Vianen ME, Wenting MJ, *et al.*: Iron deposits and catabolic properties of synovial tissue from patients with haemophilia. *J Bone Joint Surg Br*. 1998; 80(3): 540–5.  
[PubMed Abstract](#) | [Publisher Full Text](#)
98. Puetz J: Nano-evidence for joint microbleeds in hemophilia patients. *J Thromb Haemost*. 2018; 16(10): 1914–7.  
[PubMed Abstract](#) | [Publisher Full Text](#) | [F1000 Recommendation](#)
99. Acharya SS, Rule B, McMillan O, *et al.*: Point-of-care ultrasonography (POCUS) in hemophilia A: a commentary on current status and its potential role for improving prophylaxis management in severe hemophilia A. *Ther Adv Hematol*. 2017; 8(4): 153–6.  
[PubMed Abstract](#) | [Publisher Full Text](#) | [Free Full Text](#)

100.  Di Minno A, Spadarella G, Nardone A, *et al.*: **Attempting to remedy sub-optimal medication adherence in haemophilia: The rationale for repeated ultrasound visualisations of the patient's joint status.** *Blood Rev.* 2019; **33**: 106–16.  
[PubMed Abstract](#) | [Publisher Full Text](#) | [F1000 Recommendation](#)
101. Stoffman J, Andersson NG, Branchford B, *et al.*: **Common themes and challenges in hemophilia care: a multinational perspective.** *Hematology.* 2018; **24**(1): 39–48.  
[PubMed Abstract](#) | [Publisher Full Text](#)
102. Doria A, vonDrygalski A, Blanchette V, *et al.*: **Use of ultrasound for assessment of musculoskeletal disease in persons with hemophilia: Results of an International Prophylaxis Study Group (IPSG) survey.** WFH 2018 World Congress 2018 Abstract 2018.
103.  Zhou JY, Rappazzo KC, Volland L, *et al.*: **Pocket handheld ultrasound for evaluation of the bleeding haemophilic joint: A novel and reliable way to recognize joint effusions.** *Haemophilia.* 2018; **24**(2): e77–e80.  
[PubMed Abstract](#) | [Publisher Full Text](#) | [F1000 Recommendation](#)
104. Fischer K, Poonnoose P, Dunn AL, *et al.*: **Choosing outcome assessment tools in haemophilia care and research: a multidisciplinary perspective.** *Haemophilia.* 2017; **23**(1): 11–24.  
[PubMed Abstract](#) | [Publisher Full Text](#)
105. Recht M, Konkle BA, Jackson S, *et al.*: **Recognizing the need for personalization of haemophilia patient-reported outcomes in the prophylaxis era.** *Haemophilia.* 2016; **22**(6): 825–32.  
[PubMed Abstract](#) | [Publisher Full Text](#)

# Open Peer Review

Current Peer Review Status:  

---

## Editorial Note on the Review Process

F1000 Faculty Reviews are written by members of the prestigious F1000 Faculty. They are commissioned and peer reviewed before publication to ensure that the final, published version is comprehensive and accessible. The reviewers who approved the final version are listed with their names and affiliations.

---

## The reviewers who approved this article are:

### Version 1

- 1 Felipe Querol**  
Department of Physiotherapy, University of Valencia, Valencia, Spain  
**Competing Interests:** No competing interests were disclosed.
- 2 Alok Srivastava**  
Department of Haematology, Christian Medical College, Vellore, 632004, India  
**Competing Interests:** No competing interests were disclosed.

The benefits of publishing with F1000Research:

- Your article is published within days, with no editorial bias
- You can publish traditional articles, null/negative results, case reports, data notes and more
- The peer review process is transparent and collaborative
- Your article is indexed in PubMed after passing peer review
- Dedicated customer support at every stage

For pre-submission enquiries, contact [research@f1000.com](mailto:research@f1000.com)

F1000Research