

# Open Gluteus Medius and Minimus Repair With Double-Row Technique and Bioinductive Implant Augmentation



Caleb M. Gulledge, B.S., and Eric C. Makhni, M.D., M.B.A.

**Abstract:** Lateral hip pain in patients without significant osteoarthritis may be due to a number of different etiologies. Recent attention has been placed on the role of abductor tendon (gluteus medius and minimus) deficiency in these patients. These tears, analogous to rotator cuff tears in the shoulder, may cause pain, weakness, limp, and dysfunction. Mainstays of treatment include nonoperative treatment and, in select patients, operative fixation. This article presents an overview of management of patients with symptomatic, large, retracted, chronic tears of the abductor tendons. The highlighted repair is a “double-row” repair with biological patch augmentation.

Lateral hip pain, or greater trochanteric pain syndrome, is typically a chronic, disabling condition most common in middle-aged women.<sup>1,2</sup> Although this condition has historically been attributed to trochanteric bursitis, recent evidence indicates that many cases are caused by tendinopathy and/or tears of the hip abductor muscles (gluteus medius and minimus).<sup>1</sup> In these patients, gluteal tears are caused by attritional tendinopathy, which may be analogous to rotator cuff tears—resulting in hip abduction weakness against resistance and a Trendelenburg gait.<sup>2-4</sup> These injuries are often referred to as “rotator cuff tears of the hip” for these reasons.

Nonoperative treatment is first attempted for most cases.<sup>5</sup> This consists of activity modification, anti-inflammatory treatment when permitted, and physical

therapy for strengthening of the abductors and surrounding hip musculature.<sup>6</sup> Peritrochanteric cortisone injections and platelet-rich plasma injections<sup>7</sup> may also be useful for treating symptoms of pain, and these are performed under ultrasound guidance by experienced clinicians.

Surgery is considered for patients in whom exhaustive nonoperative treatment fails. The precise surgical technique depends on tear characteristics and surgeon comfort. For tears that are partial thickness, we believe that endoscopic treatment allows for optimal visualization and inspection of the tear, bursectomy of the inflamed tissue, and effective repair. Such partial tears are often difficult to visualize by gross inspection and require probing under endoscopic visualization.<sup>1</sup> Endoscopic treatment can also be effectively used for full-thickness tears that are minimally retracted.<sup>6,8-10</sup> For tears that are large with retraction, we prefer to use an open technique, which allows for adequate soft-tissue mobilization, release of adhesions, and graft augmentation when necessary.<sup>3</sup> Open treatment is technically less demanding than endoscopic treatment, especially for surgeons who are not experienced with hip arthroscopy.

An emerging option to facilitate healing and enhance strength of repair is the use of a bioinductive implant. A variety of implant augmentation materials, including degradable, nondegradable, synthetic, and extracellular matrix-based patches, have been used clinically for massive rotator cuff repairs.<sup>11</sup> Recently, the use of highly purified type I collagen bovine Achilles tendon scaffolds on partial- and full-thickness rotator cuff tears

From the Department of Orthopedics, Henry Ford Health System, West Bloomfield, Michigan, U.S.A.

The authors report the following potential conflicts of interest or sources of funding: E.C.M. is a paid consultant for Smith & Nephew and Xodus, and receives publishing royalties and financial or material support from Springer. Full ICMJE author disclosure forms are available for this article online, as supplementary material.

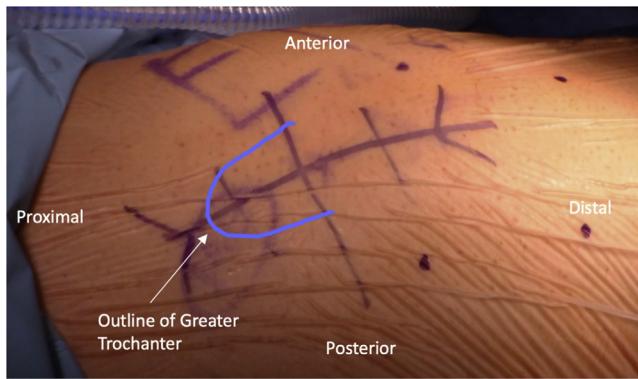Received December 6, 2018; accepted January 31, 2019.

Address correspondence to Eric C. Makhni, M.D., M.B.A., Department of Orthopedics, Henry Ford Health System, 6777 W Maple Rd, West Bloomfield, MI 48322, U.S.A. E-mail: [ericmakhnimd@gmail.com](mailto:ericmakhnimd@gmail.com)

© 2019 Published by Elsevier on behalf of the Arthroscopy Association of North America. This is an open access article under the CC BY-NC-ND license (<http://creativecommons.org/licenses/by-nc-nd/4.0/>).

2212-6287/181480

<https://doi.org/10.1016/j.eats.2019.01.019>



**Fig 1.** Superior view of right lateral hip, with patient in lateral decubitus position. The incision is centered over the prominence of the greater trochanter, measuring approximately 8 to 10 cm in length.

has shown improved outcomes; the formation of mature, well-integrated tendon-like tissue; and increasing thickness of the supraspinatus tendon.<sup>12,13</sup> Purified collagen lacks undesired impurities (elastin and hair follicles) commonly found in dermal implants and absorbs in 6 months without causing an inflammatory reaction.<sup>14</sup> Despite its widespread use in rotator cuff tears, this implant has not been heavily adopted in the hip; to date, only 1 article has described its use in an endoscopic repair of the gluteal tendons.<sup>14</sup> We describe a double-row open repair technique for a full-thickness gluteus medius and minimus tendon tear augmented with a bovine collagen patch.

### Surgical Technique

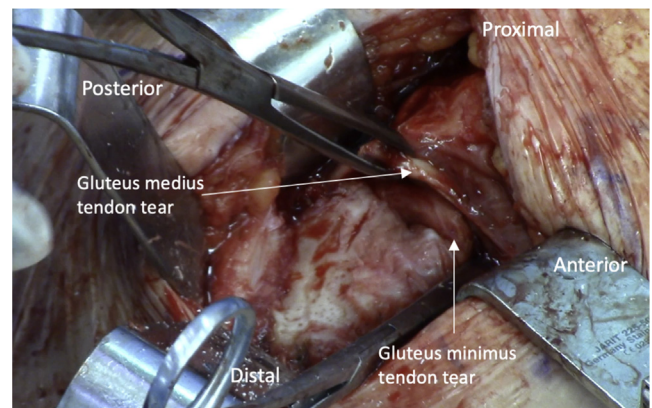
A detailed description of the procedure is provided in [Video 1](#). After informed consent is obtained, the patient is brought into the operating room and administered standard preoperative antibiotics. Our preference is to perform the operation with the patient in a lateral position so that the soft tissues can easily be retracted from the surgical field. Surgery can be performed with the patient under spinal anesthesia or general anesthesia. After administration of anesthesia, the patient is positioned lateral, by use of either a pegboard setup or a beanbag. The operative side is then prepared and draped, and a surgical pause is performed according to hospital protocol. A padded Mayo stand is also available for the operative foot to rest on, thereby providing abduction during the case (which relieves tension on the iliotibial band [ITB]).

An 8-cm longitudinal incision centered over the greater trochanter is made with a No. 15 blade ([Fig 1](#)). Sharp dissection is carried down to the deep fascia and ITB. The ITB and deep fascia are incised longitudinally in line with the long axis of the femur over the prominence of the greater trochanter to expose the trochanteric bursa. The overlying bursa is then resected,

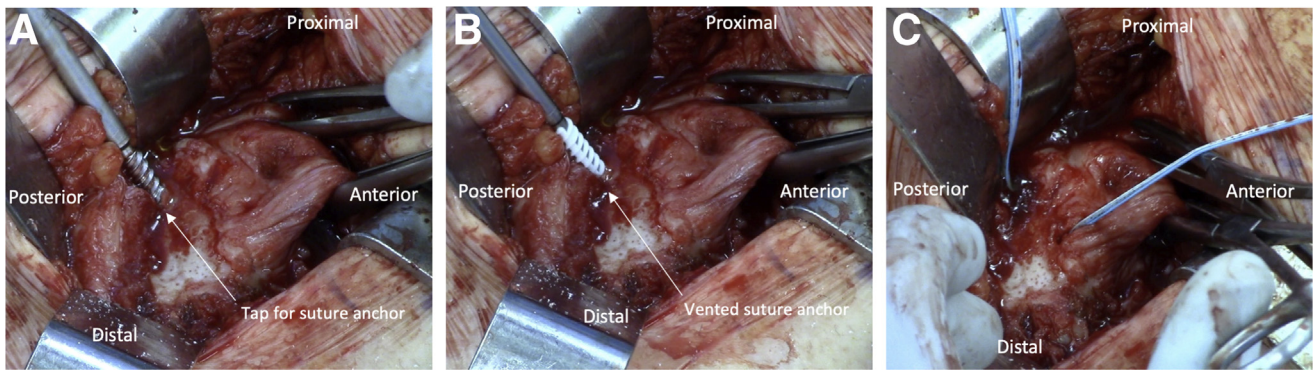
allowing identification of the gluteal tendons.<sup>15</sup> A “bald” trochanter is often encountered for large, retracted tears. The tear edges are grasped with an Allis clamp and mobilized down to the footprint to show reparability. To minimize resting tension of the repair, blunt mobilization of adhesions is performed using a Cobb device or the surgeon’s finger. After mobilization of the tear ([Fig 2](#)), the tendon footprint on the greater trochanter is decorticated with a round burr to facilitate tendon-to-bone healing.

For large, retracted tears, our preference is to repair the tendon in a “double row”—equivalent fashion. In this technique, 2 “medial”-row anchors are placed proximally on the footprint of the greater trochanter, with 2 “lateral”-row anchors placed more distally. The 2 medial-row, vented anchors (4.75-mm Healicoil; Smith & Nephew, Andover, MA) are placed after the bone is first prepared with a tap and punch. The anchors are preloaded with 4 suture strands (2 pairs, [Fig 3](#)). The gluteus medius and minimus tendon tear leaflets are then secured with a running locking stitch and a mattress stitch from each of the anchors. The sutures are sequentially tensioned, reduced, and tied down to achieve a secure tendon-bone approximation ([Fig 4A](#)) with minimal tension. The strands are then incorporated, using a knotless technique, into the 2 lateral-row anchors as is typically performed in a rotator cuff repair (Multifix System; Smith & Nephew). The repair is dynamically visualized with hip internal and external rotation, showing compression to the footprint and movement as a single repair unit ([Fig 4B](#)).

A 25 × 31-mm bovine bioinductive implant (Regeneten; Smith & Nephew) is positioned over the repaired tendon, with the distal end of the implant approximating the tendon footprint ([Fig 5A](#)). The implant is secured to the tendon with a series of staples (absorbable polylactic acid copolymer; Smith & Nephew) used to secure the implant over the repair onto the gluteus



**Fig 2.** Superior view of right lateral hip, with patient in lateral decubitus position. A full-thickness gluteus medius and minimus tear is observed, as seen from superiorly.



**Fig 3.** Superior view of right lateral hip, with patient in lateral decubitus position. A tap and punch are inserted in the posterosuperior aspect of the footprint on the greater trochanter (A) in preparation for placement of a vented, 4.75-mm bioabsorbable double-loaded suture anchor (B). (C) Placement of second anchor located slightly anterior on footprint.

medius and minimus tendons (Fig 5B). The staples are positioned approximately 2 to 4 mm in from the edge of the implant and are spaced about 5 to 7 mm apart (Fig 5C). Approximately 9 staples are used to secure the implant. Care should be taken to ensure the staples do not interfere with the underlying repair.

After copious irrigation with saline and chlorhexidine gluconate 0.05% solution (Irrisept; Irrimax, Gainesville, FL), the limb is placed into internal rotation and neutral adduction for closure. The ITB and deep fascia are identified and closed anatomically using braided, absorbable suture. The deep and subcuticular dermal layer is then closed with absorbable suture (Monocryl; Ethicon, Somerville, NJ) and a topical skin adhesive (Dermabond; Ethicon). Sterile dressing is applied (Aquacel; ConvaTec, Princeton, NJ), the patient is extubated without complication, and the patient is transferred to the postanesthesia care unit in stable condition. Pearls and pitfalls can be seen in Table 1.

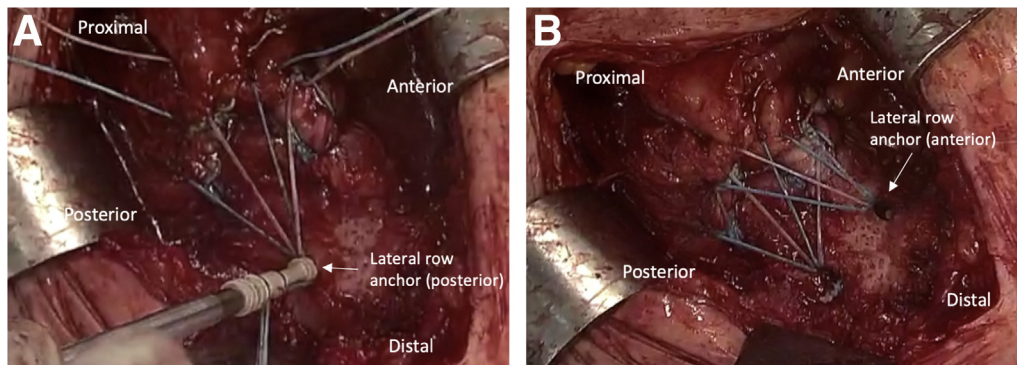
Postoperatively, the patient is restricted to partial weight bearing (approximately 50%) with a walker and placed in a hip abduction brace (Ossur, Foothill Ranch, CA) for 6 weeks. Afterward, the patient may transition to full weight bearing as tolerated, with the goal of unassisted weight bearing by week 8. Progressive

range-of-motion and isometric exercises are initiated 5 days after surgery with no resistive abduction exercises allowed for at least 12 weeks. The patient begins physical therapy 6 weeks after surgery and typically continues until 6 to 8 months postoperatively.

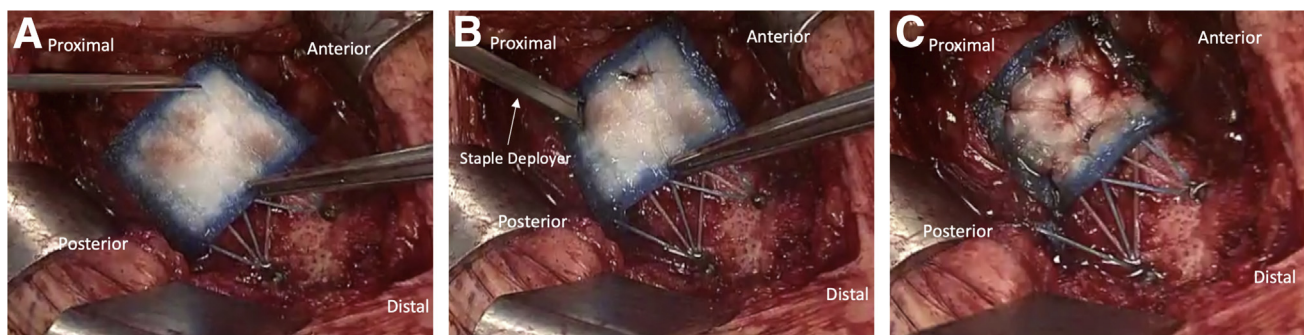
## Discussion

Disorders of the abductor tendon complex are being increasingly recognized and managed.<sup>3,4</sup> Several case series have reported good outcomes and clinical improvement after gluteal tendon repair.<sup>3,6,8</sup> Systematic reviews of open and endoscopic repair techniques have shown similar improvements in pain and function<sup>6,8</sup> between the techniques. Although these studies showed a higher complication rate for open versus endoscopic repair,<sup>6,8</sup> the lack of head-to-head trials and heterogeneity of tear pathology and repair technique make true comparisons challenging. However, for large, retracted tears, an open technique offers a comprehensive approach and treatment as described in this surgical guide.

The patch described in this article serves as a bioinductive implant with the goal of improving repair through enhanced vascularity. The goal of this patch, unlike a structural graft, is not to improve the strength



**Fig 4.** Superior view of right lateral hip, with patient in lateral decubitus position. (A) Knotless lateral-row anchor implantation onto distal, posterior aspect of tendon footprint. (B) Final repair with anterior lateral-row anchor.



**Fig 5.** Superior view of right lateral hip, with patient in lateral decubitus position. (A) Placement of bioinductive patch over final repaired tendon. (B) The patch is secured with a number of soft-tissue staples using an inserter device. (C) Final construct.

**Table 1.** Pearls and Pitfalls of Bioinductive Implant–Augmented Gluteus Medius and Minimus Repair

Pearls	Pitfalls
Proper positioning and padding with leg abduction to relax IT band during surgical approach	Failure to relax IT band during surgical approach and repair, making visualization challenging
Mobilization of retracted tendon using heavy Allis clamps or traction stitches along with blunt-finger 360° dissection around tendon	Narrow spacing of anchors, which may lead to trochanter fracture in osteoporotic bone
Proper footprint preparation with decortication using high-speed round or oval burr	Overly aggressive postoperative rehabilitation that can compromise healing at bone-tendon interface
Adequate spacing of medial- and lateral-row anchors to promote maximum footprint coverage	Failure to properly secure bioinductive patch to underlying native tendon, which can cause dislodging of graft on weight bearing and ambulation
Placement of bioinductive patch over site of repair to footprint to maximize local biology at site of tendon-bone healing	

IT, iliotibial.

of the repair but instead to improve the biology surrounding the repair.<sup>11</sup> This patch has shown improved outcomes; increasing supraspinatus tendon thickness; and the formation of mature, well-integrated tendon-like tissue in partial- and full-thickness rotator cuff repairs.<sup>12,13</sup>

The procedure described in this article does have notable risks and limitations. Patients are counseled on the risks of surgery including fracture of the trochanteric region after suture anchor placement, as well as infection, due to both the surgical procedure itself and the implants placed. Patients should be counseled that the patch used contains a bovine product and may preclude tissue and/or blood donation in the future. Additional risks are also discussed such as retear and the inability to improve pain or function to a satisfactory degree, along with standard risks related to general or spinal anesthesia. Care is also taken to counsel patients regarding realistic expectations postoperatively, especially patients who show a high degree of fatty atrophy of the abductor musculature preoperatively.

In conclusion, abductor tears of the gluteus medius and minimus may cause significant pain and weakness in affected patients. These tears may be effectively treated with a number of different techniques, both endoscopic and open. The technique described in this article is simple and effective in the treatment of large,

retracted tears. Biological augmentation may be incorporated into treatment techniques to improve healing through enhanced vascularity.

## References

- Domb BG, Nasser RM, Botser IB. Partial-thickness tears of the gluteus medius: Rationale and technique for trans-tendinous endoscopic repair. *Arthroscopy* 2010;26:1697-1705.
- LaPorte C, Vasaris M, Gossett L, Boykin R, Menge T. Gluteus medius tears of the hip: A comprehensive approach. *Phys Sportsmed* 2019;47:15-20.
- Davies JF, Stiehl JB, Davies JA, Geiger PB. Surgical treatment of hip abductor tendon tears. *J Bone Joint Surg Am* 2013;95:1420-1425.
- Hartigan DE, Perets I, Walsh JP, et al. Radiographic risk factors and signs of abductor tears in the hip. *Arthroscopy* 2018;34:2389-2397.
- Torres A, Fernandez-Fairen M, Sueiro-Fernandez J. Greater trochanteric pain syndrome and gluteus medius and minimus tendinosis: Nonsurgical treatment. *Pain Manag* 2018;8:45-55.
- Chandrasekaran S, Lodhia P, Gui C, Vemula SP, Martin TJ, Domb BG. Outcomes of open versus endoscopic repair of abductor muscle tears of the hip: A systematic review. *Arthroscopy* 2015;31:2057-2067.e2.
- Fitzpatrick J, Bulsara MK, O'Donnell J, McCrory PR, Zheng MH. The effectiveness of platelet-rich plasma

- injections in gluteal tendinopathy: A randomized, double-blind controlled trial comparing a single platelet-rich plasma injection with a single corticosteroid injection. *Am J Sports Med* 2018;46:933-939.
8. Alpaugh K, Chilelli BJ, Xu S, Martin SD. Outcomes after primary open or endoscopic abductor tendon repair in the hip: A systematic review of the literature. *Arthroscopy* 2015;31:530-540.
  9. Levy DM, Bogunovic L, Grzybowski JS, Kuhns BD, Bush-Joseph CA, Nho SJ. All-endoscopic single-row repair of full-thickness gluteus medius tears. *Arthrosc Tech* 2016;5:e1-e6.
  10. Laskovski J, Urchek R. Endoscopic gluteus medius and minimus repair with allograft augmentation using acellular human dermis. *Arthrosc Tech* 2018;7:e225-e230.
  11. Petri M, Greenspoon JA, Moulton SG, Millett PJ. Patch-augmented rotator cuff repair and superior capsule reconstruction. *Open Orthop J* 2016;10:315-323.
  12. Bokor DJ, Sonnabend D, Deady L, et al. Evidence of healing of partial-thickness rotator cuff tears following arthroscopic augmentation with a collagen implant: A 2-year MRI follow-up. *Muscles Ligaments Tendons J* 2016;6:16-25.
  13. Van Kampen C, Arnoczky S, Parks P, et al. Tissue-engineered augmentation of a rotator cuff tendon using a reconstituted collagen scaffold: A histological evaluation in sheep. *Muscles Ligaments Tendons J* 2013;3:229-235.
  14. Kaplan DJ, Dold AP, Fralinger DJ, Meislin RJ. Endoscopic gluteus medius repair augmented with bioinductive implant. *Arthrosc Tech* 2016;5:e821-e825.
  15. Tsutsumi M, Nimura A, Akita K. The gluteus medius tendon and its insertion sites: An anatomical study with possible implications for gluteus medius tears. *J Bone Joint Surg Am* 2019;101:177-184.