

# Central serous chorioretinopathy following ingestion of sildenafil citrate

This article was published in the following Dove Press journal:  
*Clinical Optometry*

Mehrdad Mohammadpour<sup>1</sup>  
Mehdi Khodaparast<sup>1</sup>  
Masoud Khorrami-Nejad<sup>1,2</sup>

<sup>1</sup>Eye Research Center, Farabi Eye Hospital, Tehran University of Medical Sciences, Tehran, Iran; <sup>2</sup>Department of Optometry, School of Rehabilitation, Shahid Beheshti University of Medical Sciences, Tehran, Iran

**Introduction:** We report a case of a 35-year-old man who presented with headache followed by decreased vision, metamorphopsia, and altered color perception in his left eye, after repeated intake of sildenafil citrate (four times; 100 mg) in a limited period (3 days).

**Methods:** On the first ocular examination, best-corrected distance visual acuity (CDVA) was 20/80 in his left eye and 20/20 in his right eye. On fundus examination, loss of foveal reflex and serous retinal detachment in the foveal region were detected. Fluorescein angiography of the left eye was compatible with a leakage area with determined borders. The patient was advised to stop sildenafil intake.

**Results:** After 4 weeks, CDVA increased to 20/25, and the fundus examination revealed significant improvement of the macular edema. Optical coherence tomography showed increased foveal thickness to 350  $\mu$ m.

**Conclusion:** Advising patients with central serous chorioretinopathy to stop sildenafil intake should be considered.

**Keywords:** central serous chorioretinopathy, sildenafil citrate, serous retinal detachment

## Introduction

Central serous chorioretinopathy is an idiopathic condition characterized by the development of a well-circumscribed serous detachment of the sensory retina resulting from the altered barrier and deficient pumping function at the level of the retinal pigment epithelium; however, the primary pathology may involve the choriocapillaris.<sup>1,2</sup>

Sildenafil citrate is a drug with (phosphodiesterase type 5) inhibitor function (PDE-5) inhibitor function that is used in different disorders such as male erectile dysfunction. Sildenafil causes several ocular manifestations such as changes in color perception, blurred vision, transient-decreased vision, ocular pain, photophobia, changes in light perception, retinal vascular accidents and ischemic optic neuropathy.<sup>3-5</sup>

Generalized increased vascular permeability following sildenafil intake especially in high doses may cause abnormally increased choroidal vascular permeability leading to serous retinal detachment.<sup>1</sup>

This study reports an unusual case of central serous chorioretinopathy (CSR) following taking sildenafil citrate, characterized by loss of foveal reflex, serous retinal detachment and decreased vision.

## Case report

A 35-year-old man presented with headache followed by decreased vision, metamorphopsia and altered color perception in his left eye after repeated intake of

Correspondence: Masoud Khorrami-Nejad  
Eye Research Center, Farabi Eye Hospital,  
Tehran University of Medical Sciences,  
Ghazvin Square, Kargar Street, Tehran  
1336616351, Iran  
Tel +98 215 540 0010  
Email op\_khorrami@yahoo.com

sildenafil citrate for four times (100 mg) in a limited period (3 days). The patient provided written informed consent for the case details and images to be published. Based on our hospital policy, Institutional Review Board (IRB) was not required as it was a case report.

The patient did not have any history of taking steroids, stressful routine in last year and background diseases such as diabetes and hypertension. The patient had a recorded medical document and referring to that the sildenafil ingestion confirmed as the direct cause of the CSR. On the first ocular examination, best-corrected distance visual acuity (CDVA) was 20/80 in his left eye and 20/20 in the right eye.

Slit lamp examinations were normal and IOP was unremarkable. On fundus examination, loss of foveal reflex and serous retinal detachment in the foveal region were detected.

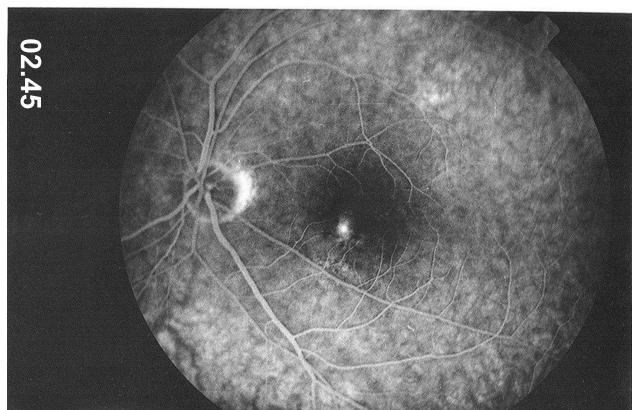
Fluorescein angiography of the left eye was compatible with a leakage area with determined borders (Figure 1).

Optical coherence tomography showed increased foveal thickness to 350  $\mu\text{m}$  (Figure 2).

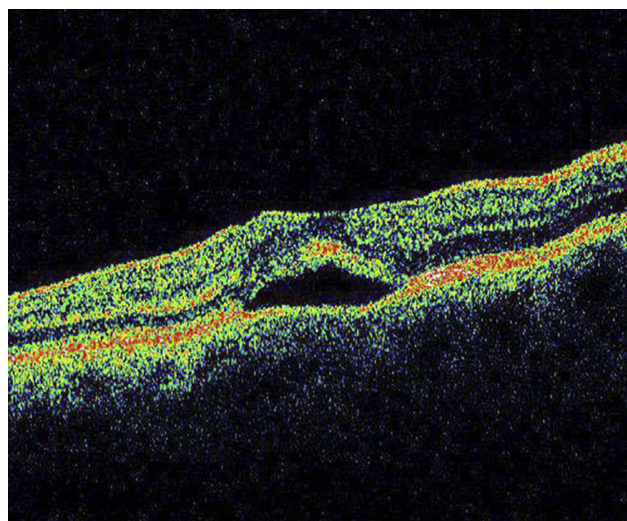
The patient was advised to stop sildenafil intake, and after 4 weeks CDVA increased to 20/25 and the fundus examination revealed significant improvement of the macular edema.

## Discussion

Central serous chorioretinopathy is an idiopathic well-circumscribed serous detachment of the sensory retina.<sup>1</sup> It occurs in the third to sixth decades of life. Men are affected 8 times greater than women. Central serous chorioretinopathy presents with sudden onset of unilateral central blurring of vision with metamorphopsia, changes



**Figure 1** Fluorescein angiography showing the leakage in the macular area of the left eye.



**Figure 2** Optical coherence tomography showing an increased thickness of macular area.

in color perception, and a relative central scotoma. Although this disorder is often painless, our patient remembered mild ocular pain before blurring of vision. Presumed risk factors include male gender, age, refractive state, systemic blood pressure, corticosteroid use and type A personality.<sup>3–7</sup>

The visual prognosis is good and spontaneous visual recovery typically occurs in approximately 85% of patients with central serous chorioretinopathy within 1–6 months.<sup>5</sup>

Sildenafil is a widely used medication to improve impotence. The evolving use of this medication has been associated with a wide variety of ophthalmic complications including anterior ischemic optic neuropathy, extraocular muscle palsy, subretinal hemorrhage in patients with age-related macular degeneration, elevated IOP and retinal vascular event.<sup>1,2</sup>

The effect of sildenafil citrate on PDE-6 enzyme that is involved in phototransduction in retina is thought to be the basis for color vision abnormality. While its effect on PDE-5 may increase cGMP level and increase smooth muscle relaxation in vascular tissues and increased inflow of blood. Sildenafil also causes dilation of systemic vasculature and possibly the choroidal circulation and may lead to central serous chorioretinopathy.<sup>4,5</sup>

CSR has been associated with pachychoroid complex, in which the choroid is thicker than in normals.<sup>8</sup> Choroidal thickness increase in response to systemic sildenafil that it could secondarily affect retinal function and increase choroidal blood flow.<sup>9</sup> There may be

an association between sildenafil's ability to increase choroidal thickness and the occurrence of CSR in this patient.

It seems that repeated use of sildenafil in young men may cause an abrupt change in the permeability of the choroidal circulation and extravasation of plasma that may lead to serous detachment of the sensory retina or retinal-pigmented epithelium, a pathology named as central serous chorioretinopathy. Also, it may cause significant visual loss, however, in contrast to nonarteritic anterior ischemic optic neuropathy that is usually reported in old men, sildenafil induced central serous chorioretinopathy is self-limited and visual loss is reversible with good prognosis.<sup>1</sup>

We concluded that in patients with central serous chorioretinopathy, advising to stop sildenafil intake should be considered.

## Disclosure

The authors report no conflicts of interest in regard to this work.

## References

1. Fraunfelder FW, Fraunfelder FT. Central serous chorioretinopathy associated with sildenafil. *Retina*. 2008;28(4):606–609. doi:10.1097/IAE.0b013e31815ec2c8
2. Allibhai ZA, Gale JS, Sheidow TS. Central serous chorioretinopathy in a patient taking sildenafil citrate. *Ophthalmic Surg Lasers Imaging*. 2004;35(2):165–167.
3. Daruich A, Matet A, Dirani A, et al. Central serous chorioretinopathy: recent findings and new physiopathology hypothesis. *Prog Retin Eye Res*. 2015;48:82–118. doi:10.1016/j.preteyeres.2015.05.003
4. Ahlers C, Geitzenauer W, Stock G, Golbaz I, Schmidt-Erfurth U, Prunte C. Alterations of intraretinal layers in acute central serous chorioretinopathy. *Acta Ophthalmol*. 2009;87(5):511–516. doi:10.1111/j.1755-3768.2008.01468.x
5. Hardwig PW, Silva AO, Pulido JS. Forgotten exogenous corticosteroid as a cause of central serous chorioretinopathy. *Clin Ophthalmol*. 2008;2(1):199–201. doi:10.2147/oph.s2165
6. Yanoga F, Gentile RC, Chui TY, et al. Sildenafil citrate induced retinal toxicity-ERG, OCT, and adaptive optics findings. *Retin Cases Brief Rep*. 2018;12:33–40. doi:10.1097/ICB.0000000000000407
7. Park HS, Yang JY, Lee J. A case of a visual field defect with optical coherence tomography changes after sildenafil citrate overdose. *J Korean Ophthalmol Soc*. 2018;59(3):288–294. doi:10.3341/jkos.2018.59.3.288
8. Cheung CM, Lee WK, Koizumi H, Dansingani K, Lai TY, Freund KB. Pachychoroid disease. *Eye*. 2018;11:1.
9. Kim DY, Silverman RH, Chan RV, et al. Measurement of choroidal perfusion and thickness following systemic sildenafil (Viagra®). *Acta Ophthalmol (Copenh)*. 2013;91(2):183–188. doi:10.1111/j.1755-3768.2011.02305.x

### Clinical Optometry

### Publish your work in this journal

Clinical Optometry is an international, peer-reviewed, open access journal publishing original research, basic science, clinical and epidemiological studies, reviews and evaluations on clinical optometry. All aspects of patient care are addressed within the journal as well as the practice of optometry including economic and business analyses. Basic and clinical research papers are published that cover

Submit your manuscript here: <https://www.dovepress.com/clinical-optometry-journal>

Dovepress

all aspects of optics, refraction and its application to the theory and practice of optometry. The manuscript management system is completely online and includes a very quick and fair peer-review system, which is all easy to use. Visit <http://www.dovepress.com/testimonials.php> to read real quotes from published authors.