

CASE REPORT

Initial temporary misdiagnosis of bronchiectasis following pumpkin seed aspiration

*Mehmet E Boleken^a, Mete Kaya^b, Adil Ozturk^c, Turan Kanmaz^b, Selçuk Yücesan^d

^a Assistant Professor of Pediatric Surgery, Harran University Medical Faculty, Sanliurfa, Turkey

^b Associate Professor of Pediatric Surgery, Harran University Medical Faculty

^c Associate Professor of Radiology, Harran University Medical Faculty

^d Professor of Pediatric Surgery, Harran University Medical Faculty

Received 18th July 2007; accepted 26th October 2007

Abstract

Undiagnosed and retained foreign bodies may result in serious complications such as pneumonia, atelectasis, or bronchiectasis. In this report, the authors present a rare case of temporary bronchiectasis of the left lung due to a long-standing retained foreign body in a child. Interestingly, the whole left lung was affected due to the check-valve type of obstruction of the main bronchus. Unexpected, unilateral findings on a chest x-ray or a CT scan could be related to an inhaled foreign body, and any delay in making the diagnosis may result in serious complications.

© 2007 General Practice Airways Group. All rights reserved.

ME Boleken *et al. Prim Care Resp J* 2007; 16(6): 384-386.

doi:10.3132/pcrj.2007.00083

Keywords Foreign body aspiration, complication, bronchiectasis, child

Introduction

Foreign body aspiration (FBA) is potentially a life-threatening emergency and requires prompt removal of the foreign body. However, the foreign body sometimes remains undetected due to an atypical history or deceptive clinical and radiological findings. An accurate diagnosis may be missed because the initial choking episode was not witnessed. Delayed residual symptoms may mimic other common conditions such as asthma, recurrent pneumonia or upper respiratory infection.¹⁻³

We report a case of FBA with delayed diagnosis in a child who had an unusual radiographic appearance of diffuse dilatation of the distal airways simulating bronchiectasis.

Case report

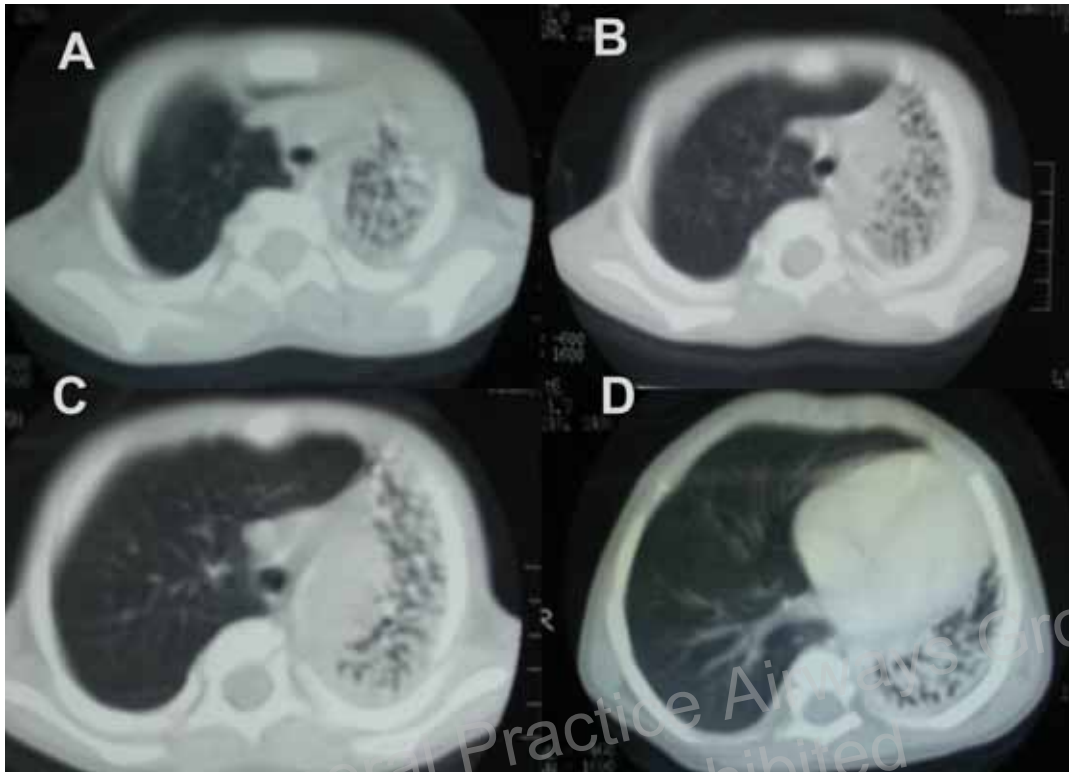
An 18-month-old boy, previously healthy, presented with a 3-month history of recurrent fever and cough. There was no definite history of witnessed FBA – such as sudden choking while holding or eating an object in the mouth – obtained

from the family. The parents had noticed elevated temperature and increasing cough for three months with no evidence of respiratory distress or cyanosis. He had been treated for pneumonia after an upper respiratory tract infection approximately two months previously, but there was little improvement and he had continuing fever and cough. He was referred to our hospital because of worsening of his respiratory symptoms.

On examination, there were coarse crepitations and decreased breath sounds on the left side. Other systems were normal. Results of routine laboratory studies were normal except for a raised white blood count (WBC) of 22.1/mm³. Plain chest radiograph (CXR) revealed atelectasis and pneumonia in the left lower lung. There was no evidence of foreign body obstruction or lymphadenopathy. Thoracic computed tomography (CT) scanning showed extensive multiple cystic dilatation of the distal airways of the upper and lower lobes of the left lung which was initially suggestive of disseminated bronchiectasis (Figure 1).

* Corresponding author: Harran Universitesi, Ars. Uyg. Hastanesi, Cocuk Cerrahisi A.D., 63100, Sanliurfa, Turkey
Tel: +90 (414) 3141170 Fax: +90 (414) 3151181 E-mail: mboleken@yahoo.com

Figure 1. CT scans display multiple small cysts in the left lung. A: Upper zone. B, C: Central zone. D: Lower zone of the left lung.



Bronchoscopy, which was performed by using an appropriate-sized pediatric ventilating rigid bronchoscope system without telescope (Karl Storz, GmbH Co, Tutlingen, Germany) showed a vegetal foreign body (pumpkin seed) with surrounding granulation and copious amounts of pus in the left main bronchus. Shell particles were successfully removed and aspirated. Intravenous steroids and antibiotics were administered. He was started on chest physiotherapy, postural drainage and mucolytic therapy.

The patient was discharged uneventfully by the end of the second week of hospitalisation without any complication. He has remained well without any symptoms after a four-month follow-up period, and a recent control CT scan was normal.

Discussion

FBA is a common, serious and potentially life-threatening problem amongst children, accounting for 7% of sudden and unexpected death in children up to the age of 3 years. FBA may result in either airway compromise and death, or serious sequels such as recurrent pulmonary infections, atelectasis, and bronchiectasis. To prevent these complications, prompt diagnosis and removal of the foreign body is mandatory.^{2,3} The diagnosis of a bronchial foreign body can be made in 91% of cases when there is a definite history of aspiration,

significant physical findings and supportive radiographic evidence. However, in some cases, there is no known history compatible with FBA, and/or the symptoms initially may be minimal and may subside quickly.^{1,3} Thus, in every medically-treated child with persistent cough, with or without a history of FBA, the possibility of retained foreign body should be kept in mind.

In 1994 Ernst *et al.* described a child with vegetal FBA whose chest CT scans showed reversible cystic dilatation of the distal airways. The extensive multiple small cysts were in the middle and lower lobes of the right lung due to obstruction of the bronchus intermedius by a foreign body.⁴ In our case, multiple small cysts of the distal airways invaded the entire left lung due to a check-valve type obstruction of the main bronchus.

Conclusion

We describe a child with FBA whose chest CT showed an unusual appearance of multiple small cysts simulating a diagnosis of bronchiectasis. Unexpected, unilateral findings on a chest x-ray or CT scan could be related to an inhaled foreign body, and these findings can be deceptive. A diagnostic bronchoscopy must be performed in all patients to rule out bronchial obstruction caused by foreign body. FBA can mimic

almost any disorder in the respiratory system. Delay in making the diagnosis and failure to act on a history of increasing symptoms may result in serious complications.

Conflict of interest declaration

There were no conflicts of interest for the authors in the preparation of this article.

References

1. Tokar B, Ozkan R, Ilhan H. Tracheobronchial foreign bodies in children:

Importance of accurate history and plain chest radiography in delayed presentation. *Clin Radiol* 2004;**59**(7):609-15.

2. Oguzkaya F, Akçali Y, Kahraman C, Bilgin M, Sahin A. Tracheobronchial foreign body aspirations in childhood: A 10-year experience. *Eur J Cardiothorac Surg* 1998;**14**(4):388-92.
3. Ciftci AO, Bingöl-Kologlu M, Senocak ME, Tanyel FC, Büyükpamukçu N. Bronchoscopy for evaluation of foreign body aspiration in children. *J Pediatr Surg* 2003;**38**(8):1170-6.
4. Ernst KD, Mahmud F. Reversible cystic dilatation of distal airways due to foreign body. *South Med J* 1994;**87**(3):404-06.

Available online at <http://www.thepcrj.org>

Copyright General Practice Airways Group
Reproduction Prohibited