

# Getting Better Results in Facelifting

Rod J. Rohrich, MD\*  
Sammy Sinno, MD†  
Elbert E. Vaca, MD‡

**ABSTRACT:** The facelift has significantly evolved over the past several decades. What was once considered a skin only operation is now a sophisticated, elegant procedure that requires meticulous preoperative analysis, understanding of underlying anatomically based aging changes, and extreme attention to detail. According to the American Society of Plastic Surgeons, 125,697 facelifts were performed in 2017. It is not surprising that given these advances that facial rejuvenation surgery is still a very common procedure with a high degree of patient satisfaction despite the increase in nonsurgical facial aging treatments. With an improved understanding of facial anatomy including the facial retaining ligaments and intervening superficial and deep fat compartments, the modern facelift requires an anatomically targeted approach. Furthermore, the modern facelift surgeon must achieve consistently excellent results with reasonably little downtime while being aware of methods to improve the safety of this popular elective procedure. Hematoma is the most common complication after rhytidectomy with an incidence between 0.9% and 9%, with a higher incidence in males. Other potential complications include seroma, nerve injury, skin flap necrosis, siaolocele as a consequence of submandibular gland debulking, and skin flap rhytid and hairline distortion. This review aims to discuss safe, consistent, and reproducible methods to achieve success with facelift. (*Plast Reconstr Surg Glob Open* 2019;7:e2270; doi: 10.1097/GOX.0000000000002270; Published online 7 June 2019.)

## BACKGROUND

The facelift has significantly evolved over the past several decades. What was once considered a skin only operation is now a sophisticated, elegant procedure that requires meticulous preoperative analysis, understanding of underlying anatomically based aging changes, and extreme attention to detail. According to the American Society of Plastic Surgeons, 125,697 facelifts were performed in 2017.<sup>1</sup> It is not surprising that given these advances that facial rejuvenation surgery is still a very common procedure with a high degree of patient satisfaction<sup>2</sup> despite the increase in nonsurgical facial aging treatments.<sup>1</sup>

With an improved understanding of facial anatomy including the facial retaining ligaments and intervening superficial and deep fat compartments,<sup>3–5</sup> the modern facelift

requires an anatomically targeted approach. Furthermore, the modern facelift surgeon must achieve consistently excellent results with reasonably little downtime while being aware of methods to improve the safety of this popular elective procedure. Hematoma is the most common complication after rhytidectomy with an incidence between 0.9% and 9%, with a higher incidence in males.<sup>6–12</sup> Other potential complications include seroma, nerve injury, skin flap necrosis, siaolocele as a consequence of submandibular gland debulking, and skin flap rhytid and hairline distortion. This review aims to discuss safe, consistent, and reproducible methods to achieve success with facelift.

## ANATOMY

The superficial musculoaponeurotic system (SMAS) is the investing fascia of the facial mimetic muscles and is continuous with the platysma inferiorly and galea superiorly.<sup>13–15</sup> Laterally, the SMAS is firmly adherent to the parotid–masseteric fascia where it is known as the immobile SMAS. The facial retaining ligaments transmit through the SMAS to the overlying skin, either originating from the periosteum (zygomatic and mandibular retaining ligaments) or from underlying muscle fascia (masseteric and cervical retaining ligaments).<sup>5,14</sup> These retaining ligaments also serve as barriers between the superficial and deep facial fat compartments with neurovascular struc-

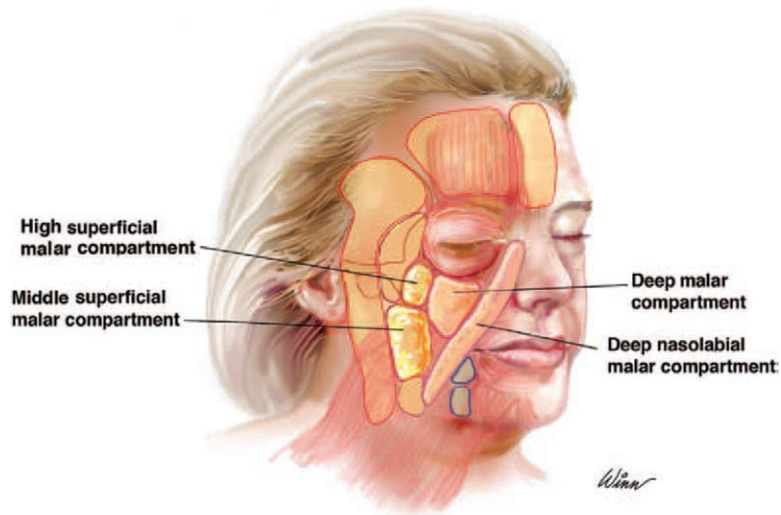
From the \*Private Practice, Dallas Plastic Surgery Institute, Dallas, Tex.; †Private Practice, TKLM Plastic Surgery, Chicago, Ill.; and ‡Division of Plastic and Reconstructive Surgery, Northwestern Feinberg School of Medicine, Chicago, Ill.

Received for publication January 20, 2019; accepted April 2, 2019.

Copyright © 2019 The Authors. Published by Wolters Kluwer Health, Inc. on behalf of The American Society of Plastic Surgeons. This is an open-access article distributed under the terms of the Creative Commons Attribution-Non Commercial-No Derivatives License 4.0 (CCBY-NC-ND), where it is permissible to download and share the work provided it is properly cited. The work cannot be changed in any way or used commercially without permission from the journal.

DOI: 10.1097/GOX.0000000000002270

**Disclosure:** The authors have no financial interest to declare in relation to the content of this article.



**Fig. 1** Facial fat compartments. Fat grafting of the labeled fat compartments is critical in the “lift-and-fill” face lift technique. Reprinted with permission from *Plast Reconstr Surg.* 2014;133:756e–767e)

tures, or “facial danger zones,” located between these retaining ligaments.<sup>3,4,16–18</sup>

### AGING CHANGES

Facial aging changes occur due to a combination of soft tissue deflation, decent, and ligamentous laxity, resulting in predictable aging patterns and radial expansion of the face.<sup>19</sup> Skeletal regression, particularly in the inferolateral orbital rim and alveolar ridges, contributes to loss of midfacial support and loss of overall facial height.<sup>20–22</sup> Furthermore, the gradual loss of skin elasticity and dermal thinning contributes to rhytid formation and can be exacerbated by smoking and ultraviolet radiation exposure.<sup>23</sup>

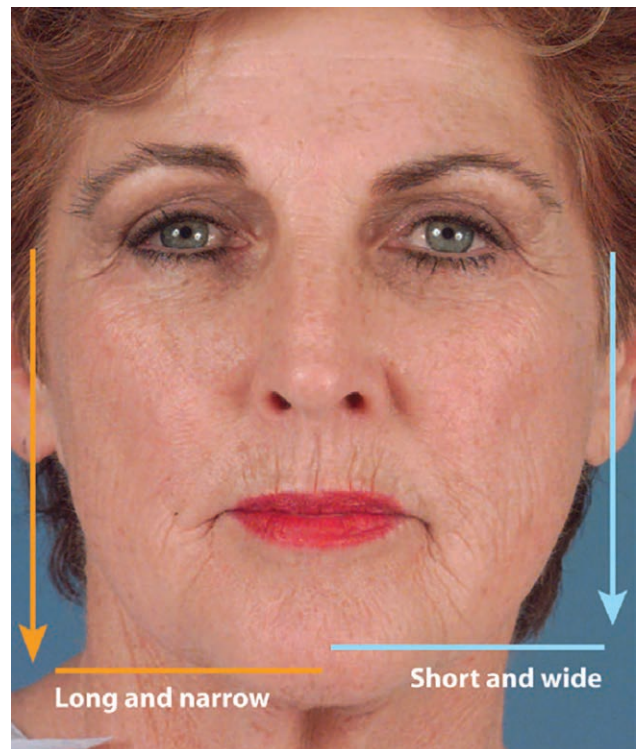
Accordingly, modern facelift techniques should be tailored to address the underlying culprits of facial aging. Soft tissue decent and ligamentous laxity are corrected by SMAS repositioning and ligamentous release. The architecture of the facial fat compartments has been previously detailed (Fig. 1).<sup>3,4</sup> Fat grafting directly treats facial fat compartment deflation.<sup>24,25</sup> Therefore, the modern facelift should involve a “Lift-and-Fill” approach.<sup>25</sup>

### FACIAL ANALYSIS AND PREOPERATIVE PLANNING

On examination, facial horizontal fifths and vertical thirds are analyzed to determine overall facial balance, making note of any asymmetries. The relationship between facial length, midfacial width, and overall fullness is critical as this guides the customized surgical intervention which, depending on asymmetries in the individual patient, may vary on each side (Fig. 2).<sup>26</sup> The neck, décolletage, and skin elasticity and quality are evaluated. The patient is asked to provide photographs from youth to better assess areas of volume loss and changes that have occurred with time. Standardized facial photographs are obtained and essential for preoperative planning, patient counseling, and

medicolegal purposes. It is important to note if the patient would benefit from ancillary procedures including brow lift, blepharoplasty, rhinoplasty, lip lift, genioplasty, and skin resurfacing procedures to improve facial aesthetic harmony.

A thorough patient history and physical examination are performed. A full list of medications and supplements must be reviewed to ensure no consumption of blood thin-



**Fig. 2.** Preoperative analysis for the individualized component facelift. Anteroposterior view is used to determine midface width, height, and overall facial shape and soft-tissue distribution. Reprinted with permission from *Plast Reconstr Surg.* 2009;123:1050–1063.

ners. Any patient over 50 requires an electrocardiogram (EKG) in addition to full laboratory testing which includes blood counts, coagulation profile, and even electrolytes as it has been shown certain medications can cause potentially serious electrolyte disturbances perioperatively.<sup>27</sup> Particular attention is paid to a history of hypertension and nicotine product use. If present, hypertension must be medically optimized and necessary medical clearances are obtained before surgery. The patient must cease nicotine product use for a minimum of 3 months before surgery to decrease the risk of skin flap necrosis. In smokers, urine nicotine metabolites are tested 1 month before surgery to confirm abstinence. Furthermore, the history of nonsurgical treatments including neuromodulators, fillers, and energy-based devices is noted as the authors have observed increased scarring in these patients during dissection.

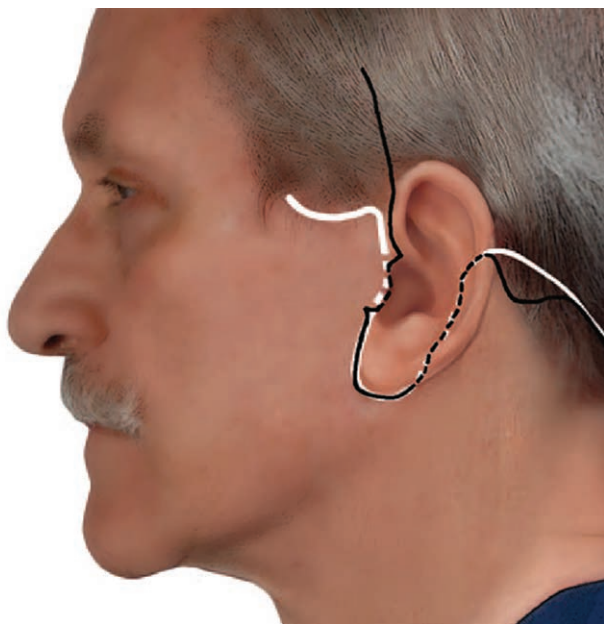
## INCISION PLANNING

### Temporal Incision

The distance between the lateral orbital rim and the anterior temporal hairline is assessed (Fig. 3). Skin redundancy and the anticipated amount of temporal skin excision is determined. If the estimated postoperative lateral orbital rim to anterior hairline distance is  $\leq 5$ cm (ie minimal temporal skin resection), then the temporal portion of the incision can be concealed behind the hairline. If the anticipated distance is  $>5$ cm, then a prehairline incision is chosen to prevent postsurgical sideburn distortion.<sup>28,29</sup>

### Preauricular Incision

The incision follows the ear–cheek junction curvature, except for the tragus, where a choice is made between a pre or intertragal incision. A pretragal incision may be



**Fig. 3.** The rhytidectomy incision. *White line*, incision used by R.J.R.; *black line*, incision used by J.M.S.. Reprinted with permission from *Plast Reconstr Surg.* 2017;139:295–307.

appropriate if there is a prominent preauricular crease, a tall vertical tragus, or prominent lateral cheek hair follicles. Otherwise, the majority of patients are best served by an intertragal incision to prevent postsurgical skin color and texture mismatch of the tragus and lateral cheek. Along the ear lobule, the incision is made 1 mm caudal to the cheek–lobule junction to prevent distortion of the interface between these anatomic units.

### Retroauricular Incision

The incision continues into the retroauricular sulcus and is carried cephalically up to the mid ear. The decision to either carry the incision posteriorly into the scalp or inferiorly along the occipital hairline at the junction of the thin and thick hair is based on the estimated skin resection.<sup>29</sup> If  $>2$  cm of retroauricular skin resection is anticipated, then the incision is made along the occipital hairline to prevent a step off in the occipital hairline.

### Submental Incision

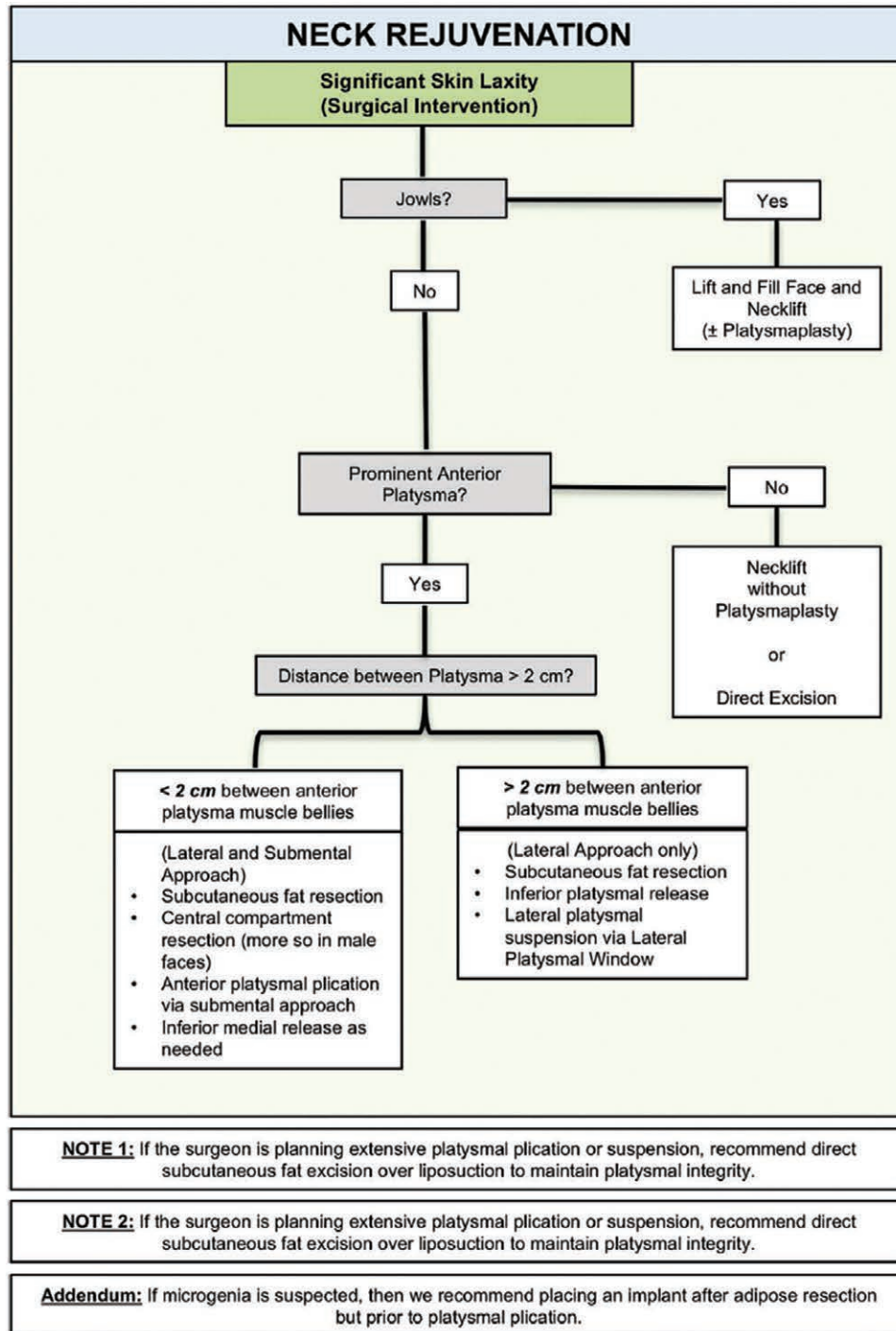
The decision to open the neck is determined preoperatively based on the presence of cervical skin laxity and is accessed via a 3–4 cm incision marked 1–2 cm posterior to the submental crease.<sup>30</sup> Surgical maneuvers are tailored to the individual patient. Considerations include the amount and location of excess cervical adiposity, the presence of jowling, severity of dynamic and static platysmal banding, and the distance between the medial platysmal borders ( $<$  or  $>2$  cm; Fig. 4).<sup>31</sup> Other authors advocate a more aggressive lateral platysmaplasty while avoiding a submental incision.<sup>32,33</sup> Because the success of a modern facelift is often judged by the quality of the neck contour correction, in the authors experience, there is a low threshold to open the neck as doing so allows the ability to tighten via midline platysmaplasty, sculpt subplatysmal contents, and reduce the incidence of recurrent platysmal bands.<sup>34</sup>

## ANESTHESIA AND PERIOPERATIVE MANAGEMENT

Hypertension is a controllable risk factor for hematoma;<sup>35,36</sup> therefore, strict multimodal blood pressure control is essential to minimize complications (Fig. 5).<sup>37</sup> Anxiety, pain, nausea, and vomiting are preemptively managed (Fig. 6). All patients receive 2 mg of midazolam in the preoperative holding area. Males and patients with a history of hypertension undergo placement of a 0.2-mg clonidine transdermal patch—in all other patients, a 0.1-mg clonidine patch is placed.

General anesthesia is preferred. The endotracheal tube is placed midline and not secured, as it is monitored closely intraoperatively. Nitrous oxide is avoided due to an increased risk of postoperative nausea. Inhalational anesthetics are also avoided due to their propensity to cause vasodilation.<sup>37</sup> Dexamethasone (8 mg IV) is given after induction for both edema and nausea management, and 4 mg of IV ondansetron is given 30 minutes before emergence. Sequential compression devices are placed, and an indwelling urinary catheter is inserted. The face is widely prepped with ophthalmic betadine and 2 g IV cefazolin is given 30 minutes before incision. As previously described by the se-





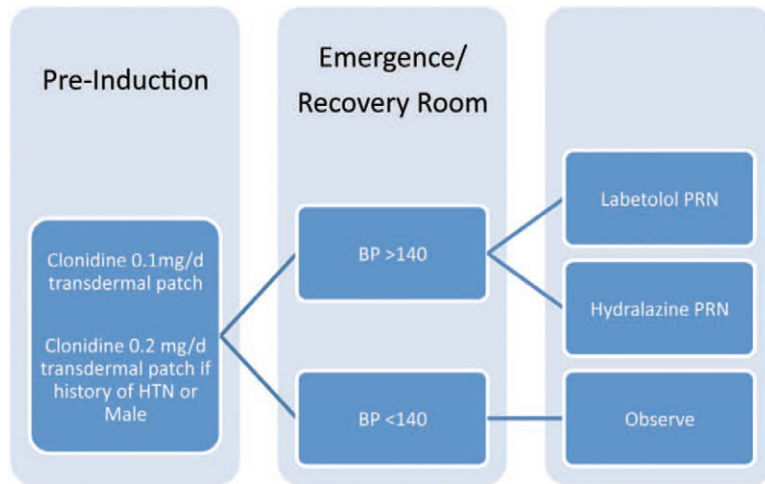
**Fig. 4.** Neck rejuvenation algorithm for patients with moderate to severe skin laxity. Reprinted with permission from *Plast Reconstr Surg.* 2017;140:405e–414e.

nior author (R.J.R.), venous blood is drawn upon induction to extract platelet-rich plasma.<sup>6</sup> The platelet-rich plasma is then drawn into a 10-cm<sup>3</sup> dual-port sprayer syringe, with the second syringe containing an activating thrombin solution. Before skin closure, the activated platelet-rich/thrombin mixture is sprayed between the skin flap and underlying SMAS to help decrease ecchymosis and edema.<sup>6,38</sup> The face-lift incisions are then marked as previously described, based

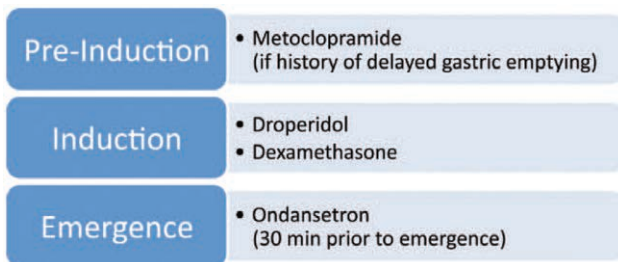
on preoperative assessment for optimal scar concealment and to minimize hairline distortion.

### FILLING OF THE FACIA FAT COMPARTMENTS

Fat grafting is performed at the beginning of the procedure to ensure meticulous injection and to minimize



**Fig. 5.** Hypertension management algorithm. HTN, hypertension; BP, blood pressure; PRN, as needed. Reprinted with permission from *Plast Reconstr Surg.* 2015;135:723–730.



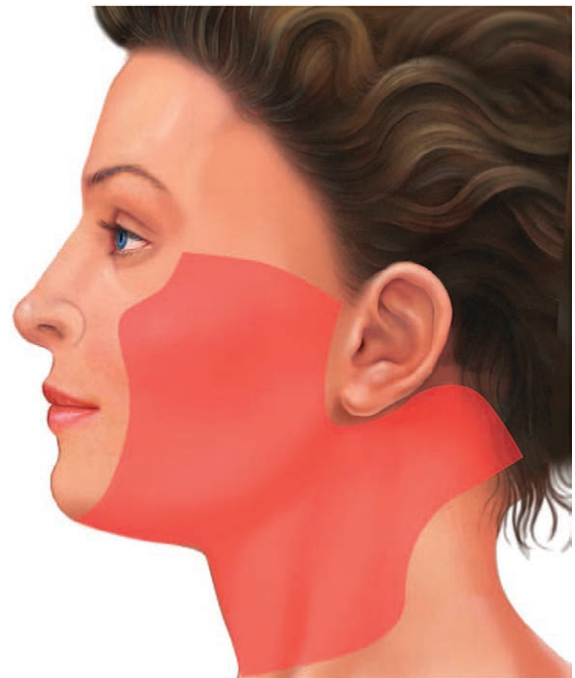**Fig. 6.** Nausea and vomiting prevention algorithm. Reprinted with permission from *Plast Reconstr Surg.* 2015;135:723–730.

fat graft contamination. For details regarding the senior author’s (R.J.R) technique, please refer to our prior article by Pezeshk et al.<sup>24</sup> Nasolabial fold correction and restoration of youthful malar projection are by means of anatomically targeted fat grafting to the deep malar, deep nasolabial malar, and the high and middle superficial malar fat compartments (Fig. 1). Typically, 1–3 ml of fat are injected per compartment.<sup>25</sup> Additionally, perioral, ear-lobe, temple fat grafting is performed if indicated.

### INDIVIDUALIZED SKIN FLAP ELEVATION

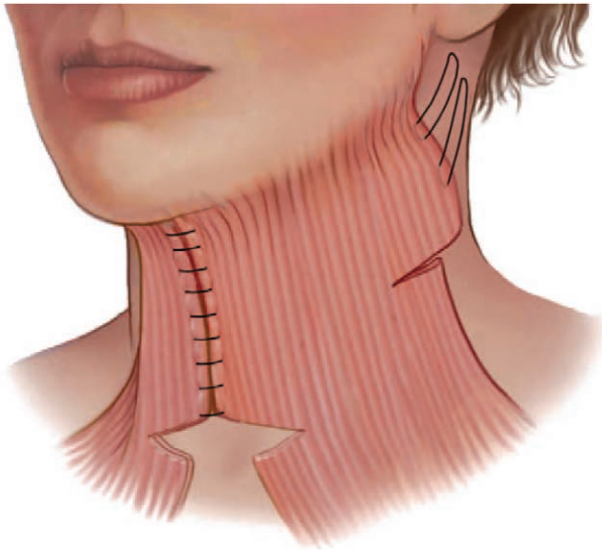
A 22-gauge spinal needle is used to inject 80–120 ml of infiltrate solution per side for the purpose of hemostasis and hydrodissection of the tissue planes. The infiltrate solution consists of 30 ml of 0.5% lidocaine and 1.5 ml of epinephrine (1:1,000) mixed with 300 ml of normal saline.<sup>6</sup> The needle is inserted along the marked facelift incisions to prevent additional flap trauma, with the solution infiltrated in the subcutaneous plane. The endpoint for infiltration is moderate and uniform skin turgor of the facial tissues. Ten minutes are allowed to elapse after infiltration before incision for optimal hemostatic effect.

The marked facelift incisions are then completed with a 15 blade and the skin flaps are raised in the subcutaneous plane with facelift scissors. At least 3 mm of



**Fig. 7.** Individualized component facelift—undermining and SMA-Sectomy vs SMAS-stacking. Reprinted with permission from *Plast Reconstr Surg.* 2009;123:1050–1063.

subcutaneous fat is left on the skin to maintain flap vascularity and to prevent contour irregularities. The extent of skin undermining is individualized to the shape and width of the patients face (Fig. 7)<sup>26,35,39</sup> and is ultimately determined intraoperatively once the SMAS maneuvers have been completed to confirm skin redraping without puckering. Limited skin flap elevation is performed in faces with mild skin laxity and wide malar width. In contrast, long faces with narrow bimaxillary width, jowling, and redundancy medial to the lateral canthus require extended skin undermining for more complete release of



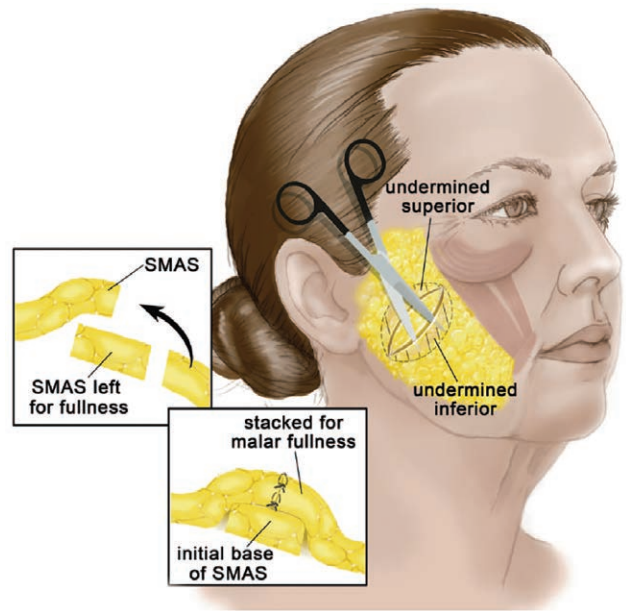
**Fig. 8.** Area of subcutaneous skin flap undermining indicated in red. Reprinted with permission from *Plast Reconstr Surg.* 2006;118:1251–1263.

the mandibular septum, zygomatic, and masseteric retaining ligaments for proper skin redraping and medial SMAS advancement (Fig. 8).<sup>26,39</sup> Of note, medial perial dissection is avoided as this results in postoperative deformities with facial animation due to dissociation of the skin with the underlying facial musculature.<sup>29,39</sup>

### OPEN TREATMENT OF THE NECK

If the decision is made to open the neck, the submental incision is opened, and the facial/neck skin subcutaneous planes are connected. The senior author (R.J.R) has abandoned submental liposuction due to the high incidence of contour irregularities. In the appropriately selected patient, the authors perform preplatysmal and central subplatysmal fat resection under direct vision.<sup>30</sup> On a technical note, preplatysmal fat is resected from lateral to medial as it is easy to inadvertently enter the subplatysmal plane with a medial approach. The medial platysma borders are plicated with figure-of-eight 4-0 Mersilene from the inferior mandibular border down to the level of the thyroid cartilage, followed by a 2-cm inferior transverse platysma myotomy (Fig. 9).<sup>34</sup> Some authors advocate for more aggressive subplatysmal surgery including submandibular gland resection and digastric shaving<sup>28,40</sup>; however, a steep learning curve is required, and notable complications include marginal mandibular nerve palsy, salivary leak, and hematoma with potentially life-threatening airway compromise<sup>41</sup>; therefore, the senior author refrains from other subplatysmal procedures to minimize potential complications. In the scenario of prominent submandibular glands, 10 units of Botox (Allergan, Inc., Irvine, Calif.) are directly injected into the gland intraoperatively and then at 6–8 weeks postoperatively to promote submandibular gland atrophy.<sup>34</sup>

The sequence of SMAS/lateral platysmaplasty and medial platysmaplasty is debated by some authors. Of note,



**Fig. 9.** Inferomedial platysma is transected, platysmal midline stitches are placed, and a lateral platysmal window is performed. Reprinted with permission from *Plast Reconstr Surg.* 2006;118:1251–1263.

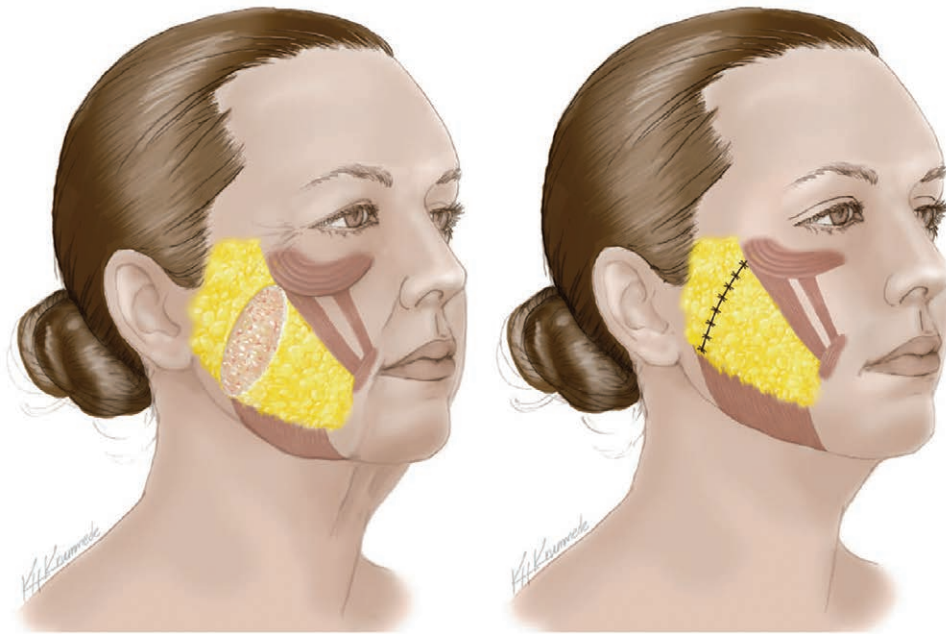
proponents of SMAS maneuvers before medial platysmaplasty believe that medial platysmaplasty “locks down” the SMAS and limits lateral SMAS correction.<sup>42</sup> However, the authors prefer to complete the medial platysmaplasty first, as they have not noticed subsequent restriction in lateral SMAS correction.

### LATERAL PLATYSMAL WINDOW AND SMAS MANEUVERS

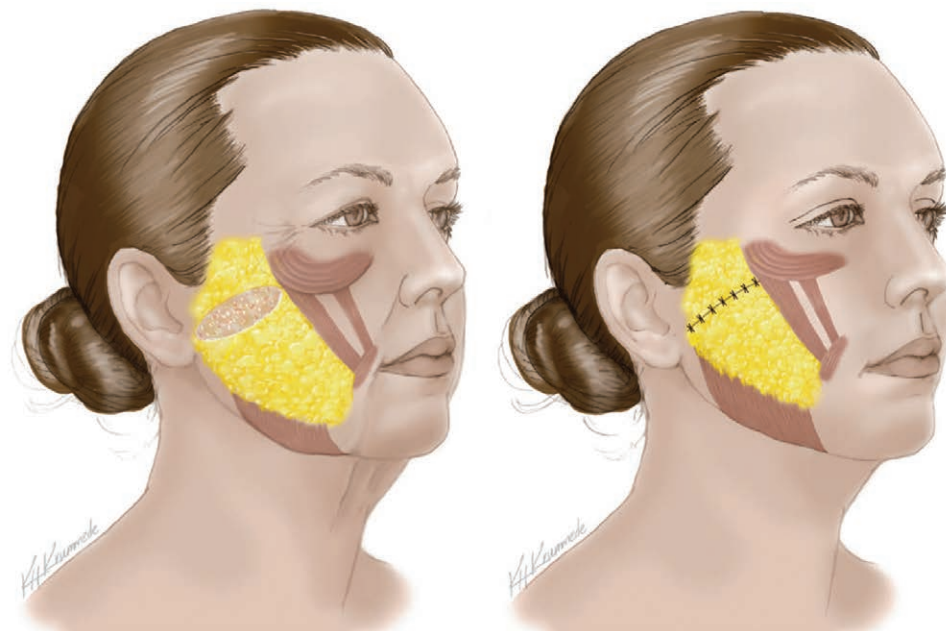
A 2-cm lateral subplatysmal “window” is made approximately 1 finger breadth below the mandibular angle and 1 cm anterior to the SCM border to avoid the great auricular nerve.<sup>30,43</sup> The lateral platysma flap is secured to the mastoid fascia with 2 figure-of-eight spanning 3-0 Mersilene sutures (Ethicon, Inc., Somerville, N.J.).

The decision of which SMAS technique to use is somewhat a topic of debate, including SMAS plication,<sup>44</sup> SMASectomy,<sup>10,45</sup> extended SMAS flap,<sup>19</sup> high SMAS,<sup>46,47</sup> and deep plane<sup>32,48</sup> techniques. Despite the plethora of available techniques, the authors feel that the most reproducible, safe, and efficient techniques are SMAS-stacking for patients that need volume (ie long and narrow faces; Fig. 10) or SMASectomy for patients that need tissue debulking (ie wide, heavy faces; Fig. 11).<sup>26</sup> In narrow faces, the long axis of SMASectomy or stacking is performed obliquely along a line from the lateral canthus to the gonial angle to improve midfacial width. However, a more horizontal vector is used in wide faces to improve submalar hollowing and avoid further midfacial widening (Figs. 12 and 13). The SMAS is secured with figure-of-eight 3-0 Mersilene (Ethicon, Inc., Somerville, N.J.), followed by running 4-0 Mersilene (Ethicon, Inc.) to prevent SMAS irregularities.





**Fig. 10.** SMAS-stacking. SMAS incision and plication serve to stack tissue in the direction that the SMAS is lifted. The SMAS base remains while limited proximal and distal SMAS undermining allows the surgeon to create a 3-layered construct. This is beneficial in narrow faces that need more fullness in the malar region. This orientation of the SMAS-stacking will dictate where this augmentation is produced. Reprinted with permission from *Plast Reconstr Surg.* 2009;123:1050–1063.

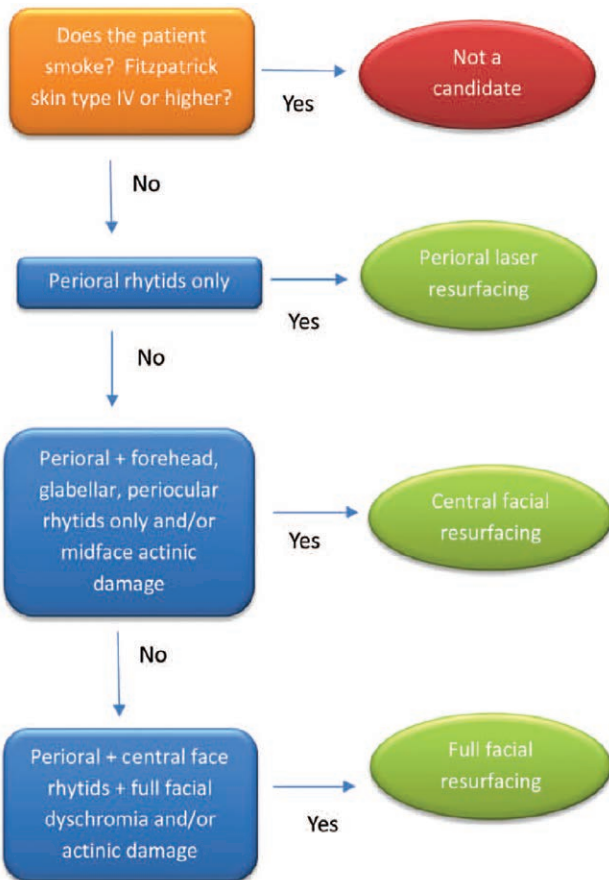


**Fig. 11.** The oblique SMASectomy. SMAS movement is directed perpendicular to the nasolabial fold. This is beneficial for the narrower facial side. (Reprinted with permission from *Plast Reconstr Surg.* 2009;123:1050–1063.)

### SKIN REDRAPING AND CLOSURE

The skin flaps are redraped along a posterosuperior vector—care is taken not to recruit cervical rhytids onto the face, as iatrogenic rhytid displacement is a telltale sign of a poorly executed facelift. As previously described, the

final extent of skin flap undermining is completed to assure the absence of skin puckering. Gauze moistened with a 3% tranexamic acid solution is placed beneath the skin flaps and allowed to sit for 3–5 minutes to help reduce bleeding, bruising, and edema.<sup>49–51</sup>



**Fig. 12.** Horizontal SMASectomy. SMASectomy is oriented horizontally so that the SMAS moves in a vertical direction. This recruits more tissue superiorly, therefore increasing medial malar fullness while creating relative submalar hollowing. This technique is used for the wide midface so that excessive width is not recruited laterally, where it is not needed. Reprinted with permission from *Plast Reconstr Surg.* 2009;123:1050–1063.

The tranexamic acid-soaked gauze is removed, and the skin flaps are then conservatively trimmed and inset with minimal tension. Platelet-rich plasma/thrombin mixture is sprayed between the skin and SMAS layers. A closed suction drain is placed in the neck via a stab incision in the occipital scalp. Sparing 3-0 Monocryl (Ethicon, Inc.) deep dermal sutures are used, followed by 5-0 Nylon (Ethicon, Inc.) interrupted skin sutures. Staples are used on the incisions in hair-bearing areas. It is important to highlighting that if a intertragal approach is performed, the tragal skin flap is defatted, and the surgeon must be cognizant of the need for additional skin to account for the pretragal concavity—failure to account for this will result in “tenting” of the skin flap in the pretragal area and tension on the tragus, leading to tragal eversion and exposure of the auditory canal. The submental incision is closed with a running external 5-0 Nylon suture (Ethicon, Inc.). Avoidance of tension on the skin closure is paramount to avoid postoperative scar widening and auricular distortion.

In patients who benefit from skin resurfacing (Fig. 14), the senior author (R.J.R.) has demonstrated that laser resurfacing and facelifting can be safely performed concomitantly after skin closure.<sup>52</sup> In these patients, 500 mg of acyclovir 4 times daily for 7 days is commenced the day before surgery. Profile dual-mode erbium–aluminum–garnet (Sciton, Inc., Palo Alto, Calif.) laser is used with 2 passes with 50% overlap over nonundermined areas, and one oblique angle pass over undermined areas. Pre, intra, and postoperative considerations are essential to optimize safety and wound healing after skin resurfacing (Fig. 15).

Xeroform gauze and bacitracin are placed over the incisions followed by gauze then a kerlix head wrap and stockinette head dressing. The surgeon must be cognizant of the inelasticity of gauze dressings and anticipate a degree of postoperative edema; therefore, the kerlix wrap must be loosely applied to avoid pressure on the skin flaps.

**Principles Optimizing Safety and Efficacy During Laser Resurfacing with Rhytidectomy**

**Pre-operative Considerations**

- No active or recent tobacco users
- Fitzpatrick 1 and 2 skin types
- Start acyclovir 1-2 days prior to procedure

**Intra-operative Considerations**

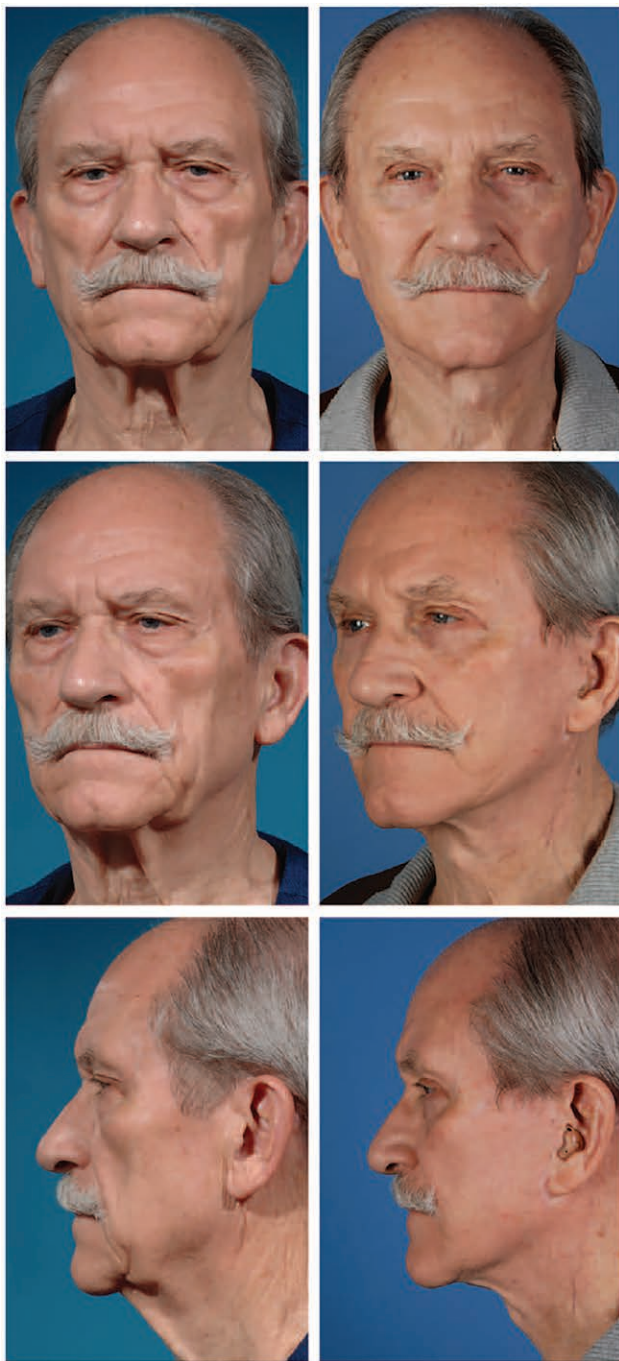
- Thick, well-vascularized flaps are essential
- Use of ablative mode only
- <100 microns ablation in undermined areas for blending

**Post-operative Considerations**

- Complete 7 day course of acyclovir
- Use of semi-occlusive dressings to maximize wound healing and patient comfort
- Frequent follow-up every 2-3 days for first 10 days until laser areas completely healed to monitor skin and perform dressing changes
- Early and aggressive use of tretinoin and hydroquinone therapy to prevent and/or treat post-inflammatory hyperpigmentation

**Fig. 13.** Individualized component facelift—SMAS shaping. Reprinted with permission from *Plast Reconstr Surg.* 2009;123:1050–1063.





**Fig. 14.** Algorithm for face lift combined with laser resurfacing. Reprinted with permission from *Plast Reconstr Surg.* 2015;136:27–38.

### POSTOPERATIVE MANAGEMENT

Patients are kept overnight with strict postoperative blood pressure, pain, and nausea management to prevent hematoma. The surgical dressings are changed the first postoperative day, and the neck drain is removed. The patient is allowed to return to regular activity 6 weeks after surgery and kept on a low-sodium diet for 1 month. Although the data are conflicting,<sup>53,54</sup> a single 8mg dose of intraoperative dexamethasone is given for both nausea

prevention and to potentially decrease facial edema in the immediate postoperative period. However, available evidence at this time does not support the use of postoperative steroid use.<sup>55,56</sup> An exception is in patients who undergo laser skin resurfacing, who are started on a methylprednisolone dose pack taper on postoperative day 1.

### SPECIAL CONSIDERATIONS

#### The Male Patient

According to the 2017 American Society of Plastic Surgeons statistics, 11,719 or 9% of all facelifts were performed in males.<sup>1</sup> While many similarities exist with the approach to the female patient, the male patient requires special considerations (Figs. 16 and 17).<sup>57</sup> Furthermore, male patients are counseled to avoid vasoactive medications (eg, Viagra; Pfizer, New York, N.Y.) for 4 weeks postoperatively.

#### Secondary and Tertiary Facelifts

The secondary and tertiary facelift patients tend to be older and often present with iatrogenic deformities from their prior rhytidectomy (Fig. 18). Furthermore, secondary facelifts require more volumization and minimal, if any, skin excision. Pixie ear deformity (ie, tethered appearing and anteriorly rotated lobule) is common and requires anatomic posterior lobule rotation, scar excision and avoidance of skin flap tension. Other deformities include sideburn distortion and the “windswept” deformity. Skin flap elevation is more difficult due to scarring of the tissue planes, making the use of infiltrating solution evermore critical for hydrodissection.<sup>58</sup> The senior author (R.J.R) endorses the “five Rs” of secondary facelift which include resection of prior scar, release of the SMAS, reshaping via tissue stacking and volumization, and skin release and redraping to correct depressions, “windswept” and J-deformities.<sup>59</sup>

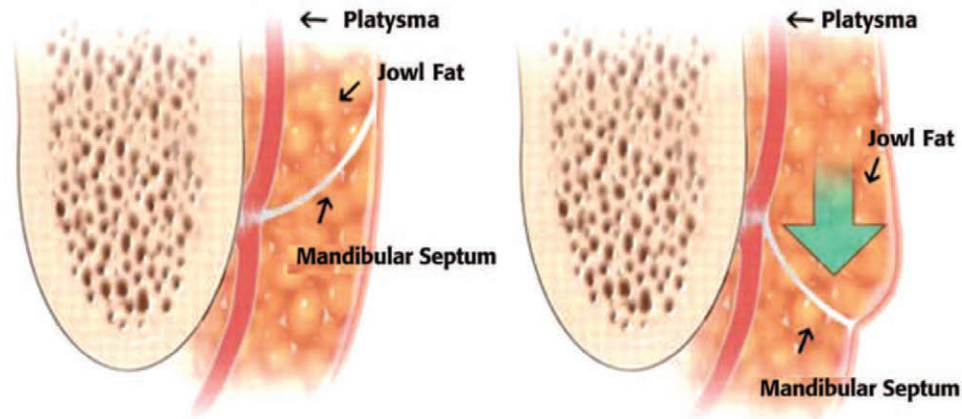
### MANAGEMENT OF COMPLICATIONS

#### Hematoma

Prompt recognition is paramount as large hematomas can result in skin flap necrosis and airway compromise. Although smaller hematomas are not life threatening, failure to evacuate these results in scarring and contour irregularities that are difficult to treat secondarily. Large hematomas require return to the operating room. Small hematomas can be aspirated with a 16-gauge needle 5–7 days after surgery in clinic, once the hematoma has liquified.

#### Seroma

Use of a closed neck drain helps avoid most seromas as they usually occur the most gravity-dependent areas. A chin strap is also used as a compression garment to close dead space.<sup>60</sup> If a seroma occurs, it should be serially drained by aspiration until resolved. For persistent areas of induration and if the seroma cannot be aspirated, injections of Kenalog 10mg/ml diluted with 1% lidocaine injections are used.



**Fig. 15.** Principles optimizing safety and efficacy during laser resurfacing during laser resurfacing with rhytidectomy. Reprinted with permission from *Plast Reconstr Surg.* 2015;136:27–38.

**Secondary Rhytidectomy Patient Analysis**

1. Evaluate for stigmata of primary facelift
  - a. Prominent scars
  - b. Hairline distortion
  - c. Ear deformities
    - Anteriorly displaced tragus
    - Pixie ear
  - d. Cheek deformity
    - Lateral sweep
    - Commissural distortion
    - Cross cheek depression/joker lines
    - Submalar hollow
    - Smile block
    - Flattening of facial contour
  - e. Neck deformities
    - Platysmal banding
    - Hollowing/cobra neck deformity
    - Skin pleating
2. Evaluate natural signs of aging
  - a. Re-ptosis of previously lifted tissues
  - b. Volumetric deflation

**Fig. 16.** Photographs obtained preoperatively (A) and 18 months postoperatively (B) of a 75-year-old man who underwent SMASectomy and plication with deep malar fat augmentation. Reprinted with permission from *Plast Reconstr Surg.* 2017;139:295–307.

**Recurrent Platysmal Bands**

Recurrent banding is most common medially. A low threshold for a submental incision and medial platysmal plication helps to decrease the incidence of recurrent platysmal bands. Despite appropriate operative interventions, platysmal bands may still recur. In these patients, either reoperation or Botox (Allergan, Inc., Irvine, Calif.) can be used.<sup>34</sup>

**Persistent/Recurrent Jowling**

Persistent jowling can result from insufficient mandibular retaining ligament release and jowl fat pad

Midface Analysis (length/width)	Skin Undermining Extent	Stacking* versus SMAS-ectomy
Long/narrow	Extended†	SMAS-stacking
Short/wide	Limited‡	SMAS-ectomy
Long/wide (uncommon)	Limited	SMAS-ectomy
Short/narrow	Extended	SMAS-stacking

\*SMAS-stacking refers to SMAS incision, limited undermining, advancement, and resuturing to stack the three SMAS layers.  
 †Extended: medial to zygomatic major muscle and lateral canthus.  
 ‡Limited: Does not extend medial to lateral canthus.

**Fig. 17.** Differences and treatment modifications in male rhytidectomy.

Midface Analysis (length/width)	SMAS Shaping Angle
Long/narrow	Oblique*
Short/wide	Horizontal†
Long/wide (uncommon)	Horizontal
Short/narrow	Oblique

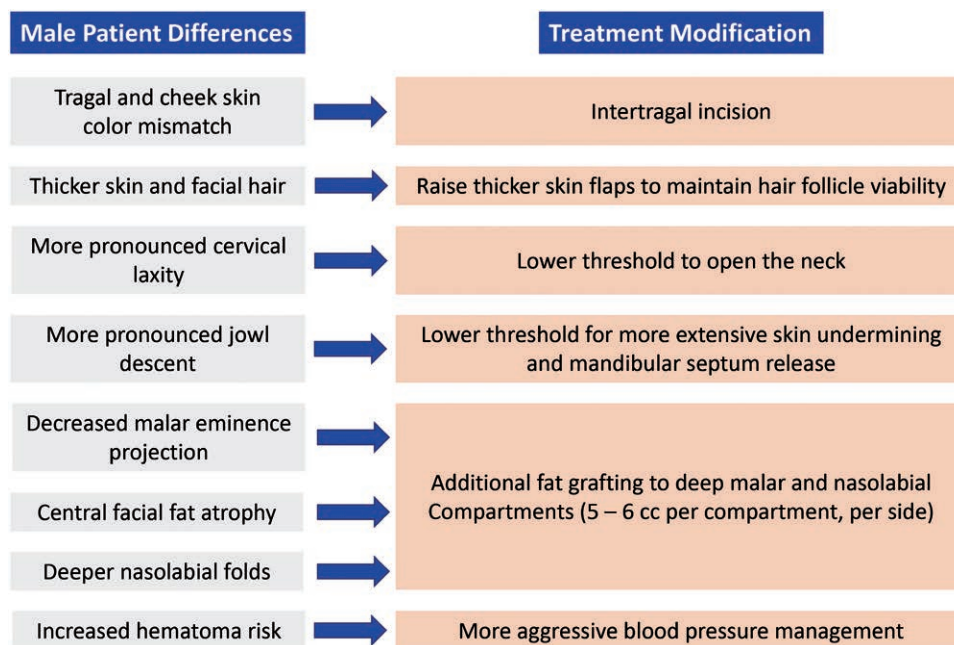
\*Oblique is defined as parallel to nasolabial fold. SMAS moves obliquely.  
 †Horizontal is defined as parallel to orbital rim line. SMAS motion is vertical.

**Fig. 18.** Laxity and descent of the mandibular septum leading to jowl formation. Reprinted with permission from *Plast Reconstr Surg.* 2013;132:339–350.

lipodystrophy (Fig. 16). Extended skin undermining with release of the mandibular retaining ligament, with direct fat excision if necessary, is critical in patients with prominent jowls.<sup>61</sup> Targeted liposuction and/or fat grafting is used for secondary jowl bulges or jawline scalloping, respectively.<sup>34</sup>

**Skin Necrosis**

Avoiding surgery in high-risk patients (ie, nicotine product users) and maintaining at least 3 mm of fat on the skin flap undersurface prevent the majority of cases. Exacerbating factors such as excess skin tension is avoided and hematoma, if present, must be promptly addressed. Nitroglycerin ointment can be applied in the operating room over compromised appearing areas. Otherwise, areas of



**Fig. 19.** Secondary rhytidectomy patient analysis. Reprinted with permission from *Plast Reconstr Surg.* 2012;130:1370–1378.

necrosis are conservatively managed with daily cleaning and triple antibiotic ointment application until the ischemic margins fully declare themselves and the eschar falls off. Areas that have healed by secondary intention can be addressed at a later date with scar revision.

#### Marginal Mandibular Nerve Palsy

Conservative management is used. Neuropraxia is the most common culprit and expected to resolve within 3 months of surgery. Contralateral depressor angularis oris neurotoxin injection can be used as a temporizing measure to improve smile symmetry.

#### Sialocele

The senior author (R.J.R.) avoids submandibular gland surgery as this risks sialocele formation and bleeding complications. Salivary leaks can be managed by serial aspiration, anticholinergics, and neurotoxin injection.

## CONCLUSIONS

The modern facelift is a sophisticated operation that focuses on treating targeted areas of facial aging using an individualized and detailed approach to the SMAS, skin, and fat compartments. Maximizing patient safety and consistency is the key to this operation to deliver high patient satisfaction.

**Rod J. Rohrich**

Dallas Plastic Surgery Institute  
9101 North Central Expressway, Suite 600  
Dallas, TX 75231  
E-mail: Rod.rohrich@dpsi.org

## REFERENCES

1. ASPS. 2017 Plastic Surgery Statistics Report, American Society of Plastic Surgeons, Available at <https://www.plasticsurgery.org/documents/News/Statistics/2017/plastic-surgery-statistics-full-report-2017.pdf>. Accessed October 14, 2018.
2. Sinno S, Schwitzer J, Anzai L, et al. Face-lift satisfaction using the FACE-Q. *Plast Reconstr Surg.* 2015;136:239–242.
3. Rohrich RJ, Pessa JE. The fat compartments of the face: anatomy and clinical implications for cosmetic surgery. *Plast Reconstr Surg.* 2007;119:2219–2227; discussion 2228–2231.
4. Schaverien MV, Pessa JE, Rohrich RJ. Vascularized membranes determine the anatomical boundaries of the subcutaneous fat compartments. *Plast Reconstr Surg.* 2009;123:695–700.
5. Alghoul M, Codner MA. Retaining ligaments of the face: review of anatomy and clinical applications. *Aesthet Surg J.* 2013;33:769–782.
6. Costa CR, Ramanadham SR, O'Reilly E, et al. The role of the superwet technique in face lift: an analysis of 1089 patients over 23 years. *Plast Reconstr Surg.* 2015;135:1566–1572.
7. Griffin JE, Jo C. Complications after superficial plane cervicofacial rhytidectomy: a retrospective analysis of 178 consecutive facelifts and review of the literature. *J Oral Maxillofac Surg.* 2007;65:2227–2234.
8. Beer GM, Goldscheider E, Weber A, et al. Prevention of acute hematoma after face-lifts. *Aesthetic Plast Surg.* 2010;34:502–507.
9. Berner RE, Morain WD, Noe JM. Postoperative hypertension as an etiological factor in hematoma after rhytidectomy. Prevention with chlorpromazine. *Plast Reconstr Surg.* 1976;57:314–319.
10. Baker D. Rhytidectomy with lateral SMASectomy. *Facial Plast Surg.* 2000;16:209–213.
11. Sraith RE, Raju DR, Hipps CJ. The study of hematomas in 500 consecutive face lifts. *Plast Reconstr Surg.* 1977;59:694–698.
12. Perkins SW, Williams JD, Macdonald K, et al. Prevention of seromas and hematomas after face-lift surgery with the use of postoperative vacuum drains. *Arch Otolaryngol Head Neck Surg.* 1997;123:743–745.
13. Mitz V, Peyronie M. The superficial musculo-aponeurotic system (SMAS) in the parotid and cheek area. *Plast Reconstr Surg.* 1976;58:80–88.
14. Furnas DW. The retaining ligaments of the cheek. *Plast Reconstr Surg.* 1989;83:11–16.



15. Stuzin JM, Baker TJ, Gordon HL. The relationship of the superficial and deep facial fascias: relevance to rhytidectomy and aging. *Plast Reconstr Surg.* 1992;89:441–459; discussion 450.
16. Pessa JE, Rohrich RJ. *Facial Topography.* Clinical Anatomy of the Face. St. Louis, Mo.: Quality Medical Publishing; 2012.
17. Roostaeian J, Rohrich RJ, Stuzin JM. Anatomical considerations to prevent facial nerve injury. *Plast Reconstr Surg.* 2015;135:1318–1327.
18. Alghoul M, Bitik O, McBride J, et al. Relationship of the zygomatic facial nerve to the retaining ligaments of the face: the SubSMAS danger zone. *Plast Reconstr Surg.* 2013;131:245e–252e.
19. Stuzin JM. Facelift: The extended SMAS technique in facial rejuvenation. In: Neligan PC, ed. *Plastic Surgery.* 3rd ed. Philadelphia: Elsevier; 2012;Vol II:238–256.
20. Pessa JE. An algorithm of facial aging: verification of Lambros's theory by three-dimensional stereolithography, with reference to the pathogenesis of midfacial aging, scleral show, and the lateral suborbital trough deformity. *Plast Reconstr Surg.* 2000;106:479–488; discussion 489.
21. Pessa JE, Chen Y. Curve analysis of the aging orbital aperture. *Plast Reconstr Surg.* 2002;109:751–755; discussion 756.
22. Pessa JE, Desvigne LD, Lambros VS, et al. Changes in ocular globe-to-orbital rim position with age: implications for aesthetic blepharoplasty of the lower eyelids. *Aesthetic Plast Surg.* 1999;23:337–342.
23. Kligman LH. Photoaging. Manifestations, prevention, and treatment. *Clin Geriatr Med.* 1989;5:235–251.
24. Pezeshk RA, Small KH, Rohrich RJ. Filling the facial compartments during a face lift. *Plast Reconstr Surg.* 2015;136:704–705.
25. Rohrich RJ, Ghavami A, Constantine FC, et al. Lift-and-fill face lift: integrating the fat compartments. *Plast Reconstr Surg.* 2014;133:756e–767e.
26. Rohrich RJ, Ghavami A, Lemmon JA, et al. The individualized component face lift: developing a systematic approach to facial rejuvenation. *Plast Reconstr Surg.* 2009;123:1050–1063.
27. Levine SM, Sinno S, Cannavo D, et al. Selective serotonin reuptake inhibitor-induced hyponatremia and the plastic surgery patient. *Plast Reconstr Surg.* 2017;139:1481–1488.
28. Marten TJ. High SMAS facelift: combined single flap lifting of the jawline, cheek, and midface. *Clin Plast Surg.* 2008;35:569, vi–603, vi.
29. Marten TJ, Elyassnia D. Secondary deformities and the secondary facelift. In: Neligan PC, ed. *Plastic Surgery.* 3rd ed. Philadelphia: Elsevier; 2012;Vol II:277–312.
30. Narasimhan K, Stuzin JM, Rohrich RJ. Five-step neck lift: integrating anatomy with clinical practice to optimize results. *Plast Reconstr Surg.* 2013;132:339–350.
31. Gassman AA, Pezeshk R, Scheuer JF III, et al. Anatomical and clinical implications of the deep and superficial fat compartments of the neck. *Plast Reconstr Surg.* 2017;140:405e–414e.
32. Mustoe TA, Rawlani V, Zimmerman H. Modified deep plane rhytidectomy with a lateral approach to the neck: an alternative to submental incision and dissection. *Plast Reconstr Surg.* 2011;127:357–370.
33. Pelle-Ceravolo M, Angelini M, Silvi E. Treatment of anterior neck aging without a submental approach: lateral skin-platysma displacement, a new and proven technique for platysma bands and skin laxity. *Plast Reconstr Surg.* 2017;139:308–321.
34. Narasimhan K, Ramanadham S, O'Reilly E, et al. Secondary neck lift and the importance of midline platysmaplasty: review of 101 cases. *Plast Reconstr Surg.* 2016;137:667e–675e.
35. Grover R, Jones BM, Waterhouse N. The prevention of haematoma following rhytidectomy: a review of 1078 consecutive facelifts. *Br J Plast Surg.* 2001;54:481–486.
36. Abboushi N, Yezhelyev M, Symbas J, et al. Facelift complications and the risk of venous thromboembolism: a single center's experience. *Aesthet Surg J.* 2012;32:413–420.
37. Ramanadham SR, Costa CR, Narasimhan K, et al. Refining the anesthesia management of the face-lift patient: lessons learned from 1089 consecutive face lifts. *Plast Reconstr Surg.* 2015;135:723–730.
38. Brown SA, Appelt EA, Lipschitz A, et al. Platelet gel sealant use in rhytidectomy. *Plast Reconstr Surg.* 2006;118:1019–1025.
39. Rohrich RJ, Narasimhan K. Long-term results in face lifting: observational results and evolution of technique. *Plast Reconstr Surg.* 2016;138:97–108.
40. Connell BF, Shamoun JM. The significance of digastric muscle contouring for rejuvenation of the submental area of the face. *Plast Reconstr Surg.* 1997;99:1586–1590.
41. Mendelson BC, Tutino R. Submandibular gland reduction in aesthetic surgery of the neck: review of 112 consecutive cases. *Plast Reconstr Surg.* 2015;136:463–471.
42. Bucky L. Facelift, how deep how wide. Paper presented at: American Society of Plastic Surgeons “The Meeting”; September 30, 2018; Chicago, IL.
43. Pezeshk RA, Sieber DA, Rohrich RJ. Neck rejuvenation through the lateral platysma window: a key component of face-lift surgery. *Plast Reconstr Surg.* 2017;139:865–866.
44. Robbins LB, Brothers DB, Marshall DM. Anterior SMAS plication for the treatment of prominent nasomandibular folds and restoration of normal cheek contour. *Plast Reconstr Surg.* 1995;96:1279–1287; discussion 1288.
45. Baker DC. Lateral SMASectomy. *Plast Reconstr Surg.* 1997;100:509–513.
46. Barton FE Jr. The “high SMAS” face lift technique. *Aesthet Surg J.* 2002;22:481–486.
47. Barton FE Jr, Hunt J. The high-superficial musculoaponeurotic system technique in facial rejuvenation: an update. *Plast Reconstr Surg.* 2003;112:1910–1917.
48. Hamra ST. The deep-plane rhytidectomy. *Plast Reconstr Surg.* 1990;86:53–61; discussion 62.
49. Brown S, Yao A, Taub PJ. Antifibrinolytic agents in plastic surgery: current practices and future directions. *Plast Reconstr Surg.* 2018;141:937e–949e.
50. Butz DR, Geldner PD. The use of tranexamic acid in rhytidectomy patients. *Plast Reconstr Surg Glob Open.* 2016;4:e716.
51. Rohrich RJ, Cho MJ. The role of tranexamic acid in plastic surgery: review and technical considerations. *Plast Reconstr Surg.* 2018;141:507–515.
52. Scheuer JF 3<sup>rd</sup>, Costa CR, Dauwe PB, et al. Laser resurfacing at the time of rhytidectomy. *Plast Reconstr Surg.* 2015;136:27–38.
53. Hoefflin SM. Decreasing prolonged swelling and pain associated with deep plane face lifts. *Plast Reconstr Surg.* 1992;90:1125.
54. Owsley JQ, Weibel TJ, Adams WA. Does steroid medication reduce facial edema following face lift surgery? A prospective, randomized study of 30 consecutive patients. *Plast Reconstr Surg.* 1996;98:1–6.
55. da Silva EM, Hochman B, Ferreira LM. Perioperative corticosteroids for preventing complications following facial plastic surgery. *Cochrane Database Syst Rev.* 2014;2(6):CD009697.
56. Pulikkottil BJ, Dauwe P, Daniali L, et al. Corticosteroid use in cosmetic plastic surgery. *Plast Reconstr Surg.* 2013;132:352e–360e.
57. Rohrich RJ, Stuzin JM, Ramanadham S, et al. The modern male rhytidectomy: lessons learned. *Plast Reconstr Surg.* 2017;139:295–307.
58. Rasko YM, Beale E, Rohrich RJ. Secondary rhytidectomy: comprehensive review and current concepts. *Plast Reconstr Surg.* 2012;130:1370–1378.
59. Beale EW, Rasko Y, Rohrich RJ. A 20-year experience with secondary rhytidectomy: a review of technique, longevity, and outcomes. *Plast Reconstr Surg.* 2013;131:625–634.
60. Knize DM. Limited incision submental lipectomy and platysmaplasty. *Plast Reconstr Surg.* 2004;113:1275–1278.
61. Stuzin JM. MOC-PSSM CME article: face lifting. *Plast Reconstr Surg.* 2008;121(Suppl 1):1–19.