

A New Electrocardiographic Algorithm to Locate the Occlusion in Left Anterior Descending Coronary Artery

Miguel Fiol, MD, PhD, Andrés Carrillo, MD, Iwona Cygankiewicz, MD, PhD*, Julio Velasco, MD, Maria Riera, MD, Antoni, Bayés-Genis, MD, PhD, Alfredo Gómez, MD, PhD, Vicente Peral, MD, PhD, Armando Bethencourt, MD, PhD, diego Goldwasser, MD*, Fredis Molina, MD*, Antoni Bayés de Luna, MD, PhD, FESH, FACC*
Son Dureta University Hospital and IUNICS(University Institute for Investigation on Health Sciences), Coronary and Critical Care Unit; *Institut Català Ciències Cardiovascular, Hospital Sant Pau, Barcelona

ABSTRACT

Background: Early prediction of proximal left anterior descending coronary artery (LAD) occlusion is essential from a clinical point of view

Hypothesis: To develop an electrocardiogram (ECG) algorithm based on ST-segment deviations to predict the location of occlusion of LAD as a culprit artery.

Methods: ECG and angiographic findings were correlated in 100 patients with an ST-segment elevation myocardial infarction (MI) in precordial leads V₁, V₂, and V₄ through V₆.

Results: ST-depression ≥ 2.5 mm in leads III + ventricular fibrillation (VF) presents sensitivity (SE) of 77% and specificity (SP) of 84% for LAD occlusion proximal to the first diagonal artery (D₁). ST-segment in III + VF isoelectric or elevated, presents SE of 44% and SP of 100% for LAD occlusion distal to D₁. Subsequent analysis of the equation \sum of ST-deviation in VR + V₁ - V₆ < 0, allows us to predict occlusion distal to first septal artery (S₁) with 100% SP. On the other hand, any ST-depression in III + VF > 0.5 mm + \sum of ST-deviation in VR + V₁ - V₆ ≥ 0 identifies a high-risk group (lower ejection fraction, worse Killip findings, higher peak of CPK and CK-MB, and major adverse cardiac events [MACE]: death, reinfarction, recurrent angina, persistent left ventricular failure, or sustained ventricular arrhythmia during hospitalization).

Conclusions: This sequential ECG algorithm based on ST-segment deviations in different leads allowed us to predict the location of occlusion in LAD with good accuracy. Cases with proximal LAD occlusion present the most markers of poor prognosis. We recommend the use of the algorithm in everyday clinical practice.

Key words: electrocardiography, coronary angiography, acute myocardial infarction

Introduction

ST-elevation in precordial leads in patients with acute coronary syndrome (ACS) symptoms indicates ST-segment elevation myocardial infarction (STEMI) involving the area perfused by the left anterior descending coronary artery (LAD).¹⁻⁵ This information alone does not predict the extent of the potentially damaged myocardium. It is known that proximal LAD occlusion involves a larger zone of myocardium than distal occlusion and therefore has a worse prognosis.^{6,7} Thus, an early prediction of proximal LAD occlusion is important not only from an academic standpoint, but also from a clinical point of view. Changes in ST-segment in different leads of surface ECG can identify patients with proximal or distal LAD occlusion.⁸⁻²⁰ Nevertheless, we consider it better to have an easy-to-use algorithm based on deviations of ST in 12-lead ECG than to assess the ECG criteria separately. Here we present such an algorithm based on the evaluation of ST changes in 12-lead ECG correlated with angiographic findings.

Methods

Study Subjects

ECG and angiographic findings in 100 consecutive patients admitted to the Son Dureta University Hospital Palma de Mallorca (Spain) with ST-elevation in precordial leads V₁, V₂, and V₄ through V₆ as the most evident abnormality were analyzed. Inclusion criteria were: no history of myocardial infarction (MI); <6 h from the onset of symptoms; sinus rhythm; ST-elevation of at least 2 mm in 2 or more consecutive precordial leads in the ECG at admittance, and no bundle branch block. Coronary angiography was performed within the first 12 h after onset of symptoms. All patients (78 men, 22 women; age range: 32 to 79 y; mean age: 56.5 ± 14.7) met the inclusion criteria. Coronary angiography documented 1-vessel disease with the culprit lesion in LAD and no other stenosis greater than 50% was found. Diagnosis of MI was based on clinical symptoms (anginal pain lasting over 20 min), ECG findings, and enzymatic changes. A primary percutaneous coronary intervention (PCI) was performed in 74 patients, a rescue PCI in 10 patients.

The following variables were considered during the in-hospital evaluation: ejection fraction (EF) measured by coronary angiography, Killip class, peak level of CPK and CK-MB, and major adverse cardiac events (MACE) during hospitalization: death, reinfarction, recurrent angina, persistent left ventricular failure, or sustained ventricular arrhythmias.

ECG Recordings

Standard 12-lead ECG were recorded at a paper speed of 25 mm/s and a voltage of 10 mm/mV at the time of admission. ECG tracings were reviewed by 2 independent investigators blinded to clinical and angiographic data. In cases of discrepancy, the final decision was made by a third investigator. In all cases, an amplifier glass was used to precisely describe ST-changes. ST-changes were measured 60 msec from J point in all the leads. Measurements were taken to the nearest 0.5 mm (0.05 mV). The TP-segment was used as the isoelectric line.

ECG Criteria

The injury vector is oriented toward the injured area and generates ST-segment elevation in the lead facing the vector head and ST-depression in the lead facing the vector tail (opposite leads). All patients presented the most evident ST-segment elevation in precordial leads, which was considered to be a sign of LAD occlusion.¹⁻³ Different ECG criteria based on previously published papers⁹⁻²¹ and our experience⁴ were evaluated to predict the placement of occlusion in LAD. Criteria used to locate the occlusion above or below the first diagonal artery (D1) and the first septal (S1) are based on deviations of the ST-segment in inferior (Figure 1A), anterolateral (Figure 1B), and/or VR leads. All these deviations were evaluated in all patients to establish the best sequential algorithm.

Coronary Angiography

Coronary angiographic findings were evaluated by 2 independent investigators blinded to clinical and ECG data of the patients. In all cases, occlusion or culprit critical stenosis in LAD was responsible for STEMI. The location of LAD occlusion was described in relation to the S1 and D1 branches. The following occlusion locations were distinguished: 1) before both branches: D1 and S1; 2) between S1 and D1; 3) distal to D1 and S1.

Statistics

Continuous variables are expressed as mean±SD. Groups of patients divided according to the ST-segment deviations in inferior leads were compared using the chi-square test with Fisher's correction when appropriate. Criteria were dichotomized according to their cut off: at 2.5 mm for changes in inferior leads and at 0 mm for the sum of changes in VR, V₁ and V₆ leads. For ECG criteria; sensitivity (SE),

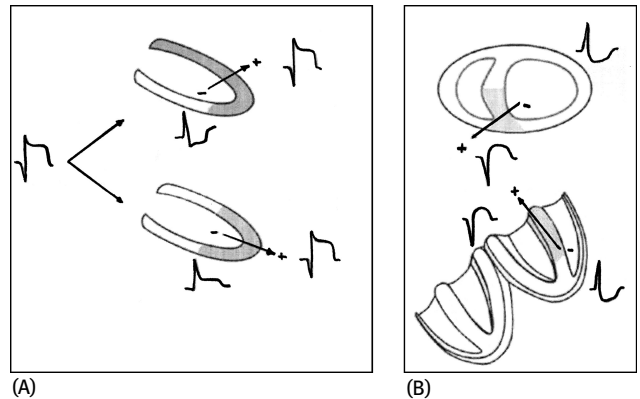


Figure 1. (A) ST-segment deviation that may be seen in case of proximal to D1 and distal to D1 LAD occlusion in frontal plane. (B) Scheme of ST-deviations seen in case of proximal to S1 LAD occlusion in the horizontal and frontal planes.

specificity (SP), and positive and negative predictive values (PPV and NPV) were assessed for all criteria separately and then sequentially as presented in the algorithm. Continuous variables were compared using Student *t* test or analysis of variance with Bonferroni correction. A *p* value <0.05 was considered statistically significant.

Results

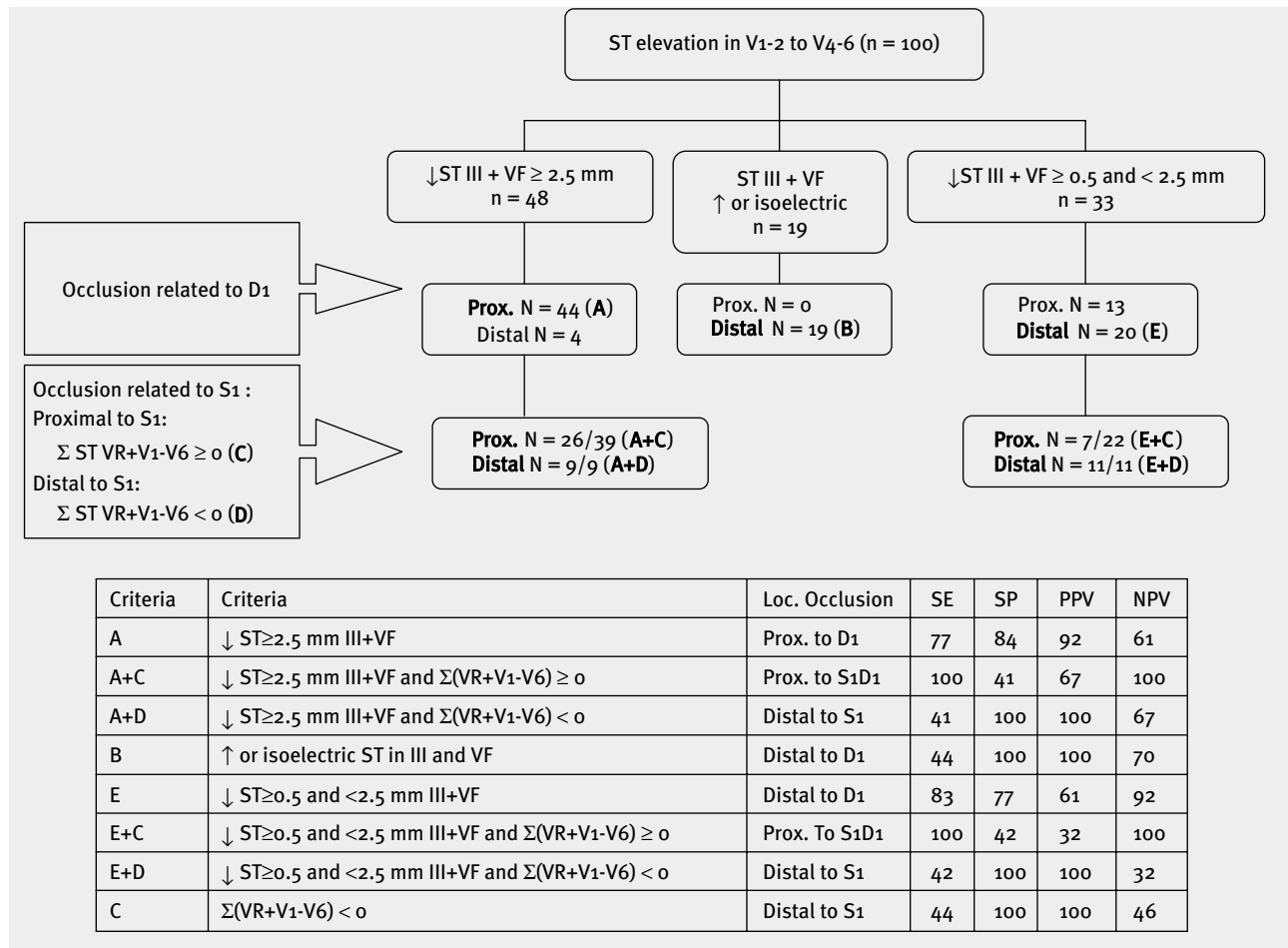
ECG Parameters to Predict Occlusion Location

Time from symptom onset to first ECG recording was 147±108 min. Different algorithms based on ST-deviations in 12-lead ECG were developed to correlate electrocardiographic and angiographic findings. The algorithm presented in Table 1 showed the best correlation with angiographic findings. This algorithm includes 2 steps: first, to locate the occlusion in relation to D1, and second, to locate the occlusion in relation to S1, as mentioned previously. According to this, the following criteria were found: criterion A: ↓ ST in III + VF ≥2.5 mm for occlusions proximal to D1, and criterion B: ∑ ST in III + VF, isoelectric or elevated, for occlusions distal to D1. We then use the equation: ∑ ST-deviation in VR + V₁ - V₆ for the second step (Figure 2). If the result is ≥0, the occlusion is proximal to S1 (criterion C) and if <0 (criterion D), distal to S1 (Figure 3). Cases with slight ST-depression in III + VF (<2.5 mm) are difficult to classify in relation to D1, but in these cases the equation: ∑ ST deviation in VR + V₁ - V₆ <0 has high specificity for distal occlusion to S1 (criterion E). The sensitivity, specificity, positive predictive value, and negative predictive value of different criteria are shown in Table 1.

Clinical-Electrocardiographic Correlation (Table 2)

Patients who presented ECG criteria of proximal occlusion (any ST-depression in III + VF >0.5 plus ∑ ST-deviation

Table 1. Sensitivity, specificity, predictive positive and negative value for each criteria.



in $VR + V1 - V6 \geq 0$) constituted a high-risk group (see Table 2). This high-risk group had lower ejection fraction, higher peak of CPK and CK-MB, and worse Killip class, and included more patients with MACE and showing a C pattern Birnbaum-Scarowsky,²² and proximal occlusions to D1, between S1 and D1, or proximal to S1, compared to the patients who did not meet all these criteria.

Discussion

The amount of left ventricle mass that presents hypoperfusion and is at risk of evolving to MI in the course of LAD STEMI depends greatly on the location of the LAD occlusion. Therefore knowing the location of the LAD occlusion at first glance, by just looking at the ECG in the emergency room is of great importance for the best therapeutic decisions to be made. The recent findings of Masoudi et al.²¹ suggest that the failure to identify high-risk ECG patterns in patients with acute myocardial infarction (AMI) results in lower quality care in the emergency room and highlights the

importance of system changes to enhance the accuracy of ECG interpretation. Knowing that the occlusion is proximal or distal to D1 or S1 may be crucial for deciding on the best approach to treatment: to start fibrinolytic treatment and keep the patient in the hospital because the risk of a large AMI is low, or, independently of fibrinolytic treatment, make the decision to send the patient immediately to a referral center for a PCI, since there is ECG evidence that the risk of a large AMI is high. Furthermore, if we have the evidence that a major left ventricle (LV) area is involved and there is a danger of MI, we may prefer to administer fibrinolytic treatment in the first hour in the emergency room or in an ambulance than perform PCI in a referral hospital 1–2h later.

Occlusion of the LAD artery may lead to a very extensive anterior MI, or only septal, apical-anterior or mid-anterior according to the site of occlusion.²³ Proximal LAD occlusion has been documented as an independent predictor of poor outcome related to higher mortality and recurrent MI,^{6,7}

Table 2. Risk groups according to ECG findings and its correlation with angiographic findings

	High Risk* n = 61 p	Low Risk** n = 39 p	p
Age (years)	55±14	58±16	ns
EF	46±12	56±11	-
Killip	1.8±0.9	1.21±0.7	-
Killip ≥II	45.9%	10.3	-
CK (ui/l)	3947±2804	2611±1986	0.013
CK-MB (ui/l)	479±371	321±265	0.027
C pattern (Birnbaum)	56.3%	24.2%	0.003
Proximal to S1	52.5%	-	-
Proximal to D1	77%	25.6%	-
Distal to D1	23%	74.4%	-
Death	3.3%	5.1%	ns
ReAMI or Angina			
LVF	19.7%	15.4%	ns
Ventricular arrhythmia	31.1%	2.6%	-
Global MACE	13.1%	7.7%	ns
	50.8%	25.6%	0.010

*ECG pattern of high risk: depression in III + VF >0.5 mm plus \sum of ST-deviation in VR + V₁ - V₆ ≥0. **ECG pattern of low risk: Patients showing ST isoelectric or elevated in III + VF or \sum of ST-deviation in VR + V₁ - V₆ <0.

and distal LAD occlusion is considered to have a better outcome. Ischemia provoked by LAD occlusion is reflected by ST-elevation in precordial leads. The different ECG criteria for predicting the site of occlusion are based on the direction of the injury vector. In relation to this idea, we also demonstrated the usefulness of another algorithm²⁴ connected to this approach to ascertain which is the culprit artery (right coronary versus circumflex artery) in STEMI with ST-segment elevation in inferior leads.

Different criteria have been used to differentiate between proximal and distal LAD using the deviation of ST in inferior leads as the most useful criterion (Figure 1A,B).^{4,9-17} However, we present for the first time a sequential, easy-to-use algorithm, that can be used in clinical practice and which predicts the location of occlusion in LAD STEMI with high accuracy.

To make the correct decisions, particularly concerning the need for urgent reperfusion, we propose the following: 1) ST-segment elevation in precordial leads V₁, V₂, and V₄ through V₆ indicates LAD occlusion; 2) To differentiate the

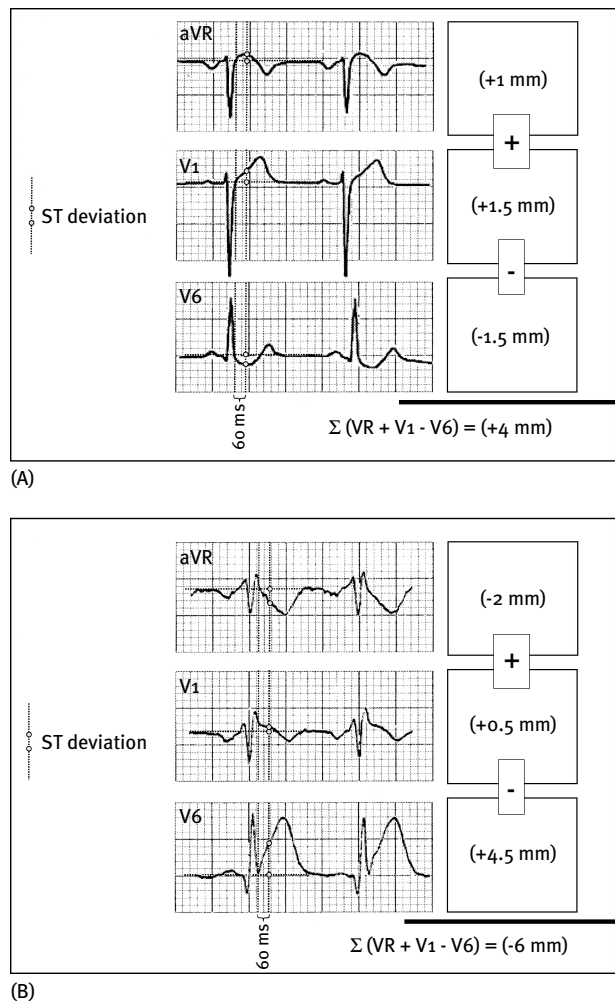


Figure 2. Two examples showing how to use the formula \sum ST in VR + V₁ - V₆ to decide if the occlusion is proximal to S1 or distal to S1.

occlusion in relation to D1 (proximal versus distal), we need to check the ST-segment deviations in inferior leads. The sum of ST depression in III and VF leads ≥ 2.5 mm indicates an occlusion proximal to D1 (criterion A). The ST-segment, isoelectric or elevated, indicates that the occlusion is distal to D1 (criterion B); and 3) To assess more precisely the location of LAD occlusion in relation to S1, ST-segment in VR, V₁, and V₆ should then be checked. If \sum of ST-deviation in VR + V₁ - V₆ is ≥ 0 , occlusion proximal to S1 is suggested. If less than 0, the occlusion is distal to S1. Our data suggest that the equation is more useful when the result is <0, and presents a high specificity for an occlusion distal to S1.

Therefore, being able to locate the occlusion site very quickly on rapidly scrutinizing the admission ECG is no longer only academic thanks to this algorithm. In agreement

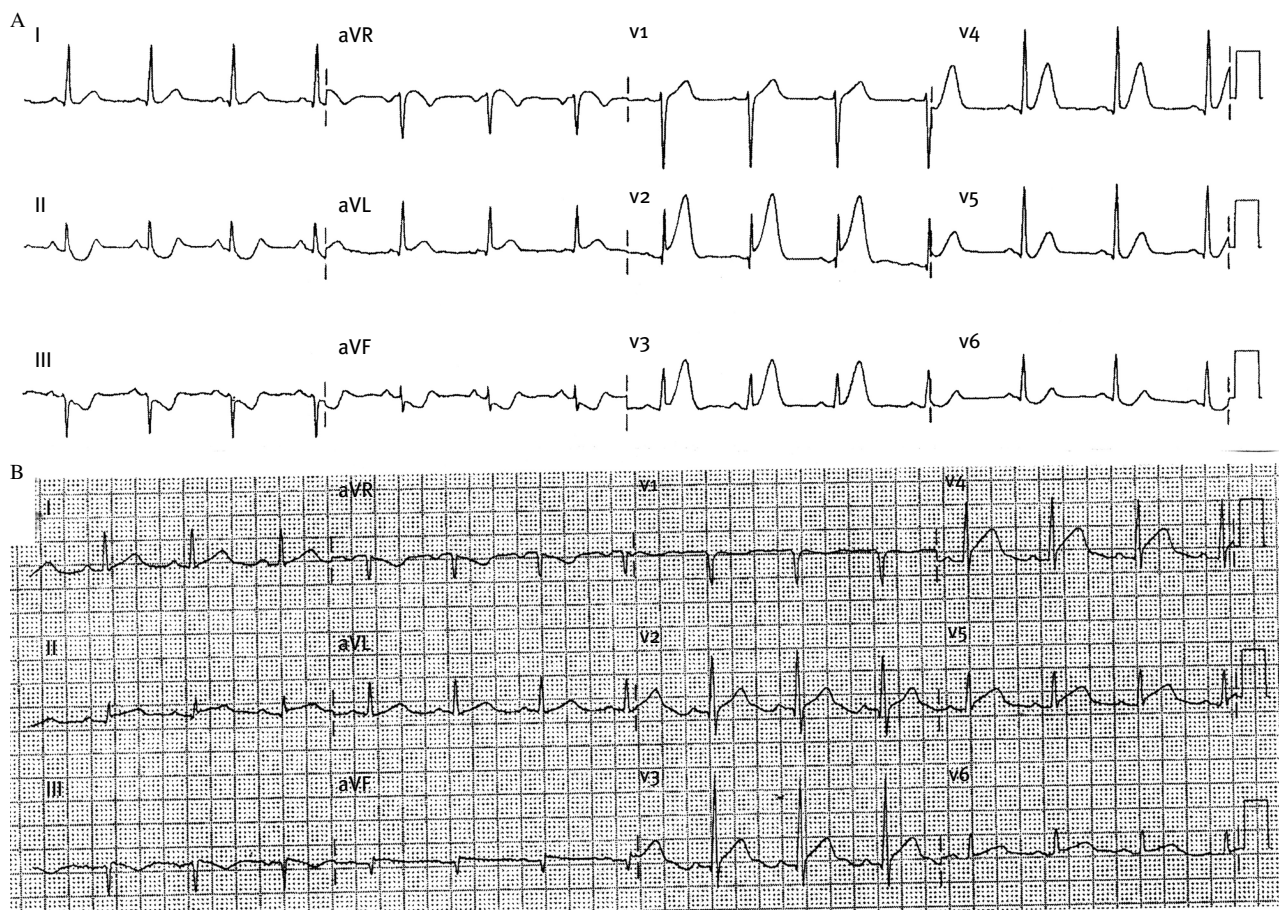


Figure 3. ECG findings according to the risk group. (A) High risk group (depression in III + VF > 0.5 mm and $\sum VR + V_1 - V_6 \geq 0$). (B) Low risk group.

with the findings of Masoudi et al.,²¹ we found a high correlation between ECG characteristics on admission and markers of poor outcome (Table 2). Therefore, this information is essential to estimate the amount of myocardium at risk and helps us to undertake clinical decisions regarding the need of urgent revascularization.

Limitations of the Study

In this study we analyzed the usefulness of ECG criteria in patients with LAD STEMI and no other vessels with more than 50% occlusion. We are now validating these criteria in a series of patients with STEMI due to culprit LAD and more than 50% coronary occlusion in the right coronary artery or circumflex artery.

Acknowledgements

The authors thank Dr. Elliot Antman and Jordi Ibáñez for their advice and support during the preparation of this paper.

References

1. Bayés de Luna A: *Clinical Electrocardiography: A Textbook*. 2nd updated ed. Armonk NY: Futura Publ; 1998.
2. Wellens HJJ: *The ECG in the Acute Myocardial Infarction*. Boston: Kluwer Academic Publishers; 2003.
3. Sclarowsky S: *Electrocardiography of Acute Myocardial Ischaemia*. London: Martin Dunitz; 1999.
4. Fiol M, Cygankiewicz I, Guindo J, Flotats A, Genis AB, et al: Evolving myocardial infarction with ST elevation: Ups and downs of ST in different leads identifies the culprit artery and location of the occlusion. *Ann Noninv Electrocardiol*. 2004;9(2):180–6.
5. Zimetbaum PJ, Josephson ME: Use of the electrocardiogram in acute myocardial infarction. *N Engl J Med*. 2003;348(10):933–40.
6. Engelen DJ, Gorgels AP, Cheriex EC, De Muinck ED, Ophuis AJ, et al: Value of electrocardiogram in localizing the occlusion site in the left anterior descending artery in acute anterior myocardial infarction. *J Am Coll Cardiol*. 1999;34(2):389–95.
7. Karha J, Murphy SA, Kirtane AJ, de Lemos JA, Aroesty JM, et al: TIMI Study Group: Evaluation of the association of proximal coronary culprit artery lesion location with clinical outcomes in acute myocardial infarction. *Am J Cardiol*. 2003;92(8):913–18.
8. Hathaway WR, Peterson ED, Wagner GS, Granger CB, Zabel KM, et al: Prognostic significance of the initial electrocardiogram in patients with acute myocardial infarction. GUSTO-I Investigators.

- Global utilization of streptokinase in t-PA for occluded coronary arteries. *JAMA*. 1998;279(5):87–91.
9. Birnbaum Y, Solodky A, Herz I, Kusniec J, Rechavia E, et al.: Implications of inferior ST segment depression in anterior acute myocardial infarction: Electrocardiographic and angiographic correlation. *Am Heart J*. 1994;127(6):1467–73.
 10. Arbane M, Goy JJ: Prediction of the site of total occlusion in the left anterior descending coronary artery using admission electrocardiogram in anterior wall acute myocardial infarction. *Am J Cardiol*. 2000;85(4):487–91.
 11. Tamura A, Kataoka H, Mikuriya Y, Nasu M: Inferior ST segment depression as a useful marker for identifying proximal left anterior descending artery occlusion during acute anterior myocardial infarction. *Eur Heart J*. 1995;16(12):1795–99.
 12. Fletcher WO, Gibbons RJ, Clement IP: The relationship of inferior ST depression, lateral ST elevation and left precordial ST elevation to myocardium at risk in acute anterior myocardial infarction. *Am Heart J*. 1993;126(3 pt1):526–35.
 13. Haraphongse M, Tanomsup S, Jugdutt BI: Inferior segment depression during acute anterior myocardial infarction: Clinical and angiographic correlations. *J Am Coll Cardiol*. 1984;4(3):467–76.
 14. Quyyumi AA, Crake T, Rubens MB, Levy RD, Rickards AF, et al.: Importance of “reciprocal” electrocardiographic changes during occlusion of left anterior descending artery. Studies during percutaneous transluminal coronary angioplasty. *Lancet*. 1986;1(8477):347–50.
 15. Lew AS, Hod H, Cercek B, Shah PK, Ganz W: Inferior ST segment changes during acute anterior myocardial infarction: A marker of the presence or absence of concomitant inferior wall ischaemia. *J Am Coll Cardiol*. 1987;10(3):519–26.
 16. Tamura A, Kataoka H, Nagase K, Mikuriya Y, Nasu M: Clinical significance of inferior ST elevation during acute anterior myocardial infarction. *Br Heart J*. 1995;74(6):611–14.
 17. Sapin PM, Musselman DR, Dehmer GJ, Cascio WE: Implications of inferior ST segment elevation accompanying anterior wall myocardial infarction for the angiographic morphology of the left anterior descending coronary artery morphology and site of occlusion. *Am J Cardiol*. 1992;69(9):860–65.
 18. Kim TY, Alturk N, Shaikh N, Kelen G, Salazar M, et al.: An electrocardiographic algorithm for the prediction of the culprit lesion site in acute anterior myocardial infarction. *Clin Cardiol*. 1999;22(2):77–83.
 19. Ben-Gal T, Herz I, Solodky A, Birnbaum Y, Sclarovsky S, et al.: Acute anterior wall myocardial infarction entailing ST elevation in V1: Electrocardiographic and angiographic correlations. *Clin Cardiol*. 1998;21(6):399–404.
 20. Senaratne MP, Weerasinghe C, Smith G, Mooney D: Clinical utility of ST segment depression in lead aVR in acute myocardial infarction. *J Electrocardiol*. 2003;36(1):11–16.
 21. Masoudi FA, Magid DJ, Vinson DR, Tricomi AJ, Lyons EE, et al.: Emergency Department Quality in Myocardial Infarction Study Investigators.: Implications of the failure to identify high-risk electrocardiogram findings for the quality of care of patients with acute myocardial infarction. *Circulation*. 2006;114(16):1565–1571.
 22. Billgren T, Birnbaum Y, Sgarbossa EB, Sejersten M, Hill NE, et al.: Refinement and interobserver agreement for the electrocardiographic Sclarovsky-Birnbaum ischemia Grading System. *J Electrocardiol*. 2004;37(3):149–56.
 23. Bayes de Luna A, Wagner G, Birnbaum Y, Nikus K, Fiol M, et al.: International Society for Holter and Noninvasive Electrocardiography.: A new terminology for the left ventricular walls and for the locations of Q wave and Q wave equivalent myocardial infarction based on the standard of cardiac magnetic resonance imaging. A statement for healthcare professionals from a committee appointment by the International Society for Holter and Non Invasive Electrocardiography. *Circulation*. 2006;114(16):1755–60.
 24. Fiol M, Cygankiewicz I, Carrillo A, Bayes-Genis A, Santoyo O, et al.: Value of electrocardiographic algorithm based on “ups and downs” of ST in assessment of a culprit artery in evolving inferior wall acute myocardial infarction. *Am J Cardiol*. 2004;94(6):709–14.