

Persistent Troponin Elevation in a Patient with Cardiac Amyloidosis

Address for correspondence:
Stephan Lindemann, MD
Department of Internal Medicine III
University Hospital of Tübingen
Otfried-Müller-Str. 10
72076 Tübingen, Germany
stephan.lindemann@med.uni-tuebingen.de

Bjoern F. Kraemer, MD, Peter Seizer, MD, Tobias Geisler, MD, Karin Klingel MD,*
Reinhard Kandolf, MD,* Stephan Lindemann, MD, Meinrad Gawaz, MD
Medizinische Klinik III, University Hospital of Tübingen, Otfried-Müller-Str, Tübingen, Germany;
*Department of Molecular Pathology, Institute of Pathology, University Hospital of Tübingen,
Liebermeisterstr, Tübingen, Germany

ABSTRACT

A 79-year-old patient repeatedly presented with chest discomfort and dyspnea on exertion. With echocardiography a prominent left ventricular and septal hypertrophy was detected with reduced left ventricular function. Despite successful revascularization and excellent results after stenting, the patient showed persistently elevated troponin levels. To investigate the abnormal findings of persistent troponin elevation, septal hypertrophy, and heart failure we performed endomyocardial biopsies which showed widespread myocardial amyloidosis. Amyloid subtyping revealed transthyretin amyloidosis. This is the first case showing *persistent* troponin elevation in a patient with transthyretin amyloidosis. Very few other cases have been published on the topic of cardiac amyloidosis and troponin elevation so far. Our case serves as an illustrating example in the differential diagnosis of nonischemic causes of persistent troponin elevation. It is important to consider cardiac amyloidosis in patients with troponin elevation and heart failure since the clinical management differs significantly from other causes of heart failure.

Key words: cardiac amyloidosis, troponin, heart failure, syncope

Introduction

Differential diagnosis of troponin elevation is broad with ischemic heart disease comprising the major cause followed by a number of nonischemic causes (Table 1). Troponin serves as a sensitive marker reflecting cardiac ischemia and myocyte necrosis. The half-life of troponin ranges from 96 h to 10 d. After successful revascularization, troponin levels tend to decline rapidly. In this study we are focusing on cardiac amyloidosis as a rare, yet important cause of nonischemic troponin elevation. Amyloid cardiomyopathy is characterized by deposition of amyloidogenic proteins leading to myocardial or conduction system dysfunction. Left ventricular wall thickening with diastolic dysfunction marks the earliest echocardiographic abnormality and can be accompanied by right ventricular diastolic dysfunction.¹ With prominent septal involvement, amyloidosis can mimic hypertrophic cardiomyopathy. Different amyloidogenic proteins define the types of amyloidosis (Table 2). Transthyretin amyloidosis, as diagnosed in our patient, is either due to an autosomal dominant disease with mutations in the ATTR gene or derived from wild-type transthyretin (TTR), or senile systemic amyloidosis (SSA). If cardiac deposits of amyloid are massive compared to the small amounts commonly found in the hearts of the elderly, the disease is termed senile cardiac amyloidosis.² Senile cardiac amyloidosis tends to take a milder clinical course with easily controllable heart failure^{2,3} which makes persistent troponin elevation, as in our case, an unusual observation. We present the interesting clinical course of a patient with cardiac amyloidosis and *persistently* elevated troponin. To

our knowledge this is the first case of a patient with *persistent* troponin elevation in transthyretin amyloidosis.

Results

Our patient initially presented in February 2006, with symptoms of a stable angina pectoris and exertional dyspnea. Lab testing showed positive troponin levels (0.6 µg/L, normal limit <0.1 µg/L) and our patient was subsequently treated for acute coronary syndrome. Coronary angiography showed 80% stenosis of the left anterior descending coronary artery (LAD) which was successfully treated with coronary intervention and drug-eluting stent placement. Cardiac risk factors include arterial hypertension, history of smoking, hyperlipidemia, and chronic renal failure. The patient had received a pacemaker system for third degree AV block in 2004. After discharge, our patient presented to our cardiology department again in February 2007, with chest discomfort and dyspnea. Troponin was elevated (3.6 µg/L, normal limit < 0.1 µg/L) with normal creatine kinase levels and without abnormal ECG findings. With regard to renal disease, the patient's kidney function, determined by serum creatinine levels, was not exceeding the patient's usual creatinine levels at that time. Follow-up coronary angiography showed an excellent result after LAD-PCI (Percutaneous Coronary Intervention). Upon examining the left ventricular function, our patient had a reduced left ventricular function (ejection fraction 45%) with prominent left ventricular and septal hypertrophy (18 mm; Figure 1). We intensified the medication for congestive heart failure

Table 1. Ischemic and nonischemic causes of troponin elevation

Ischemic troponin elevation	Combined etiology	Nonischemic troponin elevation
Coronary artery disease	Pulmonary hypertension	Myocarditis
Congestive heart failure	Pulmonary embolism	Renal failure
Cardiomyopathy (dilated/ hypertrophic)	Physical exercise	Chemotherapy
Cardiac surgery		Cardiac contusion
Status post PCI		Cardioversion
Status post supraventricular tachycardia		Defibrillator shock
		Cardiac amyloidosis

Table 2. Types of amyloidosis with typical patient characteristics and symptoms

Type of Amyloidosis	Typical symptoms	Patient characteristics
AL-Amyloidosis	Frequent severe cardiac involvement (up to 50%) dyspnea, edema, angina pectoris, ventricular arrhythmia, AV-conduction disease, syncope, autonomic neuropathy	Clonal plasma cell proliferative disorder with monoclonal light chain fibril deposits; 10% overt multiple myeloma. Peak age group for multiple myeloma 65–70 years. Most frequent cause of amyloidosis in developed countries.
ATTR-Amyloidosis (inherited)	Sinus node dysfunction, neuropathy, conduction system disturbance, frequently heart failure	Onset from 3rd decade, mainly after year 40. heterozygosity in African-American population. Deposits of mutant transthyretin
AA-Amyloidosis	Rare cardiac involvement	Amyloid deposits of inflammatory proteins. Most frequent cause of amyloidosis in developing countries.
Senile systemic amyloidosis	Senile cardiac amyloidosis as predominant clinical manifestation; mild symptoms	Elderly patients above 70 y; wild-type transthyretin deposits.

adding eplerenone to the therapy regimen. Nineteen days later the patient presented to our department again after an episode of syncope during a lecture. The patient did not complain of any chest pain or exertional dyspnea at that time. Diagnostic workup revealed orthostatic dysregulation during tilt table exercise. Episodes of arrhythmia could not be detected during clinical course and pacemaker function was fully intact. We found persistently elevated troponin levels despite adequate coronary revascularization and good result after stent intervention (Figure 2). Serum levels of creatinine were again not exceeding the patient's usual levels. In order to investigate the extraordinary findings of persistent troponin elevation (troponin levels did never normalize) and echocardiographic findings of myocardial hypertrophy and reduced ventricular function with unclear clinical presentation, we performed a right ventricular endomyocardial biopsy. Histopathologic stainings of the ventricular biopsies revealed extensive positive congo red deposits in the interstitium, defining the widespread cardiac amyloidosis in our patient (Figure 3). Amyloid subtyping revealed comprehensive transthyretin deposits. Hemochromatosis, glycogenosis, and myocarditis were

excluded by specific stainings and immunohistochemistry. Two further follow-up appointments 4 and 8 mo after biopsy still revealed elevated troponin levels (Figure 2).

Discussion

This study illustrates the importance of considering non-ischemic and noncardiac causes of troponin elevation in the workup of patients with angina pectoris or congestive heart failure. When considering cardiac amyloidosis as the underlying disease, we can attribute the decreased ventricular function and ventricular hypertrophy, at least in part, to this metabolic disorder. Troponin elevation was at initial admission most likely due to acute coronary syndrome and later persisted due to progressive heart failure maintained by amyloigenic myocyte necrosis. At the initial presentation we did not suspect another reason for troponin elevation other than acute coronary syndrome (ACS) that was subsequently treated with percutaneous coronary intervention (PCI). At no time afterwards, did we find a normalization of troponin levels in our patient despite adequate revascularization (see Figure 2). There was no evidence of other causes of troponin elevation like acute renal failure or pulmonary

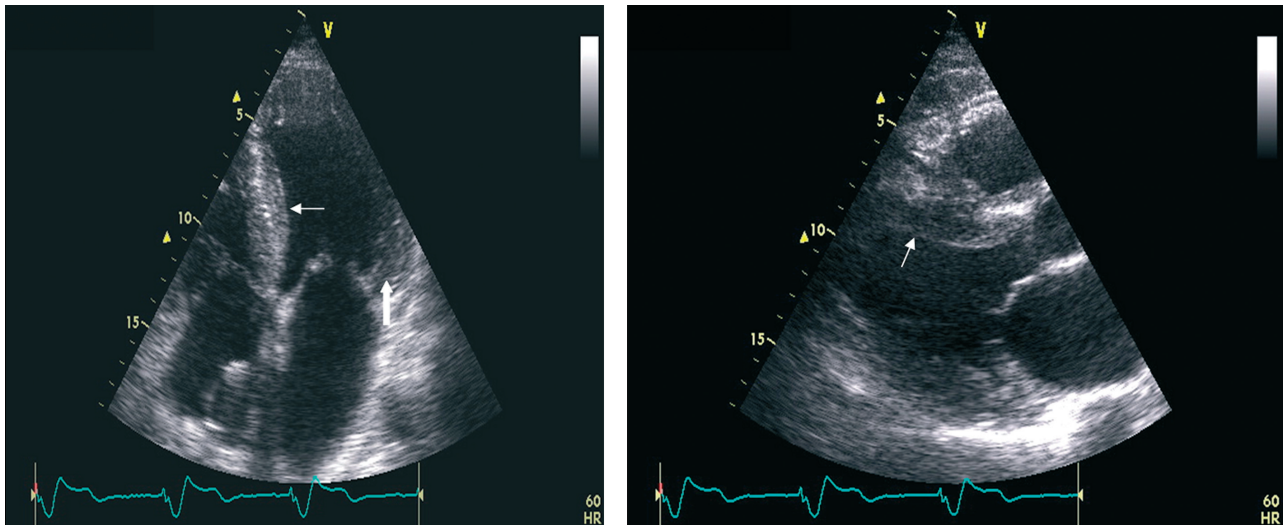


Figure 1. Echocardiography showing profound septal hypertrophy (small arrow) and left ventricular hypertrophy (broad arrow). Apical 4-chamber view (left), parasternal long axis (right).

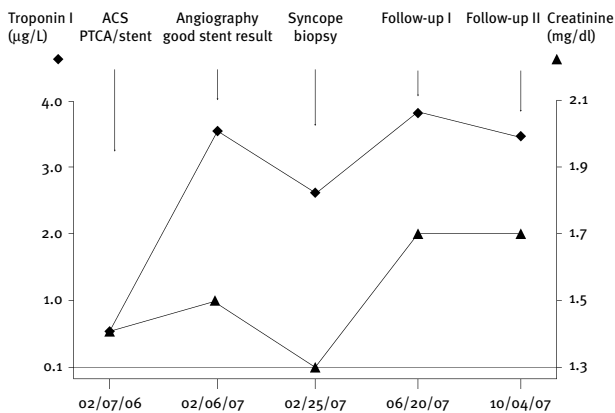


Figure 2. Clinical course of events with troponin I (◆) and creatinine (▲) time course. Normal limit for troponin <0.1 µg/L and for creatinine <1.3 mg/dl.

embolism. According to the literature, troponin elevation is frequently observed in patients with end-stage renal disease especially for troponin T.⁴ However, troponin I as routinely determined by our lab, seems to be a reliable marker despite renal disease. Troponin I is widely independent of clearance and is only elevated in 7% of patients with renal failure without evidence of acute ischemia.^{4,5} Creatinine levels in our patient were measured between 1.3–1.7 mg/dl (normal limit <1.3 mg/dl) representing the patients usual creatinine levels over the past 2 years. Pulmonary embolism was excluded by CT scan after syncope and appears as an unlikely cause of troponin elevation since our patient was continuously and effectively treated with oral anticoagulants. The syncope may be due to amyloid neuropathy involving

the autonomic nervous system, especially as syncope is not an uncommon symptom in cardiac amyloidosis.⁶ With regard to the diagnosis of amyloidosis in our patient, we may also speculate on AV nodal involvement leading to third degree AV block in the past. Retrospectively, third degree AV block can be considered as one of the earliest signs of cardiac involvement in our patient. Pacemaker function was fully intact during syncope in our patient. There are several cases linking angina pectoris and intramural coronary amyloidosis.^{7,8} It may be possible that some of the persistent symptoms of chest discomfort and dyspnea in our patient, despite good stent result and comprehensive cardiac medication, may be attributable to vascular amyloidosis. On histopathology however, a direct amyloidogenic involvement of small vessels could not be observed which makes those symptoms most likely attributable to heart failure. Amyloid subtyping showed comprehensive cardiac transthyretin deposits which are indicative of senile cardiac amyloidosis or hereditary ATTR-amyloidosis. We did not perform genetic testing for transthyretin mutations to finally differentiate between these 2 subtypes since it does not imply a therapeutic consequence for our patient. Liver transplantation, as the only definitive cure for hereditary amyloidosis, is usually reserved for young patients. However, considering the advanced age of our patient, isolated cardiac involvement and no signs of peripheral neuropathy, senile cardiac amyloidosis appears to be the most likely diagnosis (Table 2). Considering that comprehensive functional cardiac involvement is rare in senile cardiac amyloidosis it is remarkable that troponin elevation guided the diagnosis. Since there is no treatable underlying cause in senile cardiac amyloidosis, treatment in our patient will be

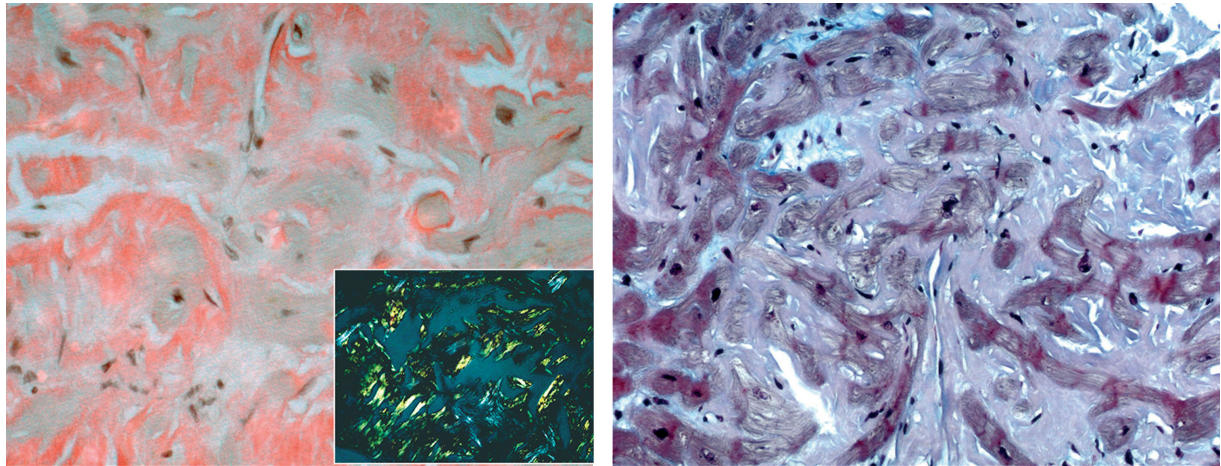


Figure 3. Congo red staining for the visualization of amyloid (left image): Note the typical green birefringence under cross-polarized light (small image). Trichrome staining (right image).

supported with consequent reduction of cardiovascular risk factors and optimal treatment of congestive heart failure symptoms. Digitalis and calcium channel blockers should be strictly avoided in cardiac amyloidosis. ACE inhibitors should be used with extreme caution due to autonomic neuronal dysregulation and risk of syncope. In case of atrial fibrillation, as in our patient, anticoagulation is strictly indicated because of the high risk of thromboembolism in amyloidosis.

Investigation of nonischemic causes of *persistent* troponin elevation is important in patients without coronary luminal obstructions. It is crucial to reach a precise diagnosis in the workup of heart failure and troponin elevation since the treatment for cardiac amyloidosis differs significantly from other forms of congestive heart failure.

Competing Interests

The author(s) declare that they have no competing interests.

References

1. Klein AL, Hatle LK, Burstow DJ, Taliencio CP, Seward JB et al.: Comprehensive Doppler assessment of right ventricular diastolic function in cardiac amyloidosis. *J Am Coll Cardiol.* 1990;15:99–108.
2. Falk RH: Diagnosis and management of the cardiac amyloidoses. *Circulation.* 2005;112:2047–2060.
3. Cornwell GG III, Westermark P: Senile amyloidosis: A protean manifestation of the aging process. *J Clin Pathol.* 1980;33:1146–1152.
4. Freda BJ, Tang WH, Van Lente F, Peacock WF, Francis GS: Cardiac troponins and renal insufficiency: review and clinical implications. *J Am Coll Cardiol.* 2002;40:2065–2071.
5. Ellis K, Dreisbach AW, Lertora JLL: Plasma elimination of cardiac troponin I in end-stage renal disease. *South Med J.* 2001;94:993–996.
6. Chamarthi B, Dubrey SW, Cha K, Skinner M, Falk RH: Features and prognosis of exertional syncope in light-chain associated AL cardiac amyloidosis. *Am J Cardiol.* 1997;80:1242–1245.
7. Mueller PS, Edwards WD, Gertz MA: Symptomatic ischemic heart disease resulting from obstructive intramural coronary amyloidosis. *Am J Med.* 2000;109:181–188.
8. Al Suwaidi J, Velianou JL, Gertz MA, Cannon RO III, Higano ST et al.: Systemic amyloidosis presenting with angina pectoris. *Ann Intern Med.* 1999;131:838–841.