

Two Brothers with Myocardial Infarction in the Absence of Atherosclerotic Coronary Artery Disease: Spontaneous Coronary Thrombosis: Case Reports of Two Brothers

Jamal Hussain, MD; Robert K. Strumpf, MD; Georges Nseir, MD; Ayman Jamal, MD; Edward Diethrich, MD

Cardiac Catheterization Laboratories, Arizona Heart Hospital and Institute, Phoenix, AZ 85006

ABSTRACT

Myocardial infarction in the absence of significant atherosclerotic coronary artery disease is not uncommonly encountered in clinical practice. This has been more often seen with the current sensitive biomarker assays for myocardial necrosis. Acute illnesses, spontaneous coronary dissection, sepsis, pulmonary embolism and coagulation disorders are some of the common clinical situation where elevated cardiac markers are noted. We describe two brothers presenting with acute myocardial infarction due to thrombus without any obvious cause.

Introduction

Myocardial infarction in the absence of significant atherosclerotic coronary artery disease is not uncommonly encountered in clinical practice. This has been more often seen with the current sensitive biomarker assays for myocardial necrosis. Acute illnesses, spontaneous coronary dissection, sepsis, pulmonary embolism, paradoxical embolism, and coagulation disorders are some of the common clinical situations where elevated cardiac markers are noted. We describe 2 brothers presenting with acute myocardial infarction due to thrombus without any obvious cause.

Case 1

A 31-year-old patient presented with pressure-like chest pain radiating to his arms, lasting about 30 minutes and finally relieved by nitroglycerin. His medical history was insignificant other than positive for smoking. He also denied illicit drug use. His ECG revealed normal sinus rhythm without evidence of ischemic abnormalities (Figure 1). His laboratory workup revealed normal hemoglobin and platelet count. His cardiac markers were as follows: creatine kinase (CK) 1162 U/L, myocardial specific iso-enzyme fraction of CK (MB) 74 ng/mL, and troponin I 17.53 ng/mL. His lipid profile revealed total cholesterol 193 mg/dl, triglycerides of 174 mg/dl, high-density lipoprotein (HDL) 38 mg/dl, and low-density lipoprotein (LDL) 120 mg/dl. The decision was made to perform coronary angiogram. Deep venous

thrombosis workup was negative. Saline contrast study for a patent foramen ovale was also normal.

Coronary angiography revealed normal left main, left anterior descending artery, and left circumflex artery. The right coronary artery which was a dominant vessel revealed a filling defect in the mid-segment extending into the posterolateral branch distal to the posterior descending artery (Figure 2). There was haziness as well as linear defects compatible with intravascular thrombus, although a dissection could not be ruled out. The thrombolysis in myocardial infarction flow (TIMI) was grade 3. Left ventriculography revealed mild inferior hypokinesis. Since the flow was normal, the patient was treated with 48 hours of eptifibatid, in addition to other standard therapy and coronary angiography was repeated. Repeat angiography revealed a filling defect in the mid right coronary artery extending distally, suggestive of intracoronary thrombus and possible dissection. The decision was made to perform intravascular ultrasound. The lesion was crossed with a 0.014 inch balanced middle weight wire. Intravascular ultrasound was done with Eagle Eye Volcano probe (manufactured by Volcano Corporation, San Diego, CA). Images were consistent with intracoronary thrombus (Figure 3). The ultrasound probe was removed and a suction thrombectomy with an Export catheter was done and we extracted a significant amount of the clot (Figure 4). Balloon angioplasty of the persistent thrombus was done with 2.0 mm × 15 mm maverick balloon. Repeat angiography was done which revealed a

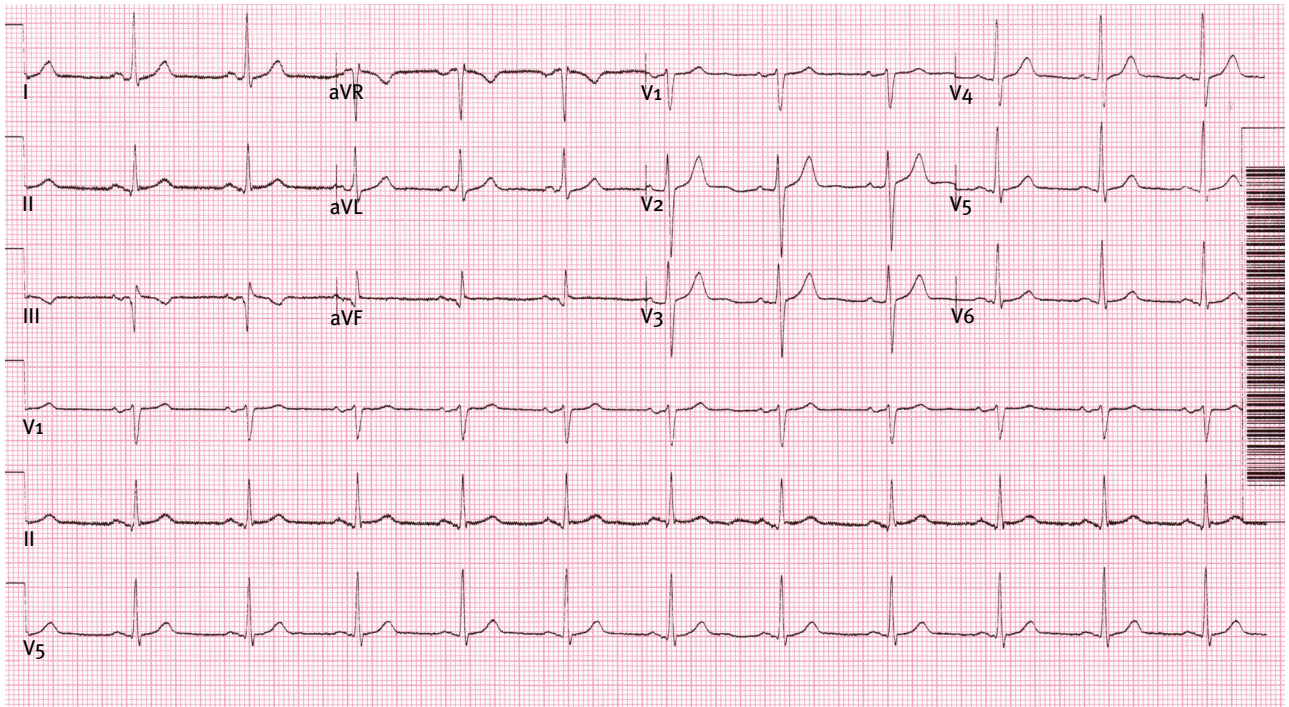


Figure 1. Electrocardiogram with nonspecific inferior T wave abnormalities and possible inferior Q waves.

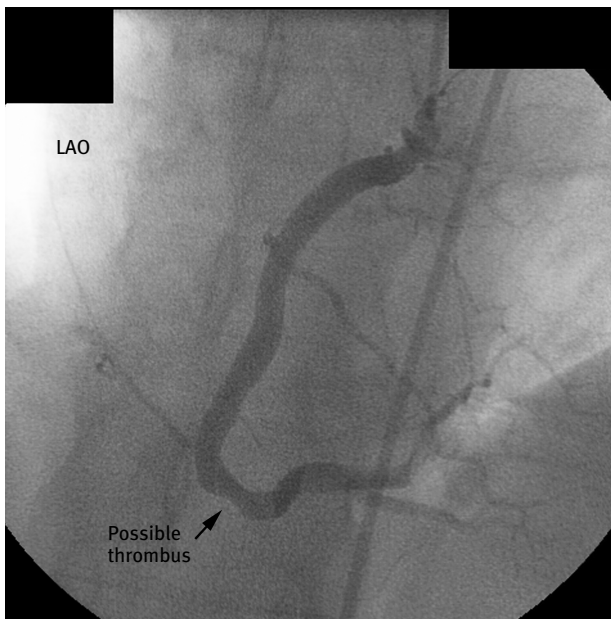


Figure 2. Mid right coronary artery (RCA) with haziness and filling defect suggestive of intracoronary thrombus. A, left anterior oblique (LAO) view. B, right anterior oblique (RAO) view.

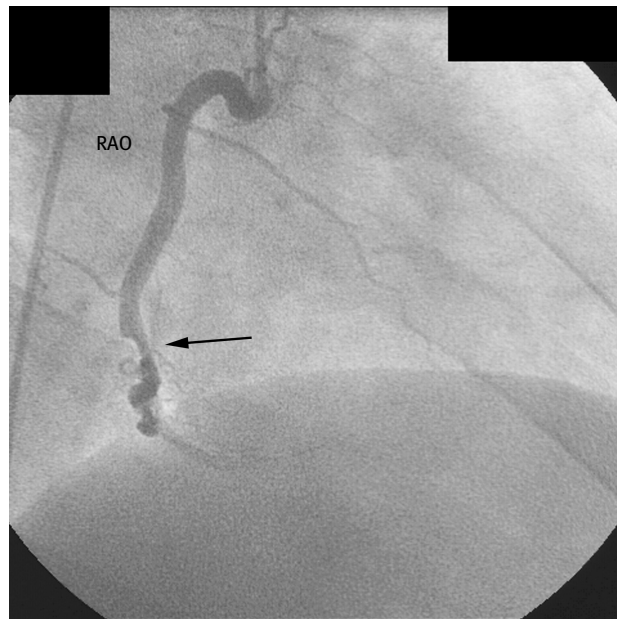


Figure 3. Intravascular ultrasound finding consistent with intracoronary thrombus.

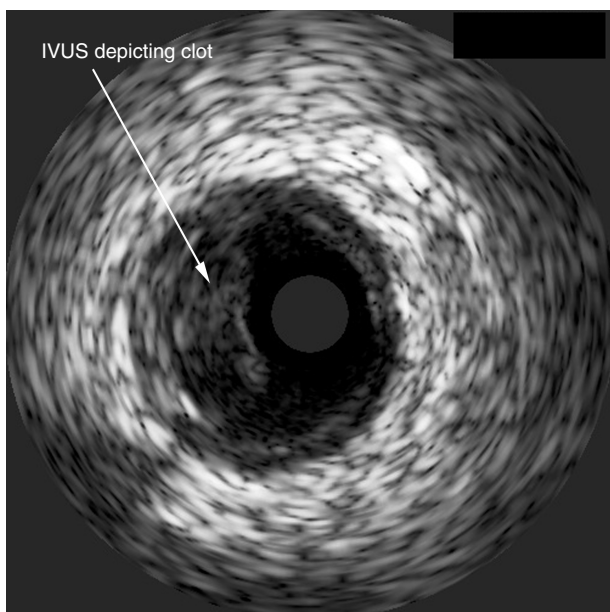


Figure 4. Thrombus extracted with suction thrombectomy.




Figure 5. Postangioplasty RCA with almost complete resolution of the previous haziness.

wide open right coronary artery with mild residual thrombus in the distal right coronary artery and posterolateral branch (Figure 5). The patient was later discharged in stable condition on aspirin and clopidogrel. Subsequent workup for

hypercoagulable state came back as negative. This workup included protein S, homocystine, protein C, lupus anticoagulant, factor V Leiden mutation, and cardiolipin antibody.

Case 2

A 28-year-old man was admitted to the hospital with non-ST-elevation myocardial infarction. He woke up with chest pain, nausea, and diaphoresis. The chest pain lasted for about 3 hours until he came to the hospital where his pain was relieved by nitroglycerine. He did not have any medical risk factors for coronary artery disease and he denied using illicit drugs. His ECG revealed sinus rhythm with T wave inversion inferiorly (Figure 6). Peak cardiac markers were as follows: CK 508 U/L, MB 53 ng/mL, and Troponin I (specific protein for myocardial infarction, normal value: < 0.4 nanogram/milliliter) 11 ng/mL.

Cardiac catheterization was performed. Left main, left anterior descending artery, and the right coronary arteries were normal angiographically. The left circumflex artery which was a large dominant vessel had an eccentric about 70% filling defect distally (Figure 7). This was stented with a bare-metal Driver 4.0 mm × 18 mm stent (Figure 8). The patient was subsequently observed and discharged in stable condition. No other abnormality was found as a possible cause for his myocardial infarction, therefore we thought that this may have been an isolated spontaneous coronary thrombus or dissection.

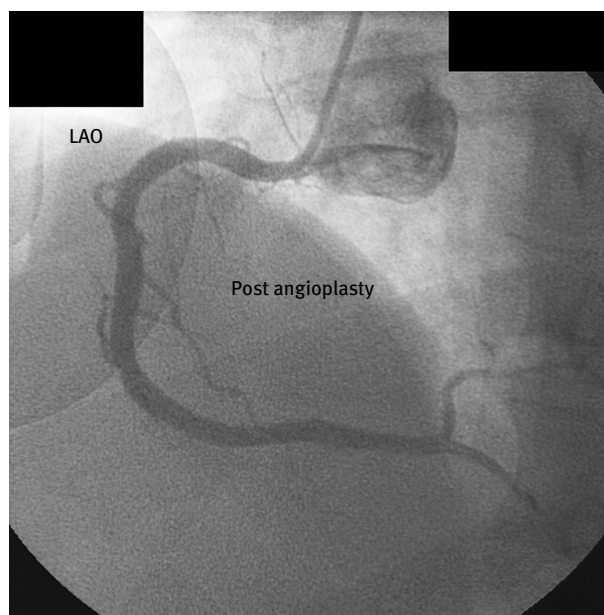

Figure 6. Electrocardiogram with nonspecific inferior T waves abnormalities.

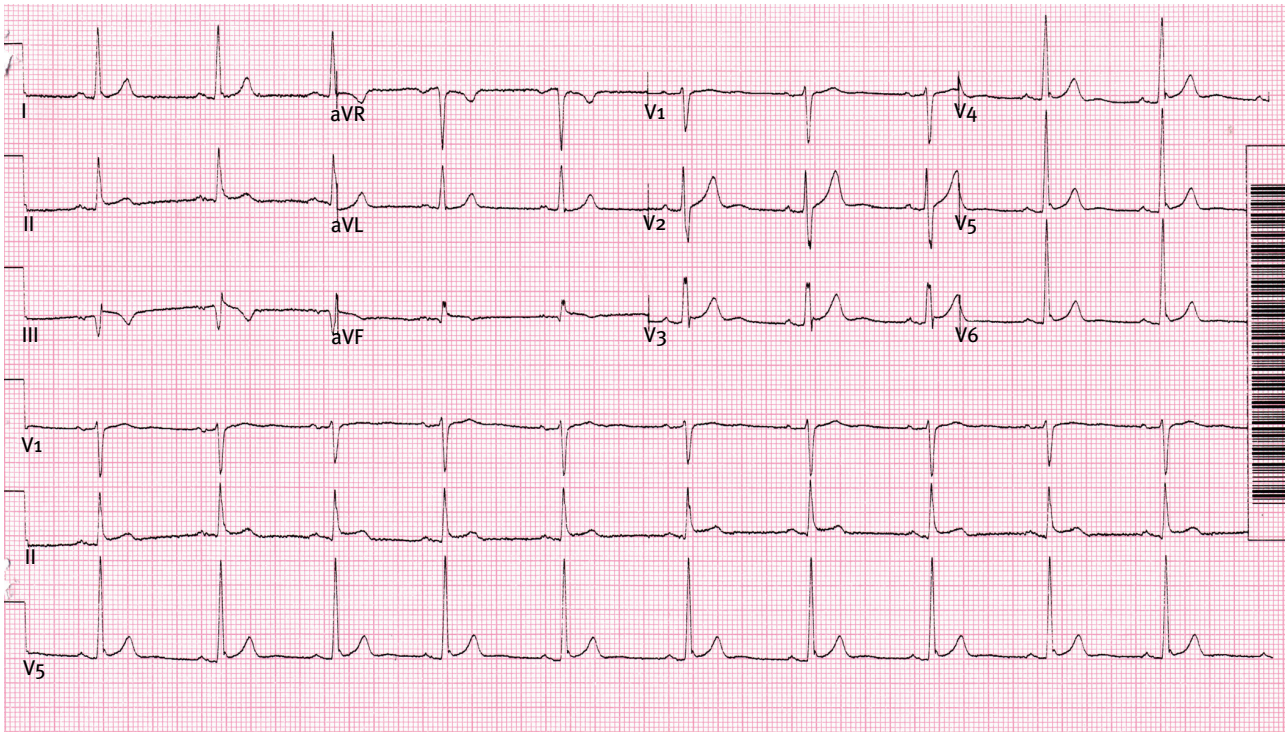


Figure 7. Distal left circumflex artery showing intraluminal haziness suggestive of thrombus and possible dissection.

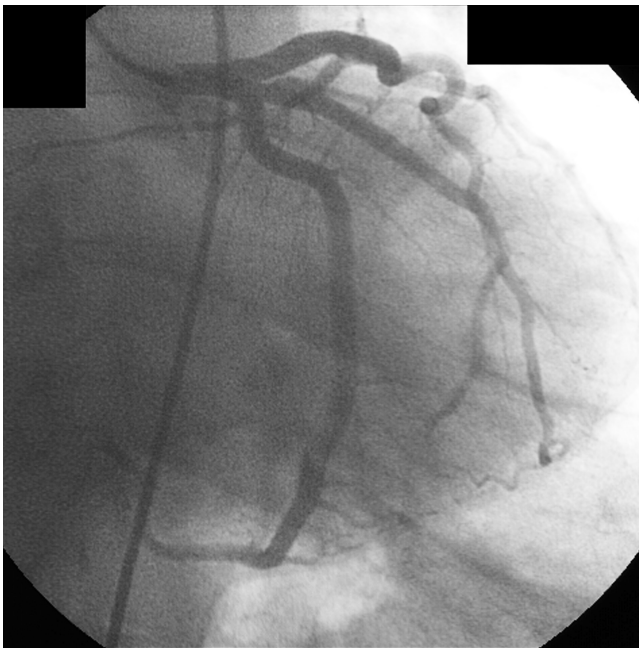


Figure 8. Left circumflex artery after stenting.

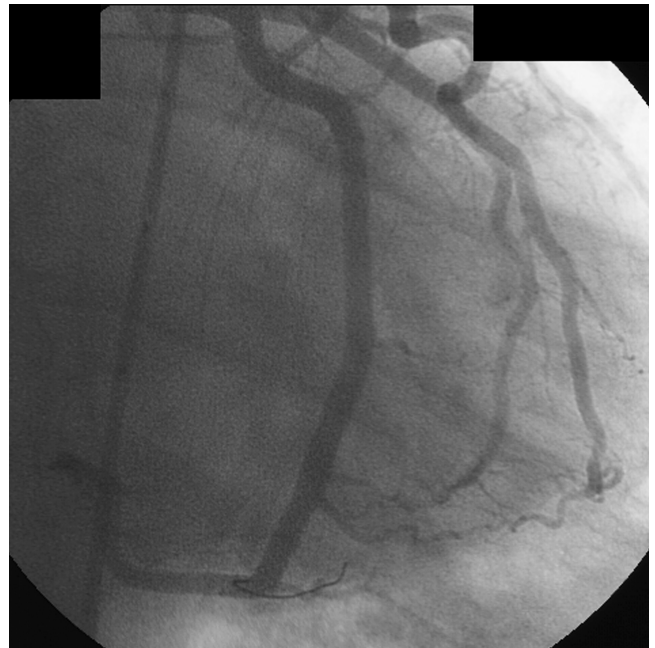


Figure 9.

Discussion

The incidence of myocardial infarction without significant coronary artery disease is rare, in the range of 1% to 3%.^{1,2} Previously described conditions include spontaneous coronary dissection, paradoxical embolism, spontaneous coronary spasm, illicit drugs such as cocaine use, and rarely, hypercoagulable states. Spontaneous coronary thrombus has been reported in association with coronary spasm, injured endothelium, or rupture of atherosclerotic plaques.

In our first case, none of the above conditions were found. It is possible that the acute events were preceded by coronary spasm or there was vascular endothelium injury, however no such abnormality was detected by intravascular ultrasound. Epicardial vasospasm is a possibility, but unlikely as such patients usually have recurrent chest pain episodes rather than acute myocardial infarction as their first presenting complaint.³ Induction of coronary spasm by acetylcholine may have helped in establishing diagnosis of coronary spasm leading to coronary thrombus and hence myocardial infarction.⁴ We thought that the coronary may have been the triggering event however it was excluded by intravascular ultrasound (IVUS). Spontaneous coronary dissections have been mainly described in peripartum female patients.⁵ The fact that the 2 siblings had similar events at a young age may signify some unidentified genetic etiology. The optimum medical therapy for such patient is also unknown. Whether antiplatelets or anticoagulant drug

therapy would prevent future events in such patients is unknown at the present time, but would seem a reasonable option. HMG CoA Reductase inhibitors: 3-hydroxy-3-methylglutaryl-Co-enzymeA reductase inhibitors or statin drugs may help stabilize endothelial reactivity and perhaps prevent clot formation.

Acknowledgments

Special thanks to Yvonne Smith for helping with manuscript preparation.

References

1. Erlechner JA. Transmural myocardial infarction with normal coronary arteries. *Am Heart J.* 1979;98:421.
2. Betriu A, Pare JC, Sanz GA, et al. Myocardial infarction with normal coronary arteries: a prospective clinical angiographic study. *Am J Cardiol.* 1981;48:28.
3. Hongato Sun, Masahiro Mohri, Hiroaki Shimokawa, Makoto, Usui. Coronary microvascular spasm causes myocardial ischemia in patient with vasospastic angina. *J Am Coll Cardiol.* 2002;39:847–851.
4. Yasuhiro Endoh, Nitaro Shibata, Kou Talceichi. Coronary thrombosis induced by intracoronary acetylcholine in a patient with normal coronary myocardial infarction. *Internal Medicine.* 1995;34(3) 349-II.
5. Siamak Aliyary, Massimo A. Mariani, Patrick M.J. Verhorst, Mark Hartman, Martin G. Stoel, and Clemens Von Birgelen. Staged Therapeutic Approach in Spontaneous Coronary Dissection. *Ann Thorac Surg.* 2007;83:1879–1881.