

Electrocardiographic Criteria for Predicting Total Occlusion of the Proximal Left Anterior Descending Coronary Artery in Anterior Wall Acute Myocardial Infarction

MASAMI KOSUGE, M.D., KAZUO KIMURA, M.D., TOSHIYUKI ISHIKAWA, M.D., TSUTOMU ENDO, M.D., TOMOHIKO SHIGEMASA, M.D., MITSUGI SUGIYAMA, M.D., OSAMU TOCHIKUBO, M.D., SATOSHI UMEMURA, M.D.

The Department of Cardiology, Yokohama City University Medical Center, Yokohama, Japan

Summary

Background: Patients with occlusion of the left anterior descending coronary artery (LAD) proximal to both the first septal branch and the first diagonal branch may benefit most from early reperfusion therapy due to extensive area at risk.

Hypothesis: The aim of the study was to examine whether 12-lead electrocardiograms (ECGs) in the acute phase of acute myocardial infarction (AMI) could identify total occlusion of the LAD proximal to both the first septal and the first diagonal branch.

Methods: A 12-lead electrocardiogram was recorded on admission in 128 patients with anterior AMI within 12 h from symptom onset. Patients were divided into three groups according to the culprit lesion: 33 patients had total occlusion of the LAD proximal to both the first septal perforator and the first diagonal branch (Group P), in 51 it was proximal to either the first septal perforator or the first diagonal branch (Group D-a), and in 44 it was distal to both the first septal perforator and the first diagonal branch (Group D-b).

Results: Sensitivity and specificity of a greater degree of ST-segment depression in lead III than that of ST-segment elevation in lead aVL were 85 and 95%, respectively, which was better than the results derived by all other ECG criteria ($p < 0.001$).

Conclusions: We conclude that a greater degree of ST-segment depression in lead III than that of ST-segment elevation in lead aVL is a useful predictor of proximal LAD occlusion in patients with anterior AMI.

Key words: acute myocardial infarction, electrocardiography, ST segment

Introduction

The clinical outcome of myocardial infarction is determined largely by infarct size,^{1,2} which is influenced by several factors, that is, the extent of area at risk, collateral flow development, myocardial metabolic demand, and duration of complete coronary artery occlusion.^{3–7} Because the number of branches proximal to the site of coronary artery occlusion is generally related to infarct size,^{8–10} patients with occlusion of the left anterior descending coronary artery (LAD) proximal to both the first septal and the first diagonal branch may benefit most from early reperfusion therapy. Therefore, we examined whether 12-lead electrocardiograms (ECGs) obtained in the acute phase of myocardial infarction (AMI) could identify the culprit lesion, that is, total occlusion proximal to both the first septal and the first diagonal branch, in patients with anterior wall AMI.

Methods

Patients

Between December 1990 and November 1998, 515 patients with anterior wall AMI were admitted to our coronary care unit. A total of 128 patients (99 men, 29 women, aged 29–81 years [mean \pm standard deviation, 60 ± 11]) fulfilled the following inclusion criteria and were enrolled in our study: (1) a first AMI, (2) complete occlusion (Thrombolysis in Myocar-

Address for reprints:

Kazuo Kimura, M.D.
The Department of Cardiology
Yokohama City University Medical Center
4-57 Urafune-cho, Minami-ku
Yokohama 232-0024, Japan

Received: January 26, 2000

Accepted with revision: March 23, 2000

dial infarction [TIMI grade 0]¹¹ of the LAD as confirmed by coronary angiography within 12 h from the onset of symptoms, (3) successful reperfusion (TIMI grade 3 flow) of the LAD, and (4) no transient or permanent bundle-branch block during the study period.

Anterior wall AMI was diagnosed on the basis of typical chest pain for > 30 min, ST-segment elevation of at least 1 mm in two contiguous precordial leads, and a typical increase in serum creatine kinase to more than twice the upper limit of normal.

Coronary Angiography

Coronary angiography was performed immediately after admission. The grade of collateral filling in the LAD was evaluated according to the criteria of Rentrop *et al.*¹² (0 = no visible filling of any collateral channel, 1 = filling of only side branches without visualization of the epicardial segment, 2 = partial filling of the epicardial segment, and 3 = complete filling of the epicardial segment). A good collateral channel was defined as grade 2 or 3, and a poor collateral channel as grade 0 or 1. Reperfusion was defined as the establishment of TIMI grade 3 coronary flow. Multiple projections of the LAD were examined and the LAD extending around the cardiac apex to the inferior wall was termed a wraparound artery.¹³ In the right coronary artery and the left circumflex coronary artery, stenosis was considered significant if the lumen diameter was narrowed by $\geq 75\%$ in any projection.

Electrocardiographic Analysis

A 12-lead ECG was recorded immediately before reperfusion, as confirmed by coronary angiography, at a paper speed of 25 mm/s and an amplification of 10 mm/mV. The isoelectric line was defined as the level of the preceding TP segment. The degree of ST-segment deviation was measured to the nearest 0.5 mm at the J point in each of the 12 standard leads. Measurements of three contiguous beats obtained by two independent observers blinded to all clinical and angiographic data were averaged for each lead. ST-segment deviation was

considered clinically significant if it was ≥ 0.5 mm above the isoelectric line.

Cardiac Enzyme Study

Blood samples were obtained on admission and at 3-h intervals during the first 24 h, at 6-h intervals for the next 2 days, and then daily until discharge. Serum creatine kinase activity was measured by the method of Rosalki.¹⁴

Statistical Analysis

Mean values \pm standard deviation (SD) were calculated for continuous variables, and absolute and relative frequencies were measured for discrete variables. For continuous variables, the statistical significance of differences between groups was analyzed by unpaired Student's *t*-test. The chi-square test was used to compare differences between discrete variables. A probability (*p*) value < 0.05 was considered to represent a statistically significant difference.

Results

Patient Characteristics

Patients were divided into three groups according to the culprit lesion as documented by coronary angiography: 33 patients had total occlusion of the LAD proximal to both the first septal and the first diagonal branch (Group P), 51 had total occlusion proximal to either the first septal or the first diagonal branch (Group D-a), and 44 had total occlusion distal to both the first septal and the first diagonal branch (Group D-b) (Figs. 1, 2). The clinical and angiographic characteristics of the three groups are summarized in Table I. There were no significant differences among the three groups in age, gender, time interval from symptom onset to recording of ECG, collateral development, concomitant right coronary artery disease, wraparound LAD, or incidence of previous angina. Peak creatine kinase was significantly greater in Group P than in Group D-b (*p* < 0.01).

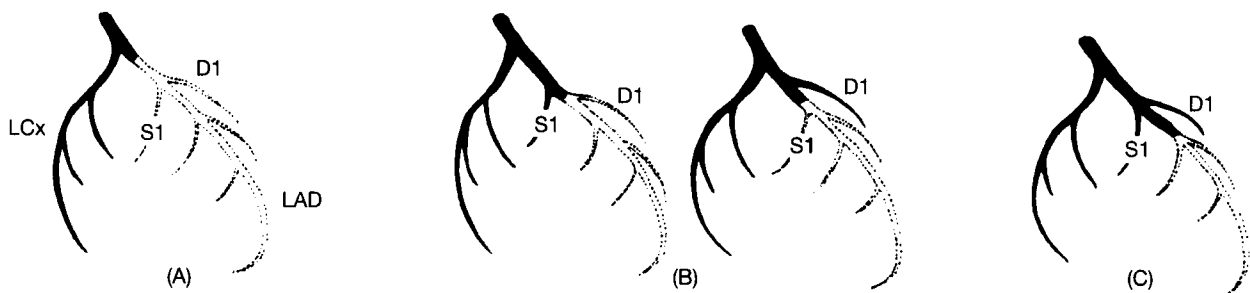


FIG. 1 Schema of the site of the left anterior descending coronary artery (LAD) occlusion of the three groups. (A) Group P: total occlusion of the LAD proximal to both the first septal perforator (S1) and the first diagonal branch (D1). (B) Group D-a: total occlusion of the LAD proximal to either S1 or D1. (C) Group D-b: total occlusion of the LAD distal to both S1 and D1. LAD = left anterior descending coronary artery, LCx = left circumflex coronary artery.

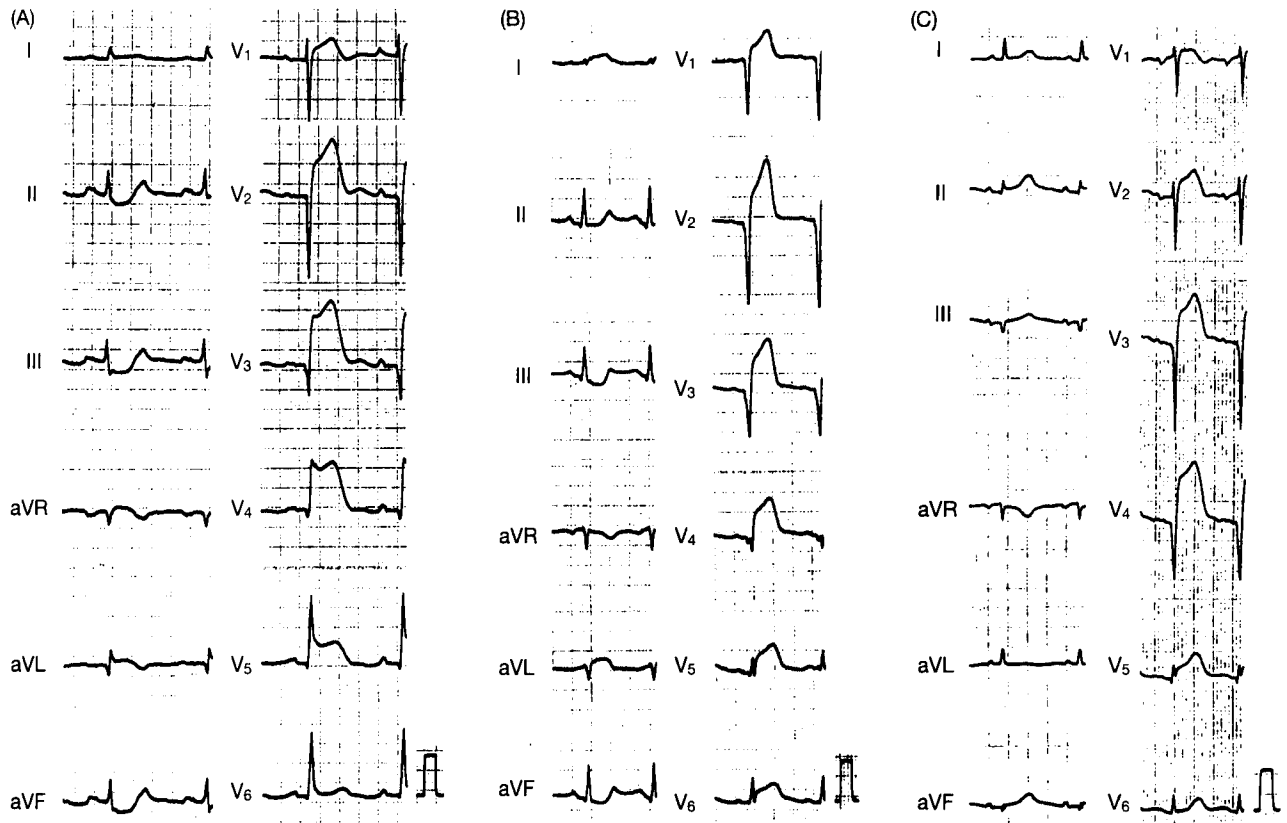


FIG. 2 Representative electrocardiograms of the three groups. (A) Group P: total occlusion of the left anterior descending coronary artery (LAD) proximal to both S1 and D1. The magnitude of ST-segment depression in lead III (ST ↓ III) was 2.5 mm. The magnitude of ST-segment elevation in lead aVL (ST ↑ aVL) was 1.0 mm. ST ↓ III > ST ↑ aVL. (B) Group D-a: total occlusion of the LAD proximal to S1 and distal to D1. ST ↓ III was 1.5 mm. ST ↑ aVL was 1.5 mm. ST ↓ III = ST ↑ aVL. (C) Group D-b: total occlusion of the LAD distal to both S1 and D1. ST-segment depression was not observed in lead III. ST-segment elevation was not observed in lead aVL.

Electrocardiographic Findings

ST-segment deviation in precordial leads (Tables II): ST-segment elevation in precordial leads (V₁₋₆): The degree of ST-

segment elevation in all precordial leads was slightly but not significantly greater in Group P than in Groups D-a and D-b.

ST segment deviation in limb leads (Tables II, III): ST-segment depression in inferior leads (II, III, aVF): The degree

TABLE I Clinical and angiographic characteristics of subjects

	Group P (n = 33)	Group D-a (n = 51)	Group D-b (n = 44)
Age (years)	60 ± 12	59 ± 11	60 ± 11
Men (%)	27 (82)	41 (80)	31 (70)
Time to recording ECG (h)	3.3 ± 1.4	3.8 ± 1.5	4.0 ± 1.6
Previous angina (%)	23 (70)	26 (51)	26 (59)
Collateral grade ≥ 2 ^a (%)	12 (36)	21 (41)	12 (27)
Wraparound LAD (%)	16 (48)	35 (69)	24 (55)
Concomitant RCA disease (%)	6 (18)	12 (24)	6 (13)
Peak CPK (mU/ml)	5548 ± 2909	4435 ± 2538	3470 ± 2128 ^b
Time to peak CPK (h)	10.1 ± 3.8	11.6 ± 4.2	10.7 ± 4.3

Patients are subgrouped according to the site of coronary artery occlusion. Data presented are mean value ± standard deviation.

^a Rentrop classification.

^b p < 0.01 vs. Group P.

Abbreviations: ECG = electrocardiogram, Wraparound LAD = the left anterior descending coronary artery wrapped around the cardiac apex to the inferior wall, RCA = right coronary artery, CPK = creatine phosphokinase.

TABLE II Relation of the culprit lesion to electrocardiographic (ECG) findings

ECG findings	Group P (n=33)	Group D-a (n=51)	Group D-b (n=44)
Limb leads			
I	0.8 ± 1.2	0.5 ± 0.7	0.3 ± 0.5 ^c
II	-1.0 ± 0.9	-0.4 ± 0.5 ^a	-0.2 ± 0.5 ^a
III	-2.1 ± 1.5 ^d	-0.7 ± 0.8 ^a	-0.4 ± 0.7 ^a
aVR	0.1 ± 0.7	-0.2 ± 0.4 ^b	-0.2 ± 0.5 ^b
aVL	1.5 ± 1.3	0.7 ± 0.8 ^a	0.3 ± 0.7 ^a
aVF	-1.4 ± 1.0	-0.6 ± 0.7 ^a	-0.3 ± 0.6 ^a
Precordial leads			
V ₁	2.2 ± 1.3	1.9 ± 1.2	1.7 ± 1.0
V ₂	4.7 ± 2.6	4.5 ± 2.6	4.1 ± 2.4
V ₃	6.1 ± 3.7	5.5 ± 3.6	5.1 ± 3.6
V ₄	4.9 ± 4.3	4.1 ± 3.6	4.1 ± 3.5
V ₅	2.2 ± 2.9	1.8 ± 2.3	1.2 ± 1.5
V ₆	0.6 ± 1.4	0.4 ± 1.1	0.3 ± 0.5

Data presented are mean values ± standard deviation.

^a p < 0.001.

^b p < 0.01.

^c p < 0.05 vs. Group P.

^d p < 0.05 vs. lead II or lead aVF in Group P.

of ST depression in leads II, III, and aVF was significantly greater in Group P than in the other two groups (p < 0.001). In Group P, the degree of ST depression was significantly higher in lead III than in leads II and aVF.

ST-segment elevation in lateral leads (I, aVL): The degree of ST elevation in lead aVL was significantly greater in Group P than in Groups D-a and D-b (p < 0.001).

ST-segment deviation in lead aVR: The degree of ST elevation in lead aVR was significantly higher in Group P than in the other two groups (p < 0.01).

Relation of ST-segment elevation in lead aVL to ST-segment depression in lead III: The degree of ST-segment depression in lead III was greater than that of ST-segment elevation in lead aVL in 85% of Group P. This rate was significantly higher than the corresponding values in the other two groups (p < 0.001).

Sensitivity, specificity, and predictive accuracy of different ECG criteria defining total occlusion of the proximal LAD: The sensitivity, specificity, and the positive and negative predictive values of the various ECG criteria defining total occlusion of the LAD proximal to both the first septal and the first diagonal branch are shown in Table IV. ST-segment elevation in lead aVL of ≥ 0.5 mm and ST-segment depression in lead III of ≥ 0.5 mm had a high sensitivity but a low specificity for predicting occlusion of the proximal LAD. In contrast, ST-segment elevation in lead aVR of ≥ 0.5 mm had a high specificity but a low sensitivity for predicting occlusion of the proximal LAD. The sensitivity and specificity of a greater degree of ST-segment depression in lead III than that of ST-segment elevation in lead aVL were 85 and 95%, respectively, and the predictive accuracy was 92%, which was better than the results derived by all other ECG criteria (p < 0.001).

TABLE III Relation of ST-segment elevation in lead aVL to ST-segment depression in lead III

	Group P (n=33)	Group D-a (n=51)	Group D-b (n=44)
ST ↓ III > ST ↑ aVL (%)	28 (85)	3 (6) ^a	2 (5) ^a
ST ↓ III = ST ↑ aVL (%)	4 (12)	25 (49) ^b	13 (29)
ST ↓ III < ST ↑ aVL (%)	0	0	1 (2)
Absence of ST-segment depression in lead III or ST-segment elevation in lead aVL (%)	1 (3)	23 (45) ^a	28 (64) ^a

^a p < 0.001.

^b p < 0.01 vs. Group P.

Abbreviations: ST ↓ III = the magnitude of ST-segment depression in lead III, ST ↑ aVL = the magnitude of ST-segment elevation in lead aVL.

Discussion

Infarct size is a most important predictor of outcome in AMI.^{1,2} Because the amount of myocardium salvaged by reperfusion therapy is proportional to the initial amount of jeopardized myocardium,¹⁵ patients with a greater area at risk may benefit more from early reperfusion. In particular, patients with total occlusion of the proximal LAD would need a more aggressive approach to reperfusion due to extensive area at risk. The standard 12-lead ECG is simple, noninvasive, and can be readily obtained. We therefore examined whether a 12-lead ECG in the acute phase of AMI could identify the culprit lesion, that is, total occlusion proximal to both the first septal and the first diagonal branch in patients with anterior wall AMI.

Several studies have investigated the relation between ECG changes and the site of the culprit lesion during anterior wall AMI.^{16,17} Our data showed that a greater degree of ST-segment depression in lead III than that of ST-segment elevation in lead aVL was a reliable index distinguishing Group P from Groups D-a or D-b (Table III). We described several ECG findings regarding prediction of proximal LAD occlusion in anterior wall AMI (Table IV). The overall diagnostic accuracy of ST-segment deviation in leads aVL, III, and aVR ranged from 56 to 78%, and these findings were consistent with previous reports.^{16,17} However, by considering the ST-segment deviation between leads aVL and III, the predictive accuracy increased significantly to 92%, which was higher than that derived from the above ECG criteria. We conclude that a greater degree of ST-segment depression in lead III than that of ST-segment elevation in lead aVL is a useful predictor of the occlusion of the LAD proximal to both the first septal and the first diagonal branch. Previous studies^{16,17} demonstrated that ST-segment depression in the inferior leads is useful for identifying proximal LAD occlusion in patients with anterior wall AMI, but the relation of ST-segment elevation in lead aVL to ST-segment depression in lead III was not mentioned. In addition, since they did not record ECGs simultaneously with

TABLE IV Sensitivity, specificity, and accuracy for the different criteria predicting total occlusion of the proximal left anterior descending coronary artery

	Sensitivity (%)	Specificity (%)	Positive predictive value (%)	Negative predictive value (%)	Predictive accuracy (%)
ST \uparrow aVL \geq 0.5 mm	100	44 ^a	38 ^a	100	56 ^a
ST \uparrow aVL \geq 1.0 mm	75	78 ^a	54 ^a	90	77 ^a
ST \uparrow aVR \geq 0.5 mm	39 ^a	92 ^a	62 ^a	81	78 ^a
ST \downarrow III \geq 0.5 mm	97	45 ^a	38 ^a	98	56 ^a
ST \downarrow III \geq 1.0 mm	88	74 ^a	54 ^a	95	77 ^a
ST \downarrow III > ST \uparrow aVL	85	95	85	95	92

^ap < 0.001 vs. ST \downarrow III > ST \uparrow aVL.

Abbreviation: ST \uparrow aVR = the magnitude of ST-segment elevation in lead aVR. Other abbreviations as in Table III.

coronary angiography, the ECG findings in their studies might not reflect exactly the occlusion site of the LAD.¹⁸ Therefore, to clarify the correlation between ECG findings and the LAD occlusion site, we recorded ECGs immediately before reperfusion, as confirmed by coronary angiography.

ST-segment elevation in lead aVL probably represents transmural ischemia in the basal anterolateral region supplied by the first diagonal branch,¹⁹ whereas ST-segment depression in inferior leads during anterior wall AMI represents a reciprocal change to the basal anterolateral region, as shown by ST-segment elevation in leads I and aVL.^{20,21} We also found that the degree of ST-segment depression in lead III was about equal to that of ST-segment elevation in lead aVL in patients with LAD occlusion distal to the first septal branch, the first diagonal branch, or both, which is in agreement with the previous report.²¹ However, the magnitude of ST-segment depression in lead III was greater than that of ST-segment elevation in lead aVL in the majority of patients with LAD occlusion proximal to both the first septal and the first diagonal branch. In the latter case, the injury current originating from the basal anterior septum supplied by the first septal branch would be oriented anterosuperiorly and to the right, and that originating from the basal anterolateral region supplied by the first diagonal branch would be oriented anterosuperiorly and to the left, resulting in the injury current oriented anterosuperiorly more strongly.¹⁶ This injury current may be reflected more suitably in the inferior leads for reciprocal change.

The other factors may influence ST-segment deviation in inferior leads. Although subendocardial rather than transmural myocardial ischemia would be expected to produce ST-segment depression,²² there were no differences among the three groups in the proportions of patients with clinically significant stenosis in the right coronary artery. In addition, we found no evidence indicating that a wraparound LAD, which can cause the inferior ST segment to shift upward rather than downward,¹³ was less frequent in patients with proximal LAD occlusion. The possibility that reciprocal ST-segment depression may be caused by ST-segment elevation in precordial leads was also not taken into consideration, because significant differences in the degree of precordial ST-segment elevation were not observed among the three groups.

Clinical Implications

It is important to be able to predict patients with total occlusion of the proximal LAD, which can cause extensive anterior wall AMI. Ideally, such assessment should be simple, quick, and noninvasive. This study shows that a greater degree of ST-segment depression in lead III than that of ST-segment elevation in lead aVL is a useful predictor of total occlusion of the LAD proximal to the first septal and the first diagonal branch. Therefore, recognition of this ECG criterion may be helpful in designing therapeutic strategies effective in the early stage of anterior wall AMI.

Study Limitations

We used very strict entry criteria for precise evaluation of the correlation between ECG and angiographic findings. Therefore, this was a small retrospective study of patients with total occlusion and successful reperfusion of the LAD as confirmed by coronary angiography within 12 h after symptom onset. Blanke *et al.*¹⁸ reported that ECG findings were not necessarily similar in patients with total occlusion and those with subtotal occlusion of an infarct-related artery. The criteria defined in this study may not be applicable in patients with subtotal occlusion. Because we focused on the prediction of occlusion of the LAD proximal to both the first septal and the first diagonal branch to identify patients who need a more aggressive approach to reperfusion because of extensive area at risk, we could unfortunately not distinguish accurately patients with occlusion of the LAD proximal to either the first septal or the first diagonal branch from those with occlusion proximal to both the first septal and the first diagonal branch. Further studies in larger numbers of patients are needed to confirm the clinical usefulness of our ECG criterion in patients with anterior wall AMI.

Conclusion

It is the conclusion of this study that a greater degree of ST-segment elevation in lead aVL is a useful predictor of occlu-

sion of the proximal left anterior descending coronary artery in patients with acute myocardial infarction.

References

1. The Multicenter Postinfarction Research Group: Risk stratification and survival after myocardial infarction. *N Engl J Med* 1983;309:331-336
2. Sheehan FH, Mathey DG, Schofer J, Krebber HJ, Dodge HT: Effect of interventions in salvaging left ventricular function in acute myocardial infarction: A study of intracoronary streptokinase. *Am J Cardiol* 1983;52:431-438
3. Reimer KA, Jennings RB, Cobb FR, Murdock RH, Greenfield JC Jr, Becker LC, Bulkley BH, Hutchins GM, Schwartz RP Jr, Bailey KR: Animal models for protecting ischemic myocardium: Results of the NHLBI cooperative study. Comparison of unconscious and conscious dog models. *Circ Res* 1985;56:651-665
4. Reimer KA, Jennings RB: The wavefront phenomenon of myocardial ischemic cell death. II. Transmural progression of necrosis within the framework of ischemic bed size (myocardial at risk) and collateral flow. *Lab Invest* 1979;40:633-644
5. Murdock RH Jr, Chu A, Grubb M, Cobb FR: Effects of reestablishing blood flow on extent of myocardial infarction in conscious dogs. *Am J Physiol* 1985;249:783-791
6. Jugdutt BI, Hutchin GM, Bulkley BH, Becker LC: Myocardial infarction in the conscious dog: Three-dimensional mapping of infarct, collateral flow and region at risk. *Circulation* 1979;60:1141-1150
7. Christian TF, Schwartz RS, Gibbons RJ: Determinants of infarct size in reperfusion therapy for acute myocardial infarction. *Circulation* 1992;96:81-90
8. Lew AS, Hod H, Cercek B, Shah PK, Ganz W: Inferior ST-segment changes during acute anterior myocardial infarction: A marker of the presence or absence of concomitant inferior wall ischemia. *J Am Coll Cardiol* 1987;10:519-526
9. Lowe JE, Reimer KA, Jennings RB: Experimental infarct size as a function of the amount of myocardium at risk. *Am J Pathol* 1978;90:363-380
10. Lee JT, Ideker RE, Reimer KA: Myocardial infarct size and location in relation to the coronary vascular bed at risk in man. *Circulation* 1981;64:526-537
11. The TIMI study group: The Thrombolysis in Myocardial Infarction (TIMI) trial: Phase I findings. *N Engl J Med* 1985;312:932-936
12. Rentrop KP, Cohen M, Blanke H, Philips RA: Change in collateral channel filling immediately after controlled coronary artery occlusion by an angioplasty balloon in human subjects. *J Am Coll Cardiol* 1985;5:587-592
13. Sapin PM, Musselman DR, Dehmer GJ, Cascio WE: Implications of inferior ST-segment elevation accompanying anterior wall acute myocardial infarction for the angiographic morphology of the left anterior descending coronary artery and site of occlusion. *Am J Cardiol* 1992;69:860-865
14. Rosalki SB: An improved procedure for serum creatine phosphokinase determination. *J Lab Clin Med* 1967;69:696-705
15. Mauri F, Gasparini M, Barbonaglia L, Santoro E, Franzosi MG, Tognoni G, Rovelli F: Prognostic significance of the extent of myocardial injury in acute myocardial infarction treated by streptokinase (the GISSI trial). *Am J Cardiol* 1989;63:1291-1295
16. Tamura A, Kataoka H, Mikuriya Y, Nasu M: Inferior ST segment depression as a useful marker for identifying proximal left anterior descending artery occlusion during acute anterior myocardial infarction. *Eur Heart J* 1995;16:1795-1799
17. Engelen DJ, Gorgels AP, Cheriex EC, De Muinck ED, Ophuis AJO, Dassen WR, Vainer J, Ommen VG, Wellens HJ: Value of the electrocardiogram in localizing the occlusion site in the left anterior descending coronary artery in acute anterior myocardial infarction. *J Am Coll Cardiol* 1999;34:389-395
18. Blanke H, Cohen M, Schlueter GU, Karsch KR, Rentrop KP: Electrocardiographic and coronary arteriographic correlations during acute myocardial infarction. *Am J Cardiol* 1984;54:249-255
19. Birnbaum Y, Sclarovsky S, Solodky A, Tschori J, Herz I, Sulkes J, Mager A, Rechavia E: Prediction of the level of left anterior descending coronary artery obstruction anterior wall acute myocardial infarction by admission electrocardiogram. *Am J Cardiol* 1993;72:823-826
20. Haraphongse M, Tanomsup S, Jugdutt BI: Inferior ST-segment depression during acute myocardial infarction: Clinical and angiographic correlation. *J Am Coll Cardiol* 1984;4:467-476
21. Birnbaum Y, Solodky A, Herz I, Kusniec J, Rechavia E, Sulkes J, Sclarovsky S: Implications of ST-segment depression in anterior acute myocardial infarction: Electrocardiographic and angiographic correlation. *Am Heart J* 1994;127:1467-1473
22. Holland RP, Brooks H: TQ-ST segment mapping critical review and analysis of current concepts. *Am J Cardiol* 1977;40:110-129