

Retrograde Atrial Kick in Acute Aortic Regurgitation. Study of Mitral and Pulmonary Venous Flow Velocities by Transthoracic and Transesophageal Echocardiography

ISIDRE VILACOSTA, M.D., JOSÉ ALBERTO SAN ROMÁN, M.D.,* JUAN ANTONIO CASTILLO, M.D., LOURDES ARGANDA, M.D.,
MARÍA JESÚS ROLLÁN, M.D., VICENTE PERAL, M.D., LUIS SÁNCHEZ-HARGUINDEY, M.D., PEDRO ZARCO, M.D.†

Hospital Universitario de San Carlos, Madrid; *Servicio de Cardiología, Hospital Universitario de Valladolid, Valladolid; †Servicios de Cardiología y Cardiopulmonar, Madrid, Spain

Summary

Background and hypothesis: The purpose of this study was the comprehensive evaluation of the changes in pulmonary venous and mitral flow velocities of patients with acute and chronic severe aortic regurgitation. Transmitral flow velocities obtained with pulsed-wave Doppler echocardiography have been used to provide information on left ventricular (LV) filling and diastolic function. Pulmonary venous flow tracings are an important adjunct to LV inflow pattern in assessing LV diastolic function.

Methods: Fourteen patients with severe aortic regurgitation (8 chronic and 6 acute) and in sinus rhythm were examined by transthoracic and transesophageal pulsed Doppler echocardiography. Mitral and pulmonary flow velocities were recorded and compared. All patients had ejection fractions >40%.

Results: Early mitral flow peak velocity was higher in patients with acute regurgitation ($p < 0.001$). The mitral A wave was absent in five patients with acute regurgitation. In contrast, a prominent reverse atrial pulmonary systolic wave AR was demonstrated in these patients. Peak diastolic velocity of the pulmonary venous flow was greater in patients with acute aortic regurgitation (0.76 ± 0.13) than in patients with chronic aortic regurgitation (0.40 ± 0.09) ($p < 0.001$). Peak systolic velocity did not differ significantly between the two groups. The systolic fraction of pulmonary venous flow in patients with acute aortic regurgitation was lower (0.43 ± 0.05) than that of patients with chronic regurgitation (0.63 ± 0.1) ($p < 0.01$). All patients with acute aortic regurgitation had an S/D ratio <1, while those with chronic regurgitation had an S/D >1 ($p < 0.001$) and an E/A <1.

Conclusion: Patients with severe acute aortic regurgitation showed a retrograde atrial kick (absence of transmitral A wave with prominent pulmonary AR wave). These patients had an S/D ratio <1 (restrictive Doppler pattern). Patients with chronic aortic regurgitation exhibited a Doppler pattern of abnormal LV relaxation (E/A <1, S/D >1).

Key words: aortic regurgitation, diastolic function, echocardiography

Introduction

Mitral flow velocity recordings obtained with pulsed-wave Doppler echocardiography have been used to provide information on left ventricular (LV) filling and diastolic function.¹ Because of the complexity of diastolic function and the similarities of normal and pseudonormal mitral Doppler patterns, more recent studies have analyzed pulmonary vein velocities in conjunction with mitral flow velocities to increase our understanding of LV filling.^{2,3} The purpose of this study was to compare the changes in pulmonary venous and mitral flow velocities during acute and chronic severe aortic regurgitation assessed by transthoracic (TTE) and transesophageal (TEE) echocardiography.

Methods

Patients

The study included 14 patients with severe aortic regurgitation demonstrated by color-Doppler-flow imaging.⁴ There were 10 men and 4 women with a mean age of 49 years (range 27–79). All patients had ejection fractions >40%, and the degree of aortic regurgitation was confirmed in 11 patients by aortography. Three patients with aortic endocarditis did not undergo cardiac catheterization. Eight patients had chronic aortic regurgitation (four with a bicuspid aortic valve, three with a dilated ascending aorta, and one with a rheumatic aortic valve), and six had acute aortic regurgitation (three with aortic

Address for reprints:

Isidre Vilacosta, M.D.
Serrano 46
28001 Madrid, Spain

Received: April 30, 1996

Accepted with revision: August 13, 1996

endocarditis and three with aortic dissection). The use of "acute" in this context means aortic regurgitation of short duration (<15 days) and does not include patients with chronic aortic regurgitation who have decompensated. The patients had neither aortic stenosis nor other valvular disease. There was no clinical history of coronary artery disease and all patients were in sinus rhythm.

Catheterization

Biplane aortic root cineangiography was performed using 40 to 60 ml of angiographic contrast injected through a #8F pigtail catheter positioned immediately above the aortic valve. The amount of aortic regurgitation was graded as severe by the method of Hunt *et al.* in every patient.⁵ Three patients with aortic endocarditis and acute aortic regurgitation did not undergo cardiac catheterization. Left ventricular diastolic pressures were recorded in the 11 patients who underwent cardiac catheterization.

Echocardiography

All patients were examined by pulsed Doppler TTE and TEE. In three patients with aortic dissection and acute aortic regurgitation, the echocardiographic studies were done within 24 h before catheterization. The echocardiographic examination of the eight patients with chronic aortic regurgitation was performed within 4 and 10 days before cardiac catheterization. The echocardiographic studies were performed on a commercially available Toshiba SSH 160 using a 2.5 MHz transducer. A 5 MHz transesophageal monoplane probe was used to obtain pulmonary venous flow velocities. The TEE studies were performed immediately after the TTE studies.

Standard baseline measurements were performed in all patients. Left ventricular end-diastolic and end-systolic diameters and ejection fraction were measured by M-mode echocardiography. In addition, the diameter of the left atrium and the existence of premature closure of the mitral valve were also investigated. Mitral flow velocities were recorded in the four-chamber view, placing the sample volume at the tip of the mitral valve leaflets to obtain the highest velocity. From the velocity tracings, early mitral flow peak velocity (VE), peak velocity of the mitral A wave (VA), E/A ratio, early diastolic velocity integral (TVI-E), and late diastolic velocity integral (TVI-A) were calculated (Fig. 1). Estimation of the severity of aortic regurgitation by color Doppler flow mapping was calculated using jet short-axis area/LV outflow tract short-axis area, measured in the parasternal short-axis view just beneath the aortic valve.⁴ By these criteria, all patients had severe aortic regurgitation (jet short-axis area/LV outflow tract short-axis area $\geq 60\%$).

Pulmonary venous flow velocities were obtained by TEE placing the sample volume 1–2 cm into the left upper pulmonary vein from its junction with the left atrium. The following measurements were taken: the peak velocity of the systolic (VS) and VD flow, peak velocity of the flow reversal during atrial systole (VAR), S/D ratio and time-velocity integral of

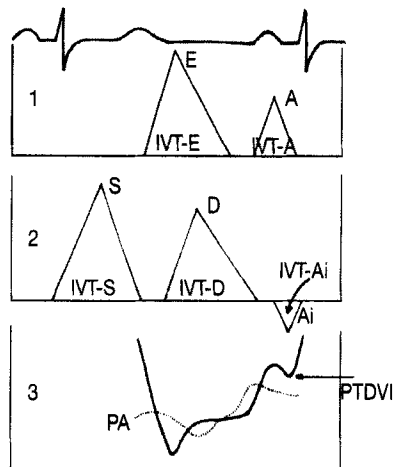


FIG. 1 Diagram showing corresponding pulmonary venous flow velocity (2) with left ventricular inflow velocity (1). The pressure tracing shows the atrial (PA) and ventricular pressure curves in diastole. The left ventricular inflow velocity is composed of a larger (E) diastolic filling velocity and the smaller atrial (A) filling velocity. PTDVI = left ventricular end-diastolic pressure, IVT-E = early diastolic velocity integral, IVT-A = late diastolic velocity integral. Pulmonary venous flow by transesophageal echocardiography is normally composed of a forward systolic (S) and diastolic (D) flow and a small reversal of flow during atrial contraction (Ai). IVT-S = time-velocity integral of forward systolic flow, IVT-D = time-velocity integral of diastolic flow, IVT-Ai = time-velocity integral of retrograde atrial contraction.

forward systolic (TVI-S) and diastolic (TVI-D) flow, and of the retrograde atrial contraction (TVI-AR). In addition, the systolic fraction (SF) (the systolic velocity time integral expressed as a fraction of the sum of systolic and diastolic velocity time integrals) was calculated (Fig. 1). In case of biphasic systolic flow, the maximal velocity was measured on the tallest of the two peaks. In four patients with acute aortic regurgitation, these echocardiographic parameters were repeated after surgery. The velocity and velocity integral measurements were made by measuring the modal velocity (darkest) portion of the spectrum.

Statistical Analysis

Data are expressed as mean \pm standard deviation. Statistical significance was determined by using Student's *t*-test for quantitative variables. A *p* value < 0.05 was considered to be statistically significant.

Results

Catheterization

All 11 patients who underwent cardiac catheterization had severe aortic regurgitation. In three patients with acute aortic regurgitation, the end-diastolic pressure varied from 40 to 55 mmHg (Table I). The eight patients with chronic aortic regur-

TABLE 1 Results of clinical, Doppler, echocardiographic and hemodynamic variables in patients with acute and chronic aortic regurgitation

Patient No.	Age(years)/sex	AR (mm)	LA (mm)	LVd (mm)	LVs (mm)	EF (%)	EDPVI (mmHg)	VE (m/s)	VA (m/s)	E/A ratio	TVI-A (m)	TVI-E (m)	VS (m/s)	VD (m/s)	S/D ratio	VAR (m/s)	TVI-S (m)	TVI-D (m)	TVI-AR (m)	SF (m)
1	76/F	C	36	59	34	73	20	0.35	0.65	0.54	0.05	0.04	0.59	0.39	1.5	-0.19	0.19	0.07	-0.01	0.73
2	68/M	C	48	62	38	63	30	0.52	0.66	0.78	0.08	0.07	0.31	0.36	0.8	-0.10	0.11	0.04	-0.01	0.73
3	44/M	C	49	56	32	75	28	0.48	0.62	0.77	0.05	0.04	0.95	0.64	1.5	-0.37	0.16	0.10	-0.03	0.61
4	42/M	A	46	58	32	80	50	1.12	—	—	—	0.09	0.58	0.74	0.7	-0.77	0.09	0.10	-0.08	0.47
5	52/M	A	45	56	30	86	55	0.69	—	—	—	0.09	0.37	0.87	0.4	-0.43	0.08	0.12	-0.05	0.4
6	27/M	C	37	65	45	44	32	0.48	0.62	0.77	0.07	0.07	0.48	0.35	1.3	-0.12	0.12	0.06	-0.02	0.66
7	33/F	C	45	62	38	63	28	0.32	0.45	0.71	0.08	0.07	0.52	0.40	1.3	-0.20	0.11	0.04	-0.01	0.73
8	29/M	A	38	57	36	58	40	0.80	—	—	—	0.08	0.44	0.75	0.5	-0.40	0.07	0.12	-0.09	0.36
9	40/M	A	42	57	33	72	—	0.92	—	—	—	0.07	0.45	0.97	0.4	-0.48	0.08	0.09	-0.06	0.47
10	42/F	A	37	54	30	80	—	1.10	—	—	—	0.08	0.35	0.62	0.5	-0.48	0.07	0.10	-0.07	0.41
11	57/M	A	39	63	38	65	—	0.80	0.19	4.21	0.01	0.07	0.52	0.65	0.8	-0.50	0.08	0.08	-0.04	0.50
12	52/M	C	53	56	38	47	25	0.40	0.60	0.67	0.06	0.07	0.72	0.37	1.9	-0.22	0.08	0.08	-0.02	0.50
13	70/M	C	55	63	39	61	30	0.28	0.48	0.58	0.06	0.08	0.62	0.38	1.6	-0.08	0.07	0.08	-0.02	0.46
14	55/F	C	48	63	36	75	28	0.36	0.48	0.75	0.08	0.06	0.52	0.38	1.3	-0.12	0.11	0.06	-0.01	0.64

Abbreviations: A = acute, AR = aortic regurgitation, C = chronic, EDPVI = end-diastolic left ventricular pressure, EF = ejection fraction, LA = left atrium, LVd = end-diastolic diameter of the left ventricle, LVs = end-systolic diameter of the left ventricle, TVI-A = time-velocity integral of mitral A wave, TVI-AR = time-velocity integral of retrograde atrial contraction, TVI-D = time-velocity integral of diastolic pulmonary flow, TVI-E = time-velocity integral of early diastolic flow, TVI-S = time-velocity integral of systolic pulmonary flow, VA = peak velocity of late mitral flow, VAR = peak velocity of reverse atrial systolic pulmonary flow, VD = peak velocity of diastolic pulmonary venous flow, VE = peak velocity of early mitral flow, VS = peak velocity of systolic pulmonary venous flow, SF = systolic fraction.

TABLE II Doppler, echocardiographic, and hemodynamic variables in patients with acute and chronic aortic regurgitation

Variable	Chronic AR (n = 8)	Acute AR (n = 6)	p Value
Left atrium (mm)	46 ± 7	42 ± 3	NS
End-diastolic left ventricular diameter (mm)	61 ± 3	57 ± 3	<0.1
End-systolic left ventricular diameter (mm)	37 ± 4	33 ± 4	<0.05
Ejection fraction (%)	62 ± 12	73 ± 10	NS
Peak early mitral diastolic velocity (VE) (m/s)	0.39 ± 0.08	0.9 ± 0.17	<0.001
Peak systolic pulmonary venous flow velocity (VS) (m/s)	0.58 ± 0.18	0.45 ± 0.08	NS
Peak diastolic pulmonary venous flow velocity (VD) (m/s)	0.40 ± 0.09	0.76 ± 0.13	<0.001
S/D ratio	1.4 ± 0.3	0.55 ± 0.16	<0.001
Peak reverse atrial systolic pulmonary flow velocity (VAR) (m/s)	0.175 ± 0.09	0.51 ± 0.13	<0.001
Early diastolic velocity integral (TVI-E) (m)	0.06 ± 0.01	0.08 ± 0.008	<0.05
Time-velocity integral of systolic pulmonary flow (TVI-S) (m)	0.11 ± 0.03	0.078 ± 0.007	<0.05
Time-velocity integral of diastolic pulmonary flow (TVI-D) (m)	0.06 ± 0.02	0.101 ± 0.01	<0.01
Time-velocity integral of retrograde atrial contraction (TVI-AR) (m)	0.016 ± 0.007	0.065 ± 0.018	<0.001
Time-velocity integral of systolic fraction	0.63 ± 0.1	0.33 ± 0.05	<0.01
End-diastolic left ventricular pressure (EDPVI) (mmHg)	27 ± 3	48 ± 7	<0.001

Values are given as mean ± standard deviation.

Abbreviations: NS = not significant, AR = aortic regurgitation.

gitation had a mean end-diastolic pressure of 27 ± 3 mmHg (Table II).

Echocardiography

Echocardiographic data for all patients are presented in Tables I and II. There were no significant differences in the left atrium diameter between patients with acute and chronic regurgitation (Table II). The LV end-systolic diameter was larger in patients with chronic aortic regurgitation (37 ± 4 vs. 33 ± 3 mm; $p < 0.05$). The end-diastolic diameter also had a trend to be larger in patients with chronic aortic regurgitation (61 ± 3 vs. 57 ± 13 mm; $p < 0.1$). The ejection fraction was not significantly different between the two groups (chronic: 62 ± 12; acute: 73 ± 10). The presence of premature closure of the mitral valve was identified in three patients with acute aortic regurgitation (one with endocarditis and two with aortic dissection).

The results of mitral and pulmonary flow Doppler variables are as follows: Mitral flow peak VE was greater in patients with acute (0.9 ± 0.17) than in patients with chronic aortic regurgitation (0.39 ± 0.08) ($p < 0.001$). Nevertheless, an interesting finding of this study was the absence of the mitral A wave in five of six patients with acute aortic regurgitation. The remaining patient had a very low peak velocity of the mitral A wave (0.19 m/s) compared with the A wave of patients with chronic aortic regurgitation (mean: 0.57 m/s) (Table I). In the pulmonary venous flow tracing of these patients (acute aortic regurgitation) there was a large increase of the velocity of flow reversal during atrial systole (VAR), (0.51 ± 0.13 m/s), that was greater than the AR velocity of patients with chronic aortic regurgitation (0.175 ± 0.09) ($p < 0.001$) (Fig. 2). The peak VD of the pulmonary venous flow was greater in patients

with acute aortic regurgitation (0.76 ± 0.13) than in patients with chronic aortic regurgitation (0.40 ± 0.09) ($p < 0.001$). There were no significant differences in peak VS among patients with acute (0.45 ± 0.08) and chronic (0.58 ± 0.18) aortic regurgitation. The systolic time/velocity integral (TVI-S) was larger in patients with chronic aortic regurgitation (0.11 ± 0.03 vs. 0.078 ± 0.007). The systolic fraction of pulmonary venous flow of patients with acute aortic regurgitation was lower (0.43 ± 0.05) than that of patients with chronic aortic regurgitation (0.63 ± 0.1) ($p < 0.01$). The time/velocity integral of diastolic (TVI-D) and reversal (TVI-AR) pulmonary venous flow and of early transmitral flow (TVI-E) were larger in patients with acute aortic regurgitation (Table II).

All patients with acute aortic regurgitation had an S/D < 1 (0.55 ± 0.16) while patients with chronic aortic regurgitation had an S/D > 1 (1.4 ± 0.3) ($p < 0.001$) (Fig. 3). The latter also had an E/A < 1 (0.70).

Discussion

Pulmonary venous flow tracings are an important adjunct to LV inflow velocity patterns in assessing LV diastolic function. In the present study, pulmonary venous flow and mitral inflow velocities of patients with severe aortic regurgitation have been measured. In contrast to chronic aortic regurgitation, in which the left ventricle has had the opportunity to adapt to the increased volume overload in acute aortic regurgitation, the regurgitant volume fills a ventricle of normal volume that cannot accommodate the regurgitant aortic volume and the transmitral flow. This overloaded ventricle operates on the steep portion of its pressure-volume curve and, in consequence, LV diastolic pressure increases dramatically. It is well known that

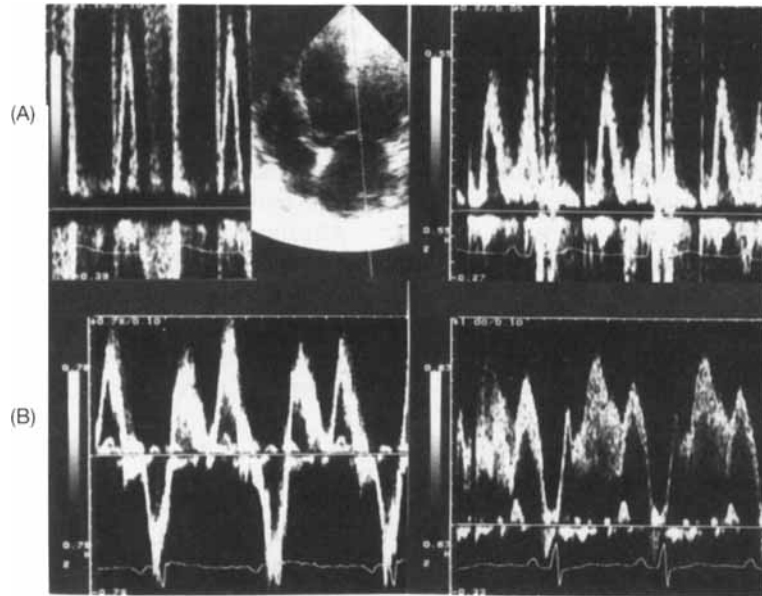


FIG. 2 Pulsed-wave Doppler transthoracic (A) and transesophageal (B) recording before (1) and after (2) surgery in a patient with acute severe aortic regurgitation. Notice the absence of an A wave in the left ventricular inflow velocity recording (1A) and the presence of a large Ai wave in the pulmonary venous flow (1B). After surgery, the left ventricular inflow and pulmonary venous flow patterns become normal (2).

for a similar severe degree of aortic regurgitation and a preserved ejection fraction, the patient with acute regurgitation has a much higher level of end-diastolic pressure than the patient with chronic aortic regurgitation. This characteristic hemodynamic finding of patients with acute aortic regurgitation was present in our patients. The end-diastolic pressure of patients with acute regurgitation was greater (48 ± 7 mmHg) than that of patients with chronic regurgitation (27 ± 3 mmHg) ($p < 0.001$). The most interesting findings of this study are derived from these hemodynamic data.

The diastolic phase of pulmonary venous flow showed a close relationship with the pattern of the early transmitral flow. The peak velocity of the rapid filling wave (VE) correlated well with the peak diastolic velocity of the pulmonary venous flow (VD). This is in agreement with the results of other authors and points out that during early diastole the left atrium is an open conduit between the pulmonary veins and the left ventricle and, therefore, ventricular factors are the main determinants for the E and D waves.⁶ In this study, patients with acute aortic regurgitation had a peak diastolic velocity greater than the peak systolic velocity ($S/D < 1$) in the pulmonary venous flow, while in patients with chronic aortic regurgitation the S/D ratio was > 1 . Kuecherer *et al.* found that the systolic fraction of the pulmonary venous flow correlated very strongly with mean left atrial pressure ($r = -0.88$) and they suggested that a decreased systolic flow pattern may be used as an index of increased mean left atrial pressure (> 15 mmHg).⁷ In this study, neither left atrial pressure nor pulmonary capillary wedge pressure are available. Nevertheless, we can tentatively presume that patients with acute regurgitation have higher left atrial pressure than patients with chronic regurgitation. If this were the truth, our findings

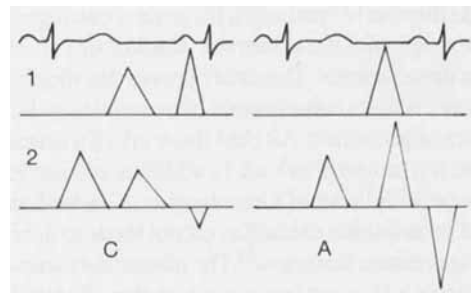


FIG. 3 Doppler patterns of abnormal relaxation (C) and restrictive left ventricular filling (A) in chronic and acute aortic regurgitation, respectively, are shown.

are in accordance with those of Kuecherer *et al.* The systolic fraction of patients with acute regurgitation was lower (0.43 ± 0.05) than that of patients with chronic regurgitation (0.63 ± 0.1) ($p < 0.01$).

The most interesting finding of this study was the different behavior of the atrial systolic wave of mitral and pulmonary venous flow patterns in acute and chronic aortic regurgitation. In normal subjects, atrial contraction produces forward flow across the mitral valve (A wave) as well as a small reverse flow in the pulmonary veins (AR wave). The present study shows that the peak velocity of reverse flow at atrial contraction (AR) of patients with acute aortic regurgitation was greater than that of patients with chronic aortic regurgitation (0.51 ± 0.13 vs. 0.175 ± 0.09) ($p < 0.001$). At the same time, five of six patients with acute aortic regurgitation had no mitral A wave in the Doppler pattern of the LV inflow. On the con-

trary, all patients with chronic aortic regurgitation had a high peak velocity of the mitral A wave (mean: 0.57 m/s). In our opinion, the absence of any forward mitral inflow A wave with a prominent atrial reversal flow in acute regurgitation is probably related to the high end-diastolic pressures of these patients.⁸ Matsuda *et al.* demonstrated that at the same time LV pressure increased, the atrial pressure curve became biphasic.⁹ The first wave resulted from left atrial contraction, and the second wave was the reflection from the ventricle back to the left atrium. The transmitral Doppler A wave is due to a positive atrioventricular pressure gradient created by the first atrial pressure peak. In patients with low end-diastolic pressures, the maximal atrial pressure occurs during this phase. On the other hand, if the end-diastolic pressure is very high (as occurs in acute aortic regurgitation), there is no positive atrioventricular pressure gradient (no mitral A wave) and the amplitude of the second atrial systolic wave becomes greater than that of the first wave. This second peak occurs at the time of maximal ventricular A wave pressure and it will be responsible for the reverse atrial pulmonary venous flow (AR).⁹

This indicates that peak velocity of reverse flow at atrial contraction is most dependent on left atrial afterload (state of ventricular rigidity and changes of end-diastolic pressure).⁸ The absence of the mitral A wave in the transmitral Doppler pattern (absence of flow from the left atrium to the left ventricle in late diastole) of patients with acute aortic regurgitation correlates well with the systematic absence of a fourth heart sound in these patients. This study proves that the absent mitral A wave is not a consequence of an atrial systolic failure (existence of prominent AR) but the result of a dramatically increased left atrium afterload. In addition, our results are in accordance with those of Greenberg *et al.*, who found that the atrial contribution to cardiac output tends to diminish as LV filling pressure increases.¹⁰ The present data show that in most patients with acute aortic regurgitation, the atrial contribution in increasing stroke volume is null. In patients with chronic aortic regurgitation a fourth heart sound is frequently present. The fact that most patients with chronic regurgitation had an E/A ratio < 1 (abnormal LV relaxation pattern) agrees with this statement. Despite the present results, not every patient with chronic aortic regurgitation will have an E/A ratio < 1; in chronic decompensated aortic regurgitation, impaired LV emptying produces an increase in end-systolic volume, a fall in ejection fraction, and elevation of LV filling pressure. This will result in an increase of the E wave and a decrease of the A wave. Therefore, it should be pointed out that the restrictive pattern (seen with acute aortic regurgitation) can be detected in other conditions.

Conclusion

A characteristic of the left ventricle of patients with acute aortic regurgitation is nonadaptation to the increased load, resulting in an elevation of LV diastolic pressure, causing a retrograde atrial kick (absence of the transmitral Doppler A wave with prominent reverse pulmonary AR wave).

All patients with acute aortic regurgitation had an S/D ratio < 1 (restrictive LV filling pattern). The left ventricle of patients with chronic aortic regurgitation has had time to accommodate the volume load, and if ventricular emptying remains normal, a Doppler pattern of abnormal LV relaxation (E/A < 1, S/D > 1) can be seen (Fig. 3).

References

1. Appleton CP, Hatle LK, Popp RL: Relations of transmitral flow velocity patterns to left ventricular diastolic function: New insights from a combined hemodynamic and Doppler echocardiographic study. *J Am Coll Cardiol* 1988;12:426-440
2. Klein AL, Hatle LK, Burstow DJ, Seward JB, Kyle RA, Bailey KR, Luscher TF, Gertz MA, Tajik AJ: Doppler characterization of left ventricular diastolic function in cardiac amyloidosis. *J Am Coll Cardiol* 1989;13:1017-1026
3. Klein AL, Tajik AJ: Doppler assessment of pulmonary venous flow in healthy subjects and in patients with heart disease. *J Am Soc Echocardiogr* 1991;4:379-393
4. Perry GJ, Helmcke F, Nanda NC, Byard C, Soto B: Evaluation of aortic insufficiency by Doppler color flow mapping. *J Am Coll Cardiol* 1987;9:952-959
5. Hunt D, Baxley WA, Kennedy JW, Judge TP, Williams JE, Dodge HT: Quantitative evaluation of cineangiography in the assessment of aortic regurgitation. *Am J Cardiol* 1973;31:696-700
6. Nishimura RA, Abel MD, Hatle LK, Tajik AJ: Relation of pulmonary vein to mitral flow velocities by transesophageal Doppler echocardiography. Effect of different loading conditions. *Circulation* 1990;81:1488-1497
7. Kuecherer HF, Muhiudeen IA, Kusumoto FM, Lee M, Moulinier LE, Cahalan MK, Schiller NB: Estimation of mean left atrial pressure from transesophageal pulsed Doppler echocardiography of pulmonary venous flow. *Circulation* 1990;82:1127-1139
8. Rossvoll O, Hatle LK: Pulmonary venous flow velocities recorded by transthoracic Doppler ultrasound: Relation to left ventricular diastolic pressures. *J Am Coll Cardiol* 1993;21:1687-1696
9. Matsuda Y, Toma Y, Matsuzaki M, Moritani K, Satoh A, Shioni K, Ohtani N, Kohno M, Fujii T, Katayama K, Matsuda M, Kusukawa R: Change of left atrial systolic pressure waveform in relation to left ventricular end-diastolic pressure. *Circulation* 1990;82:1659-1667
10. Greenberg B, Chatterjee K, Parmley WW, Werner JA, Holly AN: The influence of left ventricular filling pressure on atrial contribution to cardiac output. *Am Heart J* 1979;98:742-751