

Images in Cardiology

This section edited by Edward A. Geiser, M.D.

Aortic Saddle Embolism

JONG-WON HA, M.D., PH. D., NAMSIK CHUNG, M.D., PH. D., BYUNG-CHUL CHANG, M.D., PH. D.,* DO-YUN LEE, M.D.,†
SEUNG-YUN CHO, M.D., PH. D.

Cardiology Division, *Division of Cardiovascular Surgery, Cardiovascular Center, †Department of Diagnostic Radiology, Yonsei University, College of Medicine, Seoul, Korea

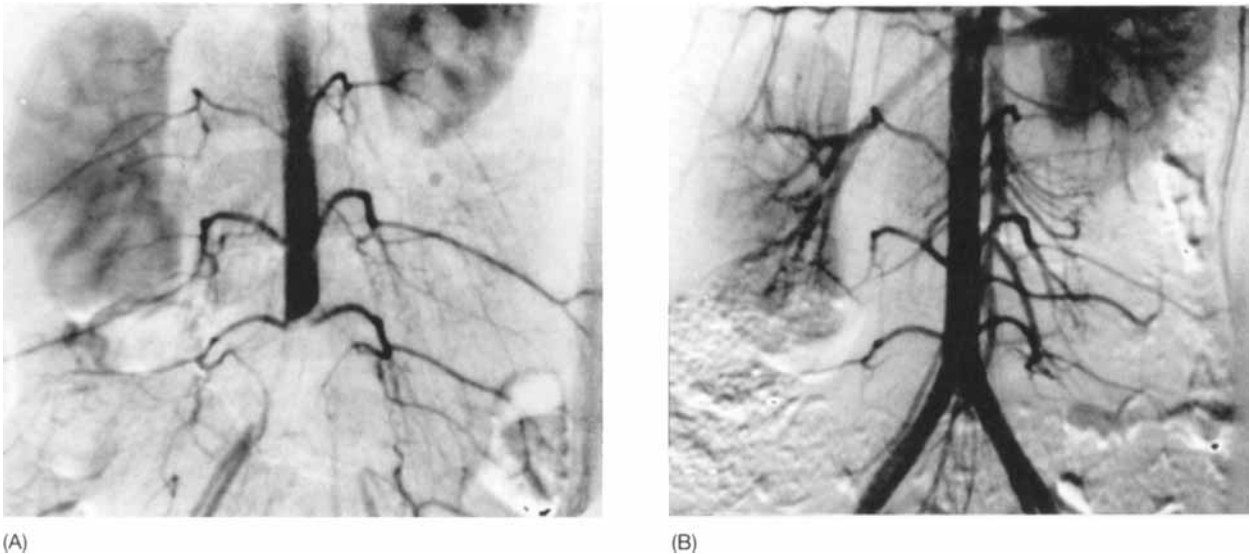


FIG. 1 Digital subtraction angiography: (A) Pre-embolectomy image shows total occlusion of the distal abdominal aorta. (B) Postembolectomy image revealed both common iliac arteries to be patent with good distal flow.

Address for reprints:

Jong-Won Ha, M.D., Ph.D.
Cardiology Division
Cardiovascular Center
Yonsei University College of Medicine
C.P.O Box 8044
Seoul, Korea

Received: July 1, 1998

Accepted with revision: July 27, 1998

A 22-year-old woman presented with left leg pain for one day. She had been diagnosed with peripartum cardiomyopathy one year previously. She also had a history of a transient ischemic attack one year previously. Physical examination revealed an acutely ill-appearing patient with a loss of both femoral artery pulses and tenderness in the left lower extremity. Immediate digital subtraction angiography of the abdominal aorta revealed total occlusion of the distal abdominal aorta (Fig. 1A). Emergent Fogarty embolectomy was performed. Digital subtraction angiography after embolectomy showed both common iliac arteries to be patent (Fig. 1B). Transthoracic echocardiography was performed to search for a cardiac source of embolism and revealed an enlarged left ventricle

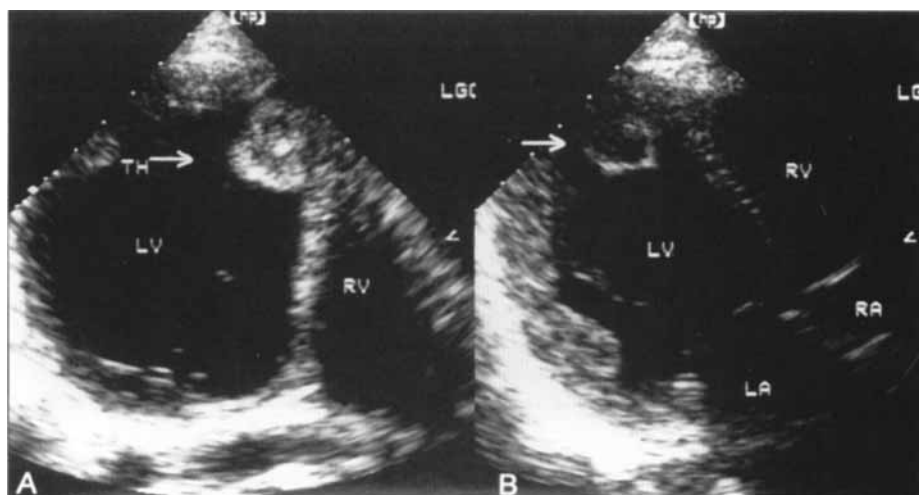


FIG. 2 Transthoracic echocardiography: (A) Apical four-chamber view shows a large, round echogenic mass attached at the apical septum, suggestive of thrombus (arrow). (B) A modified apical four-chamber view reveals a similar finding. LA = left atrium, LV = left ventricle, RA = right atrium, RV = right ventricle.

with depressed global systolic function and a large thrombus at the left ventricular apex (Fig. 2, arrow). Anticoagulation was continued and the patient was discharged several days later without further event.

Reference

Stratton JR, Lighty GW, Pearlman AS, Ritchie JL: Detection of left ventricular thrombus by two-dimensional echocardiography: Sensitivity, specificity, and causes of uncertainty. *Circulation* 1982;66:156-166