

Non-*albicans* *Candida* prosthetic joint infections: A systematic review of treatment

Christos Koutserimpas, Stylianos G Zervakis, Sofia Maraki, Kalliopi Alpantaki, Argyrios Ioannidis, Diamantis P Kofteridis, George Samonis

ORCID number: Christos Koutserimpas (0000-0002-1398-9626); Stylianos G Zervakis (0000-0002-8785-3780); Sofia Maraki (0000-0002-8553-0849); Kalliopi Alpantaki (0000-0003-0185-8474); Argyrios Ioannidis (0000-0003-0230-5302); Diamantis P Kofteridis (0000-0001-7603-2592); George Samonis (0000-0001-5857-9703).

Author contributions:

Koutserimpas C, Zervakis SG, Alpantaki K and Samonis G designed the research; Zervakis SG, Maraki S and Kofteridis DP performed the research; Koutserimpas C and Ioannidis A contributed new reagents/analytic tools; Koutserimpas C and Ioannidis A analyzed the data; Koutserimpas C, Zervakis SG, Alpantaki K and Samonis G wrote the paper.

Conflict-of-interest statement: The authors declare no conflict of interest.

PRISMA 2009 Checklist statement: PRISMA 2009 Checklist statement is provided.

Open-Access: This article is an open-access article that was selected by an in-house editor and fully peer-reviewed by external reviewers. It is distributed in accordance with the Creative Commons Attribution Non Commercial (CC BY-NC 4.0) license, which permits others to distribute, remix, adapt, build upon this work non-commercially, and license their derivative works on different terms, provided the

Christos Koutserimpas, Department of Orthopaedics and Traumatology, "251" Hellenic Air Force General Hospital of Athens, Athens 11525, Greece

Stylianos G Zervakis, Diamantis P Kofteridis, George Samonis, Department of Internal Medicine, University Hospital of Heraklion, Crete, Heraklion 71110, Greece

Sofia Maraki, Department of Clinical Microbiology and Microbial Pathogenesis, University Hospital of Heraklion, Crete, Heraklion 71110, Greece

Kalliopi Alpantaki, Department of Materials Science and Technology, University of Crete, Heraklion, Heraklion 71110, Greece

Argyrios Ioannidis, Department of General Surgery, "Sismanoglion" General Hospital of Athens, Athens 15126, Greece

Corresponding author: Christos Koutserimpas, MD, Doctor, Department of Orthopaedics and Traumatology, "251" Hellenic Air Force General Hospital of Athens, P. Kanellopoulou Av., Athens 11525, Greece. chrisku91@hotmail.com

Telephone: +30-694-8712130

Abstract

BACKGROUND

Non-*albicans Candida* prosthetic joint infections (PJIs) are rare. Optimal treatment involves a two-stage revision surgery in combination with an antifungal agent. However, no clear guidelines have been developed regarding the agent or treatment duration. Hence, a broad range of antifungal and surgical treatments have been reported so far.

AIM

To clarify treatment of non-*albicans Candida* PJIs.

METHODS

A literature review of all existing non-*albicans Candida* PJIs cases through April 2018 was conducted. Information was extracted about demographics, comorbidities, responsible species, duration and type of antifungal treatment, type of surgical treatment, time between initial arthroplasty and symptom onset, time between symptom onset and definite diagnosis, outcome of the infection and follow-up.

RESULTS

A total of 83 cases, with a mean age of 66.3 years, were located. The causative

original work is properly cited and the use is non-commercial. See: <http://creativecommons.org/licenses/by-nc/4.0/>

Manuscript source: Invited manuscript

Received: January 22, 2019

Peer-review started: January 23, 2019

First decision: March 10, 2019

Revised: March 16, 2019

Accepted: April 19, 2019

Article in press: April 19, 2019

Published online: June 26, 2019

P-Reviewer: Li J

S-Editor: Ji FF

L-Editor: Filipodia

E-Editor: Xing YX



yeast isolated in most cases was *C. parapsilosis* (45 cases; 54.2%), followed by *C. glabrata* (18 cases; 21.7%). The mean Charlson comorbidity index was 4.4 ± 1.5 . The mean time from arthroplasty to symptom onset was 27.2 ± 43 mo, while the mean time from symptom onset to culture-confirmed diagnosis was 7.5 ± 12.5 mo. A two stage revision arthroplasty (TSRA), when compared to one stage revision arthroplasty, had a higher success rate (96% vs 73%, $P = 0.023$). Fluconazole was the preferred antifungal agent (59; 71%), followed by amphotericin B (41; 49.4%).

CONCLUSION

The combination of TSRA and administration of prolonged antifungal therapy after initial resection arthroplasty is suggested on the basis of limited data.

Key words: Fungal prosthetic joint infection; Knee arthroplasty infection; Hip arthroplasty infection; Antifungal treatment; Non-*albicans* *Candida* prosthetic joint infections

©The Author(s) 2019. Published by Baishideng Publishing Group Inc. All rights reserved.

Core tip: Non-*albicans* *Candida* prosthetic joint infections (PJIs) are rare, and no clear guidelines exist regarding the treatment of these infections. The purpose of this study was to clarify, by reviewing current published cases, the treatment options of non-*albicans* *Candida* PJIs and, possibly, to improve the medical and surgical care of such cases. A literature review of all existing non-*albicans* *Candida* PJIs cases through April 2018 was conducted. The combination of two stage revision arthroplasty and administration of prolonged antifungal therapy after initial resection arthroplasty is suggested on the basis of limited data.

Citation: Koutserimpas C, Zervakis SG, Maraki S, Alpantaki K, Ioannidis A, Kofteridis DP, Samonis G. Non-*albicans* *Candida* prosthetic joint infections: A systematic review of treatment. *World J Clin Cases* 2019; 7(12): 1430-1443

URL: <https://www.wjgnet.com/2307-8960/full/v7/i12/1430.htm>

DOI: <https://dx.doi.org/10.12998/wjcc.v7.i12.1430>

INTRODUCTION

Prosthetic joint infection (PJI) is a severe complication of joint surgery, involving the joint prostheses and contiguous tissue, representing a main cause of total arthroplasty failure^[1]. A plethora of microorganisms have been held responsible for these infections, such as Gram-positive and negative bacteria, while fungal microorganisms are considered rare causes. Fungal PJIs occur in about 1-2% of all cases, while the most common spread type seems to be hematogenous^[2].

Optimal treatment is considered the two stage revision surgery in combination with an antifungal agent. However, no clear guidelines have yet been developed regarding the agent and treatment duration. Hence, a broad range of antifungal and surgical treatments have been reported so far^[3,4].

Candida spp represent the most common fungal pathogens for PJIs, with *Candida albicans* being the most prevalent species. However, over the last years, the incidence of non-*albicans* *Candida* PJIs has increased^[4,5]. The purpose of this study was to clarify, by reviewing current published cases, the treatment options of non-*albicans* *Candida* PJIs in order to potentially improve the medical and surgical care of such cases.

MATERIALS AND METHODS

A search of PubMed and MEDLINE databases was performed to identify all existing articles reporting the management of non-*albicans* *Candida* PJIs cases through April 2018. Isolated and combined terms of "fungal prosthetic joint infection", "fungal arthroplasty infection", "fungal hip arthroplasty infection", "fungal knee arthroplasty infection", "fungal shoulder arthroplasty infection", as well as terms including each non-*albicans* *Candida* species (e.g., "*candida glabrata* joint infection", "*candida parapsilosis* joint infection, etc) were used. The citations in each article were reviewed to locate

additional references that were not retrieved during the initial search.

The present review is limited to papers published in English, peer-reviewed journals. Furthermore, cases without information about management and treatment were excluded. The data extracted from these studies included age, gender, affected joint, responsible non-*albicans* *Candida* species, duration and type of antifungal treatment, type of surgical treatment, time between initial arthroplasty and symptom onset, time between symptom onset and definite diagnosis (culture), outcome of the infection and follow-up of each case. Charlson Comorbidity score was calculated, when possible, by two independent investigators based on the information provided from each report.

Data were recorded and analyzed using Microsoft Excel 2010 (Microsoft Corporation, Redmond, Washington). Two-sided Fisher's exact tests were used to compare success rates between groups. Statistical analyses were carried out at the 5% level of significance.

RESULTS

Table 1 highlights the findings from the electronic search, covering a 39 year period ending in 2018. A total of 83 non-*albicans* *Candida* PJIs were identified^[4,6-47]. A total of 46 cases (55.4%) were female patients, thirty-six male (43.4%), while in one case the gender was not clarified. The mean age of the study population was 66.3 years [standard deviation (SD) = 10.2]. The affected joint was the knee in 52 cases (62.6%), the hip in 29 (35%) and the shoulder in two (2.4%). Two of the knee prosthetic joint cases were bilateral. The mean Charlson comorbidity index of patients was 4.4 (SD = 1.5).

The mean time from initial arthroplasty implantation surgery to symptom onset was 27.2 mo (SD = 43), while the mean time from symptom onset to culture-confirmed diagnosis was 7.5 mo (SD = 12.5). Regarding the causative non-*albicans* *Candida* species, the most frequently isolated one was *C. parapsilosis*, found in 45 cases (54.2%), followed by *C. glabrata* in 18 (21.7%), *C. tropicalis* in ten (12%), *C. pelliculosa* in three (3.6%) and *C. lusitanae* in two (2.4%), while *C. famata*, *C. lipolytica*, *C. utilis*, *C. guilliermondii* and *C. freyschussii* had caused one case each (1.2%) (**Figure 1**).

Regarding surgical treatment, in the majority of the described cases (44 cases; 53%) a two stage revision arthroplasty (TSRA) was performed, followed by resection arthroplasty (RA) (18 cases; 22%), one stage revision arthroplasty (OSRA) (eight cases; 9.6%), arthrodesis (five cases; 6%), debridement (three cases; 3.6%) and amputation (two cases; 2.4%). In three cases (3.6%), there was no surgical treatment (**Figure 2**). TSRA exhibited a success rate of 96%, RA a rate of $\geq 61\%$ [in 7 cases information about the infection outcome was not provided (studies 8, 31, 32, 46, 60, 62, 66 in **Table 1**)], OSRA a rate of 73%, debridement a rate of 75%, amputation a rate of 100%, while no surgical treatment has shown a success rate of 60%. TSRA when compared to OSRA had a higher success rate (96% vs 73%; P -value = 0.023).

Regarding the preferred antifungal agent, 38 cases (45.8%) were treated with a single drug, 29 (34.9%) with two, 12 (14.5%) with more than two, while one case did not receive antifungal treatment [(1.2%); case 17 in **Table 1**; the antifungal agent was not reported in case 32].

Fluconazole was used in most cases [59; (71%), in 31 of them (52.5%) as monotherapy], followed by amphotericin B [41; (49.4%), in 4 (9.8%) as monotherapy], flucytosine [13; (15.7%), in 1 (7.7%) as monotherapy], caspofungin [7; (8.4%), in 1 (14.3%) as monotherapy], voriconazole [7; (8.4%), in 2 (28.6%) as monotherapy], ketoconazole [5; (6%), none as monotherapy], itraconazole [3; (3.6%), none as monotherapy] and anidulafungin [1; (1.2%), not as monotherapy]. The final outcome was successful in 74 cases (89.2%).

The majority of patients with *C. parapsilosis* PJIs were treated with fluconazole [30 cases; (66.7%), in 22 (73.3%) as monotherapy], followed by amphotericin B [19; (42.2%), none as monotherapy], flucytosine [8; (17.8%), in 1 (12.5%) as monotherapy], ketoconazole [3; (6.7%), none as monotherapy], while voriconazole and itraconazole were used in 1 case each (none as monotherapy). Outcome was successful in 40 cases (88.9%).

The majority of cases with *C. glabrata* PJIs were treated with amphotericin B [8; (44.4%), in 1 (12.5%) as monotherapy], followed by fluconazole [7; (38.9%), in 3 (42.9%) as monotherapy]. Caspofungin and voriconazole were used in 5 cases (27.8%) each, in 1 (20%) case each as monotherapy. Furthermore, three (16.7%) patients received flucytosine (none as monotherapy), two (11.1%) itraconazole (none as monotherapy) and one (5.6%) anidulafungin (not as monotherapy). Outcome was successful in 17 cases (94.4%), while one patient (case number 11 in **Table 1**) passed

Table 1 Non-albicans Candida prosthetic joint infection cases

Ref.	Year	Fungus	Gender	Age	Joint	Char- lson comor- bidity index	Anti- fungal treat- ment	Surgical treat- ment	Treat- ment duration	Out- come	Follow- up in mo	Time from implan- tation to symp- toms onset in mo	Time from symp- toms onset to definite diagno- sis by culture, in mo
Koutserimpas et al ^[6]	2018	<i>C. glabrata</i>	Female	68	Knee	4	Anidulafungin / Voriconazole	TSRA	28 wk	Successful	-	180	0.5
Geng et al ^[7]	2016	<i>C. glabrata</i>	Male	78	Hip	4	Fluconazole / Amphotericin B / Caspofungin	Spacer implantation (failure)/ RA	26 wk	Successful	-	11	34.8
Klatte et al ^[8]	2014	<i>C. glabrata</i>	Female	81	Hip	4	Flucytosine / Amphotericin B / Fluconazole	OSRA	-	Successful	-	8	-
Zhu et al ^[9]	2014	<i>C. glabrata</i>	Male	44	Hip	-	Amphotericin B / Voriconazole	No	6 wk	Successful	3	-	5
Anagnostakos et al ^[10]	2012	<i>C. glabrata</i>	Female	51	Hip	6	Fluconazole	TSRA	6 wk	Successful	70	-	-
Anagnostakos et al ^[10]	2012	<i>C. glabrata</i>	Male	78	Hip	6	Fluconazole	TSRA	6 wk	Successful	15	-	-
Bartalesi et al ^[11]	2012	<i>C. glabrata</i>	Female	60	Hip	-	Voriconazole / Caspofungin + Amphotericin B	TSRA	6 wk	Successful	48	-	-
Hall et al ^[12]	2012	<i>C. glabrata</i>	Female	60	Hip	4	Caspofungin	RA	6 wk	-	-	< 0.5	0.2
Duval et al ^[13]	2008	<i>C. glabrata</i>	-	72	Knee	5	Caspofungin + Flucytosine / Fluconazole + Flucytosine	Arthrodesis	16 wk	Successful	15	-	-
Lejko-Zupanc et al ^[14]	2005	<i>C. glabrata</i>	Male	74	Hip	5	Amphotericin B + Fluconazole / Caspofungin	RA	→ 3 wk	Successful	36	72	-
Fabry et al ^[15]	2005	<i>C. glabrata</i>	Female	74	Knee	6	Voriconazole	2x Debridement	32 wk	Death from unrelated causes while on therapy	24	72	-
Gaston et al ^[16]	2004	<i>C. glabrata</i>	Female	42	Knee	4	Voriconazole / Amphotericin B	Amputation (above knee)	8 wk	Successful	6	264	-

Açikgöz <i>et al</i> ^[17]	2002	<i>C. glabrata</i>	Female	70	Knee	-	Fluconazole	Arthrodesis	-	Successful	7.5	9	6
Ramamo-han <i>et al</i> ^[18]	2001	<i>C. glabrata</i>	Female	65	Hip	-	Amphotericin B + Flucytosine	TSRA	7 wk	Successful	24	48	-
Selmon <i>et al</i> ^[19]	1998	<i>C. glabrata</i>	Female	75	Knee	5	Amphotericin B/Itracozazole + Fluconazole	OSRA	> 8 wk	Successful	48	84	-
Nayeri <i>et al</i> ^[20]	1997	<i>C. glabrata</i>	Female	62	Hip	4	Amphotericin B+ Flucytosine / Itracozazole + Flucytosine	OSRA	11 wk	Successful	22	60	-
Darouiche <i>et al</i> ^[21]	1989	<i>C. glabrata</i>	Female	69	Hip	-	Amphotericin B	RA	1 wk	Successful	-	27	0.5
Goodman <i>et al</i> ^[22]	1983	<i>C. glabrata</i>	Female	69	Hip	3	-	RA	-	Successful	12	27	-
Geng <i>et al</i> ^[7]	2016	<i>C. parapsilosis</i>	Male	67	Knee	3	Fluconazole	TSRA	10 wk	Successful	48	3	-
Wang <i>et al</i> ^[23]	2015	<i>C. parapsilosis</i>	Female	67	Knee	4	Fluconazole	TSRA	10 wk	Successful	27	-	-
Wang <i>et al</i> ^[23]	2015	<i>C. parapsilosis</i>	Male	74	Knee	5	Fluconazole	TSRA	8 wk	Successful	30	-	-
Wang <i>et al</i> ^[23]	2015	<i>C. parapsilosis</i>	Female	71	Knee	4	Fluconazole	TSRA	6 wk	Successful	62	-	-
Klatte <i>et al</i> ^[8]	2014	<i>C. parapsilosis</i>	Male	69	Knee	8	Flucytosine+ Amphotericin. B	OSRAx3 (Failure the first 2 times)	-	Successful	19	1	-
Klatte <i>et al</i> ^[8]	2014	<i>C. parapsilosis</i>	Female	82	Knee	4	Flucytosine+ Amphotericin. B	OSRA	-	Successful	-	2	-
Klatte <i>et al</i> ^[8]	2014	<i>C. parapsilosis</i>	Male	46	Knee	1	Flucytosine+ Amphotericin. B	OSRA	-	Successful	-	6	-
Ueng <i>et al</i> ^[24]	2013	<i>C. parapsilosis</i>	Male	62	Knee	4	Fluconazole	TSRA	-	Successful	≥ 24	4.5	1.5
Ueng <i>et al</i> ^[24]	2013	<i>C. parapsilosis</i>	Male	77	Knee	-	Fluconazole	TSRA	-	Successful	≥ 24	4	3
Ueng <i>et al</i> ^[24]	2013	<i>C. parapsilosis</i>	Male	66	Hip	-	Fluconazole	TSRA	-	Successful	≥ 24	2	1
Ueng <i>et al</i> ^[24]	2013	<i>C. parapsilosis</i>	Male	76	Knee	8	Fluconazole	TSRA	-	Successful	≥ 24	33	2
Ueng <i>et al</i> ^[24]	2013	<i>C. parapsilosis</i>	Male	36	Knee	-	Fluconazole	TSRA	-	Successful	≥ 24	74	2
Ueng <i>et al</i> ^[24]	2013	<i>C. parapsilosis</i>	Male	66	Hip	4	Fluconazole	RA	-	-	-	2	2
Kuiper <i>et al</i> ^[25]	2013	<i>C. parapsilosis</i>	Male	58	Hip	-	None	RA/refused further treatment	-	Refused further treatment	8	-	-
Chiu <i>et al</i> ^[26]	2013	<i>C. parapsilosis</i>	Male	71	Hip	5	Fluconazole	RA	40 wk	Successful	24	48	-
Hwang <i>et al</i> ^[4]	2012	<i>C. parapsilosis</i>	Female	71	Knee	-	Amphotericin B / Fluconazole	TSRA	≥ 6 wk	Successful	46	-	-

Hwang et al ^[4]	2012	<i>C. parapsilosis</i>	Female	76	Knee	-	Amphotericin B / Fluconazole	TSRA	≥ 6 wk	Successful	56	-	-
Hwang et al ^[4]	2012	<i>C. parapsilosis</i>	Female	76	Knee	-	Amphotericin B / Fluconazole	TSRA	≥ 6 wk	Successful	67	-	-
Hwang et al ^[4]	2012	<i>C. parapsilosis</i>	Female	72	Knee	-	Fluconazole	TSRA	≥ 6 wk	Successful	73	-	-
Hwang et al ^[4]	2012	<i>C. parapsilosis</i>	Female ¹	61 ¹	Bilateral Knee	-	Amphotericin B / Fluconazole	TSRA	≥ 6 wk	Successful	65	-	-
Hwang et al ^[4]	2012	<i>C. parapsilosis</i>	Female ¹	61 ¹	Bilateral Knee	-	Amphotericin B / Fluconazole	TSRA	≥ 6 wk	Successful	46	-	-
Hwang et al ^[4]	2012	<i>C. parapsilosis</i>	Female	67	Knee	-	Amphotericin B / Fluconazole	TSRA	≥ 6 wk	Successful	65	-	-
Hwang et al ^[4]	2012	<i>C. parapsilosis</i>	Female	68	Knee	-	Fluconazole,	TSRA	≥ 6 wk	Successful	69	-	-
Hwang et al ^[4]	2012	<i>C. parapsilosis</i>	Female	68	Knee	-	Fluconazole,	TSRA	≥ 6 wk	Successful	42	-	-
Hwang et al ^[4]	2012	<i>C. parapsilosis</i>	Female	67	Knee	-	Amphotericin B / Fluconazole	TSRA	≥ 6 wk	Successful	49	-	-
Hwang et al ^[4]	2012	<i>C. parapsilosis</i>	Female	60	Knee	-	Amphotericin B / Fluconazole	TSRA	≥ 6 wk	Successful	41	-	-
Hwang et al ^[4]	2012	<i>C. parapsilosis</i>	Female	73	Knee	-	Amphotericin B / Fluconazole	TSRA	≥ 6 wk	Successful	52	-	-
Anagnostakos et al ^[10]	2012	<i>C. parapsilosis</i>	Male	67	Knee	-	Fluconazole	RA	6 wk	-	-	-	-
Dutronic et al ^[27]	2010	<i>C. parapsilosis</i>	Male	66	Hip	5	Fluconazole	TSRA	24 wk	Successful	-	0	-
Dutronic et al ^[27]	2010	<i>C. parapsilosis</i>	Female	77	Hip	4	Amphotericin B + fluorocytosine / Fluconazole	RA	38 wk	Successful	-	5	-
Antony et al ^[28]	2008	<i>C. parapsilosis</i>	Female	67	Shoulder	3	Voriconazole / Fluconazole	TSRA	-	Successful	6	-	-
Antony et al ^[28]	2008	<i>C. parapsilosis</i>	Female	67	Hip	3	Fluconazole	TSRA	-	Successful	-	-	-
Yang et al ^[29]	2001	<i>C. parapsilosis</i>	Female	68	Knee	3	Fluconazole	TSRA	10 wk	Successful	48	0	16
Bruce et al ^[30]	2001	<i>C. parapsilosis</i>	Female	51	Hip	-	Fluconazole	TSRA	-	Successful	84	36	36
Brooks ^[3]	1998	<i>C. parapsilosis</i>	Male	64	Knee	5	Amphotericin B/Fluconazole	Debridement	28 wk	Successful	24	15	4
Wada et al ^[32]	1998	<i>C. parapsilosis</i>	Male	77	Knee	4	Fluconazole	Debridement	28 wk	Successful	36	0.5	0.5
Cushing et al ^[33]	1997	<i>C. parapsilosis</i>	Female	73	Knee	-	Fluconazole	No	> 24 wk	Successful	12	1	-
Fukasawa et al ^[34]	1997	<i>C. parapsilosis</i>	Female	80	Knee	-	Fluconazole	Debridement	53 wk	Successful	24	-	2

White et al ^[35]	1995	<i>C. parapsilosis</i>	Female	64	Knee	-	Fluconazole/Amphotericin B / Itracozazole	RA	20 wk	Successful	-	0	9
Tunkel et al ^[36]	1993	<i>C. parapsilosis</i>	Male	37	Knee	6	Amphotericin B / Ketocozazole / Fluconazole	TSRA (Failure) / Amputation (Successful)	-	Successful	7	4	0
Paul et al ^[37]	1992	<i>C. parapsilosis</i>	Male	63	Knee	-	Amphotericin + fluorocytosine / ketocozazole	Arthrodesis	9 wk	Successful	24	3	4
Lim et al ^[38]	1986	<i>C. parapsilosis</i>	Male	35	Knee	-	Fluorocytosine	Arthrodesis	-	-	-	0	6
Younkin et al ^[39]	1984	<i>C. parapsilosis</i>	Female	75	Hip	-	Fluorocytosine+ Amphotericin B	TSRA	6 wk	Successful	24	0	60
Lichtman ^[40]	1983	<i>C. parapsilosis</i>	Male	59	Shoulder	-	Amphotericin B / ketocozazole	RA	Indefinite (> 58 d)	-	-	20	9
MacGregor et al ^[41]	1979	<i>C. parapsilosis</i>	Male	64	Knee	-	Amphotericin B + Fluorocytosine	Non-surgical (failure)/ then RA	21 wk	Successful	12	27	5
Sebastian et al ^[42]	2017	<i>C. tropicalis</i>	Male	53	Hip	3	Fluconazole	TSRA	28 wk	Successful	NR	24	0
Reddy et al ^[43]	2013	<i>C. tropicalis</i>	Female	62	Knee	3	Fluconazole	TSRA	30 wk	Successful	24	22.5	1.5
Ueng et al ^[24]	2013	<i>C. tropicalis</i>	Male	67	Hip	-	Fluconazole	RA	-	-	-	15	1
Lidder et al ^[44]	2013	<i>C. tropicalis</i>	Female	76	Hip	-	Amphotericin B	RA	24 wk	Successful	24	36	15
Azam et al ^[45]	2008	<i>C. tropicalis</i>	Male	73	Hip	6	Caspofungin / Fluconazole	TSRA	≥ 9 wk, (Caspofungin 1 wk, fluconazole ≥ 8 wk)	Successful	12	108	-
Wyman et al ^[46]	2002	<i>C. tropicalis</i>	Male	62	Knee	-	Fluconazole / Amphotericin B	TSRA	18 wk	Successful	36	0.25	6
Darouiche et al ^[21]	1989	<i>C. tropicalis</i>	Male	72	Hip	4	Amphotericin B / ketocozazole	Debridement (failure)/ RA	12 wk	Successful	36	0.5	1
Lambertus et al ^[47]	1988	<i>C. tropicalis</i>	Male	61	Hip	3	Amphotericin B	RA	-	Successful	24	6	6
Lambertus et al ^[47]	1988	<i>C. tropicalis</i>	Male	65	Hip	-	Amphotericin B / ketocozazole	RA/ arthrodesis	>24 wk	Successful	14	4	4
73.Goodman et al ^[30]	1983	<i>C. tropicalis</i>	Female	59	Knee	-	Amphotericin B	TSRA (failure)/ RA	6 wk	Successful	12	3	6
Hwang et al ^[41]	2012	<i>C. pelliculosa</i>	Female	67	Knee	-	Fluconazole	TSRA	≥ 6 wk	Successful	56	-	-
Hwang et al ^[41]	2012	<i>C. pelliculosa</i>	Female	64	Knee	-	Amphotericin B / fluconazole	TSRA	≥ 6 wk	Successful	35	-	-

Hwang et al ^[4]	2012	<i>C. pelliculosa</i>	Male	75	Knee	-	Amphotericin B / fluconazole	TSRA	≥ 6 wk	Successful	34	-	-
Klatte et al ^[6]	2014	<i>C. lusitaniae</i>	Male	74	Knee	6	Voriconazole	OSRA	-	Successful		12	-
Hwang et al ^[4]	2012	<i>C. lusitaniae</i>	Female	66	Knee	-	Amphotericin B / fluconazole	TSRA	≥ 6 wk	Successful	43	-	-
Hwang et al ^[4]	2012	<i>C. famata</i>	Female	83	Knee	-	Amphotericin B / fluconazole	TSRA	≥ 6 wk	Successful	33	-	-
Anagno-stakos et al ^[10]	2012	<i>C. lipolytica</i>	Male	77	Hip	7	Fluconazole	TSRA	6 wk	Successful	22	-	-
Wang et al ^[23]	2015	<i>C. utilis</i>	Female	56	Knee	2	Fluconazole	TSRA	6 wk	Successful	24	-	5
Dutronc et al ^[27]	2010	<i>C. guilliermondii</i>	Male	76	Knee	4	Amphotericin B+ fluorocytosine / Fluconazole	None	14 wk (2 wkAMB+ 5FC, then 3 mo FZ)	Failure	-	0	-
Geng et al ^[7]	2016	<i>C. freyschussii</i>	Female	58	Knee	2	Fluconazole / Caspofungin	TSRA	10 wk	Successful	55	<0.25	

Patient demographics, antifungal treatment, its duration, as well as infection outcome and follow-up period are presented.

¹Bilateral PJI in the same patient; -: Not reported or unclear. TSRA: Two stage revision arthroplasty; OSRA: One stage revision arthroplasty; RA: Resection arthroplasty.

away from unrelated causes.

The majority of *C. tropicalis* PJIs were treated with amphotericin B [6; (60%), in 3 (50%) as monotherapy], followed by fluconazole [5; (50%), in 3 (60%) as monotherapy], ketoconazole [2; (20%), none as monotherapy] and caspofungin [1; (10%), not as monotherapy]. Outcome was successful in 9 cases (90%; case number 66 in Table 1, treated with fluconazole as monotherapy, did not provide information about outcome).

All patients suffering from *C. pelliculosa* PJI received fluconazole [3 cases; (100%), 1 (33.3%) as monotherapy], while 2 of them (66.7%) received amphotericin B (none as monotherapy). All patients (100%) were treated successfully. Both patients suffering from *C. lusitaniae* were treated successfully. Voriconazole was used as monotherapy in 1 case (50%), while amphotericin B and fluconazole were used in the other.

One patient suffering from *C. famata* was successfully treated with amphotericin B and fluconazole, while fluconazole as monotherapy was successfully used for the treatment of each case of *C. lipolytica* and *C. utilis* PJI. One case of *C. freyschussii* was successfully treated with fluconazole and caspofungin. A case of *C. guilliermondii* infection received amphotericin B, fluorocytosine and fluconazole, however, the result was failure. The mean antifungal treatment duration was 12.8 wk (SD = 10.9), while the mean follow-up of these cases was 33.3 mo (SD = 19.6).

DISCUSSION

Fungal invasive infections, such as PJIs, due to *Candida* species have been acknowledged as a major cause of morbidity and mortality. These infections have been associated with progress in medical modalities, and in some cases have been considered iatrogenic^[3,4]. *Candida* PJIs are relative rare, since only case reports or small case series have been reported so far. *Candida albicans* is the most prevalent species. However, the incidence of invasive candidiasis and PJIs due to non-*albicans Candida* is increasing^[5,48]. Optimal treatment of these infections remains unclear, since no certain guidelines exist for the antifungal, as well as for the surgical treatments^[48]. It is, therefore, of paramount importance to report such cases and to obtain a better understanding of treatment options and outcomes of these infections. The present study is an effort to review, in a systematic way, the non-*albicans Candida* PJI cases

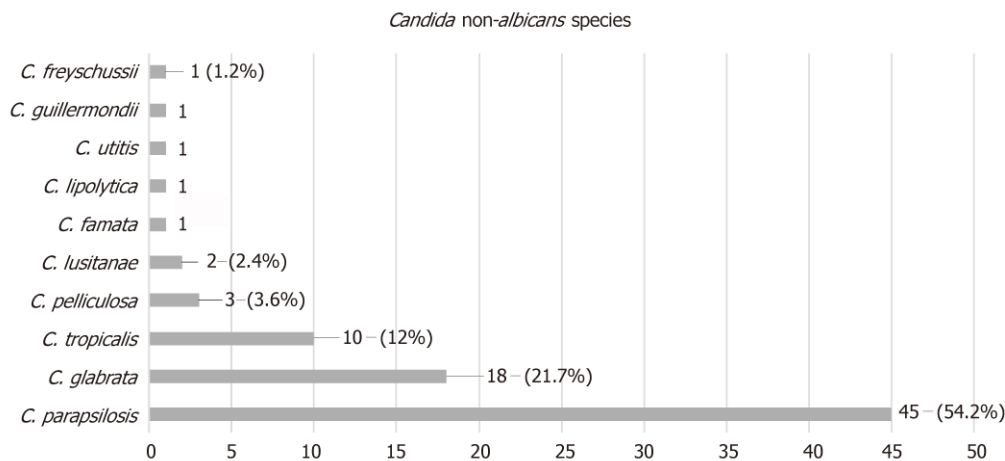


Figure 1 Prosthetic joint infection causative non-*albicans* *Candida* species.

DISCUSSION

Fungal invasive infections, such as PJIs, due to *Candida* species have been acknowledged as a major cause of morbidity and mortality. These infections have been associated with progress in medical modalities, and in some cases have been considered iatrogenic^[3,4]. *Candida* PJIs are relative rare, since only case reports or small case series have been reported so far. *Candida albicans* is the most prevalent species. However, the incidence of invasive candidiasis and PJIs due to non-*albicans* *Candida* is increasing^[5,48]. Optimal treatment of these infections remains unclear, since no certain guidelines exist for the antifungal, as well as for the surgical treatments^[48]. It is, therefore, of paramount importance to report such cases and to obtain a better understanding of treatment options and outcomes of these infections. The present study is an effort to review, in a systematic way, the non-*albicans* *Candida* PJI cases described in the literature. The study focuses on the preferred antifungal agent, the optimal surgical treatment, and the duration of therapy.

The electronic search has revealed a total of 83 patients with non-*albicans* *Candida* PJI. Their mean age was 66.3 years. Although *Candida* PJI is still considered rare, its incidence is expected to rise, due to the increasing number of joint arthroplasty surgeries performed worldwide^[2,48].

Several risk factors have been identified for invasive candidiasis, such as immunosuppression, long-term antimicrobial use and systemic disease^[3,4,5,48]. Such a patient profile has been illustrated by the relatively high mean Charlson comorbidity index of the present study's population, found to be 4.4.

Candida PJI is most commonly considered of hematogenous origin^[2,6,48]. The mean time between initial arthroplasty surgery and symptomatology onset in the study population was 27.2 mo, while it ranged from immediately after surgery to 264 mo. It is of note that in 13 cases [15.7%; cases 8, 23, 47, 51, 54, 55, 57, 60, 61, 69, 70, 82, 83 (Table 1)] this time was found to be less than 1 mo. Therefore, in these cases the spread should be considered perioperative.

It is also of interest that the mean time between symptomatology onset and definite (culture-based) diagnosis was 7.5 mo, ranging from immediately after onset to 60 mo. This could be attributed to the fact that the main symptoms of *Candida* PJI are non-specific, which mainly include pain and swelling^[1-3,48]. The symptomatology onset may be mild, insidious and slowly progressive. Therefore, diagnosis may be delayed due to low suspicion index.

The most frequently isolated non-*albicans* *Candida* spp was *C. parapsilosis*, found in 45 cases (54.2%), followed by *C. glabrata* in 18 (21.7%), *C. tropicalis* in 10 (12%), *C. pelliculosa* in 3 (3.6%), *C. lusitanae* in 2 (2.4%) and 1 case each (1.2%) of PJI caused by *C. famata*, *C. lipolytica*, *C. utitis*, *C. guilliermondii* and *C. freyschussii*.

In the present study, *C. parapsilosis* was found to be the predominant pathogen causing PJIs, as compared to other non-*albicans* *Candida* species. *C. parapsilosis* prevalence has dramatically increased over the last 3 decades. Infections due to this pathogen are more frequently associated with prosthetic devices, indwelling catheters and hyperalimentation solutions. The pathogenesis of the infection depends on the expression of virulence factors, including adherence to host cells and tissues, biofilm formation and secretion of extracellular hydrolytic enzymes^[5,49].

The treatment of *C. parapsilosis* PJIs has proven to be successful in 88.9% of the

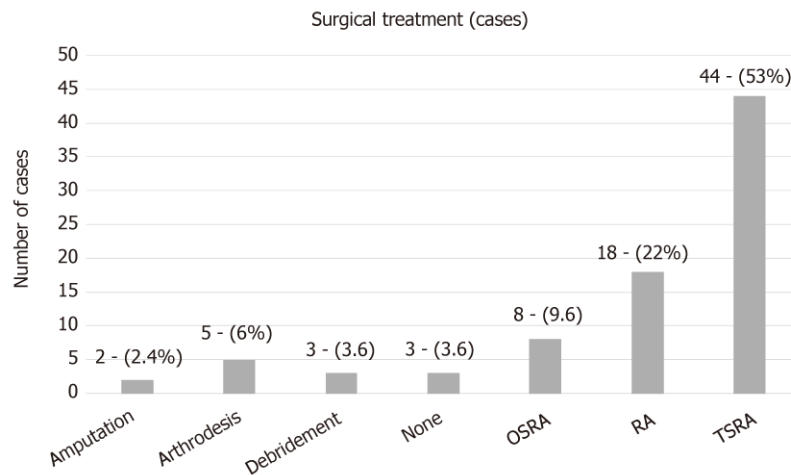


Figure 2 Surgical treatment for non-albicans *Candida* prosthetic joint infection. TSRA: Two stage revision arthroplasty; OSRA: One stage revision arthroplasty; RA: Resection arthroplasty.

studied cases. This is probably due to the fact that echinocandins were not used for the treatment of such cases, taking into account that *C. parapsilosis*' MICs are usually elevated to echinocandins, as compared to other *Candida* spp^[50].

Treatment of *C. glabrata* PJIs has been successful in 94.4% of the studied cases. This is probably due to the fact that an azole compound has rarely been used for treatment and, in the limited number of cases when an azole was used, the drug has been given in combination with another antifungal, taking into account that *C. glabrata* is often resistant to azoles^[50]. In most cases of *C. tropicalis* PJIs, treatment has been successful, since either single antifungal agents or combinations are known to be effective against this *Candida* spp.

All cases of *C. pelliculosa* PJIs have been treated successfully due to the use of effective agents. *C. lusitanae* is intrinsically resistant to amphotericin B^[50,51]. One case received this agent in combination with fluconazole, while the other one was treated with voriconazole as monotherapy. Hence, finally, the 2 cases caused by *C. lusitanae* were successfully treated.

The cases of *C. famata*, *C. lyopolitica* and *C. utilis* were successfully treated with the antifungals given. It is of note that the single case of *C. guilliermondii*, although treated with a combination of antifungals, resulted in failure. For successful treatment, it is of the utmost importance to carry out susceptibility testing to obtain accurate MIC values following *Candida* isolation, taking into account that different *Candida* species are characterized by intrinsic resistance to certain antifungal compounds. Regarding the preferred antifungal agent, fluconazole was used in most cases [59; (71%), in 31 of them (52.5%) as monotherapy], followed by amphotericin B [41; (49.4%), in 4 (9.8%) as monotherapy]. Fluconazole has been rarely associated with severe hepatotoxicity. Therefore, liver function tests should be performed regularly during prolonged fluconazole therapy^[50,51]. Amphotericin B is an effective broad spectrum agent. However, it is relatively toxic and its side effects, including renal dysfunction, may restrict its long-term use, which is essential in PJI cases^[6]. Echinocandins are the most recently developed anti-*Candida* agents. Although *C. parapsilosis* strains mostly exhibit high MICs, these agents can often be clinically effective due to their immunomodulatory properties and the fact that they successfully penetrate biofilms^[52].

The mean duration of antifungal treatment in the study population was 12.8 wk, while it ranged from 1 to 53 wk. One case (case 32 in Table 1) did not receive any antifungal treatment. Guidelines for the treatment of osteoarticular infections from *Candida* spp exist. However, no clear recommendations are available for the treatment of such PJIs^[6,48]. Therefore, the treatment duration is mainly based on the clinical and laboratory findings of each case.

Several options for surgical treatment have also been described. In the study population, in most cases (44 cases; 53%) a TSRA was performed, followed by RA (18 cases; 22%), OSRA (8 cases; 9.6%), arthrodesis (5 cases; 6%), debridement (3 cases; 3.6%) and amputation (2 cases; 2.4%). Three cases did not receive surgical treatment (3.6%; case 4, 55 and 82 in Table 1). RA, arthrodesis, amputation and debridement are usually considered alternative options to arthroplasty exchange. TSRA had a statistically significant higher success rate when compared to OSRA (96% vs 73%; *P*-

value = 0.023). Therefore, it seems more proper that TSRA should be considered as the optimal surgical intervention.

The present review has shown that non-*albicans Candida* PJIs represent a dangerous reality. Optimal management consists of a combination of the proper medical antifungal treatment based on susceptibility testing and surgical intervention. Although there have been reports of successful treatment of such cases with OSRA and debridement only, TSRA should be strongly recommended. The combination of TSRA separated by 3–6 mo and a prolonged period of antifungal therapy is suggested on the basis of limited data. Additional issues, such as the duration of antifungal therapy after prosthesis implantation (second stage of the TSRA), as well as the role of antifungal-loaded cement spacers, need to be addressed in order to determine the optimal treatment combinations.

ARTICLE HIGHLIGHTS

Research background

Prosthetic joint infection (PJI) represents a severe complication of joint reconstruction surgery, causing total arthroplasty failure. Many pathogens have been identified in PJIs, such as Gram-positive and negative bacteria, while fungal microorganisms are considered rare causes, occurring in 1–2% of cases. *Candida* spp represent the most common fungal pathogens in these infections, with *Candida albicans* being the most prevalent species. However, the incidence of non-*albicans Candida* PJIs has increased over the last years. Hence, regarding non-*albicans Candida* PJIs, only case reports or small series have been reported so far. Optimal treatment is considered the two stage revision surgery in combination with an antifungal agent. However, no clear guidelines have yet been developed regarding the agent and treatment duration. Hence, a broad range of antifungal and surgical treatments has been reported so far. The present review article represents the first effort of evaluating the reported non-*albicans Candida* PJIs, aiming to clarify the treatment options of these infections and, possibly, to improve the medical and surgical care of such cases.

Research motivation

The absence of clear guidelines regarding fungal PJIs represents a primary issue in managing these infections in clinical practice. A broad range of antifungal and surgical treatments have been reported, while treatment duration remains unclear. Furthermore, due to the limited data regarding these infections, information about patient demographics, responsible non-*albicans Candida* species, time between initial arthroplasty and symptom onset, time between symptom onset and definite diagnosis (culture), and outcome of the infection has not been reported in a systematic way. Hence, it is of utmost importance in the future to report such cases in order to obtain a better understanding about this devastating arthroplasty complication.

Research objectives

The main objective of this study was to clarify, by systematically reviewing current published cases in the literature, the treatment options of non-*albicans Candida* PJIs and, possibly, to improve the medical and surgical care of such cases. During the process of reviewing the literature, it became apparent that information about patient demographics, fungal species, time between initial arthroplasty and symptom onset, time between symptom onset and definite diagnosis (culture), as well as outcome of the infection should also be reported, due to the absence of a systematic review regarding this topic.

Research methods

A meticulous electronic search of PubMed and MEDLINE databases was performed to identify all articles reporting the management of non-*albicans Candida* PJIs cases through April 2018 by two independent investigators. The citations in each article were reviewed to locate additional references that were not retrieved during the initial search. The evaluated parameters were patient demographics and comorbidities, affected joints, responsible non-*albicans Candida* species, duration and type of antifungal treatment, type of surgical treatment, time between initial arthroplasty and symptom onset, time between symptom onset and definite diagnosis (culture), and outcome of the infection. Data were recorded and analyzed using Microsoft Excel 2010 (Microsoft Corporation, Redmond, Washington). Two-sided Fisher's exact tests were used to compare success rates between groups. Statistical analyses were carried out at the 5% level of significance.

Research results

A total of 83 non-*albicans Candida* PJIs were located, with a mean age of 66.3 years (SD = 10.2). The knee was the affected joint in 52 cases (62.6%), the hip in 29 (35%) and the shoulder in 2 (2.4%). The mean time from arthroplasty to symptoms onset was found to be 27.2 mo (SD = 43), while the mean time from symptoms onset to culture-confirmed diagnosis was 7.5 mo (SD = 12.5). The most commonly isolated non-*albicans Candida* species was *C. parapsilosis*, found in 45 cases (54.2%), followed by *C. glabrata* in 18 (21.7%), *C. tropicalis* in 10 (12%), *C. pelliculosa* in 3 (3.6%) and *C. lusitanae* in 2 (2.4%), while *C. famata*, *C. lipolytica*, *C. utilis*, *C. guilliermondii* and *C. freyschussii* had caused one case each (1.2%). A two stage revision arthroplasty (TSRA) was performed in most cases (44 cases; 53%), followed by RA (18 cases; 22%), OSRA (8 cases; 9.6%),

arthrodesis (5 cases; 6%), debridement (3 cases; 3.6%) and amputation (2 cases; 2.4%), while 3 cases (3.6%) received no surgical treatment. TSRA when compared to OSRA had a higher success rate (96% vs 73%; P -value = 0.023). Fluconazole was used in most cases as antifungal treatment [59; (71%), in 31 of them (52.5%) as monotherapy], followed by amphotericin B [41; (49.4%), in 4 (9.8%) as monotherapy], flucytosine [13; (15.7%), in 1 (7.7%) as monotherapy], caspofungin [7; (8.4%), in 1 (14.3%) as monotherapy], voriconazole [7; (8.4%), in 2 (28.6%) as monotherapy], ketoconazole [5; (6%), none as monotherapy], itraconazole [3; (3.6%), none as monotherapy] and anidulafungin [1; (1.2%), none as monotherapy]. The final outcome was successful in 74 cases (89.2%). The mean antifungal treatment duration was 12.8 wk (SD = 10.9), while the mean follow-up of these cases was 33.3 mo (SD = 19.6). The present review has shown that the optimal management of non-*albicans Candida* consists of a combination of the proper medical antifungal treatment and surgical intervention. Although there have been reports of the successful treatment of such cases with OSRA and debridement only, TSRA should be strongly recommended. The combination of TSRA and a prolonged period of antifungal therapy based on susceptibility testing is suggested on the basis of limited data. Additional issues, such as the duration of antifungal therapy after prosthesis implantation (second stage of the TSRA) and the role of antifungal-loaded cement spacers need to be addressed in order to determine an optimal treatment combination.

Research conclusions

The present study is an effort to review, in a systematic way, the non-*albicans Candida* PJI cases described in the literature. The study focuses on the preferred antifungal agent, the optimal surgical treatment, and the duration of therapy. *C. parapsilosis* was found to be the predominant pathogen causing PJIs, as compared to other non-*albicans Candida* species. For successful management of non-*albicans Candida* PJI, susceptibility testing to obtain accurate MIC values should always be performed following the *Candida* isolation, considering that different *Candida* species are characterized by intrinsic resistance to certain antifungal compounds. The mean duration of antifungal treatment in the present review was 12.8 wk, while it ranged from 1 to 53 wk. Although, guidelines for the treatment of osteoarticular infections from *Candida* spp are available, no clear recommendations exist for the treatment of such PJIs. Therefore, the treatment duration is mostly based upon clinical and laboratory findings. In most cases (44 cases; 53%) a TSRA was performed, followed by RA (18 cases; 22%), OSRA (8 cases; 9.6%), arthrodesis (5 cases; 6%), debridement (3 cases; 3.6%) and amputation (2 cases; 2.4%). Three cases did not receive surgical treatment (3.6%). RA, arthrodesis, amputation and debridement are usually considered alternative options to arthroplasty exchange. TSRA when compared to OSRA had a statistically significant higher success rate (96% vs 73%; P -value= 0.023). Therefore, it seems more proper that TSRA should be considered as the optimal surgical intervention. The present review has shown that the optimal management of non-*albicans Candida* PJIs consists of a combination of the proper medical antifungal treatment based on susceptibility testing and a surgical intervention, while TSRA should be strongly recommended. The combination of TSRA separated by 3–6 mo, in addition to a prolonged period of antifungal therapy, is suggested.

Research perspectives

Non-*albicans Candida* PJIs represent a dangerous reality. The combination of TSRA separated by 3–6 mo and a prolonged period of antifungal therapy is suggested on the basis of limited data. It is of paramount importance to report the treatment of such cases, even the failed ones, in order to obtain a better understanding of these infections and to determine the optimum treatment combination.

REFERENCES

- 1 **Pulido L**, Ghanem E, Joshi A, Purtil JJ, Parvizi J. Periprosthetic joint infection: the incidence, timing, and predisposing factors. *Clin Orthop Relat Res* 2008; **466**: 1710-1715 [PMID: 18421542 DOI: 10.1007/s11999-008-0209-4]
- 2 **Schoof B**, Jakobs O, Schmidl S, Klatt TO, Frommelt L, Gehrke T, Gebauer M. Fungal periprosthetic joint infection of the hip: a systematic review. *Orthop Rev (Pavia)* 2015; **7**: 5748 [PMID: 25874063 DOI: 10.4081/or.2015.5748]
- 3 **Azzam K**, Parvizi J, Jungkind D, Hanssen A, Fehring T, Springer B, Bozic K, Della Valle C, Pulido L, Barrack R. Microbiological, clinical, and surgical features of fungal prosthetic joint infections: a multi-institutional experience. *J Bone Joint Surg Am* 2009; **91** Suppl 6: 142-149 [PMID: 19884422 DOI: 10.2106/JBJS.1.00574]
- 4 **Hwang BH**, Yoon JY, Nam CH, Jung KA, Lee SC, Han CD, Moon SH. Fungal peri-prosthetic joint infection after primary total knee replacement. *J Bone Joint Surg Br* 2012; **94**: 656-659 [PMID: 22529086 DOI: 10.1302/0301-620X.94B5.28125]
- 5 **Deorukhkar SC**, Saini S, Mathew S. Virulence Factors Contributing to Pathogenicity of *Candida tropicalis* and Its Antifungal Susceptibility Profile. *Int J Microbiol* 2014; **2014**: 456878 [PMID: 24803934 DOI: 10.1155/2014/456878]
- 6 **Koutserimpas C**, Samonis G, Velivassakis E, Iliopoulou-Kosmadaki S, Kontakis G, Kofteridis DP. *Candida glabrata* prosthetic joint infection, successfully treated with anidulafungin: A case report and review of the literature. *Mycoses* 2018; **61**: 266-269 [PMID: 29272049 DOI: 10.1111/myc.12736]
- 7 **Geng L**, Xu M, Yu L, Li J, Zhou Y, Wang Y, Chen J. Risk factors and the clinical and surgical features of fungal prosthetic joint infections: A retrospective analysis of eight cases. *Exp Ther Med* 2016; **12**: 991-999 [PMID: 27446310 DOI: 10.3892/etm.2016.3353]
- 8 **Klatta TO**, Kendoff D, Kamath AF, Jonen V, Rueger JM, Frommelt L, Gebauer M, Gehrke T. Single-stage revision for fungal peri-prosthetic joint infection: a single-centre experience. *Bone Joint J* 2014; **96**-

- B:** 492-496 [PMID: 24692616 DOI: 10.1302/0301-620X.96B4.32179]
- 9 **Zhu Y, Yue C, Huang Z, Pei F.** Candida glabrata infection following total hip arthroplasty: A case report. *Exp Ther Med* 2014; **7:** 352-354 [PMID: 24396403 DOI: 10.3892/etm.2013.1420]
 - 10 **Anagnostakos K, Kelm J, Schmitt E, Jung J.** Fungal periprosthetic hip and knee joint infections clinical experience with a 2-stage treatment protocol. *J Arthroplasty* 2012; **27:** 293-298 [PMID: 21752583 DOI: 10.1016/j.arth.2011.04.044]
 - 11 **Bartalesi F, Fallani S, Salomoni E, Marcucci M, Meli M, Pecile P, Cassetta MI, Latella L, Bartoloni A, Novelli A.** Candida glabrata prosthetic hip infection. *Am J Orthop (Belle Mead NJ)* 2012; **41:** 500-505 [PMID: 23431513]
 - 12 **Hall RL, Frost RM, Vasukutty NL, Minhas H.** Candida glabrata: an unusual fungal infection following a total hip replacement. *BMJ Case Rep* 2012; **2012** [PMID: 23008369 DOI: 10.1136/bcr-2012-006491]
 - 13 **Dumaine V, Eyrolle L, Baixench MT, Paugam A, Larousserie F, Padoin C, Tod M, Salmon D.** Successful treatment of prosthetic knee Candida glabrata infection with caspofungin combined with flucytosine. *Int J Antimicrob Agents* 2008; **31:** 398-399 [PMID: 18242959 DOI: 10.1016/j.ijantimicag.2007.12.001]
 - 14 **Lejko-Zupanc T, Mozina E, Vrevc F.** Caspofungin as treatment for Candida glabrata hip infection. *Int J Antimicrob Agents* 2005; **25:** 273-274 [PMID: 15737527 DOI: 10.1016/j.ijantimicag.2005.01.005]
 - 15 **Fabry K, Verheyden F, Nelen G.** Infection of a total knee prosthesis by Candida glabrata: a case report. *Acta Orthop Belg* 2005; **71:** 119-121 [PMID: 15792220]
 - 16 **Gaston G, Ogden J.** Candida glabrata periprosthetic infection: a case report and literature review. *J Arthroplasty* 2004; **19:** 927-930 [PMID: 15483812 DOI: 10.1016/j.arth.2004.04.012]
 - 17 **Açikgöz ZC, Sayli U, Avci S, Doğruel H, Gamberzade S.** An extremely uncommon infection: Candida glabrata arthritis after total knee arthroplasty. *Scand J Infect Dis* 2002; **34:** 394-396 [PMID: 12069030 DOI: 10.1080/00365540110080232]
 - 18 **Ramamohan N, Zeineh N, Grigoris P, Butcher I.** Candida glabrata infection after total hip arthroplasty. *J Infect* 2001; **42:** 74-76 [PMID: 11243760 DOI: 10.1053/jinf.2000.0763]
 - 19 **Selmon GP, Slater RN, Shepperd JA, Wright EP.** Successful 1-stage exchange total knee arthroplasty for fungal infection. *J Arthroplasty* 1998; **13:** 114-115 [PMID: 9493549 DOI: 10.1016/S0883-5403(98)90086-9]
 - 20 **Nayeri F, Cameron R, Chryssanthou E, Johansson L, Söderström C.** Candida glabrata prosthesis infection following pyelonephritis and septicemia. *Scand J Infect Dis* 1997; **29:** 635-638 [PMID: 9571751 DOI: 10.3109/00365549709035912]
 - 21 **Darouiche RO, Hamill RJ, Musher DM, Young EJ, Harris RL.** Periprosthetic candidal infections following arthroplasty. *Rev Infect Dis* 1989; **11:** 89-96 [PMID: 2916098 DOI: 10.1093/clinids/11.1.89]
 - 22 **Goodman JS, Seibert DG, Reahl GE, Geckler RW.** Fungal infection of prosthetic joints: a report of two cases. *J Rheumatol* 1983; **10:** 494-495 [PMID: 6684169]
 - 23 **Wang QJ, Shen H, Zhang XL, Jiang Y, Wang Q, Chen YS, Shao JJ.** Staged reimplantation for the treatment of fungal peri-prosthetic joint infection following primary total knee arthroplasty. *Orthop Traumatol Surg Res* 2015; **101:** 151-156 [PMID: 25676891 DOI: 10.1016/j.otsr.2014.11.014]
 - 24 **Ueng SW, Lee CY, Hu CC, Hsieh PH, Chang Y.** What is the success of treatment of hip and knee candidal periprosthetic joint infection? *Clin Orthop Relat Res* 2013; **471:** 3002-3009 [PMID: 23633184 DOI: 10.1007/s11999-013-3007-6]
 - 25 **Kuiper JW, van den Bekerom MP, van der Stappen J, Nolte PA, Colen S.** 2-stage revision recommended for treatment of fungal hip and knee prosthetic joint infections. *Acta Orthop* 2013; **84:** 517-523 [PMID: 24171675 DOI: 10.3109/17453674.2013.859422]
 - 26 **Chiu WK, Chung KY, Cheung KW, Chiu KH.** Candida parapsilosis total hip arthroplasty infection: case report and literature review. *J Orthop Trauma* 2013; **17:** 33-36 [DOI: 10.1016/j.jotr.2012.04.008]
 - 27 **Dutronic H, Dauchy FA, Cazanave C, Rougie C, Lafarie-Castet S, Couprie B, Fabre T, Dupon M.** Candida prosthetic infections: case series and literature review. *Scand J Infect Dis* 2010; **42:** 890-895 [PMID: 20608769 DOI: 10.3109/00365548.2010.498023]
 - 28 **Antony S, Dominguez D C, Jackson J, Misenheimer G.** Evaluation and treatment of candida species in prosthetic joint infections. *Infect Dis Clin Pract* 2008; 354-359 [DOI: 10.1097/IPC.0b013e31817cfd7]
 - 29 **Yang SH, Pao JL, Hang YS.** Staged reimplantation of total knee arthroplasty after Candida infection. *J Arthroplasty* 2001; **16:** 529-532 [PMID: 11402423 DOI: 10.1054/arth.2001.21458]
 - 30 **Bruce AS, Kerry RM, Norman P, Stockley I.** Fluconazole-impregnated beads in the management of fungal infection of prosthetic joints. *J Bone Joint Surg Br* 2001; **83:** 183-184 [PMID: 11284561 DOI: 10.1302/0301-620X.83B2.0830183]
 - 31 **Brooks DH, Puppato F.** Successful salvage of a primary total knee arthroplasty infected with Candida parapsilosis. *J Arthroplasty* 1998; **13:** 707-712 [PMID: 9741450 DOI: 10.1016/S0883-5403(98)80017-X]
 - 32 **Wada M, Baba H, Imura S.** Prosthetic knee Candida parapsilosis infection. *J Arthroplasty* 1998; **13:** 479-482 [PMID: 9645532 DOI: 10.1016/S0883-5403(98)90019-5]
 - 33 **Cushing RD, Fulgenzi WR.** Synovial fluid levels of fluconazole in a patient with Candida parapsilosis prosthetic joint infection who had an excellent clinical response. *J Arthroplasty* 1997; **12:** 950 [PMID: 9458262 DOI: 10.1016/S0883-5403(97)90166-2]
 - 34 **Fukasawa N, Shirakura K.** Candida arthritis after total knee arthroplasty--a case of successful treatment without prosthesis removal. *Acta Orthop Scand* 1997; **68:** 306-307 [PMID: 9247001 DOI: 10.3109/17453679708996709]
 - 35 **White A, Goetz MB.** Candida parapsilosis prosthetic joint infection unresponsive to treatment with fluconazole. *Clin Infect Dis* 1995; **20:** 1068-1069 [PMID: 7795057 DOI: 10.1093/clinids/20.4.1068]
 - 36 **Tunkel AR, Thomas CY, Wispelwey B.** Candida prosthetic arthritis: report of a case treated with fluconazole and review of the literature. *Am J Med* 1993; **94:** 100-103 [PMID: 8420285 DOI: 10.1016/0002-9343(93)90127-B]
 - 37 **Paul J, White SH, Nicholls KM, Crook DW.** Prosthetic joint infection due to Candida parapsilosis in the UK: case report and literature review. *Eur J Clin Microbiol Infect Dis* 1992; **11:** 847-849 [PMID: 1468427 DOI: 10.1007/BF01960889]
 - 38 **Lim EV, Stern PJ.** Candida infection after implant arthroplasty. A case report. *J Bone Joint Surg Am* 1986; **68:** 143-145 [PMID: 3510212 DOI: 10.2106/00004623-198668010-00020]
 - 39 **Younkin S, Evarts CM, Steigbigel RT.** Candida parapsilosis infection of a total hip-joint replacement: successful reimplantation after treatment with amphotericin B and 5-fluorocytosine. A case report. *J Bone Joint Surg Am* 1984; **66:** 142-143 [PMID: 6690437 DOI: 10.2106/00004623-198466010-00023]
 - 40 **Lichtman EA.** Candida infection of a prosthetic shoulder joint. *Skeletal Radiol* 1983; **10:** 176-177 [PMID: 6635692 DOI: 10.1007/BF00357775]

- 41 **MacGregor RR**, Schimmer BM, Steinberg ME. Results of combined amphotericin B-5-fluorocytosine therapy for prosthetic knee joint infected with *Candida parapsilosis*. *J Rheumatol* 1979; **6**: 451-455 [PMID: 392095]
- 42 **Sebastian S**, Malhotra R, Pande A, Gautam D, Xess I, Dhawan B. Staged Reimplantation of a Total Hip Prosthesis After Co-infection with *Candida tropicalis* and *Staphylococcus haemolyticus*: A Case Report. *Mycopathologia* 2018; **183**: 579-584 [PMID: 28735470 DOI: 10.1007/s11046-017-0177-x]
- 43 **Reddy KJ**, Shah JD, Kale RV, Reddy TJ. Fungal prosthetic joint infection after total knee arthroplasty. *Indian J Orthop* 2013; **47**: 526-529 [PMID: 24133317 DOI: 10.4103/0019-5413.118213]
- 44 **Lidder S**, Tasleem A, Masterson S, Carrington RW. *Candida tropicalis*: diagnostic dilemmas for an unusual prosthetic hip infection. *J R Army Med Corps* 2013; **159**: 123-125 [PMID: 23720596 DOI: 10.1136/jramc-2013-000053]
- 45 **Azam A**, Singh PK, Singh VK, Siddiqui A. A Rare Case of *Candida Tropicalis* Infection of a Total Hip Arthroplasty: A Case Report and Review of Literature. *MOJ* 2008; **2**: 43-46 [DOI: 10.5704/MOJ.0811.011]
- 46 **Wyman J**, McGough R, Limbird R. Fungal infection of a total knee prosthesis: successful treatment using articulating cement spacers and staged reimplantation. *Orthopedics* 2002; **25**: 1391-4; discussion 1394 [PMID: 12502204 DOI: 10.1007/s00132-002-0391-0]
- 47 **Lambertus M**, Thordarson D, Goetz MB. Fungal prosthetic arthritis: presentation of two cases and review of the literature. *Rev Infect Dis* 1988; **10**: 1038-1043 [PMID: 3055186 DOI: 10.1093/clinids/10.5.1038]
- 48 **Pappas PG**, Kauffman CA, Andes DR, Clancy CJ, Marr KA, Ostrosky-Zeichner L, Reboli AC, Schuster MG, Vazquez JA, Walsh TJ, Zaoutis TE, Sobel JD. Executive Summary: Clinical Practice Guideline for the Management of Candidiasis: 2016 Update by the Infectious Diseases Society of America. *Clin Infect Dis* 2016; **62**: 409-417 [PMID: 26810419 DOI: 10.1093/cid/civ1194]
- 49 **Trofa D**, Gácser A, Nosanchuk JD. *Candida parapsilosis*, an emerging fungal pathogen. *Clin Microbiol Rev* 2008; **21**: 606-625 [PMID: 18854483 DOI: 10.1128/CMR.00013-08]
- 50 **Sanguinetti M**, Posteraro B, Lass-Flörl C. Antifungal drug resistance among *Candida* species: mechanisms and clinical impact. *Mycoses* 2015; **58** Suppl 2: 2-13 [PMID: 26033251 DOI: 10.1111/myc.12330]
- 51 **Pasternak B**, Wintzell V, Furu K, Engeland A, Neovius M, Stephansson O. Oral Fluconazole in Pregnancy and Risk of Stillbirth and Neonatal Death. *JAMA* 2018; **319**: 2333-2335 [PMID: 29896619 DOI: 10.1001/jama.2018.6237]
- 52 **Dimopoulou D**, Hamilos G, Tzardi M, Lewis RE, Samonis G, Kontoyiannis DP. Anidulafungin versus caspofungin in a mouse model of candidiasis caused by anidulafungin-susceptible *Candida parapsilosis* isolates with different degrees of caspofungin susceptibility. *Antimicrob Agents Chemother* 2014; **58**: 229-236 [PMID: 24145540 DOI: 10.1128/AAC.01025-13]



Published By Baishideng Publishing Group Inc
7041 Koll Center Parkway, Suite 160, Pleasanton, CA 94566, USA

Telephone: +1-925-2238242

Fax: +1-925-2238243

E-mail: bpgoffice@wjgnet.com

Help Desk: <https://www.f6publishing.com/helpdesk>

<https://www.wjgnet.com>

