

Widespread Microglial Activation in Multiple System Atrophy

Dorothee Kübler, MD,^{1*} Tobias Wächter, MD,^{2,3} Nicole Cabanel, MD,⁴ Zhangjie Su, MD, PhD,⁵ Federico E. Turkheimer, PhD,⁶ Richard Dodel, MD, MBA,⁷ David J. Brooks, MD, DSc,^{8,9} Wolfgang H. Oertel, MD^{10,11} and Alexander Gerhard, MD^{12,13}

¹Movement Disorders Section, Department of Neurology, Charité-Universitätsmedizin Berlin, corporate member of Freie Universität Berlin, Humboldt-Universität zu Berlin and Berlin Institute of Health, Berlin, Germany ²Hertie-Institute for Clinical Brain Research, Department of Neurodegenerative Diseases, Tübingen, Germany ³Department of Neurology, Rehabilitation Centre Bad Gögging, Passauer Wolf, Bad Gögging, Germany ⁴Vitos Clinical Centre for Psychiatry and Psychotherapy, Giessen-Marburg, Germany ⁵Department of Neurosurgery, Salford Royal NHS Foundation Trust, Salford, UK ⁶Department of Neuroimaging, Institute of Psychiatry, Psychology and Neuroscience, King's College London, London, UK ⁷Chair of Geriatrics, University Hospital Essen, Center for Geriatric Medicine Haus Berge, Essen, Germany ⁸Department of Nuclear Medicine and PET-Centre, Institute of Clinical Medicine, Aarhus University, Aarhus C, Denmark ⁹Institute of Neuroscience, Newcastle University, Newcastle Upon Tyne, UK ¹⁰Department of Neurology, Philipps-Universität Marburg, Marburg, Germany ¹¹Institute for Neurogenomics, Helmholtz Center for Health and Environment, München, Germany ¹²Departments of Nuclear Medicine and Geriatric Medicine, University Hospital Essen, Germany ¹³Wolfson Molecular Imaging Centre, University of Manchester, Manchester, UK

*The copyright line for this article was changed on July 5, 2019, after original print and online publication.

This is an open access article under the terms of the Creative Commons Attribution License, which permits use, distribution and reproduction in any medium, provided the original work is properly cited.

*Correspondence to: Dorothee Kübler, Movement Disorders Section, Department of Neurology, Charité-Universitätsmedizin Berlin, Campus Virchow Klinikum, Augustenburger Platz 1, 13353 Berlin, Germany; E-mail: dorothee.kuebler@charite.de

Relevant conflicts of interest/financial disclosures: Nothing to report.

Funding agencies: The project has been supported by Action Research (SP 3615), the Parkinson's Disease Society UK (MAP 02/04), the Medical Research Council (MRC) and the European Union's Seventh Framework Program (FP7/2007-2013) under the grant agreement HEALTH-F2-2011-278850 (INMiND). D. Kübler is a participant in the BIH-Charité Clinician Scientist Program funded by the Charité-Universitätsmedizin Berlin and the Berlin Institute of Health. W.H. Oertel is Hertie Senior Research Professor supported by the Charitable Hertie Foundation, Frankfurt, Germany.

Received: 16 September 2018; **Revised:** 31 December 2018; **Accepted:** 2 January 2019

Published online 6 February 2019 in Wiley Online Library (wileyonlinelibrary.com). DOI: 10.1002/mds.27620

ABSTRACT

Background: The pattern and role of microglial activation in multiple system atrophy is largely unclear. The objective of this study was to use [¹¹C](R)-PK11195 PET to determine the extent and correlation of activated microglia with clinical parameters in MSA patients.

Methods: Fourteen patients with the parkinsonian phenotype of MSA (MSA-P) with a mean disease duration of 2.9 years (range 2-5 years) were examined with [¹¹C](R)-PK11195 PET and compared with 10 healthy controls.

Results: Patients with the parkinsonian phenotype of MSA showed a significant ($P \leq 0.01$) mean increase in binding potentials compared with healthy controls in the caudate nucleus, putamen, pallidum, precentral gyrus, orbitofrontal cortex, presubgenual anterior cingulate cortex, and the superior parietal gyrus. No correlations between binding potentials and clinical parameters were found.

Conclusions: In early clinical stages of the parkinsonian phenotype of MSA, there is widespread microglial activation as a marker of neuroinflammatory changes without correlation to clinical parameters in our patient population. © 2019 The Authors. *Movement Disorders* published by Wiley Periodicals, Inc. on behalf of International Parkinson and Movement Disorder Society.

Key Words: microglia; multiple system atrophy; neuroinflammation; PET; PK11195

Multiple system atrophy (MSA) is a sporadically occurring, adult-onset progressive neurodegenerative disease and presents clinically with variable combinations of marked autonomic insufficiency combined with a progressive akinetic-rigid syndrome and/or cerebellar dysfunction.^{1,2} The parkinsonian phenotype of MSA (MSA-P) exhibits predominant parkinsonism, whereas MSA-C has predominant cerebellar signs.

Histopathological findings in MSA show neuronal loss mainly in the nigrostriatal and olivopontocerebellar pathways, with α -synuclein positive glial cytoplasmic inclusions³ associated with reactive astrocytes and activated microglia.⁴⁻⁶ α -Synuclein aggregates are released from degenerating neurons, inducing neuroinflammation in the form of glial activation that results in cell loss and the formation of further aggregates and thus potentiates its neurodegenerating effect.⁵ Although the exact role of activated microglia in MSA and other neurodegenerative diseases is still a matter of discussion, there is evidence that microglia, once activated, continue to promote disease progression.

Neuropathological findings demonstrate that microglial activation parallels system degeneration in MSA.⁷

Microglia are the resident immunocompetent cells of the CNS.⁸ They respond to a variety of pathological stimuli by developing phagocytic properties and express immunologically relevant molecules.⁹ As these cells react before signs of tissue damage are apparent, they provide an early marker of active disease. One of the molecules selectively expressed by activated microglia is the mitochondrial translocator protein 18-kDa TSPO.¹⁰ In lesions with an intact blood-brain barrier, activated microglia are the primary source of TSPO expression. (R)-PK11195 (1-[2-chlorophenyl]-N-methyl-N-[1-methylpropyl]-3-isoquinoline carboxamide) is a selective ligand for TSPO and, when labeled with [¹¹C], can be used as a PET tracer.¹¹

In a pilot study in patients with MSA using [¹¹C](R)-PK11195 PET, we previously demonstrated increased microglial activation in the dorsolateral prefrontal cortex, putamen, pallidum, substantia nigra (SN) and pons in 5 patients with MSA.¹²

The aim of our present study was to assess the quantity and distribution of microglial activation in a large MSA patient cohort using a high-resolution, high-sensitivity PET camera and to correlate the extent of microglial activation with clinical parameters.

Methods

Fourteen patients (7 female, 7 male; mean age, 58 years; range 45-73 years) with MSA-P according to consensus criteria¹ were recruited for [¹¹C](R)-PK11195 PET. Mean disease duration (from the onset

of first motor symptoms) was 2.9 years (range 2 to 5 years). For clinical details, see Table 1. Ten healthy controls (HCs; 4 female, 6 male, mean age, 59 years; range 38-70 years) also had [¹¹C](R)-PK11195 PET. None of the HCs reported any relevant medical history, and all HCs had a normal neurologic examination.

Ethical approval and permission were given by the Hammersmith Hospitals Trust Ethics Committee and the Administration of Radioactive Substances Advisory Committee of the UK Department of Health. Informed written consent was obtained from all study participants prior to enrollment. All procedures were conducted according to the Declaration of Helsinki.

MRI

Volumetric T₁-weighted MR images were acquired for coregistration with PET to define anatomical regions of interest using a 1.0 T Picker HPQ scanner (Picker, Cleveland, OH).

[¹¹C](R)-PK11195 PET

Participants underwent 3-dimensional [¹¹C](R)-PK11195 PET using an ECAT EXACT HR++ (CTI/Siemens 966) camera located in the Cyclotron Building at Hammersmith Hospital, London, UK, with an axial field of view of 23.4 cm. The tomograph has a spatial resolution of 4.8 ± 0.2 mm FWHM (transaxial, 1 cm off axis) and 5.6 ± 0.5 mm (axial, on axis) after image reconstruction.¹³ Scanning procedures were performed according to previously established protocols (please refer to reference 14 and online supplement). Binding potential (BP), a measure of specific binding of the tracer (B_{\max}/K_d — available concentration of binding sites/receptor

TABLE 1. Clinical and demographic data of the MSA-P cohort

Patient number	Age	Disease duration	UPDRS III	H + Y	S + E	Autonomic	Cerebellar	Pyramidal	L-Dopa response	MSA-P
1	45	2	28	2	100	OH	None	yes	No	Possible
2	54	5	52	4	40	OH, urinary urgency	None	None	Only initially	Probable
3	51	4	31	3	80	urinary frequency and urgency	None	None	Partial	Possible
4	53	2	28	2,5	90	Urinary incontinence, ED	None	None	No	Probable
5	64	4	44	3	70	Urinary incontinence	None	Yes	Partial	Possible
6	59	2	42	4	50	OH, urinary incontinence	None	None	Poor	Probable
7	59	3	41	3	70	Marginal OH	Slight action tremor	Yes	Poor	Possible
8	73	4	31	3	40	OH	None	Yes	Only initially	Probable
9	69	2.5	13	2,5	80	ED, urinary urgency, OH	None	None	Partial	Probable
10	47	2	14	2	80	ED, OH	None	None	No	Probable
11	57	2.5	31	2,5	70	Urinary frequency and urgency, OH	None	None	No	Probable
12	47	3	45	4	40	Urinary incontinence, OH	None	None	Poor	Probable
13	63	2	30	2,5	70	ED, urinary incontinence, OH	None	Yes	Poor	Probable
14	69	3	30	2,5	80	ED	None	None	No	Possible

ED, erectile dysfunction.

Overview of clinical patient data including age and disease duration at study participation in years, UPDRS III, Hoehn and Yahr stage (H + Y), and Schwab and England scale (S + E). Orthostatic hypotension (OH) is defined by a reduction of systolic blood pressure by at least 30 mm Hg or of diastolic blood pressure by at least 15 mm Hg within 3 minutes of standing from the recumbent position.

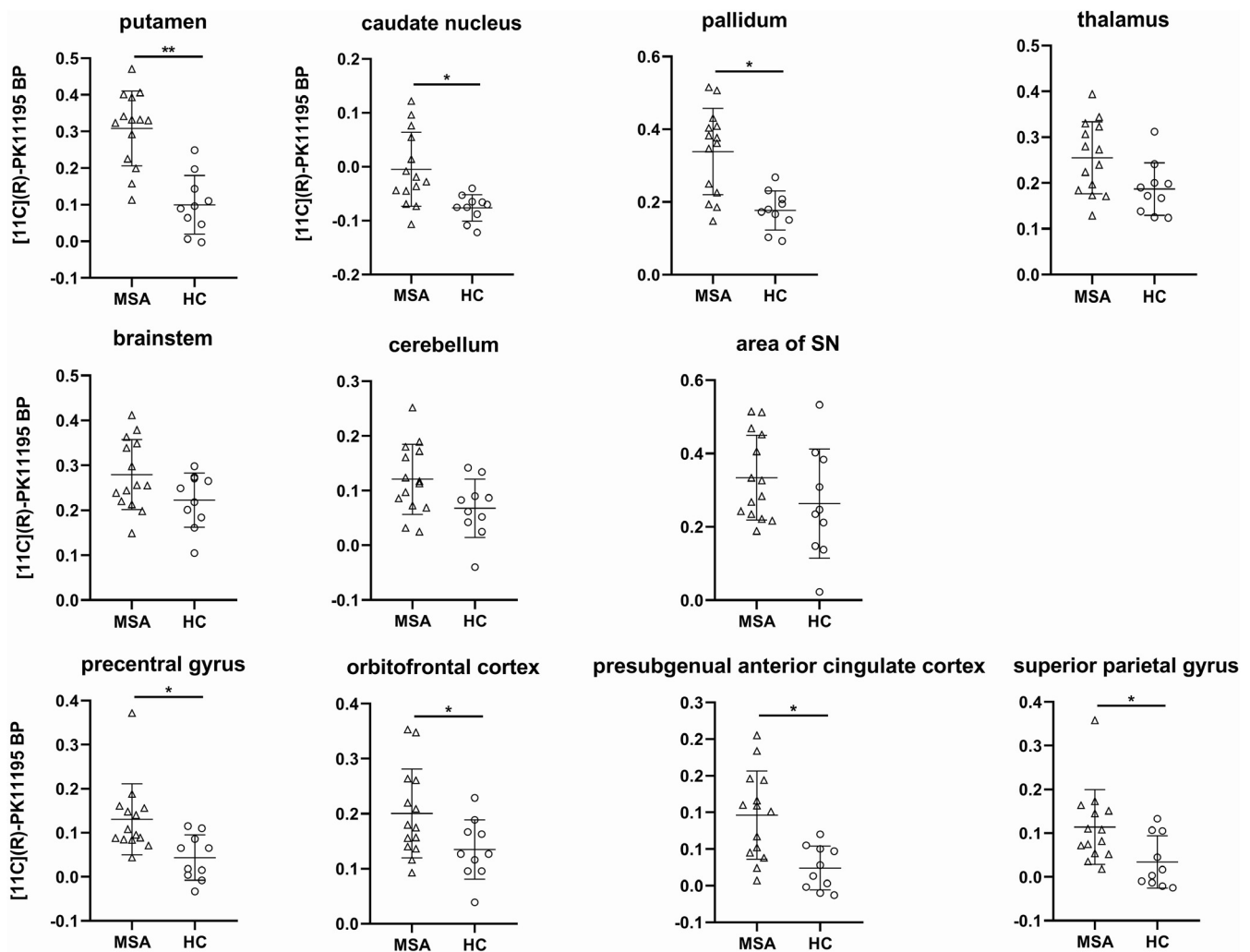


FIG. 1. Comparison of binding potential (BP) values of MSA-P patients and HCs. $[^{11}\text{C}](\text{R})\text{-PK11195}$ BP of MSA-P patients in the 7 selected VOIs and selected cortical VOIs (mean of left and right, if given). Horizontal bars indicate mean and standard deviation. * $P < 0.01$, ** $P \leq 0.001$.

dissociation constant), was calculated at a voxel level using a simplified reference tissue model.¹⁵ For details, see reference 16 and online supplement.

Image Analysis

Parametric BP images were coregistered to the patients' MRIs (see Fig. 1 in the online supplement). Volumes of interest (VOIs) were outlined on the MRI using a probabilistic atlas¹⁷ and applied to the corresponding BP maps using Analyze software.¹⁸ We defined the SN on MRI slices where clearly visible, but as its volume is small compared with PET resolution, anatomical definition was imprecise when coregistering the BP map to the MRI. To account for this inaccuracy, we use the term *area of SN*.

Mann-Whitney *U* tests performed with SPSS 23 (SPSS Inc., Chicago, IL) were used to interrogate the presence of significant differences in mean BP values between groups, and a *Z* value was calculated

for each VOI. Seven VOIs that were reported to be affected in MSA by previous studies (brain stem [includes the pons and medulla oblongata], cerebellum, caudate nucleus, putamen, pallidum, thalamus, and area of SN) were selected. Results were corrected for multiple comparisons using p-plot on an α level of 0.05 (Hochberg correction).¹⁹

Data Availability

The data sets generated and/or analyzed during the current study are available from the corresponding author on reasonable request.

Results

$[^{11}\text{C}](\text{R})\text{-PK11195}$ PET

A significant increase in microglial activation in MSA-P patients compared with HCs (Fig. 1) was seen in the putamen ($P = 0.001$), caudate nucleus ($P = 0.002$), pallidum

($P = 0.002$), precentral gyrus ($P = 0.004$), orbitofrontal cortex ($P = 0.006$), presubgenual anterior cingulate cortex ($P = 0.006$), and superior parietal gyrus ($P = 0.007$). The other VOIs did not show a significant difference between MSA-P patients and HCs. Comparison of BP between groups looking at the whole brain ($P = 0.013$), the parietal lobe ($P = 0.016$), and the frontal lobe ($P = 0.022$) revealed a trend toward an increase in BP in MSA-P patients but did not reach statistical significance (p-plot, $\alpha = 0.05$).

Correlation BP Clinical Parameters

Spearman correlation between BP in the selected VOIs and the clinical parameters age and disease duration at study participation, sum of the motor part (III) of the UPDRS, Hoehn and Yahr stage, and Schwab and England scale did not show significant results ($P \leq 0.05$ was considered significant).

Discussion

Neuroinflammation is a crucial part of the neuropathological changes in MSA,⁷ and [¹¹C](R)-PK11195 PET allows detection of the location and extent of activated microglia in vivo. In our study, [¹¹C](R)-PK11195 PET in patients with MSA-P detected increased signals in regions known to be targeted by the disease: the striatum and pallidum. In addition, frontal and parietal regions also displayed increased BP. Interestingly, there was a trend toward an increase in BP on a whole-brain level and in the frontal and parietal lobes. The failure to find a significant BP increase in the SN is in contrast to our earlier findings.¹⁵ However, 12 of our 14 patients showed an increase in this region compared with the mean BP value of HCs in at least 1 SN. Also, the patients in the previous study had longer mean disease duration than in our present study (68 versus 35 months) and were clinically more severely affected.

Although the changes in BP values in the cerebellums of MSA patients were not statistically significant when compared with those in the HCs, a number of patients showed raised values. This is of particular interest, as all our patients were classified as MSA-P and only 1 of them had a slight tremor. Potentially, the raises in [¹¹C](R)-PK11195 binding indicate a “preclinical” change. Studies in other neurological diseases have shown that microglial activation can precede clinical manifestations. Asymptomatic gene carriers have shown increased striatal and cortical BP in Huntington’s disease.²⁰ Patients with idiopathic rapid eye movement sleep behavior disorder showed an increase in BP in the left SN along with a decrease in F-dopa uptake in the bilateral putamen compared with HCs.²¹ As most cases are converting to α -synucleinopathies, these findings support the role of microglia as an early component of

neurodegenerative disorders that could be a potential therapeutic target.

Our patients were clinically at an early stage of the disease, and we did not find a correlation between regional BP values and clinical severity. Most had a diagnosis of probable MSA-P but showed some clinical heterogeneity. There was high intersubject variability for regional BP values, a phenomenon that has been observed in other neurodegenerative disorders that have been examined with TSPO PET tracers. The high variability of microglial activation is also reflected in PET studies of idiopathic Parkinson’s disease, with some authors finding a correlation with clinical phenotype, but others failing to do so.²² Because of the lack of TSPO studies in MSA, we can only assume at this stage that the clinical phenotype and severity will not be a simple linear function of the amount and localization of microglial activation. Overall, microglial activation appears to happen early in neurological diseases, and the mutual relationship between neurodegeneration and neuroinflammation is complex. Ishizawa and colleagues suggest a distinction in the course of microglial activation between gray and white matter. They hypothesize that the amount of microglial activation in MSA is reduced with increasing severity of tissue injury in white- but not in gray-matter areas, where such correlations could not be shown.⁶ Also, although some authors assume that microglial activation is part of pathogenesis, it might also be that these cells play a protective role initially, as has been postulated for patients with early-stage Alzheimer’s disease.^{23,24}

To further elucidate the complex interaction between microglial activation and clinical phenotype and progression in MSA and other neurodegenerative disorders, longitudinal combined clinical and imaging studies are needed that also investigate other aspects of microglial activation apart from TSPO expression.²⁵

When interpreting our results, it is important to realize that TSPO expression is only one part of the much more complex phenomenon of microglial activation. We currently do not have in vivo imaging methods available that allow distinguishing between different types of activated micro- and astroglia. In our study, we used [¹¹C](R)-PK11195 as a marker of TSPO rather than one of the second-generation TSPO PET tracers. [¹¹C](R)-PK11195 is the best characterized TSPO tracer and has enabled us to compare our results with those of previous studies of microglial activation in α -synucleinopathies. Also, its binding affinity is not influenced by the TSPO polymorphism. However, [¹¹C](R)-PK11195 has a lower specific-to-background signal ratio than newer microglial tracers, which might lead to underestimation of the extent of microglial activation.²⁶

We provide evidence that microglial activation is an important feature of the pathological changes in MSA.

Decoding the role of neuroinflammation in the pathophysiology of neurodegenerative diseases is a crucial step toward possible therapeutic strategies. ■

Acknowledgments: We thank the patients and volunteers who participated in this study. A. Blyth, H. McDevitt, and L. Schnorr provided expert technical assistance with PET data acquisition. N. Quinn and C. Mathias, National Hospital for Neurology and Neurosurgery, London, kindly helped with patient identification.

References

- Wenning GK, Gilman S, Seppi K. Second consensus statement on the diagnosis of multiple system atrophy. *Aktuelle Neurologie* 2008; 35:670-676.
- Ubhi K, Low P, Masliah E. Multiple system atrophy: a clinical and neuropathological perspective. *Trends Neurosci* 2011;34:581-590.
- Wakabayashi K, Takahashi H. Cellular pathology in multiple system atrophy. *Neuropathology* 2006;26:338-345.
- Brück D, Wenning GK, Stefanova N, Fellner L. Glia and alpha-synuclein in neurodegeneration: a complex interaction. *Neurobiol Dis* 2016;85:262-274.
- Vieira B, Radford RA, Chung RS, Guillemin GJ, Pountney DL. Neuroinflammation in Multiple System Atrophy: Response to and Cause of α -Synuclein Aggregation. *Front Cell Neurosci* 2015; 9:437.
- Ishizawa K, Komori T, Arai N, Mizutani T, Hirose T. Glial cytoplasmic inclusions and tissue injury in multiple system atrophy: A quantitative study in white matter (olivopontocerebellar system) and gray matter (nigrostriatal system). *Neuropathology* 2008;28:249-257.
- Ishizawa K, Komori T, Sasaki S, Arai N, Mizutani T, Hirose T. Microglial activation parallels system degeneration in multiple system atrophy. *J Neuropathol Exp Neurol* 2004;63:43-52.
- Ginhoux F, Lim S, Hoeffel G, Low D, Huber T. Origin and differentiation of microglia. *Front Cell Neurosci* 2013;7:45.
- Kreutzberg G. Microglia: a sensor for pathological events in the CNS. *Trends Neurosci* 1996;19:312-318.
- Papadopoulos V, Baraldi M, Guilarte T, et al. Translocator protein (18kDa): new nomenclature for the peripheral-type benzodiazepine receptor based on its structure and molecular function. *Trends Pharmacol Sci* 2006;27:402-409.
- Turkheimer F, Rizzo G, Bloomfield P, et al. The methodology of TSPO imaging with positron emission tomography. *Biochem Soc Trans* 2015;43:586-592.
- Gerhard A, Banati RB, Goerres GB, et al. [^{11}C](R)-PK11195 PET imaging of microglial activation in multiple system atrophy. *Neurology* 2003;61:686-689.
- Spinks TJ, Jones D, Bailey DL, et al. Physical performance of a positron tomograph for brain imaging with retractable septa. *Phys Med Biol* 1992;37:1637-1655.
- Gerhard A, Pavese N, Hotton G, et al. In vivo imaging of microglial activation with [^{11}C](R)-PK11195 PET in idiopathic Parkinson's disease. *Neurobiol Dis* 2006;21:404-412.
- Gunn R, Lammertsma A, Hume S, Cunningham V. Parametric imaging of ligand-receptor binding in PET using a simplified reference region model. *Neuroimage* 1997;6:279-287.
- Banati RB, Newcombe J, Gunn RN, et al. The peripheral benzodiazepine binding site in the brain in multiple sclerosis: quantitative in vivo imaging of microglia as a measure of disease activity. *Brain* 2000;123(Pt 11):2321-2337.
- Hammers A, Allom R, Koeppe M, et al. Three-dimensional maximum probability atlas of the human brain, with particular reference to the temporal lobe. *Hum Brain Mapp* 2003;19:224-247.
- Robb RA, Hanson DP. A software system for interactive and quantitative visualization of multidimensional biomedical images. *Australas Phys Eng Sci Med* 1991;14:9-30.

- Turkheimer FE, Smith CB, Schmidt K. Estimation of the number of 'true' null hypotheses in multivariate analysis of neuroimaging data. *Neuroimage* 2001;13:920-930.
- Tai Y, Pavese N, Gerhard A, et al. Microglial activation in presymptomatic Huntington's disease gene carriers. *Brain* 2007;130:1759-1766.
- Stokholm M, Iranzo A, Østergaard K, et al. Assessment of neuroinflammation in patients with idiopathic rapid-eye-movement sleep behaviour disorder: a case-control study. *The Lancet Neurology* 2017;16(10):789-798.
- Gerhard A. TSPO imaging in parkinsonian disorders. *Clin Transl Imaging* 2016;4:183-190.
- Hamelin L, Lagarde J, Dorothée G, et al. Early and protective microglial activation in Alzheimer's disease: a prospective study using 18F-DPA-714 PET imaging. *Brain* 2016;139:1252-1264.
- Fan Z, Okello A, Brooks D, Edison P. Longitudinal influence of microglial activation and amyloid on neuronal function in Alzheimer's disease. *Brain* 2015;138:3685-3698.
- Janssen B, Vugts D, Windhorst A, Mach R. PET imaging of microglial activation—beyond targeting TSPO. *Molecules* 2018; 23:607.
- Cumming P, Burgher B, Patkar O, et al. Sifting through the surfeit of neuroinflammation tracers. *J Cereb Blood Flow Metab* 2017;38: 204-224.

Supporting Data

Additional Supporting Information may be found in the online version of this article at the publisher's web-site.

Clinical Heterogeneity of Frontotemporal Dementia and Parkinsonism Linked to Chromosome 17 Caused by *MAPT* N279K Mutation in Relation to Tau Positron Emission Tomography Features

Aya Ikeda, MD,¹ Hitoshi Shimada, MD, PhD,² Kenya Nishioka, MD, PhD,¹ Masashi Takanashi, MD, PhD,¹ Arisa Hayashida, MD,¹ Yuanzhe Li, MD, PhD,¹ Hiroyo Yoshino, PhD,³ Manabu Funayama, PhD,^{1,3} Yuji Ueno, MD, PhD,¹ Taku Hatano, MD, PhD,¹ Naruhiko Sahara, PhD,² Tetsuya Suhara, MD, PhD,² Makoto Higuchi, MD, PhD^{2*} and Nobutaka Hattori, MD, PhD^{1,3*}

¹Department of Neurology, Juntendo University School of Medicine, Tokyo, Japan ²Department of Functional Brain Imaging Research, National Institute of Radiological Sciences, National Institutes for Quantum and Radiological Science and Technology, Chiba, Japan ³Research Institute for Diseases of Old Age, Graduate School of Medicine, Juntendo University, Tokyo, Japan