



RESEARCH ARTICLE

Postoperative pain and antibacterial effect of 980 nm diode laser versus conventional endodontic treatment in necrotic teeth with chronic periapical lesions: A randomized control trial [version 1; peer review: 2 approved, 1 approved with reservations]

Dina A. Morsy , Maged Negm, Alaa Diab, Geraldine Ahmed

Department of Endodontics, Faculty of Oral and Dental Medicine, Cairo University, Cairo, 11553, Egypt

v1 **First published:** 15 Nov 2018, 7:1795 (<https://doi.org/10.12688/f1000research.16794.1>)
Latest published: 15 Nov 2018, 7:1795 (<https://doi.org/10.12688/f1000research.16794.1>)

Abstract

Background: Many challenges encounter the endodontist, especially when dealing with necrotic teeth with chronic periapical lesions. Postoperative pain may be induced following conventional endodontic therapy and total eradication of the bacteria is almost unachievable even with recently available techniques. In recent years, diode laser usage in the endodontic field has gained acceptance. Thus, this study aimed to investigate the ability of the diode laser (DL) to decrease postoperative pain and achieve root canal sterility.

Methods: 56 patients with anterior teeth with chronic periapical lesions in upper anterior teeth were randomly divided into two groups (n = 28). All patients were treated with two visits of conventional root canal treatment with ProTaper Universal. The DL group: root canals were irradiated with 200 µm fiber optic at both visits; the control group (Endo): the DL fiber was placed in root canal with no activation. Bacterial samples were collected from all the cases at each step of the treatment. Pain levels were evaluated using a numerical rating scale preoperatively, and after 6, 12, 24, 48 hours and 7 days. Bacterial count was used to detect both aerobic and anaerobic bacterial load.

Results: The qualitative pain scores revealed statistically significant lower pain levels in the DL group compared with the Endo group at all time intervals (P<0.001), except preoperatively where there was no significant difference. There was a statistically significant lower bacterial count for both aerobic and anaerobic bacteria in the DL group compared with the Endo group in both S3 samples (after laser application) and S4 samples (bacterial colonization) (P<0.001).

Conclusion: The 980 nm diode laser may be a successful adjunct to conventional endodontic treatment of necrotic cases with chronic periapical lesions in terms of postoperative pain and root canal disinfection.




Trail registration: [PACTR201511001275414](https://www.pactr.org/201511001275414) (date: 23rd September 2015)



Keywords

Diode laser, intracanal irradiation, necrotic pulp, periapical lesion, endodontic

Open Peer Review

Reviewer Status   

| | Invited Reviewers | | |
|--|---|---|---|
| | 1 | 2 | 3 |
| version 1 published 15 Nov 2018 |  report |  report |  report |

- Eman H.A. Abouezz** , National Research Centre, Cairo, Egypt
- Patricia da Ana** , Federal University of ABC, Sao Bernardo do Campo, Brazil
- Ibrahim Ethem Yaylali**, Isparta Military Hospital, Isparta, Turkey

Any reports and responses or comments on the article can be found at the end of the article.

Corresponding author: Dina A. Morsy (dina.amorsy@dentistry.cu.edu.eg)

Author roles: **Morsy DA:** Conceptualization, Data Curation, Funding Acquisition, Investigation, Methodology, Resources, Visualization, Writing – Original Draft Preparation, Writing – Review & Editing; **Negm M:** Methodology, Writing – Review & Editing; **Diab A:** Methodology, Writing – Review & Editing; **Ahmed G:** Methodology, Writing – Review & Editing

Competing interests: No competing interests were disclosed.

Grant information: The author(s) declared that no grants were involved in supporting this work.

Copyright: © 2018 Morsy DA *et al.* This is an open access article distributed under the terms of the [Creative Commons Attribution Licence](#), which permits unrestricted use, distribution, and reproduction in any medium, provided the original work is properly cited. Data associated with the article are available under the terms of the [Creative Commons Zero "No rights reserved" data waiver](#) (CC0 1.0 Public domain dedication).

How to cite this article: Morsy DA, Negm M, Diab A and Ahmed G. **Postoperative pain and antibacterial effect of 980 nm diode laser versus conventional endodontic treatment in necrotic teeth with chronic periapical lesions: A randomized control trial [version 1; peer review: 2 approved, 1 approved with reservations]** F1000Research 2018, 7:1795 (<https://doi.org/10.12688/f1000research.16794.1>)

First published: 15 Nov 2018, 7:1795 (<https://doi.org/10.12688/f1000research.16794.1>)

Introduction

The therapeutic goal of endodontic treatment in cases of necrotic teeth with chronic periapical lesions is the creation of a sterile, bacteria-free environment in the tooth and at the apex, including the periodontal tissue and the surrounding apical bone¹. There are two main complicating factors preventing achievement of this goal: the complicated anatomical root configuration and the special characteristics of the resident bacterial flora, which makes it sometimes inaccessible even with recent available armamentarium². In recent years, intracanal laser irradiation has been used in root canal preparation³, gaining acceptance for its disinfection ability as adjunct to the conventional mechanical instrumentation and irrigation protocols available^{4,5}. It was also reported that the use of laser therapy may result in decreased postoperative pain⁶. Recently, the diode laser (DL) 980 nm was introduced and its use in root canal disinfection was established⁴.

Objectives

This study aimed to evaluate the ability of the 980 nm DL to reduce the post-operative pain and intracanal bacteria when compared with conventional endodontic treatment.

Methods

Trial design

This study is a parallel randomized controlled trial, with an allocation ratio of 1:1 and a superiority framework.

This study was approved by the Research Ethics Committee of the Faculty of Oral and Dental Medicine, Cairo University (15-9-19).

This article was written in concordance with the CONSORT checklist 2010 ([Supplementary File 1](#)).

Participants

Patients received in the outpatient clinic of the Endodontic Department, Faculty of Dentistry, Cairo University in the duration between March 2016 and March 2017 were invited to participate. In total 56 participants were included in the study after fulfilling the inclusion criteria and after signing an informed consent.

Inclusion criteria: Adult patients with average age between 18 and 35 years; medically free patients; patients suffering from necrotic pulp in maxillary central incisors permanent teeth with: closed apex, associated with or without sinus tract, radiographic evidence of periapical radiolucency; patients with healthy dental and periodontal status; positive patients' acceptance for participation in the study.

Exclusion criteria: Illiterate patients; pregnant woman (as the hormonal changes may alter the pain perception); patients having systemic disorder; teeth that have: open apex, extra coronal restorations, greater than grade I mobility, pocket depth greater than 4 mm, non restorable tooth, previous endodontic treatment; patients taking analgesics 12 hours before the intervention; patients who had received antibiotics in the last month; patients with acute pain at the time of intervention.

Sample size

To assess DL versus conventional endodontic regarding the postoperative pain, an independent t test was done. It was estimated that a total of 50 patients would be required for the detection of a difference between groups using a two-tailed α of 0.05 and a power of 0.80 if the absolute difference in periapical lesions is 0.37 mm with SD 0.46 as reported in Markovick *et al.* in 2006. To compensate losses during the follow-up this number should be increased to 56 patients (10% more than the calculated). Sample size was calculated using G* Power program (2).

Interventions

All patients were treated by a single endodontic over two visits after signing an informed consent.

First visit. At the first visit, all patients recorded their pain level preoperatively using a numerical rating scale (NRS; see below for details). The teeth were locally anaesthetized (Articaine in 4% solution with epinephrine in concentration of 1:100000 (Ultracaine- dental forte, Germany)

Before isolation, antiseptics of the oral cavity was performed by rinsing for 1 min with 10 mL chlorhexidine gluconate mouth wash 0.2 %. The teeth were properly isolated with rubber dam¹. An access cavity was performed. Patency of the root canal was obtained using stainless steel hand k- files size #15 (MANI-MANI, INC. Industrial Park, Utsunomiya, Tochigi, Japan). The root canals were irrigated with 1 ml sterile saline solution. The first microbial samples (S1) were collected to assess the initial colonizers of the root canals using 3 sterile paper points which were inserted into the root canal for 1 min each with pumping movements. They were immediately placed inside sterile tubes containing a reduced transport medium of thioglycolate. Working length was determined using an electronic apex locator (DENTA PORT ZX (J.Morita, Irvine, Japan)), then confirmed with intraoral periapical radiograph. Mechanical preparation was performed with the ProTaper Universal Ni Ti system up to #F4 file for all the cases. In total 10 ml of 2.5% sodium hypochlorite was used for irrigation between each file and the next using a 25-gauge needle. 5 ml of 17% EDTA (Calix E, DHARMA research, Miami, USA) was used at the end of the procedure to remove the smear layer. 5 ml of saline solution was the final irrigant used to neutralize all the previously used solutions. The second microbial samples (S2) representing the antibacterial effect of the mechanical preparation were obtained with the same procedure as the (S1) samples.

According to the randomization and sequence generation, the patients were allocated into two groups (n = 28/group).

Experimental (DL) group: Root canals were irradiated with 980 nm diode laser coupled with optical fiber 200 μ m (Lite medics, Italy) with setting 1.2-watt power, in pulsed mode. The irradiation protocol was a 5 sec irradiation followed by a 10 sec pause, which constituted one lasing cycle. The lasing cycle was performed four times for each tooth. The tip was positioned 1 mm short of the apex. This was followed by activation during which it was slowly dragged at a speed of approximately

2 mm/ sec in a way that the root canals were irradiated from the apical to the coronal portion, in a helicoidal movement touching the canal walls. This was done to ensure equal diffusion of light inside the root canal lumen (Figure 1). The third microbial samples (S3) were collected as mentioned before to evaluate the effect of DL on the bacterial count.

Control (Endo) group: Conventional endodontic treatment as above, after which the fiber optic was placed inside the root canals without activation (placebo) with no bacterial sample collected at this stage.

At the end of the first visit a piece of sterile cotton was placed in the pulp chamber and all teeth was dressed with intermediate restorative material (IRM) as a temporary filling (Dentsply, Latin America)

Second visit. At the second visit, one week later; the canals of both groups were accessed under rubber dam. Canals were irrigated with 1 ml sterile saline solution. The fourth microbial samples (S4) were taken to assess the recolonization of the bacteria and were collected from both groups. The same procedures of the first visit, the intracanal irradiation for the DL group and placebo for the Endo group was performed. The fifth microbial samples (S5) were collected to assess the status of root canal just before the obturation.

Each root canal was obturated with the modified single cone technique using the ProTaper Universal gutta-percha points size F4 and gutta-percha points size 25 (META, Biomed, Republic of Korea) as auxiliaries with ADSEAL resin-based root canal sealer (META BIOMED CO., LTD. Chungbuuk, Korea). All the teeth were restored with IRM as a temporary filling. At the end of the second visit, all patients were instructed to record pain level on the pain scale chart after 6, 12, 24 and 48 hours and after 7 days. The patients were instructed to submit the pain scale charts after the 7th day. Patients were referred for final restorations. Any patient who reported the intake of an analgesic during this period was excluded from the study.

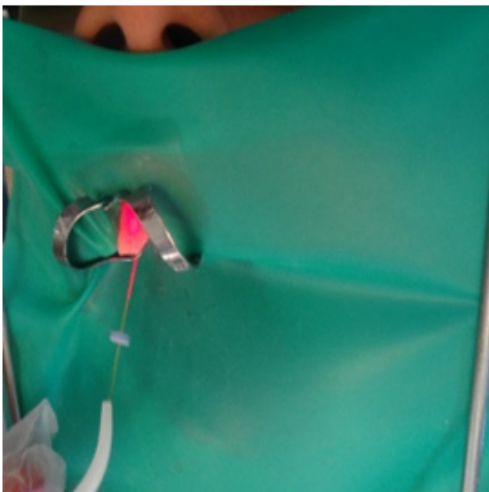


Figure 1. Intracanal application of diode laser.

Primary outcome: Pain evaluation

The NRS consisted of a line anchored by two extremes “No pain” and “the worst pain”. The patients were asked to mark the chart at the point that represented their level of pain from 0 to 10.

Pain level was assigned to one of 4 categorical scores: No pain (0), Mild (1–3), Moderate (4–6) and Severe (7–10).

Secondary outcome: Microbiological analysis

The bacterial count method was used². Once the samples arrived to the microbiology department, Cairo University, the tubes containing the thioglycolate (transport medium) (Thioglycollate broth U.S.P alternative, Oxoid microbiology product, LTD, England) with the paper points were placed in microcentrifuge and vortexed for 30 sec. 100 µl aliquots of the vortexed samples were placed in a new sterile tube containing 1 ml of thioglycolate to obtain 1/10 concentration to assess the microbial load of common aerobes and anaerobes found in each root canal. However, no attempt was made to identify the specific microbial flora during the process. The effect of the treatment in each group, the mechanical preparation (S2), the Diode laser irradiation (S3) in the DL group only, the bacterial recolonization (S4) and the bacterial count just before obturation (S5), were compared.

Aerobic bacterial culture: 50 µl of these diluted samples were transferred to BHI agar plates (Oxoid microbiology product, LTD, England) and cultured under aseptic conditions, followed by incubation at 37° C for 24 hours for the aerobic bacteria. The number of bacterial colonies in each plate was counted and reported as colony forming units per milliliter (CFU/ml).

Anaerobic bacterial culture: The other 50 µl of these diluted samples were transferred to BHI agar plates under aseptic conditions, the agar plates were placed in an anaerobic sealed jar with Gas-Pak (Gas-Pak system) (Oxoid microbiology product, LTD, Basingstoke, Hants, England) and anaerobic indicator (Anaerobic indicator, BR0055B.Oxoid Ltd. Basingstoke, Hants, England) were incubated for 48 hours at 37° C. Eventually, the number of bacterial colonies in each plate was counted and reported as CFU/ml.

Blinding and randomization

Double blinding was implemented in this study by the assessor and the statistician concerning evaluation of the post-operative pain intensity and microbiological evaluation. However, single blinding was implemented only by the statistician concerning the results of periapical lesion size. The blinded assessors were asked to fill a chart for each outcome with the number corresponding to each patient without knowing which group the participants were related to.

A random sequence was generated by computer software (<http://www.random.org/>) in the Center of Evidence Based Dentistry, Cairo University. The table was kept with the assistant supervisor. Four-folded numbered papers were packed in opaque sealed envelopes to be chosen by the patients after entering the study. The opaque envelopes contained the numbers of each random sequence to assign the patient to either the experimental (DL) or control group (Endo).

The assistant supervisor assigned the participants to the experimental or control groups according to the randomization table. After confirmation on patient eligibility with the assistant, the operator applied the treatment procedure assigned to that patient.

Statistical analysis

Statistical analysis was performed using SPSS 19 (SPSS, Chicago, IL, USA). As data related to patients’ age and bacterial colony formation were parametric, significance of the difference between both groups was evaluated using unpaired t test. Chi square test was used to compare the qualitative pain scores. The level of significance was set at P<0.05.

Results

In total, 56 patients were included in the study. A CONSORT flow diagram can be seen in [Supplementary File 2](#).

Demographic data, age and gender, had no significant difference between the two groups (P=0.1967 and 0.053, respectively; [Table 1](#) and [Table 2](#)).

The qualitative pain scores revealed statistically significant lower pain levels in the DL group compared with the Endo group at 6, 12 and 24 hours (P<0.001), and at 48 hours and 7 days (P=0.002 and 0.044, respectively), while preoperatively there was no statistical significance difference (P=1.0) ([Figure 2](#) and [Table 3](#)). The results of the bacterial count of both aerobic and the anaerobic bacteria of the DL group showed statistically significant reduction in the bacterial count than the Endo group at S4 and S5 (Aerobic: P< 0.01 and 0.002, respectively; anaerobic: P< 0.002 and 0.012, respectively; [Figure 3](#) and [Table 4](#) and [Table 5](#)).

Dataset 1. Full de-identified data for each participant, including demographic data, pain scores at all time intervals, and bacterial count of both aerobic and anaerobic bacteria
<https://dx.doi.org/10.5256/f1000research.16794.d224351>

Discussion

This study aimed to evaluate the ability of the 980nm diode laser to decrease postoperative pain and disinfect the root canal and to evaluate whether the diode laser could be a successful adjunctive aid to conventional endodontic treatment.

Over time, various laser types have been developed and are used in different dentistry fields⁷. Among the various lasers, diode lasers are the most frequently used⁸. The active medium of the 980 nm diode laser is a solid-state semiconductor made of indium, gallium and arsenide. Diode lasers have several advantages: extreme compactness, affordability, ease of operation, simple setting-up, versatility and small size⁸. Diode wavelengths are highly absorbed in hemoglobin and melanin and have little absorption in dental hard tissue. They are also highly absorbed by water⁹, which provides the laser with the advantage of acting selectively and precisely⁸.

Table 1. Age of participants.

| Age (years) | Diode laser group | Control group |
|-------------|----------------------|--------------------|
| Mean | 25.28 ^a | 26.25 ^a |
| SD | 5.11 | 5.47 |
| Min | 18 | 18 |
| Max | 35 | 35 |
| t-test | 1.31 | |
| P-value | 0.1967 ^{ns} | |

SD= standard deviation, Min= minimum, Max= Maximum, t=unpaired t test, *: p<0.05 (Significant), ns: P> 0.05 (not significant)

Table 2. Gender distribution of participants.

| Gender | Diode laser group | Control group |
|----------------|---------------------|---------------|
| Male | 14 | 10 |
| Female | 14 | 18 |
| X ² | 3.733 | |
| P-value | 0.053 ^{ns} | |

X²: Chi square test, Significance level: P<0.05, ns: non-significant. SD= standard deviation, Min= minimum, Max= Maximum, t=unpaired t test, *: p<0.05 (Significant), ns: P> 0.05 (not significant)

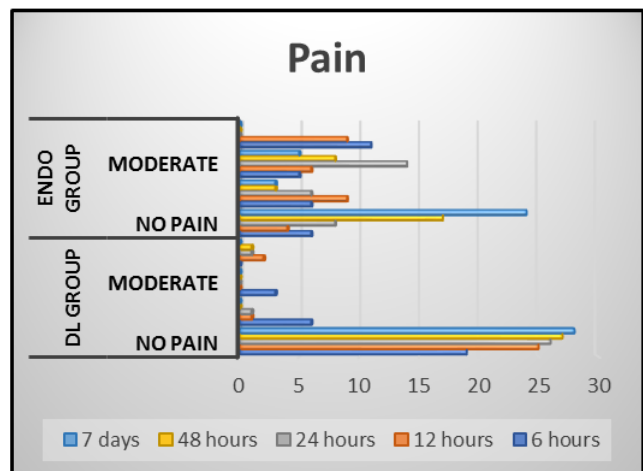


Figure 2. Column chart showing qualitative score of pain in patients enrolled in both groups. Means with different small letters in the same column indicate statistically significance difference, means with different capital letters in the same row indicate statistically significance difference. *: significant (p<0.05), ns: non-significant (p>0.05).

Table 3. Mean and SD values of pain intensity of different time periods within each group.

| | Pain | Pre-operative | 6 hrs | 12hrs | 24hrs | 48hrs | 7 days | X ² | P-value | |
|---------------------|----------------|---------------|---------|---------|---------|--------|--------|----------------|---------|---------|
| Diode laser group | No pain | n | 28 | 19 | 25 | 26 | 28 | 33.25 | <0.001* | |
| | | % | 100 | 67.9 | 89.3 | 92.9 | 100 | | | 100 |
| | Mild | n | 0 | 6 | 1 | 1 | 0 | | | 0 |
| | | % | 0 | 21.4 | 3.6 | 3.6 | | | | |
| | Mod | n | 0 | 3 | 0 | 1 | 0 | | | 0 |
| | | % | 0 | 10.7 | | 3.6 | | | | |
| | Severe | n | 0 | 0 | 2 | 0 | 0 | | | 0 |
| | | % | 0 | | 7.2 | | | | | |
| Control group | No pain | n | 28 | 6 | 4 | 8 | 17 | 24 | 65.93 | <0.001* |
| | | % | 100 | 21.4 | 14.3 | 28.6 | 60.7 | 85.7 | | |
| | Mild | n | 0 | 6 | 9 | 6 | 3 | 3 | | |
| | | % | 0 | 21.4 | 32.1 | 21.4 | 10.7 | 10.7 | | |
| | Mod | n | 0 | 5 | 6 | 14 | 8 | 1 | | |
| | | % | 0 | 17.9 | 21.4 | 50 | 28.6 | 3.6 | | |
| | Severe | n | 0 | 11 | 9 | 0 | 0 | 0 | | |
| | | % | 0 | 39.4 | 32.1 | | | | | |
| X ² test | X ² | 3.744 | 18.26 | 34 | 28.101 | 14.273 | 8.077 | | | |
| | P-value | 1 | <0.001* | <0.001* | <0.001* | 0.002* | 0.044* | | | |

DL: Diode laser group, ES: endosurgery group, hrs: hours, n: number of patients, %: percentage of patients, mod: moderate pain, SD, standard deviation. X²: Chi square test, significance level: P<0.05, *significant

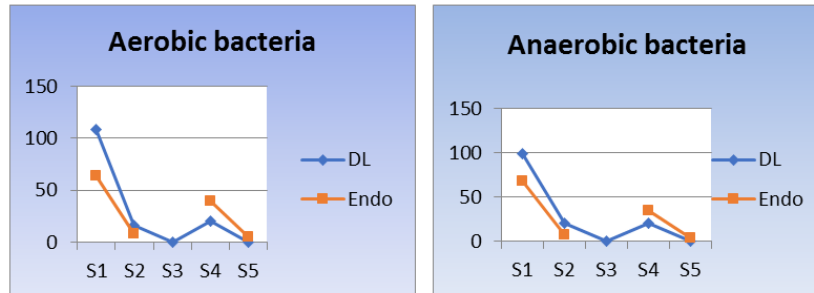


Figure 3. Line chart showing bacterial count (a) aerobic and (b) anaerobic. Means with different small letters in the same column indicate statistically significance difference, means with different capital letters in the same row indicate statistically significance difference. *: significant (p<0.05), ns; non-significant (p>0.05).

Table 4. Mean and standard deviation values of the bacterial count (CFU/ml ×10⁴) of aerobic bacteria of different groups.

| Variables | Aerobic bacteria | | | | |
|-----------|----------------------|-------|---------------------|-------|---------|
| | Diode laser group | | Control group | | P-value |
| | Mean | SD | Mean | SD | |
| S1 | 108.21 ^{aA} | 36.05 | 63.50 ^{aB} | 18.77 | 0.012* |
| S2 | 16.00 ^{cA} | 4.42 | 8.29 ^{cB} | 2.99 | 0.006* |
| S3 | 0.286 ^{dC} | 0.09 | - | - | <0.001* |
| S4 | 13.678 ^{bB} | 10.77 | 40.25 ^{bA} | 38.45 | 0.01* |
| S5 | 0.00 ^{dB} | 0.00 | 5.25 ^{dA} | 1.04 | 0.002* |
| P-value | < 0.001* | | < 0.001* | | |

Table 5. Mean and standard deviation values of the bacterial count (CFU/ml $\times 10^4$) of anaerobic bacteria of different groups.

| Variables | Anaerobic bacteria | | | | | |
|-----------|----------------------|-------|----------------------|-------|---------|---------|
| | Diode laser group | | Control group | | P-value | |
| | Mean | SD | Mean | SD | | |
| S1 | 98.79 ^{aA} | 31.37 | 67.50 ^{aB} | 16.12 | 0.047* | |
| S2 | 19.750 ^{cA} | 6.79 | 7.32 ^{cB} | 2.32 | 0.016* | <0.001* |
| S3 | 0.036 ^{dC} | 0.009 | - | - | - | |
| S4 | 8.75 ^{bB} | 7.428 | 36.607 ^{bA} | 11.68 | 0.002* | |
| S5 | 0.00 ^{dB} | 0.00 | 3.61 ^{dA} | 1.09 | 0.012* | |
| P-value | < 0.001* | | < 0.001* | | | |

In the present study, the intracanal irradiation was done using the pulsed mode to decrease the risk of thermal damage on external root surface and thus decrease the postoperative pain and favor healing of periapical area¹⁰. The temperature on the root canal walls rapidly decreases as the intracanal irradiation with the activated 200 μm fiber-optic is directed from apical to coronal direction rapidly. Thus, guaranteeing that the surrounding tissue is only marginally affected and damage of periodontal tissues or the underlying bone should not be expected⁹.

The 980 nm diode laser use an optical flexible fiber 200 μm to deliver the beam to the target area, probably distributing homogeneously the light inside the root canal for a more efficient photoreaction⁷. Garcez *et al.*¹¹ achieved higher antimicrobial effect when they used the optical fiber in disinfection of the root canal. Diode lasers have demonstrated excellent clinical benefits¹².

In this study, the NRS scale was used to record postoperative pain. Jamison *et al.*¹³, reported that, the NRS has greater sensitivity to change in pain intensity. Amelia and Barbara¹⁴ reported that the NRS represents interval levels so it can provide data for parametric analysis.

The results of this study showed that the DL group had statistically significant lower pain levels than the Endo group at all tested time intervals (6, 12, 24, 48 hours and 7 days). These results are in accordance with the findings of Berk *et al.*¹⁵ and Pawar *et al.*¹⁶, who reported that the use of diode laser in root canal irradiation showed significantly lower pain at 8, 24, 48 hours and 7 days postoperatively when compared to conventional treatment. Tuner *et al.*¹⁷, found that, usually after conventional RCT of chronic cases, which is the situation in this trial, the case become acute when the process of healing starts, thus patients are at risk of experiencing postoperative pain which was not the situation in the DL group. The exact mechanism by which the use of laser results in decreasing post-operative pain is still unknown. Some authors proposed some mechanisms by

which the diode laser relieves pain: Pawar *et al.*¹⁶ and Bjordal *et al.*¹⁸ found that the diode laser acts on chronic pain and has an anti-inflammatory effect by decreasing PGE2, bradykinin, histamine, acetyl choline and serotonin, also the diode laser was proved to decrease the production of substance P. Our results concerning postoperative pain in the cases of chronic apical periodontitis, when treated with diode laser, showed promising results.

It is generally accepted that the development of periapical diseases are pathologic features of polymicrobial bacterial infection and its components which stimulate bone resorption¹⁹. Thus, in this study the effect of the treatment on both the aerobic and the anaerobic bacterial count were assessed following the same methodology of Garcez *et al.*²⁰ and Bonsor *et al.*² This technique was selected due to its ability to detect exclusively the viable bacteria and also the correlation proved previously, by many studies^{21,22}, between negative cultures at time of obturation and more favorable treatment outcomes.

In this study, the antibacterial results showed statistically significant lower bacterial count in the S3 samples of DL group than the S2 samples of both groups. It also showed significantly lower bacterial recolonization in S4 samples of the DL group than the Endo group. The S5 samples of the DL group resulted in significantly lower bacterial count than the Endo group, which may favor the treatment outcomes^{21,22}. Our findings are in accordance with the findings of Garcez *et al.*¹¹ and Gutknecht *et al.*⁴, who found that the use of diode laser resulted in significant decrease of the intracanal bacterial load. The high antibacterial effect of diode laser may be explained by the fact that the near infrared lasers are absorbed to small extent by dentin. This is important for the efficient disinfection as the laser is not absorbed by the superficial dentin but rather penetrates deep into the intertubular dentin¹. Vaarkamp *et al.*²³ and Odor *et al.*²⁴ provided an explanation for this way of light propagation, as they described the ability of enamel prisms and dentinal tubules to act as an optical fiber and thus allowing the diode laser to be more

effective in deep layers of dentin. According to Gutknecht *et al.* in 2008⁹, the ND: YAG, 810 nm diode laser and 980 nm diode laser are the only wavelengths that showed high transmission through hydroxyapatite and water. Thus, it can be used successfully for the disinfection of root canals.

Diode laser radiation has a bactericidal effect by altering the bacterial cell wall. Microbiologists²⁵ talk about a permanent destruction of the cell membrane, which is commonly in correlation with direct heat having an impact on the bacteria. The diode laser exerts a photo-thermal effect on the bacteria²⁶. It also, exerts a photo-disruptive effect on the unreachable bacteria²⁶.

Gutknecht *et al.*⁴ demonstrated that diode laser light can penetrate up to >1000 µm into the dentin. Thus, it can be an effective means for disinfection of the root canal system together with conventional biomechanical instrumentation reaching areas, which were considered earlier non-reachable.

Strengths and limitations

This study is a randomized clinical trial conducted on a relatively big sample size patients, in real clinical settings and was conducted efficiently. It proposes an alternative way for treatment of necrotic teeth with chronic periapical lesions efficiently and without postoperative pain.

The following limitations should be considered: this study didn't evaluate if there is a difference between single visit or two visit approach when the intracanal diode laser is used on postoperative

pain and bacterial count of necrotic teeth with chronic periapical lesions.

Further *in vivo* and immunological studies are needed to identify the exact mechanism by which the intracanal Diode laser resulted in decreasing postoperative pain.

Conclusions

Intracanal diode laser irradiation has the ability to decrease the postoperative pain experienced after conventional root canal treatment in cases of necrotic teeth with periapical lesions. Implementation of suitable wavelengths, together with conventional methods of cleaning and shaping, can effectively sterilize the root canals, dentin and periapical area and decrease the bacterial recolonization. Thus, based on the findings of this study, it may be concluded that the 980 nm diode laser can be used as an adjunct to conventional endodontic therapy.

Data availability

F1000Research: Dataset 1. Full de-identified data for each participant, including demographic data, pain scores at all time intervals, and bacterial count of both aerobic and anaerobic bacteria., <https://doi.org/10.5256/f1000research.16794.d224351>²⁷

Grant information

The author(s) declared that no grants were involved in supporting this work.

Supplementary material

Supplementary File 1: Completed CONSORT checklist.

[Click here to access the data](#)

Supplementary File 2: CONSORT flow diagram.

[Click here to access the data](#)

Supplementary File 2: Full study protocol.

[Click here to access the data](#)

References

- Asnaashari M, Asnaashari N: **Clinical application of 810nm diode laser and low-level laser therapy for treating an endodontic problem: A case presentation.** *Lasers Med Sci.* 2011; **2**: 82–86. [PubMed Abstract](#) | [Publisher Full Text](#)
- Bonsor SJ, Nichol R, Reid TM, *et al.*: **Microbiological evaluation of photo-activated disinfection in endodontics (an *in vivo* study).** *Br Dent J.* 2006; **200**(6): 337–41, discussion 329. [PubMed Abstract](#) | [Publisher Full Text](#)
- Moritz A, Gutknecht N, Goharkhay K, *et al.*: ***In vitro* irradiation of infected root canals with a diode laser: results of microbiologic, infrared spectrometric, and stain penetration examinations.** *Quintessence Int.* 1997; **28**(3): 205–9. [PubMed Abstract](#)
- Gutknecht N, Franzen R, Schippers M, *et al.*: **Bactericidal effect of a 980-nm diode laser in the root canal wall dentin of bovine teeth.** *J Clin Laser Med Surg.* 2004; **22**(1): 9–13. [PubMed Abstract](#) | [Publisher Full Text](#)
- Beer F, Buchmair A, Wernisch J, *et al.*: **Comparison of two diode lasers on bactericidity in root canals—an *in vitro* study.** *Lasers Med Sci.* 2012; **27**(2): 361–4. [PubMed Abstract](#) | [Publisher Full Text](#)
- Koba K, Kimura Y, Matsumoto K, *et al.*: **Post-operative symptoms and healing after endodontic treatment of infected teeth using pulsed Nd:YAG laser.** *Endod Dent Traumatol.* 1999; **15**(2): 68–72. [PubMed Abstract](#) | [Publisher Full Text](#)
- Pimat S: **Versatility of an 810-nm diode laser in dentistry: An overview.** *Journal of the Laser and Health Academy.* 2007; **4**: 1–9. [Reference Source](#)

8. Maturò P, Perugia C, Docimo R: **Versatility of an 810 Nm Diode laser in pediatric dentistry.** *International Journal of Clinical Dentistry.* 2013; **6**: 161–72.
[Reference Source](#)
9. Gutknecht N: **Lasers in endodontics.** *Journal of the Laser and Health Academy.* 2008; **4**: 1–5.
[Reference Source](#)
10. Gutknecht N, Franzen R, Meister J, *et al.*: **Temperature evolution on human teeth root surface after diode laser assisted endodontic treatment.** *Lasers Med Sci.* 2005; **20**(2): 99–103.
[PubMed Abstract](#) | [Publisher Full Text](#)
11. Silva Garcez A, Núñez SC, Lage-Marques JL, *et al.*: **Efficiency of NaOCl and laser-assisted photosensitization on the reduction of Enterococcus faecalis in vitro.** *Oral Surg Oral Med Oral Pathol Oral Radiol Endod.* 2006; **102**(4): e93–8.
[PubMed Abstract](#) | [Publisher Full Text](#)
12. Goharkhay K, Moritz A, Wilder-Smith P, *et al.*: **Effects on oral soft tissue produced by a diode laser in vitro.** *Lasers Surg Med.* 1999; **25**(5): 401–6.
[PubMed Abstract](#) | [Publisher Full Text](#)
13. Jamison RN, Gracely RH, Raymond SA, *et al.*: **Comparative study of electronic vs. paper VAS ratings: a randomized, crossover trial using healthy volunteers.** *Pain.* 2002; **99**(1–2): 341–7.
[PubMed Abstract](#) | [Publisher Full Text](#)
14. Amelia W, Barbara H: **Pain: A review of three commonly used pain rating scales.** *Journal of Clinical Nursing.* 2005; **14**(7): 789–804.
[PubMed Abstract](#) | [Publisher Full Text](#)
15. Berk G, Ulucam U, Berk N: **Clinical healing process and symptoms of two cases of chronic periapical lesions treated with Er, Cr:YSGG laser.** *Journal of Oral Laser Application.* 2004; **4**: 211–5.
[Reference Source](#)
16. Pawar S, Pujar M, Makandar S, *et al.*: **Postendodontic treatment pain management with low-level laser therapy.** *Journal of Dental Lasers.* 2014; **8**(2): 60–3.
[Reference Source](#)
17. Tuner J, Hode L: **The laser therapy handbook, Sweden, Prima Book AB.** 2007.
18. Bjordal JM, Johnson MI, Iversen V, *et al.*: **Low-level laser therapy in acute pain: A systematic review of possible mechanisms of action and clinical effects in randomized placebo-controlled trials.** *Photomedicine and Laser Surgery.* 2006; **24**(2): 158–68.
[PubMed Abstract](#) | [Publisher Full Text](#)
19. Stashenko P: **Role of immune cytokines in the pathogenesis of periapical lesions.** *Endod Dent Traumatol.* 1990; **6**(3): 89–96.
[PubMed Abstract](#) | [Publisher Full Text](#)
20. Garcez AS, Núñez SC, Hamblin MR, *et al.*: **Antimicrobial effects of photodynamic therapy on patients with necrotic pulps and periapical lesion.** *J Endod.* 2008; **34**(2): 138–42.
[PubMed Abstract](#) | [Publisher Full Text](#) | [Free Full Text](#)
21. Sjögren U, Figdor D, Persson S, *et al.*: **Influence of infection at the time of root filling on the outcome of endodontic treatment of teeth with apical periodontitis.** *Int Endod J.* 1997; **30**(5): 297–306.
[PubMed Abstract](#) | [Publisher Full Text](#)
22. Waltimo T, Trope M, Haapasalo M, *et al.*: **Clinical efficacy of treatment procedures in endodontic infection control and one year follow-up of periapical healing.** *J Endod.* 2005; **31**(12): 863–6.
[PubMed Abstract](#) | [Publisher Full Text](#)
23. Vaarkamp J, Bosch JJ, Verdonchot EH: **Propagation of light through human dental enamel and dentine.** *Caries Res.* 1995; **29**(1): 8–13.
[PubMed Abstract](#) | [Publisher Full Text](#)
24. Odor TM, Watson TF, Pitt Ford TR, *et al.*: **Pattern of transmission of laser light in teeth.** *Int Endod J.* 1996; **29**(4): 228–34.
[PubMed Abstract](#) | [Publisher Full Text](#)
25. Ahmeduddin M, Nagesh B, Reddy KN, *et al.*: **An assessment of bactericidal effect of two different types of lasers on enterococcus faecalis: An in vitro study.** *Journal of Dental Lasers.* 2012; **6**(1): 2–6.
[Publisher Full Text](#)
26. Preethee T, Kandaswamy D, Arathi G, *et al.*: **Bactericidal effect of the 908 nm diode laser on Enterococcus faecalis in infected root canals.** *J Conserv Dent.* 2012; **15**(1): 46–50.
[PubMed Abstract](#) | [Publisher Full Text](#) | [Free Full Text](#)
27. Morsy DA, Negm M, Diab A, *et al.*: **Dataset 1 in: Postoperative pain and antibacterial effect of 980 nm diode laser versus conventional endodontic treatment in necrotic teeth with chronic periapical lesions: A randomized control trial.** *F1000Research.* 2018.
<http://www.doi.org/10.5256/f1000research.16794.d224351>

Open Peer Review

Current Peer Review Status:



Version 1

Reviewer Report 25 July 2019

<https://doi.org/10.5256/f1000research.18360.r49690>

© 2019 Yaylali I. This is an open access peer review report distributed under the terms of the [Creative Commons Attribution Licence](#), which permits unrestricted use, distribution, and reproduction in any medium, provided the original work is properly cited.



Ibrahim Ethem Yaylali

Department of Dentistry, Isparta Military Hospital, Isparta, Turkey

Introduction:

There is a lack of information about the previously performed studies. The authors should clearly and briefly describe the existing studies, which have been done so far. Why did the authors perform this study? Which gaps was/were exist in the field of postoperative pain evaluation when diode lasers are used? What was the Null hypothesis? All should be described in the Introduction. The power analysis is adequate.

Methods:

Allocation concealment and sequence generation were described adequately.

Results:

Demographic and baseline characteristics (mean age, sex, education, etc) of the patients can be showed in one Table so that Table 1 and Table 2 can be removed.

Discussion:

In the Discussion, the second paragraph is unnecessary. It can be completely removed and can be add to the Introduction.

Is the work clearly and accurately presented and does it cite the current literature?

No

Is the study design appropriate and is the work technically sound?

Yes

Are sufficient details of methods and analysis provided to allow replication by others?

Yes

If applicable, is the statistical analysis and its interpretation appropriate?

Yes

Are all the source data underlying the results available to ensure full reproducibility?

Yes

Are the conclusions drawn adequately supported by the results?

Yes

Competing Interests: No competing interests were disclosed.

Reviewer Expertise: Evidence-based medicine.

I confirm that I have read this submission and believe that I have an appropriate level of expertise to confirm that it is of an acceptable scientific standard.

Reviewer Report 04 July 2019

<https://doi.org/10.5256/f1000research.18360.r49584>

© 2019 da Ana P. This is an open access peer review report distributed under the terms of the [Creative Commons Attribution Licence](#), which permits unrestricted use, distribution, and reproduction in any medium, provided the original work is properly cited.



Patricia da Ana 

Center for Engineering, Modeling and Applied Social Sciences, Federal University of ABC, Sao Bernardo do Campo, Brazil

This is a well-written and well-conducted article with clear problem and objective. For indexing, it is suggested some changes, described below:

1. There are many recent published papers that report the clinical efficacy of diode laser in endodontic treatment (see Genc Sen and, Kaya 2019¹). In this way, the authors need to make clear in the introduction what is the innovation that this manuscript presents.
2. References need to be more up-to-date. There is no citation of any article published in the last 5 years.
3. The authors should pay attention to the citations. In the last sentence of the introduction, they comment that the use of the diode laser in endodontics was recently established, but they cite a 2004 reference.
4. Please replace the abbreviation of units using capital letters; for example, ml to mL, watt to Watt.
5. Please give references to the laser protocol used. Are there studies in the literature based on temperature increases generated in the root canal using such parameters? What are the observed values? Comment on their safety for the periodontal ligaments in the discussion.
6. The authors do not explain how they ensured periods of pain assessment.

7. Please correct the neodymium laser nomenclature. The correct one is Nd:YAG.
8. Please explain why there was no bacterial collection in the S3 period of the placebo group. Discuss whether the insertion of the laser fiber may have exerted some mechanical removal of the biofilm.
9. Please correct the captions of all the figures and tables. There are legends that mention letters and asterisks, but there is nothing in the figure (e.g., Figure 2), while Tables 4 and 5 do not explain what upper and lower case letters refer to.

References

1. Genc Sen O, Kaya M: Effect of Root Canal Disinfection with a Diode Laser on Postoperative Pain After Endodontic Retreatment. *Photobiomodul Photomed Laser Surg.* 2019; **37** (2): 85-90 [PubMed Abstract](#) | [Publisher Full Text](#)

Is the work clearly and accurately presented and does it cite the current literature?

Partly

Is the study design appropriate and is the work technically sound?

Yes

Are sufficient details of methods and analysis provided to allow replication by others?

Yes

If applicable, is the statistical analysis and its interpretation appropriate?

Yes

Are all the source data underlying the results available to ensure full reproducibility?

Yes

Are the conclusions drawn adequately supported by the results?

Yes

Competing Interests: No competing interests were disclosed.

Reviewer Expertise: Dentistry and lasers applications in dental tissues

I confirm that I have read this submission and believe that I have an appropriate level of expertise to confirm that it is of an acceptable scientific standard, however I have significant reservations, as outlined above.

Reviewer Report 03 December 2018

<https://doi.org/10.5256/f1000research.18360.r40677>

© 2018 Aboulezz E. This is an open access peer review report distributed under the terms of the [Creative Commons Attribution Licence](#), which permits unrestricted use, distribution, and reproduction in any medium, provided the original work is properly cited.



Eman H.A. Aboulezz 

Basic Dental Science Department, Oro-dental Research Division, National Research Centre, Cairo, Egypt

After reviewing the manuscript entitled 'Posteroperative pain and antibacterial effect of 980nm diode laser versus conventional nedodontic treatment in necrotic teeth with chronic periapical lesions:A randomized control trial', I have found that it is such an outstanding article overall. It provides a comprehensive examination of a complex subject; providing new options in treatment of such an inevitable problem. A detailed description of the manuscript will be as follows:

Introduction: which was a well-written and covering more than enough of the relevant theoretical data of literature.

Aim of the study: Here the author stated the objectives and goals of the study in an appropriate manner.

In the Methods: the author gave a detailed description of the employed methodology of the investigation. It was very well elaborated and relevant to the aim of the study.

Results: The results were well organized into different categories; this section included tables and charts. All of which help the reader get a clear detailed insight of the different aspects occurring within the two groups of patients.

Discussion: the author in this chapter was successful in showing logical overall arguments and used appropriate number of bibliography sources. This shows that the author developed a deep understanding of the theoretical knowledge and the discussed problems.

Conclusion: The manuscript provides a relevant summary of the subject, methodology and results.

References: They were organized and included a lot of recent publications.

Generally, this manuscript meets all the basic requirements of good research and demonstrates coherence between theoretical position, problem presented and the methodology appointed. The author showed in this manuscript a significant level of understanding and analytical ability. I find the work innovative and recommend indexing it.

Is the work clearly and accurately presented and does it cite the current literature?

Yes

Is the study design appropriate and is the work technically sound?

Yes

Are sufficient details of methods and analysis provided to allow replication by others?

Yes

If applicable, is the statistical analysis and its interpretation appropriate?

Yes

Are all the source data underlying the results available to ensure full reproducibility?

Yes

Are the conclusions drawn adequately supported by the results?

Yes

Competing Interests: No competing interests were disclosed.

I confirm that I have read this submission and believe that I have an appropriate level of expertise to confirm that it is of an acceptable scientific standard.

The benefits of publishing with F1000Research:

- Your article is published within days, with no editorial bias
- You can publish traditional articles, null/negative results, case reports, data notes and more
- The peer review process is transparent and collaborative
- Your article is indexed in PubMed after passing peer review
- Dedicated customer support at every stage

For pre-submission enquiries, contact research@f1000.com

F1000Research