

Received: 2019.02.26

Accepted: 2019.03.25

Published: 2019.07.19

Outcomes of Vacuum Sealing Drainage Treatment Combined with Skin Flap Transplantation and Antibiotic Bone Cement on Chronic Tibia Osteomyelitis: A Case Series Study

Authors' Contribution:

Study Design A

Data Collection B

Statistical Analysis C

Data Interpretation D

Manuscript Preparation E

Literature Search F

Funds Collection G

CEF **Jingfeng Li**

BF **Hao Zhang**

BCF **Baiwen Qi**

AD **Zhenyu Pan**

Department of Orthopedics, Zhongnan Hospital of Wuhan University, Wuhan, Hubei, P.R. China

Corresponding Author: Zhenyu Pan, e-mail: soloistp@126.com

Source of support: Departmental sources

Background: Chronic osteomyelitis is one of the currently refractory diseases. The aim of this study is to discuss the method and curative effects of vacuum sealing drainage (VSD) treatment combined with skin flap transplantation and antibiotic bone cement for chronic tibia osteomyelitis.

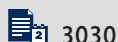
Material/Methods: For this study, 18 cases of open fracture secondary chronic tibia osteomyelitis were selected. After the granulation tissue of the wound surface became fresh and infection was controlled, the wound surface was repaired with a medial head of gastrocnemius transfer flap or a myofascial and cutaneous island pedicle flap with a collateral vessel nourished by the retrograde sural nerve. VSD combined with focus debridement and antibiotic bone cement filling was conducted. After inflammation was completely regulated, elective bone cement extraction, bone grafting, and internal fixation were performed. Within 2 to 3 years of follow-up post-surgery, the satisfaction and recurrence rates were evaluated. The patients' pre-operative and post-operative recovery of limb functions were compared according to the Enneking scoring system.

Results: The patients did not suffer from osteomyelitis recurrence, with the exception of 1 case that manifested osteomyelitis recurrence and recovered through surgical treatment within the period of follow-up. The satisfaction and recurrence rates of these study cases post-surgery were 94.4% and 5.6%, respectively. The average functional recovery post-surgery was 81.5% of normal function.

Conclusions: Vacuum sealing drainage combined with skin flap transplantation and antibiotic bone cement is an effective treatment for chronic tibia osteomyelitis.

MeSH Keywords: **Bone Cements • Drainage • Osteomyelitis • Skin Transplantation**

Full-text PDF: <https://www.medscimonit.com/abstract/index/idArt/915921>



3030



1



1



31



Background

With rapid social development, open fractures and internal fixations have become the main causes of infection that lead to chronic osteomyelitis [1–3]. Chronic osteomyelitis is mainly a consequence of improper or delayed treatment for acute osteomyelitis. The morbidity of tibia osteomyelitis combined with bone exposure is much higher than that of other sites because the soft tissue coverage of the anterior tibia is limited and blood circulation is poor [4,5]. This phenomenon is usually manifested in various conditions, such as long-term suppuration in the anterior shank or the internal sinus tract, bone defect and exposure, or fracture non-union with massive sequestrum [6]. Chronic tibia osteomyelitis with a wound surface that is difficult to heal is one of the problems in current clinical orthopedic treatment. If this condition is not treated promptly, chronic sinus infection, skin scar formation or scar contracture, skin defect, bone fracture, and bone defect will likely occur, which might possibly lead to a high failure rate of surgery and high incidence rate of infection. Consequently, these problems will impart mental and economic problems on patients [7,8].

Post-traumatic chronic osteomyelitis is a type of chronic persistent disease that frequently occurs clinically with a long disease course. It easily relapses, but it is difficult to treat [9]. In conventional therapeutic methods, an antibiotic solution is flushed after focus debridement. However, flushing requires a long period (2 to 4 weeks). Bacteria can become resistant to antibiotics, leading to unsatisfactory curative effects [10,11].

In this study, 18 patients with chronic tibia osteomyelitis underwent vacuum sealing drainage (VSD) treatment combined with skin flap transplantation and antibiotic bone cement in our hospital from March 2012 to February 2015. In 2–3 years of follow-up visits after surgery, 1 patient experienced osteomyelitis recurrence, whereas the rest of the patients received satisfactory curative effects.

In this report we discussed the method and curative effects of VSD treatment combined with skin flap transplantation and antibiotic bone cement for chronic tibia osteomyelitis.

Material and Methods

Ethics approval and consent to participate

This study was approved by the ethics committee of our hospital and was performed according to the ethical standards outlined by the 1964 Declaration of Helsinki and its later amendments or comparable ethical standards. Informed consent was obtained from all individual participants included in our study.

Clinical data

In this study, 18 patients aged 14–57 years with open fractures secondary to chronic tibia osteomyelitis were included. All patients did not suffer from internal diseases such as diabetes or rheumatoid diseases. Among these patients, 12 were male and 6 were female. Ten patients suffered from injuries on the left side, and 8 patients suffered injuries on the right side. Seven cases were at the superior segment, 6 cases at the middle segment, and 5 cases at the inferior segment. Eleven cases were caused by traffic injury, and in 7 cases the injury was caused by being hit with a heavy object. In general, the original wound swelled at 2–6 months after initial treatment. Some fistula sinus tracts formed, suppuration was unhealed for a long time, the wound surface was enlarged, the minimum wound area was 6.0×3.5 cm, the maximum wound area was 12.0×7.0 cm, and no blood supply was found in the skin. The bacterial culture and drug sensitivity tests showed that 18 cases were positive in the primary bacterial culture and 11 cases were positive in the secondary culture. The bacterial types were as follows successively: *Staphylococcus aureus* in 7 cases (38.9%), colon bacillus in 9 cases (50%), and *Pseudomonas aeruginosa* in 2 cases (11.1%). The patients were provided with a conventional treatment of a sensitive antibiotic for 2 weeks before surgery.

Surgical methods

Removal of osteomyelitis lesions + tibia external fixation + VSD coverage

Methylene blue (2–3 mL) was injected into the sinus tract to stain the focus sequestrum. Surgery was then conducted with a pneumatic tourniquet without blood evacuation. An incision was made at the external side of the anterior shank. The fistula, inflammatory granulation, and scar tissues were removed, and the sequestrum chunk was excised. A small curette was used to completely eliminate inflammatory granulation tissues in the remaining dead space and the sequestrum patch stained with methylene blue. Afterward, the wound was flushed alternately with 3% hydrogen peroxide, diluted povidone iodine, and normal saline for 3 times. The attached sub-healthy tissues were removed again. The sclerotic bone at the end of the fracture was also eradicated, and the marrow cavity was excavated. The nervous tissue of the blood vessel was protected, and tibia external fixation was performed. Exsanguination bands were loosened, and a hot brine gauze was filled for hemostasis. The wound was flushed, and complete hemostasis was conducted through electrocoagulation. VSD coverage was provided for the wound. After the VSD dressing was removed, the wound surface became fresh and covered with a new granulation tissue. The optimal surgical timing for the skin flap transplantation was the time when bacterial

culture from tissue was negative. If there were remaining necrotic tissues, VSD treatment was repeated until the wound surface was fresh and covered with new granulation tissues.

Skin flap transplantation + antibiotic bone cement + VSD coverage

The flap type was designed according to the tibia defect and bone exposure scope and location. The location of the skin flap was marked. During surgery, the scar covering the bone was excised, and the hematocoele was drawn from the marrow cavity. Necrotic sclerotin around the focus of the marrow cavity and inflammatory granulation tissues was scraped until the sclerotin was covered with fresh tissues only. The focus was then thoroughly removed, and the wound was repeatedly flushed. The bone defect was filled with an appropriate amount of antibiotic vancomycin loaded with poly (methyl methacrylate, Heraeus Medical GmbH, Germany) bone cement. Soft tissues of the skin were incised along the marking, and the pedicle flap was carefully dissociated. The distal end skin flap of the gastrocnemius medial head or the myofascial and cutaneous island pedicle flap with a collateral vessel nourished by the retrograde sural nerve was covered on the wound surface at the interior shin. The bone cement filled in the tibia defect could be observed through x-ray radiography. The muscles on the periphery fascia were fixed, and the skin flap on the periphery skin was sutured without tension. The remaining defects were covered with artificial skin, while the wound surface was covered with VSD suture and fixed on the periphery skin. Vacuum aspiration was continuously performed.

Evaluation of the curative effect

The patients' general condition and their satisfaction and recurrence rates after treatment for chronic tibia osteomyelitis were observed.

The patients were rated excellent if the following conditions were observed: no local swelling, heat, and pain; closed sinus tract; no local tenderness; no new focus found in the affected region through x-ray radiography; affected bone segment recovery; and wide marrow cavity. The patients were rated good if the following conditions were observed: occasional pain in local regions; no swelling, heat, and pain; no pathological features detected through x-ray radiography; and affected bone segment recovery. The patients were rated poor if the following conditions were observed: local swelling, heat, and pain; open sinus tract with seepage; and focus revealed by x-ray radiography.

Evaluation of limb functions

Scoring was performed before and after surgery according to Enneking scores with 6 indexes [12]: limb pain, activity

function, self-perception, brace application, walking ability, and gait change. Each item yielded 5 scores. The percentage was obtained by dividing the total scores of the 6 indexes by a full mark of 30 scores. The obtained value corresponded to the percentage of the affected limb that reached normal limb functions.

Statistical analysis

The values were presented as arithmetic mean \pm standard deviation. Paired-sample *t*-test was used for the statistical analyses of age and gender, and Enneking scores were used for the statistical analyses of Frankel grades. All analyses were performed using the Statistical Package for the Social Sciences software (SPSS 19.0; SPSS Inc., Chicago, IL, USA), and differences were considered statistically significant when $P < 0.05$.

Results

Of the 18 patients, 2 patients experienced necrosis in the distal margin of the incised flap after surgery, and 2 patients suffered from venous crisis because of the compression induced by the tight suture at the pedicle flap 2 days after surgery. However, the flap survived after expectant treatment was administered. In the 14 remaining patients, the flap survived successfully, and all incisions exhibited primary healing. All 18 cases were followed for 2–3 years (average 29.7 months). The color of the transplanted skin flap was similar to that of the skin periphery with good texture. After VSD combined with focus debridement and antibiotic bone cement was applied, the patients did not suffer from osteomyelitis recurrence, except in 1 case with osteomyelitis recurrence that healed through surgical treatment. The surgical curative effects of the cases were as follows: 11 cases were excellent, 6 cases were good, and 1 case was poor. The satisfaction and recurrence rates were 94.4% and 5.6%, respectively.

The pre-operative and post-operative function scores of the cases were 9.78 ± 1.26 and 24.44 ± 4.27 , respectively. The average post-operative functional recovery was 81.5% of the normal function. Nine cases (50.5%) yielded a score of 26–30, 7 cases (38.9%) obtained a score of 21–25, 1 case (5.6%) achieved a score of 16–20, and 1 case (5.6%) attained a score less than 16. The pre-operative function scores were significantly different from the post-operative function scores, and the surgical curative effect was satisfactory (Table 1, Figure 1).

Discussions

Thorough debridement is the premise for chronic osteomyelitis treatment [13]. Previous debridement methods for patients with

Table 1. Patient data and results.

| Patient No. | Gender | Age (Y) | Leg (L or R) | Location | Follow-up time | Efficacy | Enneking scores | |
|-------------|--------|---------|--------------|----------|----------------|-----------|-----------------|------------|
| | | | | | | | Pre-oper | Post-oper* |
| 1 | M | 36 | L | Middle | 28 | Excellent | 11 | 28 |
| 2 | M | 40 | L | Proximal | 30 | Excellent | 12 | 30 |
| 3 | M | 25 | R | Proximal | 24 | Excellent | 10 | 23 |
| 4 | F | 41 | R | Distal | 27 | Good | 9 | 22 |
| 5 | M | 14 | L | Proximal | 24 | Good | 10 | 27 |
| 6 | M | 52 | R | Middle | 35 | Excellent | 10 | 26 |
| 7 | F | 46 | R | Distal | 34 | Good | 9 | 17 |
| 8 | F | 55 | L | Middle | 24 | Excellent | 11 | 27 |
| 9 | M | 45 | L | Middle | 36 | Bad | 8 | 13 |
| 10 | M | 32 | R | Distal | 29 | Excellent | 10 | 28 |
| 11 | M | 18 | L | Proximal | 36 | Excellent | 12 | 29 |
| 12 | M | 50 | R | Distal | 30 | Good | 8 | 23 |
| 13 | F | 53 | L | Middle | 25 | Excellent | 9 | 24 |
| 14 | M | 27 | L | Proximal | 27 | Excellent | 9 | 25 |
| 15 | M | 38 | R | Proximal | 36 | Good | 8 | 21 |
| 16 | F | 49 | L | Distal | 32 | Good | 9 | 24 |
| 17 | M | 57 | L | Proximal | 30 | Excellent | 10 | 26 |
| 18 | F | 51 | R | Middle | 28 | Excellent | 11 | 27 |

* $P < 0.05$, compared with the preoperative data using paired *t*-test.

chronic tibia osteomyelitis were not thorough, which involved uncovered bone wound or tendon exposure [14]. However, the wound must be fresh, and the fresh dressing for a wound must be changed continuously when using the gastrocnemius medial head transfer flap or the myofascial and cutaneous island pedicle flap with a collateral vessel nourished by the retrograde sural nerve for repair. VSD was used in this therapeutic scheme to treat wounds and minimize necrotic tissues. The tissue cultures indicated no bacterial growth. Afterward, the gastrocnemius medial head transfer flap or the myofascial and cutaneous island pedicle flap with a collateral vessel nourished by the retrograde sural nerve was used for repair. Of the 18 patients, one manifested osteomyelitis recurrence. Simpson et al. [15] divided 50 cases of patients with chronic osteomyelitis into 2 groups: the first group with a margin excision of ≥ 5 mm and the second group with a margin excision of < 5 mm. They administered post-operative antibiotic treatment for the patients for 6 weeks and observed that first group did not experience recurrence, whereas the recurrence rate of the second group reached 28%. These results emphasized the importance of thorough debridement during surgery.

In the present study, 2 patients experienced swelling in the original wound without a blood supply to the skin. After VSD was applied, the wound was fresher, and the exposure was evidently reduced compared to before injury without residual necrotic tissues. The tissue cultures showed no bacterial growth. Then the wound was repaired through flap transfer. It reduced the possibility of infection, and the survival rate of the flaps was consequently increased. The post-operative wounds of the 18 patients in this study were in the primary stage of healing. Therefore, thorough debridement was the first step of chronic osteomyelitis treatment.

Sufficient drainage by VSD is required, in addition to thorough debridement, to closely observe if the drainage tube is unobstructed and to find and eliminate obstructing substances. If the VSD drainage tube is obstructed, then the surgical curative effect is significantly influenced. If massive necrotic tissues and secretions are still found under the dressing 5–7 days after VSD treatment, VSD should be repeatedly changed until the granulation tissues of the wound become fresh [16]. Among the cases in the present study, 1 was subjected to a 5-time continuous change in VSD for 28 days. The shape of the drainage tube must be closely monitored after surgery. If this tube

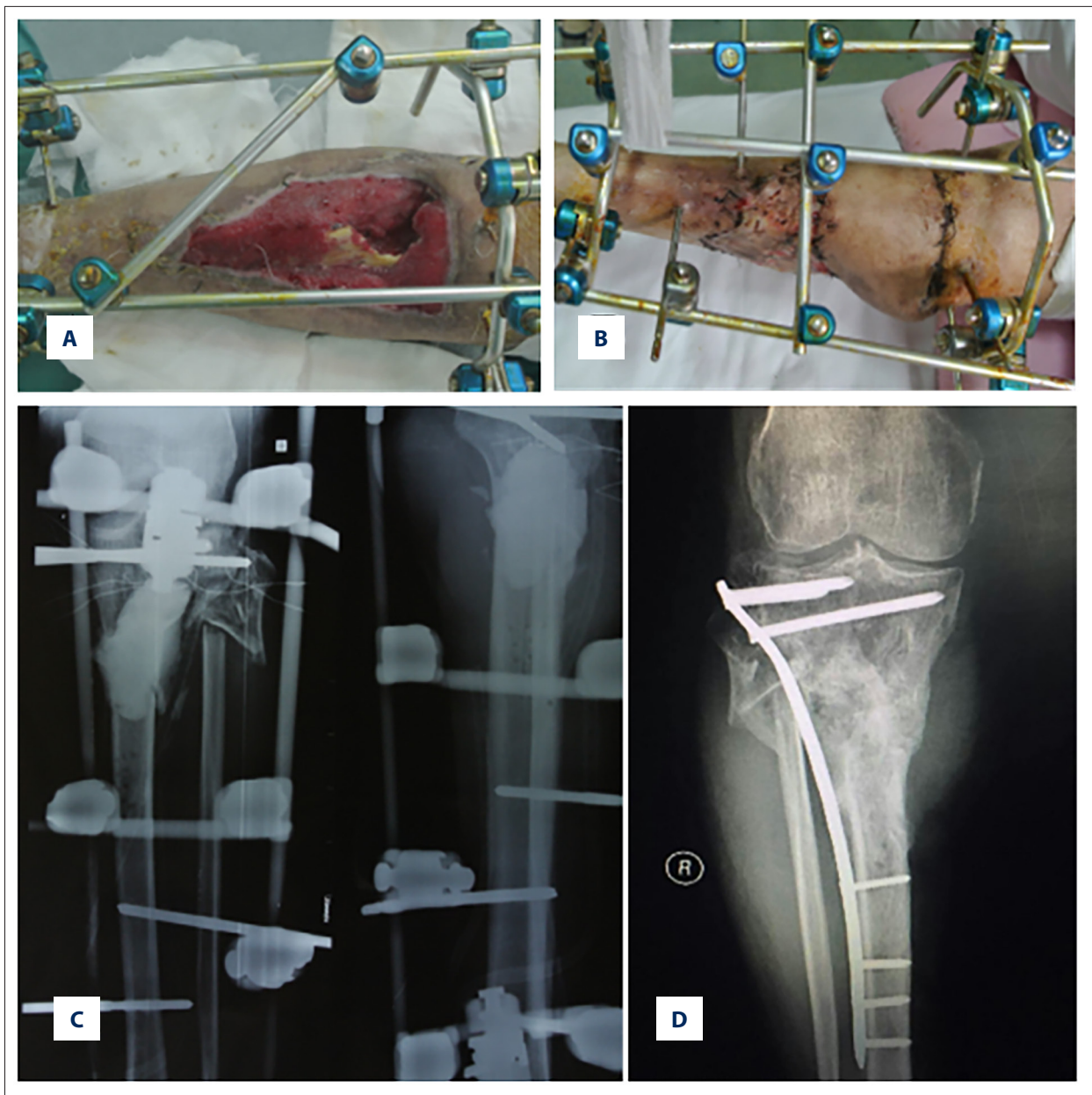


Figure 1. A chronic tibia osteomyelitis patient was treated with a medial head of gastrocnemius flap transfer combined with vacuum sealing drainage and antibiotic bone cement. (A) Medial head of gastrocnemius flap transfer pre-operative; (B) flap transfer post-operative; (C) antibiotic bone cement implanted post-operative; (D) tibia bone defect cured post-operative.

shape disappears, a thin film should be added, or a VSD device should be replaced to avoid affecting. If the drainage tube is obstructed, heparin saline or hydrogen peroxide should be used to flush promptly. The color of the drainage liquid should also be observed over time. If bright red blood is drained, active bleeding and hemostasis should be performed without delay. The blood supply of the distal extremities must also be monitored, and vacuum pressure must be adjusted according to the blood supply conditions. Thus, sufficient drainage for VSD is a key factor in chronic osteomyelitis treatment.

Flap transplantation is an essential surgical treatment for the patients in our study because different degrees of tibia exposure were found. Different flap transplantations can be selected according to the scope of tibia exposure and the location of lesions [17]. If the bone defect and exposure are at the superior segment of the tibia, a gastrocnemius medial head flap transfer or a cross-leg flap can be used to repair the wound of the exposed tibia. If the bone defect and exposure are at the middle segment of the tibia, a cutaneous island pedicle flap with a collateral vessel nourished by the retrograde sural nerve, a soleus

muscle transposition flap, or a cross-leg flap can be selected to repair the wound on the exposed tibia. If the bone defect and exposure are at the inferior segment of the tibia, a cross-leg flap or a cutaneous island pedicle flap with a collateral vessel nourished by the retrograde sural nerve can be selected to repair the wound on the exposed tibia [18–21]. However, cross-leg flaps cause economic and mental burden to patients [22]. As such, these flaps are rarely used. Of the 18 cases, 7, 6, and 5 cases displayed lesions at the superior, middle, and inferior segments, respectively. The gastrocnemius medial head transfer flap was utilized for the patients with lesions at the superior segment to repair the wound. The cutaneous island pedicle flap with a collateral vessel nourished by the retrograde sural nerve was used for patients with lesions at the middle and inferior segments to repair the wounds. Our results reveal that the surgical curative effect is satisfactory.

The operating points during surgery are summarized as follows: 1) flaps should be designed according to the location and size of wounds. The size of flaps should be 1.0–2.0 cm larger in length and width than those of the wound surface in a graft field. 2) During flap incision, the proximal margin of the flaps should be cut, the cutaneous nerve trunk should be searched, and the location of the flaps should be properly adjusted. The pedicle should also be cut along one side of the flaps. An interrupted suture should be placed on the margin of the myocutaneous flaps for all layers and simultaneously cut to avoid delamination peeling. 3) The looseness of pedicles during surgery should be ensured. The tract should remain open, if necessary, to prevent twisting compression in pedicles. Appropriately longer fascial pedicle flaps should be designed to inhibit the effect of blood supply on flaps because of stretching. The height of the pedicle rotation point should also be guaranteed to avoid damaging the perforating branch of the peroneal artery and affecting blood supply because of excessively low height. The reversible repair scope of flaps was increased by 2.0 cm when the rotation point was reduced by 1.0 cm. 4) The bandage placed after surgery should be as loose as possible to prevent pedicle compression and stretching. 5) Anastomosis should be carried out in the proximal end of the small saphenous vein to increase the reflux and to reduce swelling. 6) Tension during flap suture should not be excessive. The stitch length can be sparse to facilitate tissue fluid exudation.

The French scholar Masquelet performed an induction filming by using bone cement to fill the damaged area from 1986–1999. Autogenous spongy bone grafting and fixation treatment were

conducted in 35 patients with long bone defect, with the longest bone measuring 25 cm, which achieved a good effect [23]. This technology is easily performed and characterized by several advantages, such as a short learning curve, few complications, low infection rate, and early weight loading time. This technology is also widely applied to treat post-traumatic bone defect, congenital pseudarthrosis, bone defect after bone tumor excision, and infective bone non-union [24–27].

Masquelet technology was implemented in 2 stages [28–30]. In stage 1, a bone cement spacer was implanted in the bone defect region after unfavorable tissues were thoroughly debrided. A film layer called an induction film surrounding the bone cement was also formed. Therefore, Masquelet technology was also called film induction technology. In stage 2, the bone cement was extracted 4–8 weeks after the stage I surgery. An autogenous spongy bone was implanted into a membrane vesicle, and fracture sites were fixed with a bone fracture plate, an intramedullary nail, or an external fixator. This technology aimed to repair the long segment of cortical bone defect on the basis of the rapid ossification and corticalization of spongy bone in induction films. The key technology involved the formation of an induction film in stage I. In our study, thorough debridement and sufficient drainage were performed, an antibiotic bone cement was implanted into the bone defect, and bone grafting through Masquelet technology was conducted to repair bone defects. The antibiotic bone cement with bactericidal effect and membrane induction could promote bone formation strongly, and would not form a cavity after bone grafting, where the infection would thus not spread. When using the fibula graft, the gap after grafting the fibula would need to be filled with autologous or autologous bone, which might lead to ankle instability [31]. Once the wound is infected, recurrence can easily occur. In addition, for 8 cm defects, VSD combined with appropriate flap transplantation and antibiotic bone cement can be very effective and result in less complications. Therefore, our results showed a satisfactory curative effect.

Conclusions

VSD combined with appropriate flap transplantation and antibiotic bone cement is an effective treatment for chronic tibia osteomyelitis.

Conflicts of interest

None.

References:

1. Kremers HM, Nwojo ME, Ransom JE et al: Trends in the epidemiology of osteomyelitis: A population-based study, 1969 to 2009. *J Bone Jt Surg Am*, 2015; 97: 837–45
2. Ovaska MT, Makinen TJ, Madanat R et al: Risk factors for deep surgical site infection following operative treatment of ankle fractures. *J Bone Jt Surg Am*, 2013; 95: 348–53
3. Parkkinen M, Madanat R, Lindahl J et al: Risk factors for deep infection following plate fixation of proximal tibial fractures. *J Bone Joint Surg Am*, 2016; 98: 1292–97
4. Roussignol X, Sigonneu G, Potage D et al: Secondary nailing after external fixation for tibial shaft fracture: risk factors for union and infection. A 55-case series. *Orthop Traumatol Surg Res*, 2015; 101: 89–92
5. Chen AT, Vallier HA: Noncontiguous and open fractures of the lower extremity: Epidemiology, complications, and unplanned procedures. *Injury*, 2016; 47: 742–47
6. Court-Brown CM, Keating JF, McQueen MM: Infection after intramedullary nailing of the tibia. Incidence and protocol for management. *J Bone Joint Surg Br*, 1992; 74: 770–74
7. Lew DP, Waldvogel FA: Osteomyelitis. *N Engl J Med*, 1997; 336: 999–1007
8. Mouzopoulos G, Kanakaris NK, Kontakis G et al: Management of bone infections in adults: The surgeon's and microbiologist's perspectives. *Injury* 2011; 42(Suppl. 5): S18–23
9. Tseng CH, Huang WS, Muo CH et al: Increased depression risk among patients with chronic osteomyelitis. *J Psychosom Res*, 2014; 77: 535–40
10. Birt MC, Anderson DW, Bruce Toby E et al: Osteomyelitis: Recent advances in pathophysiology and therapeutic strategies. *J Orthop*, 2016; 14: 45–52
11. Virani SR, Dahapute AA, Bava SS et al: Impact of negative pressure wound therapy on open diaphyseal tibial fractures: A prospective randomized trial. *J Clin Orthop Trauma*, 2016; 7: 256–59
12. Enneking WF, Danham W, Gebhardt MC et al: A system for the functional evaluation of reconstruction procedures after surgical treatment of tumors of the musculoskeletal system. *Clin Orthop*, 1993; 286: 241–46
13. Tetsworth K, Cierny G III: Osteomyelitis debridement techniques. *Clin Orthop Relat Res*, 1999; 360: 87–96
14. Eralp İL, Kocaoğlu M, Dikmen G et al: Treatment of infected nonunion of the juxta-articular region of the distal tibia. *Acta Orthop Traumatol Turc*, 2016; 50: 139–46
15. Simpson AH, Deakin M, Latham JM: Chronic osteomyelitis. The effect of the extent of surgical resection on infection-free survival. *J Bone Joint Surg Br*, 2001; 83: 403–7
16. Kumar S, O'Donnell ME, Khan K et al: Successful treatment of perineal necrotising fasciitis and associated pubic bone osteomyelitis with the vacuum assisted closure system. *World J Surg Oncol*, 2008; 6: 67
17. Franceschini M, Di Matteo A, Bösebeck H et al: Treatment of a chronic recurrent fistulized tibial osteomyelitis: Administration of a novel antibiotic-loaded bone substitute combined with a pedicular muscle flap sealing. *Eur J Orthop Surg Traumatol*, 2012; 22(Suppl. 1): 245–49
18. Chaput B, Bertheuil N, Grolleau JL et al: Comparison of propeller perforator flap and venous supercharged propeller perforator flap in reconstruction of lower limb soft tissue defect: A prospective study. *Microsurgery*, 2018; 38(2): 177–84
19. Nenad T, Reiner W, Michael S et al: Saphenous perforator flap for reconstructive surgery in the lower leg and the foot: A clinical study of 50 patients with posttraumatic osteomyelitis. *J Trauma*, 2010; 68: 1200–7
20. Tajsic N, Winkel R, Husum H: Distally based perforator flaps for reconstruction of post-traumatic defects of the lower leg and foot. A review of the anatomy and clinical outcomes. *Injury*, 2014; 45: 469–77
21. Lu S, Wang C, Wen G et al: Versatility of the greater saphenous fasciocutaneous perforator flap in coverage of the lower leg. *J Reconstr Microsurg*, 2014; 30: 179–86
22. Wang ZQ, Cao YL, Huang YF et al: Cross-leg repair of large soft-tissue defects in distal sites of the feet by distally based neuro-fasciocutaneous flaps with perforating vessels. *Genet Mol Res*, 2014; 13: 5484–91
23. Masquelet AC, Fitoussi F, Begue T et al: [Reconstruction of the long bones by the induced membrane and spongy autograft.] *Ann Chir Plast Esthet*, 2000; 45(3): 346–53 [in French]
24. Karger C, Kishi T, Schneider L et al: Treatment of posttraumatic bone defects by the induced membrane technique. *Orthop Traumatol Surg Res*, 2012; 98: 97–102
25. Gouron R, Deroussen F, Juvet M et al: Early resection of congenital pseudarthrosis of the tibia and successful reconstruction using the Masquelet Technique. *J Bone Joint Surg Br*, 2011; 93: 552–54
26. Accadbled F, Mazeau P, Chotel F et al: Induced-membrane femur reconstruction after resection of bone malignancies: Three cases of massive graft resorption in children. *Orthop Traumatol Surg Res*, 2013; 99: 479–83
27. Powerski M, Maier B, Frank J et al: Treatment of severe osteitis after elastic intramedullary nailing of a radial bone shaft fracture by using cancellous bone graft in Masquelet technique in a 13-year-old adolescent girl. *J Pediatr Surg*, 2009; 44: E17–19
28. Mühlhäusser J, Winkler J, Babst R et al: Infected tibia defect fractures treated with the Masquelet technique. *Medicine (Baltimore)*, 2017; 96: e6948
29. Jiang N, Qin CH, Ma YF et al: Possibility of one-stage surgery to reconstruct bone defects using the modified Masquelet technique with degradable calcium sulfate as a cement spacer: A case report and hypothesis. *Biomed Rep*, 2016; 4: 374–78
30. Han W, Shen J, Wu H et al: Induced membrane technique: Advances in the management of bone defects. *Int J Surg*, 2017; 42: 110–16
31. Chen H, Zhang Y, Xia H et al: Stability of tibial defect reconstruction with fibular graft and unilateral external fixation: A finite element study. *Int J Clin Exp Med*, 2014; 7(1): 76–83