



Contrast induced acute kidney injury and the role of beta-blockers in its prevention

Umberto Barbero, Mario Iannaccone, Michele De Benedictis, Baldassarre Doronzo

Cardiology Division, Santissima Annunziata Hospital, Savigliano, Italy

Correspondence to: Umberto Barbero. Division of Cardiology, Santissima Annunziata Hospital, Savigliano, Italy. Email: ubarbero@unito.it.

Comment on: Liu J, Sun G, He Y, *et al.* Early β -blockers administration might be associated with a reduced risk of contrast-induced acute kidney injury in patients with acute myocardial infarction. *J Thorac Dis* 2019;11:1589-96.

Submitted Jun 13, 2019. Accepted for publication Jun 18, 2019.

doi: 10.21037/jtd.2019.06.53

View this article at: <http://dx.doi.org/10.21037/jtd.2019.06.53>

Contrast-induced acute kidney injury (CI-AKI) is a well-known plight after diagnostic or interventional procedures requiring iodinated contrast media. It is actually the third cause of renal breakdown in hospitalized patients, and an everyday concern for procedures with high contrast use like coronary angioplasty (1).

In the last setting the risk of CI-AKI is independently associated with baseline comorbidities: chronic kidney disease (CKD), impaired left ventricular systolic function, anaemia, diabetes, acute coronary syndrome (ACS) presentation and hemodynamic instability (2-4). According to the patient risk profile, the risk of AKI may range from less than 3% in low-risk patients with normal renal function (i.e., eGFR >45 mL/min/1.73 m²) who undergo an elective procedure (5) to >10 –30% in patients presenting with acute myocardial infarction (AMI) (6-9). When AMI is complicated by cardiogenic shock, AKI prevalence increases to more than 50% of the patients (10).

Recognizing the patients with the higher risk of developing this complication is therefore mandatory, in order to set up in good time the best preventive manoeuvres. This fact is so important because CI-AKI is not only deleterious for the kidney per se, but because it has been independently associated with short- and long-term risk for death and major adverse cardiovascular events (MACE) and with 30-day major bleeding (11,12): it increases the risk of mortality up to 20% and sometimes leads to permanent impairment of renal function (11,13,14). Over the simple but essential evaluation of serum creatinine levels (and estimated glomerular filtration rate), some scores have been developed to help physicians in patients'

stratification: the most famous is the Mehran score which was derived from a cohort of 8,357 patients (4). Another interesting score is the one by Bartholomew *et al.* (15), who studied 20,479 patients who formerly received contrast medium during percutaneous coronary intervention (PCI). Recently, Maioli *et al.* (16) developed an easy scoring to predict CI-AKI before coronary angiography and elective percutaneous coronary intervention (PCI). A summary of these scores with the included variables and the risk stratification is presented in *Figure 1*.

A good preventive strategy obviously starts from the knowledge of the pathophysiological mechanism, but to date the etiopathogenesis of contrast induced nephropathy remains largely unclear. The contrast medium is thought to induce CI-AKI through different levels of damage: Firstly, it may promote renal vasoconstriction, resulting in an augmentation of intrarenal resistance with a fall in renal blood flow and therefore in glomerular filtration rate (17,18). Secondly, it has both a direct cytotoxic effects on endothelial and tubular cells (which in turn leads to epithelial vacuolization and necrosis of proximal tubules) and an indirect toxic effects through the reduction in nitric oxide (NO) production that promote the formation of reactive oxygen species and increase the angiotensin-II effects causing direct constriction of descending vasa recta and subsequently medullary hypoxia (19). Finally, the iodinated contrast medium might increase the active sodium reabsorption in the Henle's loop (thus increasing the O₂ demand and as a result worsening medullary hypoxia) (20). All these mechanisms participate in reducing cell survival, finally escalating in acute kidney injury that in turn may

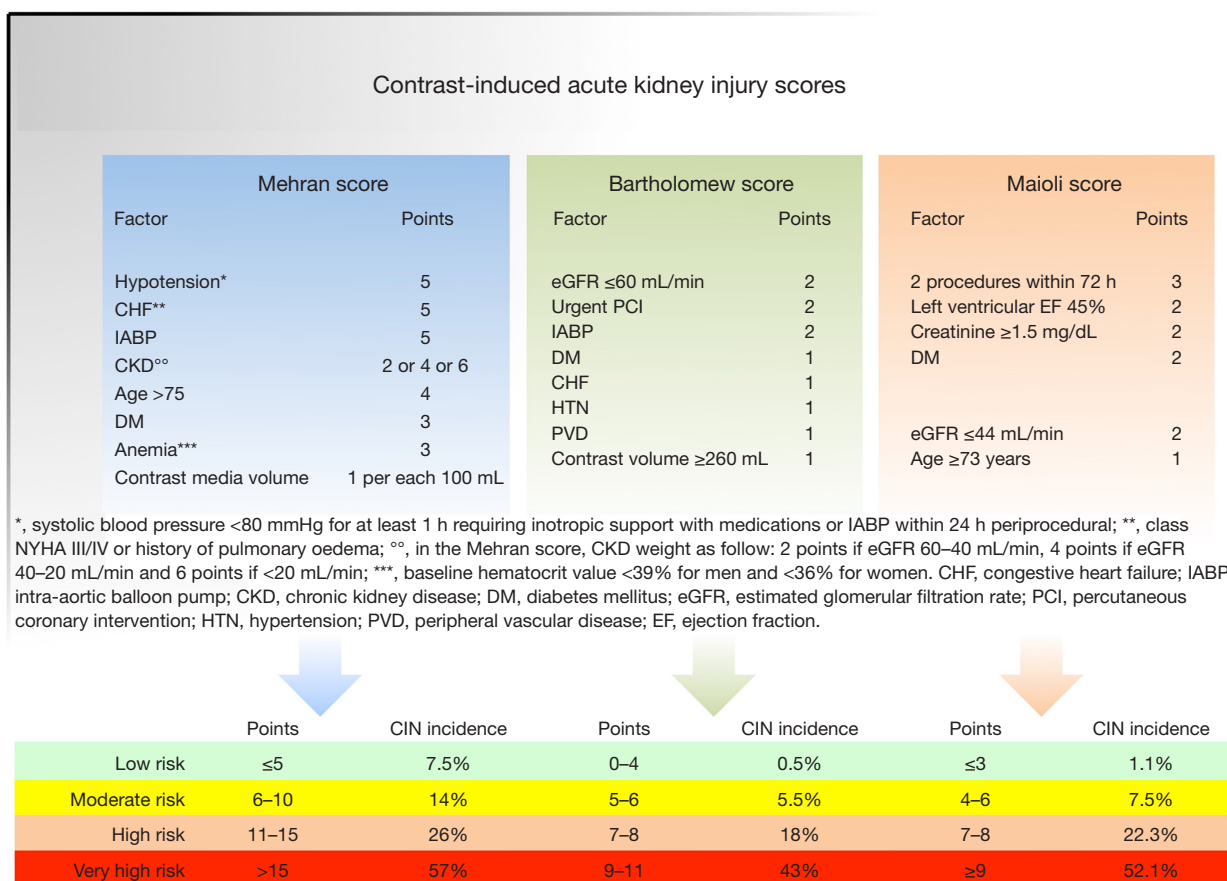


Figure 1 Some of the most used risk scores [Mehran score (4), Bartholomew score (15) and Maioli score (16)] for CI-AKI with the derived classification and associated risk. CIN, contrast-induced nephropathy; CI-AKI, contrast-induced acute kidney injury.

favour inflammation leading to apoptosis and fibrosis at the cellular level (12,21) [and the sympathetic stimulation has been demonstrated to increase the ischemia/reperfusion renal damage (22)], and also fluid retention leading to cardiac instability. To aggravate the situation, patients who develop CI-AKI usually have a worse cardiovascular risk profile and a higher prevalence of comorbidities.

As above mentioned, CI-AKI has also been reported to be associated with bleedings. From the first report by Levy *et al.* (23) who described a 38% prevalence of bleeding events among patients with CI-AKI to the exhaustive pooled analysis from the HORIZONS-AMI and ACUITY trials by Giacoppo *et al.* who reported CI-AKI as the strongest predictor of bleeding (12), a variety of causal mechanisms have been postulated to explain the increased bleeding propensity in the setting of CKD: anomalous platelet function and aggregation (24) with altered

platelet-endothelial interactions (25,26), an enhanced NO production (27) with unbalanced prostaglandin metabolism (25) and impaired serotonin uptake and release (28) and the presence of an abnormal von Willebrand factor (29).

Once recognized patients who deserve adequate prevention for contrast-induced nephropathy (CIN), this is mainly based on extracellular volume expansion after the results of many randomized trial (30). Pretreatment with high-dose statins may be of interest (31). Conflicting results however have been obtained with nebivolol and other beta-blockers, furosemide, theophylline, calcium-channel blockers, N-acetylcysteine, sodium bicarbonate and hemodialysis (32-34).

The potentially preventive role of beta-blockers in patients undergoing coronary angiography is particularly attractive since the common use of such drugs in ischemic

patients, with a well-known prognostic impact in who experienced myocardial infarction. Indeed, AMI patients are at high-risk for developing AKI: the risk factors for this complication are related to comorbidities [high prevalence of diabetes and CKD (35)], to the revascularization procedures with use of iodinated contrast medium and to cardiac complications (hemodynamic instability, heart failure) and their weight in each clinical setting have already been extensively studied (4,11,35,36).

The renewed interest in AKI after AMI is due to the increasing evidence of the association between AKI with in-hospital and long-term mortality (6,8-10,12), even after 10 years of follow-up (6). These studies identified a new concern regarding the prevention of AKI after AMI: as suggested by guidelines (37,38), ST-elevation myocardial infarction (STEMI) patients benefit from the early use of β -blockers (39) and from a kidney perspective there are data that β -blockers also improve endothelial dysfunction in renal ischemia because of the abovementioned endothelial NO synthase (eNOS) activation (18,33,40). In addition, sympathetic activity plays a pivotal role in renal damage that β -blockers might interdict (22). Actually, the retrospective study by Queiroz *et al.* showed that β -blocker use (mainly propranolol) was protective against AKI occurrence during hospitalization in 406 patients with STEMI (41). In the paper by Leung *et al.* on 5,991 patients with ACS, the use of beta-blockers remained associated with lower mortality in both individuals with and without AKI (42).

Among beta-blockers, nebivolol is particularly captivating due to its antioxidant and vasodilator properties by facilitating NO release through several mechanisms (18,40,43). Nebivolol is able to both increasing eNOS expression and activity (44), while decreasing asymmetric dimethyl-arginine which is a natural eNOS inhibitor (45) and also the degradation of eNOS itself (46).

Since both vasoconstriction and oxidative stress in the renal medullary capillaries may be responsible for development of CIN, several studies explored whether nebivolol can prevent CIN or not (33,47): Avci *et al.* compared post angiographic results of 55 patients who used nebivolol and 35 patients who used metoprolol and they showed that the occurrence of CIN was significantly lower in the nebivolol group (33). But, as noted by Bowden's editorial comment, the non-randomized strategy and the small sample size of this study reduce the conclusion strength (33).

Toprak *et al.* previously described the protective role of nebivolol in CI-AKI. No difference between patients

receiving nebivolol or no was detected during six-days serum creatinine monitoring, but intravenous nebivolol reduced the severity of histological damages and the levels of oxidative stress markers (48).

Finally, Altunoren *et al.* used serum neutrophil-gelatinase associated lipocalin (NGAL), a more sensitive marker of renal damage than CrCl, to evaluate the role of nebivolol as a preventive treatment. After investigating 159 patients they concluded that it does not seem to prevent CI-AKI after coronary angiography (49).

The PROCOMIN study tried to address the issue of AKI prevention by means of beta-blockers administration in 1,309 patients presenting to the cath lab with a diagnosis of AMI (1). In this prospective observational study, the authors excluded patients with severe kidney disease (eGFR at admission <15 mL/min), and guaranteed adequate hydration according to guidelines suggestion. Patients were assigned into two groups according to β -blockers use or non-use within 24 h of the perioperative period (with 1,074 patients in the β -blockers group and 235 in the non- β -blockers group). They tested serum creatinine from the admission to 3 days after the procedure, and the follow-up after hospital discharge was 48 months. They concluded that taking β -blockers might be associated with a reduced risk of CI-AKI and long-term mortality among AMI patients sent to coronary angiography and/or PCI.

Despite the goodness of the aim of this study, some considerations arise regarding the data displayed. First, no mention of the proportion of STEMI and NSTEMI patients is available in the text or in the tables: since NSTEMI may have been studied even later than 24 h from admission, a sub-analysis of STEMI patients and NSTEMI patients may be recommended to better clarify the role of early administration of such drugs since on the long term the protective role of these drugs has been already clarified (50,51). Indeed, it should be presumed that the majority of AMI patients would have received β -blockers at the moment of hospital discharge. Nevertheless, no mention of discharge therapy is found in the paper. Secondly, we know the absolute importance that reperfusion time has on the prognosis of patients with AMI. As a matter of fact, that protection is also related with AKI development: when early reperfusion is performed there is less myocardial damage resulting in lower probability of heart failure and hemodynamic instability. More data about this time interval and its inclusion in the multivariate analysis may be of interest to better explore the role of beta-blockers, which effects on heart rate is known and since a long-lasting

higher heart rate has been previously showed to correlate with AKI.

In conclusion, despite several limits the PROCOMIN trial however has the credit to light on again the need to not underestimate the role of acute kidney injury in the emergency department and in the cath lab. Beta-blockers are commonly prescribed in myocardial patients and an interpretation of this study data implies, at least, that an AMI patient who cannot receive β -blockers early after admission must be observed by physicians as a patient with a higher risk of developing AKI. This paper also remembers us the difficulty in obtaining strong evidences of a direct effect of β -blockers on renal function, even after adjusting for many variables: indeed, only a randomized study could satisfactorily answer this question, but it is not achievable because of the already known and important beneficial effect of β -blockers on mortality in the AMI setting.

Acknowledgments

None.

Footnote

Conflicts of Interest: The authors have no conflicts of interest to declare.

Ethical Statement: The authors are accountable for all aspects of the work in ensuring that questions related to the accuracy or integrity of any part of the work are appropriately investigated and resolved.

References

1. Liu J, Sun G, He Y, et al. Early β -blockers administration might be associated with a reduced risk of contrast-induced acute kidney injury in patients with acute myocardial infarction. *J Thorac Dis* 2019;11:1589-96.
2. Leoncini M, Toso A, Maioli M, et al. Early High-Dose Rosuvastatin for Contrast-Induced Nephropathy Prevention in Acute Coronary Syndrome. *J Am Coll Cardiol* 2014;63:71-9.
3. Marenzi G, Lauri G, Assanelli E, et al. Contrast-induced nephropathy in patients undergoing primary angioplasty for acute myocardial infarction. *J Am Coll Cardiol* 2004;44:1780-5.
4. Mehran R, Aymong ED, Nikolsky E, et al. A simple risk score for prediction of contrast-induced nephropathy after percutaneous coronary intervention. *J Am Coll Cardiol* 2004;44:1393-9.
5. Lindsay J, Apple S, Pinnow EE, et al. Percutaneous coronary intervention-associated nephropathy foreshadows increased risk of late adverse events in patients with normal baseline serum creatinine. *Catheter Cardiovasc Interv* 2003;59:338-43.
6. Parikh CR, Coca SG, Wang Y, et al. Long-term Prognosis of Acute Kidney Injury After Acute Myocardial Infarction. *Arch Intern Med* 2008;168:987.
7. Hwang SH, Jeong MH, Ahmed K, et al. Different clinical outcomes of acute kidney injury according to acute kidney injury network criteria in patients between ST elevation and non-ST elevation myocardial infarction. *Int J Cardiol* 2011;150:99-101.
8. Fox CS, Muntner P, Chen AY, et al. Short-Term Outcomes of Acute Myocardial Infarction in Patients With Acute Kidney Injury: A Report From the National Cardiovascular Data Registry. *Circulation* 2012;125:497-504.
9. Goldberg A, Hammerman H, Petcherski S, et al. Inhospital and 1-year mortality of patients who develop worsening renal function following acute ST-elevation myocardial infarction. *Am Heart J* 2005;150:330-7.
10. Marenzi G, Assanelli E, Campodonico J, et al. Acute kidney injury in ST-segment elevation acute myocardial infarction complicated by cardiogenic shock at admission. *Crit Care Med* 2010;38:438-44.
11. Seeliger E, Sendeski M, Rihal CS, et al. Contrast-induced kidney injury: mechanisms, risk factors, and prevention. *Eur Heart J* 2012;33:2007-15.
12. Giacoppo D, Madhavan MV, Baber U, et al. Impact of Contrast-Induced Acute Kidney Injury After Percutaneous Coronary Intervention on Short- and Long-Term Outcomes: Pooled Analysis From the HORIZONS-AMI and ACUTY Trials. *Circ Cardiovasc Interv* 2015;8:e002475.
13. Barbero U, D'Ascenzo F, Campo G, et al. Safety of FFR-guided revascularisation deferral in Anatomically prognostic disease (FACE: CARDIOGROUP V STUDY): A prospective multicentre study. *Int J Cardiol* 2018;270:107-12.
14. Iannaccone M, Barbero U, D'ascenzo F, et al. Rotational atherectomy in very long lesions: Results for the ROTATE registry. *Catheter Cardiovasc Interv* 2016;88:E164-72.
15. Bartholomew BA, Harjai KJ, Dukkupati S, et al. Impact of nephropathy after percutaneous coronary intervention and a method for risk stratification. *Am J Cardiol*

- 2004;93:1515-9.
16. Maioli M, Toso A, Gallopin M, et al. Preprocedural score for risk of contrast-induced nephropathy in elective coronary angiography and intervention. *J Cardiovasc Med (Hagerstown)* 2010;11:444-9.
 17. Andreucci M, Faga T, Pisani A, et al. Acute Kidney Injury by Radiographic Contrast Media: Pathogenesis and Prevention. *BioMed Res Int* 2014;2014:362725.
 18. Myers SI, Wang L, Liu F, et al. Iodinated contrast induced renal vasoconstriction is due in part to the downregulation of renal cortical and medullary nitric oxide synthesis. *J Vasc Surg* 2006;44:383-91.
 19. Andreucci M, Fuiano G, Presta P, et al. Radiocontrast media cause dephosphorylation of Akt and downstream signaling targets in human renal proximal tubular cells. *Biochem Pharmacol* 2006;72:1334-42.
 20. Heyman SN, Khamaisi M, Rosen S, et al. Renal Parenchymal Hypoxia, Hypoxia Response and the Progression of Chronic Kidney Disease. *Am J Nephrol* 2008;28:998-1006.
 21. Kelly KJ. Acute Renal Failure: Much More Than a Kidney Disease. *Semin Nephrol* 2006;26:105-13.
 22. Fujii T, Kurata H, Takaoka M, et al. The role of renal sympathetic nervous system in the pathogenesis of ischemic acute renal failure. *Eur J Pharmacol* 2003;481:241-8.
 23. Levy EM, Viscoli CM, Horwitz RI. The effect of acute renal failure on mortality. A cohort analysis. *JAMA* 1996;275:1489-94.
 24. Castaldi PA, Rozenberg MC, Stewart JH. The bleeding disorder of uraemia. A qualitative platelet defect. *Lancet* 1966;2:66-9.
 25. Castillo R, Lozano T, Escolar G, et al. Defective platelet adhesion on vessel subendothelium in uremic patients. *Blood* 1986;68:337-42.
 26. Schetz MR. Coagulation disorders in acute renal failure. *Kidney Int Suppl* 1998;66:S96-101.
 27. Noris M, Benigni A, Boccardo P, et al. Enhanced nitric oxide synthesis in uremia: implications for platelet dysfunction and dialysis hypotension. *Kidney Int* 1993;44:445-50.
 28. Malyszko J, Malyszko JS, Pawlak D, et al. Hemostasis, platelet function and serotonin in acute and chronic renal failure. *Thromb Res* 1996;83:351-61.
 29. Zwaginga JJ, Ijsseldijk MJ, Beeser-Visser N, et al. High von Willebrand factor concentration compensates a relative adhesion defect in uremic blood. *Blood* 1990;75:1498-508.
 30. Weisbord SD, Gallagher M, Jneid H, et al. Outcomes after Angiography with Sodium Bicarbonate and Acetylcysteine. *N Engl J Med* 2018;378:603-14.
 31. Gandhi S, Mosleh W, Abdel-Qadir H, et al. Statins and contrast-induced acute kidney injury with coronary angiography. *Am J Med* 2014;127:987-1000.
 32. Briguori C, Donnarumma E, Quintavalle C, et al. Contrast-induced acute kidney injury: potential new strategies. *Curr Opin Nephrol Hypertens* 2015;24:145-53.
 33. Avci E, Ye il M, Bayata S, et al. The role of nebivolol in the prevention of contrast-induced nephropathy in patients with renal dysfunction. *Anadolu Kardiyol Derg* 2011;11:613-7.
 34. Zhou L, Duan S. Effects of Angiotensin Converting Enzyme Inhibitors and Angiotensin Receptor Blockers in Contrast-Induced Nephropathy. *Kidney Blood Press Res* 2013;38:165-71.
 35. Shaw A. Models of preventable disease: contrast-induced nephropathy and cardiac surgery-associated acute kidney injury. *Contrib Nephrol* 2011;174:156-62.
 36. Ko B, Garcia S, Mithani S, et al. Risk of acute kidney injury in patients who undergo coronary angiography and cardiac surgery in close succession. *Eur Heart J* 2012;33:2065-70.
 37. Ibanez B, James S, Agewall S, et al. 2017 ESC Guidelines for the management of acute myocardial infarction in patients presenting with ST-segment elevation. *Eur Heart J* 2018;39:119-77.
 38. Roffi M, Patrono C, Collet JP, et al. 2015 ESC Guidelines for the management of acute coronary syndromes in patients presenting without persistent ST-segment elevation: Task Force for the Management of Acute Coronary Syndromes in Patients Presenting without Persistent ST-Segment Elevation of the European Society of Cardiology (ESC). *Eur Heart J* 2016;37:267-315.
 39. Hirschl MM, Wollmann CG, Erhart F, et al. Benefit of Immediate Beta-Blocker Therapy on Mortality in Patients With ST-Segment Elevation Myocardial Infarction. *Crit Care Med* 2013;41:1396-404.
 40. Feng MG, Prieto MC, Navar LG. Nebivolol-induced vasodilation of renal afferent arterioles involves 3-adrenergic receptor and nitric oxide synthase activation. *Am J Physiol Renal Physiol* 2012;303:F775-82.
 41. Queiroz REB, de Oliveira LSN, de Albuquerque CA, et al. Acute kidney injury risk in patients with ST-segment elevation myocardial infarction at presentation to the ED. *Am J Emerg Med* 2012;30:1921-7.
 42. Leung KCW, Pannu N, Tan Z, et al. Contrast-Associated AKI and Use of Cardiovascular Medications after Acute Coronary Syndrome. *Clin J Am Soc Nephrol*

- 2014;9:1840-8.
43. Vanhoutte PM, Gao Y. Beta blockers, nitric oxide, and cardiovascular disease. *Curr Opin Pharmacol* 2013;13:265-73.
 44. Ladage D, Brixius K, Hoyer H, et al. Mechanisms Underlying Nebivolol-Induced Endothelial Nitric Oxide Synthase Activation in Human Umbilical Vein Endothelial Cells: eNOS activation by nebivolol. *Clin Exp Pharmacol Physiol* 2006;33:720-4.
 45. Garbin U, Pasini AF, Stranieri C, et al. Nebivolol reduces asymmetric dimethylarginine in endothelial cells by increasing dimethylarginine dimethylaminohydrolase 2 (DDAH2) expression and activity. *Pharmacol Res* 2007;56:515-21.
 46. Mollnau H, Schulz E, Daiber A, et al. Nebivolol Prevents Vascular NOS III Uncoupling in Experimental Hyperlipidemia and Inhibits NADPH Oxidase Activity in Inflammatory Cells. *Arterioscler Thromb Vasc Biol* 2003;23:615-21.
 47. Günebakmaz O, Kaya MG, Koc F, et al. Does nebivolol prevent contrast-induced nephropathy in humans? *Clin Cardiol* 2012;35:250-4. .
 48. Toprak O, Cirit M, Tanrisev M, et al. Preventive effect of nebivolol on contrast-induced nephropathy in rats. *Nephrol Dial Transplant* 2008;23:853-9.
 49. Altunoren O, Balli M, Eren N, et al. Is Nebivolol Really Effective in Preventing Contrast Induced Nephropathy? *Kidney Blood Press Res* 2015;40:533-41.
 50. The beta-blocker heart attack trial. beta-Blocker Heart Attack Study Group. *JAMA* 1981;246:2073-4.
 51. Dargie HJ. Effect of carvedilol on outcome after myocardial infarction in patients with left-ventricular dysfunction: the CAPRICORN randomised trial. *Lancet* 2001;357:1385-90.

Cite this article as: Barbero U, Iannaccone M, De Benedictis M, Doronzo B. Contrast induced acute kidney injury and the role of beta-blockers in its prevention. *J Thorac Dis* 2019;11(7):2689-2694. doi: 10.21037/jtd.2019.06.53