

Case Control Study

Changes in corneal endothelial cell density in patients with primary open-angle glaucoma

Zi-Yan Yu, Ling Wu, Bo Qu

ORCID number: Zi-Yan Yu (0000-0003-1091-428X); Ling Wu (0000-0003-3057-6302); Bo Qu (0000-0002-2261-8464).

Author contributions: All authors helped to perform the research; Qu B drafted the manuscript; Yu ZY and Wu L reviewed the published articles and analyzed the data; All authors read and approved the final manuscript.

Institutional review board statement: This study was reviewed and approved by the Ethics Committee of the 4th Affiliated Hospital of China Medical University, No. EC-2019-KS-018.

Informed consent statement: Written informed consent was obtained from all of the patients.

Conflict-of-interest statement: The authors have stated that they have no conflicts of interest.

Data sharing statement: The datasets of this study are readily available from the corresponding author upon reasonable request.

STROBE statement: The guidelines of the STROBE statement have been adopted.

Open-Access: This article is an open-access article that was selected by an in-house editor and fully peer-reviewed by external reviewers. It is distributed in accordance with the Creative Commons Attribution Non Commercial (CC BY-NC 4.0) license, which permits others to distribute, remix, adapt, build

Zi-Yan Yu, Bo Qu, Department of Ophthalmology, 4th Affiliated Hospital of China Medical University, Eye hospital of China Medical University, Key Laboratory of Lens Research of Liaoning Province, Shenyang 110005, Liaoning Province, China

Ling Wu, Department of Ophthalmology, the 4th people's Hospital of Shenyang, Shenyang 110005, Liaoning Province, China

Corresponding author: Bo Qu, MD, PhD, Associate Professor, Dr., Department of Ophthalmology, 4th affiliated Hospital of China Medical University, Eye Hospital of China Medical University, Key Laboratory of Lens Research of Liaoning Province, Shenyang 110005, Liaoning Province, China. dolphinemu@foxmail.com
Telephone: +86-130-66660193
Fax: +86-024-62037227

Abstract

BACKGROUND

Glaucoma is a group of diseases characterized by a specific pattern of optic nerve neuropathy and retinopathy. Increasing evidence demonstrates glaucoma associated corneal endothelium loss. Direct-compression mechanism due to elevated intraocular pressure (IOP), cell toxicity after long term exposure to preservatives and glaucoma surgery have been reported to be the possible mechanism. Herein, we compare the specular endothelial microscopy in primary open-angle glaucoma (POAG) patients and healthy controls of the same age group to observe the corneal endothelium changes and the correlations to the mean IOP in a Chinese case control study.

AIM

To investigate corneal endothelial cell density in Chinese patients with POAG.

METHODS

A case control study was performed on 60 eyes of 60 patients with POAG. Exclusion criteria included history of corneal diseases, intraocular diseases, contact lens use, ocular trauma or surgery (including intraocular surgery and laser treatment), congenital abnormalities or systemic diseases such as diabetes. Intraocular pressure was measured using Goldmann tonometry. Indirect specular microscopy (TOPCON SP-2000P) was performed on central corneas and endothelial images were acquired. Endothelial cell density, area and cell counts were analyzed.

RESULTS

upon this work non-commercially, and license their derivative works on different terms, provided the original work is properly cited and the use is non-commercial. See: <http://creativecommons.org/licenses/by-nc/4.0/>

Manuscript source: Unsolicited manuscript

Received: April 9, 2019

Peer-review started: April 12, 2019

First decision: May 31, 2019

Revised: June 28, 2019

Accepted: July 3, 2019

Article in press: July 4, 2019

Published online: August 6, 2019

P-Reviewer: Shariat-Madar Z

S-Editor: Dou Y

L-Editor: Filipodia

E-Editor: Xing YX



Endothelial cell density was 2959 ± 236 cells/mm² in healthy controls and 2757 ± 262 cells/mm² in patients with POAG. The POAG eyes had significantly lower endothelial cell density compared to healthy control eyes ($P < 0.001$). In the POAG group, endothelial cell density was 2686 ± 233 cells/mm² in the patients receiving medication and 2856 ± 272 cells/mm² in the untreated subgroup. The eyes receiving medication had significantly lower endothelial cell density compared to untreated eyes. There was a negative correlation between cell density and mean IOP ($r = -0.286$, $P = 0.004$), positive correlation between the average cell area and mean IOP ($r = 0.228$, $P = 0.022$), maximum cell area and mean IOP ($r = 0.218$, $P = 0.029$) and minimum cell area and mean IOP ($r = 0.290$, $P = 0.003$). The percentage of hexagonal cells was not correlated with mean IOP.

CONCLUSION

Patients with POAG have lower corneal endothelial cell density than healthy controls of the same age. This may be attributed to mechanical damage from elevated IOP and toxicity of glaucoma medications.

Key words: Corneal endothelium; Primary open angle glaucoma; Intraocular pressure

©The Author(s) 2019. Published by Baishideng Publishing Group Inc. All rights reserved.

Core tip: Loss of corneal endothelial cells have been reported in primary open-angle glaucoma (POAG) patients. Elevated intraocular pressure, cell toxicity after long-term exposure to preservatives and glaucoma surgery have been reported to be possible mechanisms for endothelial damage. In this study, we aimed to document the corneal endothelial changes and their correlations with mean intraocular pressure between POAG patients and normal controls. We found that the corneal endothelial cell density in POAG patients is decreased and the average endothelial cell area is increased compared with those in healthy controls. High intraocular pressure and anti-glaucoma medication in POAG may be the main causes of corneal endothelial cell damage.

Citation: Yu ZY, Wu L, Qu B. Changes in corneal endothelial cell density in patients with primary open-angle glaucoma. *World J Clin Cases* 2019; 7(15): 1978-1985

URL: <https://www.wjgnet.com/2307-8960/full/v7/i15/1978.htm>

DOI: <https://dx.doi.org/10.12998/wjcc.v7.i15.1978>

INTRODUCTION

The corneal endothelial monolayer maintains corneal clarity by actively regulating stromal hydration through its barrier and pump functions. Corneal endothelial cells (CECs) have limited proliferative capacity *in vivo*^[1,2], thus damage to the corneal endothelium is irreversible. Loss of CECs occurs as a consequence of intraocular surgery, trauma or diseases such as diabetes and glaucoma^[3-8]. At the early stage of endothelial damage, neighboring cells spread and/or migrate to compensate for the cell loss, which results in an increase in cell size and/or alteration of cell shape. Progression of cell loss further compromises corneal transparency and causes corneal edema, bullous keratopathy and impaired visual acuity.

Glaucoma is a group of diseases characterized by a specific pattern of optic nerve neuropathy and retinopathy^[6,7,9]. There is increasing evidence of glaucoma-associated corneal endothelial changes. Loss of CECs has been reported in various types of glaucoma such as primary angle-closure glaucoma, primary open-angle glaucoma (POAG) and some types of secondary glaucoma^[7,9-15]. Endothelial cell loss is attributed to both glaucoma itself and treatment that lowers intraocular pressure (IOP). A direct-compression mechanism due to elevated IOP has been proposed in CEC loss in acute angle-closure glaucoma^[11,16]. In addition, cell toxicity after long-term exposure to preservatives in ocular hypotensive drugs is considered another possible mechanism for endothelial damage^[13,17]. Moreover, endothelial cell loss caused by glaucoma surgery has been reported in patients after application of antiproliferative medications in filtration surgery and aqueous shunt implantation^[18-21].

In this study, we aimed to document the corneal endothelial changes and their correlations with mean IOP by comparing specular endothelial microscopy in patients

of similar age with and without glaucoma.

MATERIALS AND METHODS

Study subjects

Case control study. We recruited 60 POAG patients (32 male, 28 female; mean age 63 ± 13 years, age range 50-80 years) who visited the Glaucoma Division at the Fourth Affiliated Hospital, China Medical University between February and March 2019 and 60 age-matched healthy controls (28 male, 32 female; mean age 61 ± 12 years, age range 50-80 years). We retrospectively analyzed with regard to their pre-treatment characteristics. There was no significant difference of age between the two groups. Only one eye from each patient or healthy control was analyzed. All study procedures adhered to the Declaration of Helsinki for research involving human participants. The exclusion criteria included: previous ocular (including laser peripheral iridotomy), orbital or palpebral surgery; previous ocular trauma; previous or present contact lens use; other ocular diseases (such as corneal endothelial dystrophy, intraocular inflammation and infection) that could affect the corneal endothelium; and systemic diseases (such as diabetes and congenital abnormalities) that could affect the corneal endothelium.

Specular microscopy

Indirect specular microscopy (SP-2000P; TOPCON, Tokyo, Japan) was performed on each subject. Images were captured from the central cornea and analyzed using IMAGEnet 2000 software (TOPCON). Endothelial cell density (ECD), percentage of hexagonal cells, average cell area, maximum cell area, minimum cell area, standard deviation of cell area (SD) and coefficient of variation in cell area were determined. All examinations were performed by the same examiner.

IOP evaluation

The IOP of all subjects was measured using Goldmann tonometry every 2 h from 08:00 to 18:00 h. The average of all measurements was determined and used for analysis.

Statistical analysis

Statistical analysis was performed using SPSS version 19.0 (SPSS, Chicago, IL, United States). The unpaired Student's *t* test was used to compare the means between normal subjects and patients with POAG. The Chi-square test was applied to the comparison between untreated patients and patients receiving ophthalmic medication. Correlation between IOP and each characteristic of CECs was assessed by Pearson's correlation coefficient. Data are presented as mean \pm SD and the significance level was set at 0.05.

RESULTS

Endothelial cell characteristics of healthy eyes and POAG eyes

ECD was significantly lower in patients with POAG (2757 ± 262 cells/mm²) compared to the control group (2959 ± 236 cells/mm²). The average cell area was significantly increased in glaucoma patients (364.37 ± 34.05 μ m²) compared with the control group (322.23 ± 54.69 μ m²). Consistently, glaucoma patients exhibited increased maximum, minimum and SD of cell area. There were no significant differences in the coefficient of variation of cell area and percentage of hexagonal cells between the two groups (Table 1, Figure 1).

The 60 POAG patients were further divided into two subgroups, untreated patients ($n = 25$) and patients receiving ophthalmic medications ($n = 35$) at the time of the study. No significant difference in age and gender was found between the subgroups. The patients receiving medication had significantly lower ECD (2686 ± 233 cells/mm²) compared to the untreated subgroup (2856 ± 272 cells/mm²). Both subgroups had lower cell densities compared to the controls; however, only the difference between patients receiving medication and healthy controls was significant. The maximum, minimum and SD of cell area and percentage of hexagonal cells did not differ between the subgroups (Table 2).

Correlations between endothelial cell characteristics and IOP

The mean IOP in POAG patients (24 ± 5 mmHg) was significantly higher than that in healthy controls (15 ± 2 mmHg). There was a negative correlation between ECD and mean IOP ($r = -0.286$, $P = 0.004$). Positive correlations were found between the

Table 1 Endothelial cell characteristics of study groups

	POAG, n = 60	Control, n = 60	P value
CD, cells/mm ²	2757 ± 262	2959 ± 236	< 0.001
SD, μm ²	153.87 ± 29.13	140.65 ± 19.53	0.008
CV, %	43.48 ± 7.71	43.06 ± 5.65	0.749
6A, %	49.45 ± 8.23	49.08 ± 9.11	0.831
AVE, μm ²	364.37 ± 34.05	322.23 ± 54.69	< 0.001
MAX, μm ²	963.52 ± 214.04	827.57 ± 198.18	0.002
MIN, μm ²	78.10 ± 16.59	69.37 ± 17.33	0.013

POAG: primary open-angle glaucoma; CD: Cell density; SD: Standard deviation; CV: Coefficient of variation; 6A: Percentage of hexagonal cells; AVE: Average cell area; MAX: Maximum cell area; MIN: Minimum cell area.

average cell area and mean IOP ($r = 0.228$, $P = 0.022$), maximum cell area and mean IOP ($r = 0.218$, $P = 0.029$) and minimum cell area and mean IOP ($r = 0.290$, $P = 0.003$). The percentage of hexagonal cells was not correlated with mean IOP (Figure 2).

DISCUSSION

In Asian populations, primary angle-closure glaucoma is the major type of glaucoma^[22,23]. However, a higher prevalence of POAG than primary angle-closure glaucoma has been reported in recent studies in Chinese populations^[24,25]. Our data demonstrate that, in a Chinese case control study, patients with POAG had a reduction in corneal ECD and an increase in average endothelial cell area compared to age-matched healthy controls. To our knowledge, this is the first report on CEC loss in Chinese patients with POAG. Our data show a 5.47% reduction in ECD in POAG patients compared to healthy controls. Possible explanations include direct mechanical damage, elevated IOP, cytotoxic effects of ocular hypotensive eye drops, impaired endothelial metabolism due to disruptive aqueous humor circulation and congenital endothelial abnormalities.

Correlation between ECD loss and elevated IOP has been investigated^[10]. High IOP directly damages the physical barrier function of CECs and affects the function of the endothelial pump leading to changes in aqueous humor dynamics, which cause corneal stromal edema^[13]. Gagnon *et al*^[13] hypothesized that the mechanism of IOP damage to CECs is as pressure dependent as damage to the optic nerve. Gagnon *et al*^[13] showed that corneal ECD is inversely proportional to mean IOP. Some researchers hypothesized that CEC changes are not associated with high IOP^[26-27]. Our data showed that the glaucoma and normal control groups had significant differences in corneal ECD, consistent with Gagnon *et al*'s^[13] research.

Our results indicated the negative correlation between mean IOP and corneal ECD and the positive correlation between mean IOP and CEC area (Figure 2). High IOP may be an important factor in corneal endothelial injury. In a high IOP animal model, CEC density decreased by an average 5.8% compared with the normal control eyes^[13]. CEC ultrastructure was observed by transmission electron microscopy, and mitochondrial swelling and vacuolar degeneration were observed after 3 d of high IOP, indicating that IOP damaged the physical barrier of endothelial cells. CEC dysfunction allows large amounts of water to enter the cells without any damage and cause endothelial cell edema. However, there was no significant change in intracellular nuclei compared to normal cells. However, if high IOP lasted for 2 wk, the mitochondrial vacuolization and dilated endoplasmic reticulum of CECs indicated aggravation of cell edema. Mild or moderate cell damage can return to normal after the cause of the damage is eliminated, or irreversible damage by cell necrosis may occur. Electron microscopic observation of CECs in a model with high IOP for 4 wk showed irreversible loss of heterochromatin edge, multiple nuclear membrane rupture, and nuclear efflux, showing signs of cell necrosis.

The above observations show that the longer the duration of high IOP, the more severe the ultrastructural destruction of CECs, which have some tolerance to high IOP. Within a certain range, if high IOP is controlled and the damage factor is removed, CECs can recover their structure and function and transparency. The longer high IOP persists, the less the healing capacity of CECs. When the damage exceeds its limit, irreversible damage occurs leading to moderate corneal edema and visual

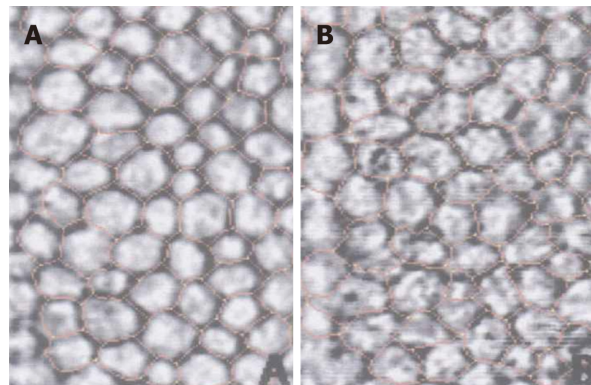


Figure 1 Indirect specular microscopy images of corneal endothelium in normal eyes and eyes with primary open-angle glaucoma. A: Corneal endothelial cells showed regular hexagonal monolayer with clear cell borders in normal eyes; B: Endothelial cells showed irregular and indistinct cell borders with guttae like dark cells in patients with glaucoma.

dysfunction.

It has been shown that damage to CECs can be caused by toxicity of anti-glaucoma medicine^[28,29]. The preservative commonly used in anti-glaucoma medication, benzalkonium chloride, plays an important role in ocular surface damage. Its toxic and adverse effects are dose and time dependent and increase in combination and may damage corneal epithelial cells, CECs and central thickness of the cornea^[30]. In this study, the corneal ECD of the glaucoma sub groups was compared, and covariance analysis was used to exclude the interference factor of average IOP on CECs. The ECD in the glaucoma treated group was significantly reduced compared with that of the untreated groups, which may have been caused by the benzalkonium chloride preservative in the anti-glaucoma medication. However, the difference in CEC area between the treated and untreated groups was not significant, and further large-scale studies are needed.

Aqueous circulation block may affect metabolism of the corneal endothelium and cause hypoxia in the aqueous humor^[31]. That study reported that 30 patients with acute angle-closure glaucoma had significant changes in CEC density compared to normal subjects. The longer the duration of high IOP, the more severe the damage to the corneal endothelium was. The decrease in ECD and the increase in CEC area were related to the length of acute attack and high IOP. Meanwhile, patients with a history of acute attacks showed significantly increased cell area and various changes in shape. Even if the morphologically abnormal CECs show normal density, complications such as loss of corneal endothelial function are more likely to occur after surgery. CEC function requires a certain cell density, but more importantly, it depends on cell morphology, which is a more sensitive indicator of functional changes in the CEC membrane.

The normal corneal endothelium is composed of uniform regular hexagonal cells. Once this structure is destroyed, the corneal endothelium is in an unstable state, and the cells are easily damaged, which causes further deformation and loss^[32]. High IOP and aqueous humor blockade can affect the metabolism of the corneal endothelium and cause pathological changes. Glaucoma patients may have congenital abnormal development of corneal endothelial cell layer and trabecular meshwork. In the diagnosis and treatment of glaucoma, the function of CECs directly affects visual acuity and tolerance of intraocular surgery as well as the treatment options. In patients with a history of elevated IOP, the risk of decompensation is greater, corneal edema is more likely and irreversible corneal opacity can be a perioperative or postoperative complication during or after intraocular surgery^[33].

The corneal ECD in POAG patients is decreased and the average endothelial cell area is increased compared with those in healthy controls. High IOP and anti-glaucoma medication in POAG may be the main causes of CEC damage. Therefore, for glaucoma patients, quantitative analysis of CEC morphology is necessary, and high IOP should be controlled as soon as possible to prevent corneal endothelial damage.

Table 2 Endothelial cell characteristics of glaucoma subgroups

	With medication, n = 35	Untreated, n = 25	P value
CD, cells/mm ²	2686 ± 233	2856 ± 272	0.043
6A, %	49.80 ± 8.32	48.96 ± 8.25	0.929
AVE, μm ²	364.31 ± 34.41	364.44 ± 34.24	0.998
MAX, μm ²	963.70 ± 187.97	963.26 ± 250.14	0.922
MIN, μm ²	80.47 ± 16.28	74.78 ± 16.77	0.089

CD: Cell density; 6A: Percentage of hexagonal cells; AVE: Average cell area; MAX: Maximum cell area; MIN: Minimum cell area.

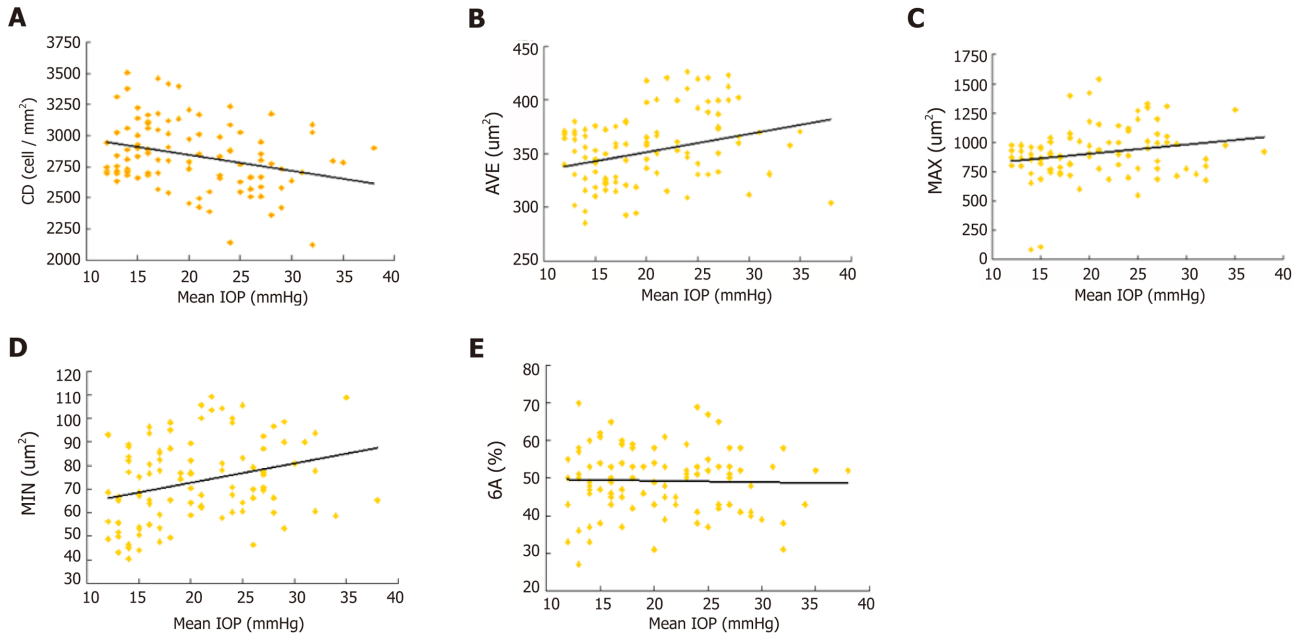


Figure 2 Correlations between endothelial cell characteristics and intraocular pressure. Scatterplots showing the relationship between corneal endothelial cell characteristics and intraocular pressure (IOP). A: There was a negative correlation between cell density and mean IOP ($r = -0.286, P = 0.004$); B: Positive correlations were found between the average of cell area and mean IOP ($r = 0.228, P = 0.022$); C: Maximum cell area and mean IOP ($r = 0.218, P = 0.029$); D: Minimum cell area and mean IOP ($r = 0.290, P = 0.003$); E: The percentage of hexagonal cells was not correlated with mean IOP. CD: Endothelial cell density; AVG: Average of cell area; MAX: Maximum cell area; MIN: Minimum cell area; GA: Percentage of hexagonal cells.

ARTICLE HIGHLIGHTS

Research background

The corneal endothelial monolayer maintains corneal clarity, and its damage is irreversible. Cornea endothelial cell loss is attributed to open-angle glaucoma, medicine and surgery treatments.

Research motivation

The main topic is the changes in corneal endothelial cell density in primary open-angle glaucoma (POAG) patients.

Research objectives

To investigate the corneal endothelium changes and the correlations to the mean intraocular pressure (IOP) in POAG patients.

Research methods

Sixty POAG patients were selected as the patient group (32 male, 28 females; mean age 63 ± 13 years, age range 50-80 years). Meanwhile, 60 age-matched healthy controls who underwent physical examination were selected. IOP was measured by Goldmann tonometry. Corneal endothelial cell density, percentage of hexagonal cells, average cell area, maximum cell area, minimum cell area, standard deviation of cell area and coefficient of variation in cell area were measured by specular microscopy.

Research results

Endothelial cell density was 2959 ± 236 cells/mm² in healthy controls and 2757 ± 262 cells/mm² in patients with POAG. The POAG eyes had significantly lower endothelial cell density compared to healthy control eyes ($P < 0.001$). In the POAG group, endothelial cell density was 2686 ± 233 cells/mm² in the patients receiving medication and 2856 ± 272 cells/mm² in the untreated subgroup. The eyes receiving medication had significantly lower endothelial cell density compared to untreated eyes. There was a negative correlation between cell density and mean IOP ($r = -0.286$, $P = 0.004$) and positive correlation between the average cell area and mean IOP ($r = 0.228$, $P = 0.022$), maximum cell area and mean IOP ($r = 0.218$, $P = 0.029$) and minimum cell area and mean IOP ($r = 0.290$, $P = 0.003$). The percentage of hexagonal cells was not correlated with mean IOP.

Research conclusions

For glaucoma patients, quantitative analysis of CEC morphology is necessary, and high IOP should be controlled as soon as possible to prevent corneal endothelial damage.

Research perspectives

Patients with POAG have lower corneal endothelial cell density than healthy controls of the same age. This may be attributed to mechanical damage from elevated IOP and toxicity of glaucoma medications.

REFERENCES

- Murphy C, Alvarado J, Juster R, Maglio M. Prenatal and postnatal cellularity of the human corneal endothelium. A quantitative histologic study. *Invest Ophthalmol Vis Sci* 1984; **25**: 312-322 [PMID: 6698749]
- Hollingsworth J, Perez-Gomez I, Mutalib HA, Efron N. A population study of the normal cornea using an in vivo, slit-scanning confocal microscope. *Optom Vis Sci* 2001; **78**: 706-711 [PMID: 11700964 DOI: 10.1097/00006324-200110000-00010]
- Urban B, Bakunowicz-Lazarczyk A, Michalczyk M, Krętońska M. Evaluation of corneal endothelium in adolescents with juvenile glaucoma. *J Ophthalmol* 2015; **2015**: 895428 [PMID: 25642345 DOI: 10.1155/2015/895428]
- Cho SW, Kim JM, Choi CY, Park KH. Changes in corneal endothelial cell density in patients with normal-tension glaucoma. *Jpn J Ophthalmol* 2009; **53**: 569-573 [PMID: 20020233 DOI: 10.1007/s10384-009-0740-1]
- Buettner H, Bourne WM. Effect of trans pars plana surgery on the corneal endothelium. *Dev Ophthalmol* 1981; **2**: 28-34 [PMID: 7262410 DOI: 10.1159/000395299]
- Kim KN, Lee SB, Lee YH, Lee JJ, Lim HB, Kim CS. Changes in corneal endothelial cell density and the cumulative risk of corneal decompensation after Ahmed glaucoma valve implantation. *Br J Ophthalmol* 2016; **100**: 933-938 [PMID: 26508781 DOI: 10.1136/bjophthalmol-2015-306894]
- Kusakabe A, Okumura N, Wakimasu K, Kayukawa K, Kondo M, Koizumi N, Sotozono C, Kinoshita S, Mori K. Effect of Trabeculotomy on Corneal Endothelial Cell Loss in Cases of After Penetrating-Keratoplasty Glaucoma. *Cornea* 2017; **36**: 317-321 [PMID: 28151811 DOI: 10.1097/ICO.0000000000001088]
- Aldrich BT, Schlötzer-Schrehardt U, Skeie JM, Burckart KA, Schmidt GA, Reed CR, Zimmerman MB, Kruse FE, Greiner MA. Mitochondrial and Morphologic Alterations in Native Human Corneal Endothelial Cells Associated With Diabetes Mellitus. *Invest Ophthalmol Vis Sci* 2017; **58**: 2130-2138 [PMID: 28395029 DOI: 10.1167/iovs.16-21094]
- Setälä K. Corneal endothelial cell density after an attack of acute glaucoma. *Acta Ophthalmol (Copenh)* 1979; **57**: 1004-1013 [PMID: 545996 DOI: 10.1111/j.1755-3768.1979.tb00531.x]
- Malaise-Stals J, Collignon-Brach J, Weekers JF. Corneal endothelial cell density in acute angle-closure glaucoma. *Ophthalmologica* 1984; **189**: 104-109 [PMID: 6493688 DOI: 10.1159/000309393]
- Bigar F, Witmer R. Corneal endothelial changes in primary acute angle-closure glaucoma. *Ophthalmology* 1982; **89**: 596-599 [PMID: 7122040 DOI: 10.1016/S0161-6420(82)34744-2]
- Knorr HL, Händel A, Naumann GO. [Morphometric and qualitative changes in corneal endothelium in primary chronic open angle glaucoma]. *Fortschr Ophthalmol* 1991; **88**: 118-120 [PMID: 1855725]
- Gagnon MM, Boisjoly HM, Brunette I, Charest M, Amyot M. Corneal endothelial cell density in glaucoma. *Cornea* 1997; **16**: 314-318 [PMID: 9143804 DOI: 10.1097/00003226-199705000-00010]
- Knorr HL, Jünemann A, Händel A, Naumann GO. [Morphometric and qualitative changes in corneal endothelium in pseudoexfoliation syndrome]. *Fortschr Ophthalmol* 1991; **88**: 786-789 [PMID: 1794803]
- Vannas A, Setälä K, Ruusuvaara P. Endothelial cells in capsular glaucoma. *Acta Ophthalmol (Copenh)* 1977; **55**: 951-958 [PMID: 579548 DOI: 10.1111/j.1755-3768.1977.tb05676.x]
- Chen MJ, Liu CJ, Cheng CY, Lee SM. Corneal status in primary angle-closure glaucoma with a history of acute attack. *J Glaucoma* 2012; **21**: 12-16 [PMID: 21048505 DOI: 10.1097/IJG.0b013e3181fe800a]
- Baratz KH, Nau CB, Winter EJ, McLaren JW, Hodge DO, Herman DC, Bourne WM. Effects of glaucoma medications on corneal endothelium, keratocytes, and subbasal nerves among participants in the ocular hypertension treatment study. *Cornea* 2006; **25**: 1046-1052 [PMID: 17133051 DOI: 10.1097/01.icc.0000230499.07273.c5]
- Pastor SA, Williams R, Hetherington J, Hoskins HD, Goodman D. Corneal endothelial cell loss following trabeculectomy with mitomycin C. *J Glaucoma* 1993; **2**: 112-113 [PMID: 19920497 DOI: 10.1097/00061198-199300220-00008]
- Smith DL, Skuta GL, Lindenmuth KA, Musch DC, Bergstrom TJ. The effect of glaucoma filtering surgery on corneal endothelial cell density. *Ophthalmic Surg* 1991; **22**: 251-255 [PMID: 1852377]
- Souza C, Tran DH, Loman J, Law SK, Coleman AL, Caprioli J. Long-term outcomes of Ahmed glaucoma valve implantation in refractory glaucomas. *Am J Ophthalmol* 2007; **144**: 893-900 [PMID: 17916318 DOI: 10.1016/j.ajo.2007.07.035]
- Ates H, Palamar M, Yagci A, Egrilmez S. Trabeculectomy Versus EX-PRESS Shunt Versus Ahmed Valve Implant: Short-term Effects on Corneal Endothelial Cells. *Am J Ophthalmol* 2016; **162**: 201-202

- [PMID: 26654385 DOI: 10.1016/j.ajo.2015.11.012]
- 22 **Sun J**, Zhou X, Kang Y, Yan L, Sun X, Sui H, Qin D, Yuan H. Prevalence and risk factors for primary open-angle glaucoma in a rural northeast China population: a population-based survey in Bin County, Harbin. *Eye (Lond)* 2012; **26**: 283-291 [PMID: 22157917 DOI: 10.1038/eye.2011.243]
- 23 **Cheng JW**, Cheng SW, Ma XY, Cai JP, Li Y, Wei RL. The prevalence of primary glaucoma in mainland China: a systematic review and meta-analysis. *J Glaucoma* 2013; **22**: 301-306 [PMID: 22134352 DOI: 10.1097/IJG.0b013e31824083ca]
- 24 **Baskaran M**, Foo RC, Cheng CY, Narayanaswamy AK, Zheng YF, Wu R, Saw SM, Foster PJ, Wong TY, Aung T. The Prevalence and Types of Glaucoma in an Urban Chinese Population: The Singapore Chinese Eye Study. *JAMA Ophthalmol* 2015; **133**: 874-880 [PMID: 25974263 DOI: 10.1001/jamaophthalmol.2015.1110]
- 25 **Zhong H**, Li J, Li C, Wei T, Cha X, Cai N, Luo T, Yu M, Yuan Y. The prevalence of glaucoma in adult rural Chinese populations of the Bai nationality in Dali: the Yunnan Minority Eye Study. *Invest Ophthalmol Vis Sci* 2012; **53**: 3221-3225 [PMID: 22511635 DOI: 10.1167/iovs.11-9306]
- 26 **Lee JH**, Oh SY. Corneal endothelial cell loss from suture fixation of a posterior chamber intraocular lens. *J Cataract Refract Surg* 1997; **23**: 1020-1022 [PMID: 9379371 DOI: 10.1016/S0886-3350(97)80074-0]
- 27 **Verma S**, Nongpiur ME, Husain R, Wong TT, Boey PY, Quek D, Perera SA, Aung T. Characteristics of the Corneal Endothelium Across the Primary Angle Closure Disease Spectrum. *Invest Ophthalmol Vis Sci* 2018; **59**: 4525-4530 [PMID: 30208420 DOI: 10.1167/iovs.18-24939]
- 28 **Yee RW**. The effect of drop vehicle on the efficacy and side effects of topical glaucoma therapy: a review. *Curr Opin Ophthalmol* 2007; **18**: 134-139 [PMID: 17301615 DOI: 10.1097/ICU.0b013e328089f1c8]
- 29 **Schehlein EM**, Novack G, Robin AL. New pharmacotherapy for the treatment of glaucoma. *Expert Opin Pharmacother* 2017; **18**: 1939-1946 [PMID: 29172818 DOI: 10.1080/14656566.2017.1408791]
- 30 **Chen W**, Li Z, Hu J, Zhang Z, Chen L, Chen Y, Liu Z. Corneal alternations induced by topical application of benzalkonium chloride in rabbit. *PLoS One* 2011; **6**: e26103 [PMID: 22022526 DOI: 10.1371/journal.pone.0026103]
- 31 **Sandoval HP**, Al Sarraf O, Vroman DT, Solomon KD. Corneal endothelial cell damage after lens extraction using the fluid-based system compared to ultrasound phacoemulsification in human cadaver eyes. *Cornea* 2004; **23**: 720-722 [PMID: 15448500 DOI: 10.1097/01.ico.0000130184.56514.51]
- 32 **Niederer RL**, Perumal D, Sherwin T, McGhee CN. Age-related differences in the normal human cornea: a laser scanning in vivo confocal microscopy study. *Br J Ophthalmol* 2007; **91**: 1165-1169 [PMID: 17389741 DOI: 10.1136/bjo.2006.112656]
- 33 **Sheng H**, Bullimore MA. Factors affecting corneal endothelial morphology. *Cornea* 2007; **26**: 520-525 [PMID: 17525643 DOI: 10.1097/ICO.0b013e318033a6da]



Published By Baishideng Publishing Group Inc
7041 Koll Center Parkway, Suite 160, Pleasanton, CA 94566, USA
Telephone: +1-925-2238242
Fax: +1-925-2238243
E-mail: bpgoffice@wjgnet.com
Help Desk: <https://www.f6publishing.com/helpdesk>
<https://www.wjgnet.com>

