

Comparative Study of the Osteointegration of Irradiated and Non-irradiated Bone Grafts Used in Patients with Revision Hip Arthroplasty*

Estudo comparativo da osteointegração de enxertos ósseos irradiados e não irradiados utilizados em pacientes com revisão de artroplastia do quadril

André Ferreira da Silva¹ Uri Antebi¹ Emerson Kiyoshi Honda² Marco Rudelli²
Rodrigo Pereira Guimarães²

¹Musculoskeletal Tissue Bank, Irmandade da Santa Casa de Misericórdia de São Paulo, São Paulo, SP, Brazil

²Orthopedics and Traumatology Department, Santa Casa de São Paulo, Faculdade de Ciências Médicas da Santa Casa de São Paulo, São Paulo, SP, Brazil

Address for correspondence André Ferreira da Silva, MD, Rua Nossa Senhora do Desterro, 05, Terra Preta, Mairiporã, São Paulo, SP, 07600-000, Brasil (e-mail: ferreiradasilva_andre@yahoo.com.br).

Rev Bras Ortop 2019;54:477–482.

Abstract

Objective To evaluate and compare the osteointegration of irradiated and non-irradiated frozen bone grafts used in 21 patients undergoing revision hip arthroplasty procedures with the Exeter technique.


Methods A retrospective study of 21 patients undergoing revision hip arthroplasty with the Exeter technique using bone tissues treated or not with gamma radiation between 2013 and 2014. The patients were divided into two groups according to the use of grafts treated or not with ionizing radiation (gamma rays); as such, these groups were classified as irradiated or non-irradiated. The osteointegration results determined by radiographic analysis of these grafts were compared in the postoperative period of 6 and 12 months.

Results Comparing the graft osteointegration in all patients at 6 and 12 months postoperatively, we noticed a significant difference in the radiographic evaluations in this period ($p = 0.031$). Out of the patients studied, 7 were from the irradiated group,

Keywords


- ▶ osteointegration
- ▶ tissue bank
- ▶ bone grafts
- ▶ arthroplasty


* Work developed at Hospital Central da Irmandade da Santa Casa de Misericórdia de São Paulo, São Paulo, SP, Brazil.

 André Ferreira da Silva's ORCID is <https://orcid.org/0000-0002-8384-2208>.

 Uri Antebi's ORCID is <https://orcid.org/0000-0002-3185-7766>.

 Emerson Kiyoshi Honda's ORCID is <https://orcid.org/0000-0001-9448-2335>.

 Marco Rudelli's ORCID is <https://orcid.org/0000-0003-1106-0706>.

 Rodrigo Pereira Guimarães's ORCID is <https://orcid.org/0000-0002-0564-4660>.

Introduction

In Brazil, the most transplanted human tissue is homologous bone, followed by other transplants, such as skin, cornea and bone marrow transplants. Bone tissues are used in orthopedic and dental reconstructions, and their demand has grown over the last decade.¹

Autologous bone tissues are considered the gold standard in reconstructive surgeries because of their osteogenic,

received
July 5, 2018
accepted
March 12, 2019

DOI <https://doi.org/10.1055/s-0039-1694715>.
ISSN 0102-3616.

Copyright © 2019 by Sociedade Brasileira de Ortopedia e Traumatologia. Published by Thieme Revinter Publicações Ltda, Rio de Janeiro, Brazil

License terms



and 14 belonged to the non-irradiated group. No statistically significant differences were observed ($p = 0.804$) regarding osteointegration when we compared the irradiated and non-irradiated groups.

Conclusion There was no significant difference in the use of irradiated or non-irradiated grafts in revision hip arthroplasty procedures with the Exeter technique.

Resumo

Objetivo Avaliar e comparar a osteointegração dos enxertos ósseos congelados irradiados e não irradiados utilizados em 21 pacientes submetidos à revisão de prótese do quadril pela técnica Exeter.

Métodos Foi realizado estudo retrospectivo de 21 pacientes submetidos a revisão de artroplastia do quadril pela técnica Exeter com utilização de tecidos ósseos tratados ou não com radiação gama no período entre 2013 e 2014. Dividimos os pacientes em dois grupos, de acordo com o uso do enxerto tratado ou não com radiação ionizante (raios gama), que foram, portanto, classificados como: grupo irradiado e não irradiado. Os resultados da osteointegração por análise radiográfica destes enxertos foram comparados no pós-cirúrgico de 6 e 12 meses.

Resultados Quando comparamos a osteointegração dos enxertos no pós-cirúrgico de 6 e 12 meses de todos os pacientes, notamos que houve diferença significativa entre as avaliações radiográficas neste período ($p = 0,031$). Dos pacientes estudados, 7 pertenciam ao grupo irradiado, e 14, ao grupo não irradiado. Não foram observadas diferenças estatisticamente significativas ($p = 0,804$) quando a osteointegração entre os grupos irradiados e não irradiados foi comparada.

Conclusão Não houve diferença significativa no uso de enxerto irradiado e não irradiado nas revisões de artroplastias do quadril pela técnica Exeter.

Palavras-chave

- ▶ osteointegração
- ▶ banco de tecidos
- ▶ enxertos ósseos
- ▶ artroplastia

osteoinductive and osteoconductive properties; in addition, they do not cause immunological reactions. However, homologous bone tissues have advantages when compared to autologous tissues, including reduced morbidity, lack of a second surgical incision, and lower blood loss during surgery; moreover, homologous tissues enable reconstructions requiring a greater amount of graft.²⁻⁴

In orthopedics, bone grafts are used mainly in scoliosis surgeries, musculoskeletal tumor resection, pseudarthrosis treatment and revision hip and knee arthroplasty with increasing procedural numbers.^{2,4} The improvement of tissue banks in the preparation and supply of different types of graft increased the efficiency of bone transplants and revision arthroplasty surgeries with severe bone stock loss.⁵⁻⁷

There is a great concern in assuring the quality of bone tissues and the safety of the recipients regarding the transmission of infectious and contagious diseases.⁴

Tissue sterilization using ionizing radiation is the only process that provides a safety level of 10^{-6} , that is, the probability of finding a viable organism is 1:1,000,000; in addition, this method has advantages over other sterilization procedures, such as good penetrability, absence of toxic waste, and potential use as a final sterilization, thus avoiding the risk of contamination by poststerilization manipulation.⁸ Although gamma radiation from ^{60}Co sources has been applied in the sterilization of biological tissues for years, several authors demonstrate that this procedure can lead to structural and biological alterations according to the applied dose.⁹⁻¹¹

The present study evaluates and compares the osteointegration of irradiated and non-irradiated frozen bone grafts used in patients submitted to revision hip arthroplasty procedures.

Materials and Methods

This is a retrospective study of 21 patients undergoing revision hip arthroplasty procedures with the Exeter technique using bone tissues treated with or not gamma radiation between 2013 and 2014. A total of 14 patients were male, and 7 were female; their age ranged from 48 to 85 years (mean: 67.7 years). The study was approved by the Ethics in Research Committee, and was performed at the tissue bank in conjunction with the hip group from our institution.

Routine preoperative and postoperative radiological evaluations, performed at the immediate postsurgical period and at 6 and 12 months after the surgery, were analyzed to determine graft osteointegration, as shown in ▶ **Figure 1**.

The radiographical criteria proposed by Coon et al¹² and Azuma et al¹³ were used to interpret the osteointegration achieved 6 and 12 months after surgery, and to stratify the patients, as shown in ▶ **Table 1**.

The patients were divided into two groups according to the use of grafts treated or not with ionizing radiation (gamma rays); as such, these groups were classified as irradiated or non-irradiated.

The tissues were irradiated with gamma rays at a dose of 25 kGy, with a dose rate of 0.00138 kGy/s and an

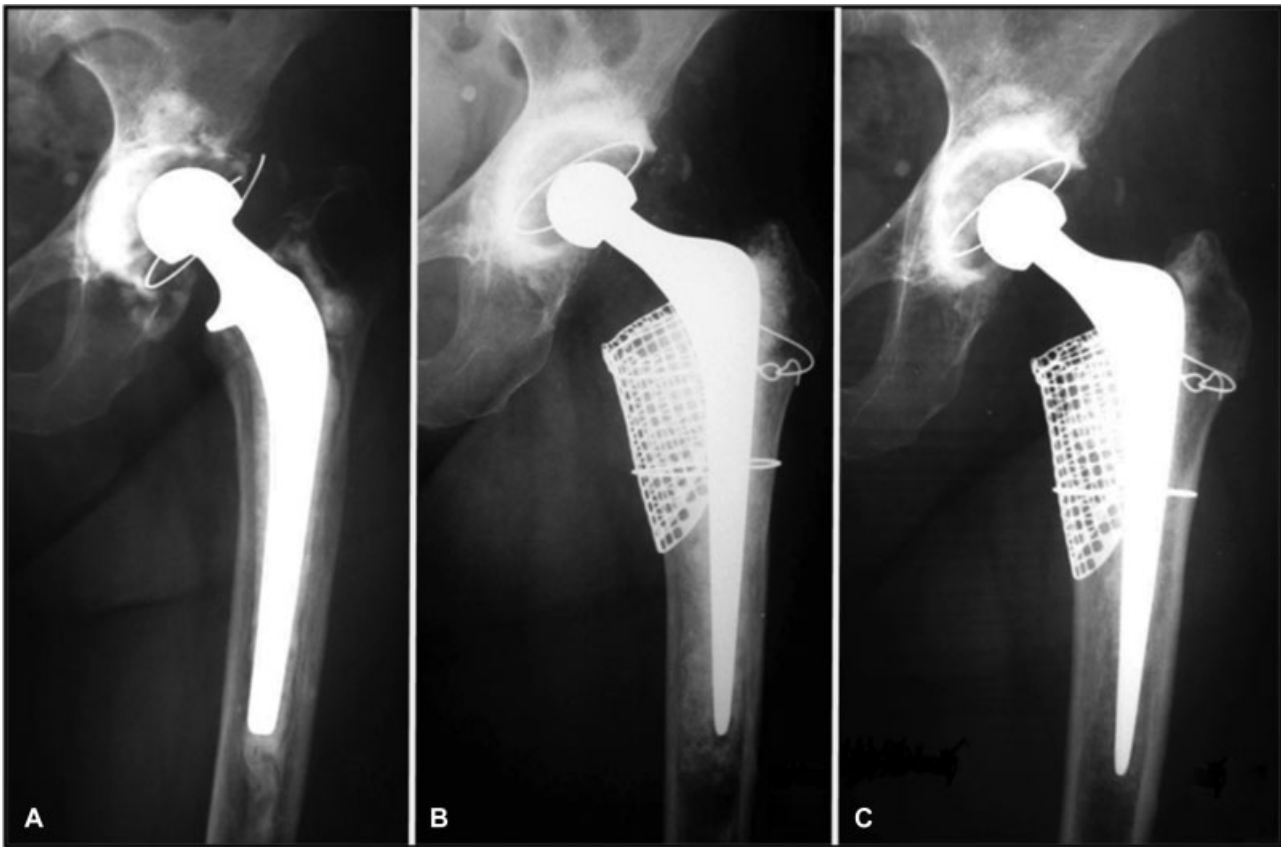


Fig. 1 Anteroposterior hip radiographs. (A) Preoperative radiography with assessment of left acetabular and femoral bone loss. (B) Postoperative radiograph immediately after prosthesis revision with irradiated bone graft in the acetabulum and femur. (C) Postoperative radiograph at 12 months, showing bone integration of the irradiated graft in the acetabulum and femur.

Table 1 Bone integration classification of the impacted graft using the Exeter technique, as described by Coon et al¹² and Azuma et al¹³

Osteointegration classification	Conditions proposed for osteointegration classification
1–Total graft osteointegration	Total formation of a continuous trabecular template at the interface between the bone graft and the recipient bone, denoting the appearance of a new trabecular pattern similar to a normal bone structure in all areas of the impacted graft, followed by bone tissue reorganization, disappearance of the sclerotic line at the graft–receptor interface, and identical radiodensity between the graft and the receptor bone.
2–Partial graft osteointegration	Partial formation of a continuous trabecular template at the interface between the bone graft and the recipient bone, denoting the appearance of a new trabecular pattern similar to a normal bone structure in part of the impacted graft, followed by bone tissue reorganization, partial disappearance of the sclerotic line at the graft–receptor interface and partially identical radiodensity between the graft and the receptor bone.
3–Absence of osteointegration	There was no graft osteointegration.
4–Inability to evaluate osteointegration	Impossibility to visualize the grafts due to the presence of screens or other prosthetic devices.

approximate temperature of -70°C , since these conditions reduce undesirable radiation effects, including high doses, high energy transfer rate and heating respectively, in order to maintain their biological integrity.⁴

The results were analyzed and compared between the groups. A total of 3 patients were excluded during the comparison of the irradiated and non-irradiated groups with osteointegration classification number 4. The statistical anal-

ysis was performed by result comparison using the unpaired, non-parametric Mann-Whitney Test for the statistical differences ($p < 0.05$).

Results

Out of the 21 patients studied, 7 belonged to the irradiated group (use of irradiated frozen bone graft), and 14 were from

the non-irradiated group (use of non-irradiated frozen bone graft). Their initial diagnoses for primary hip arthroplasty were: hip arthrosis (71.4%); femoral neck or acetabulum fracture (14.2%); femoral head necrosis (4.8%); developmental dysplasia of the hip (4.8%); and ankylosing spondylitis (4.8%). None of the evaluated cases presented infection.

The amount of bone grafts used in the patients ranged from 50 to 266 g (mean: 128.4 g).

► **Table 2** shows that 8 patients presented partial osteointegration at the 6-month postoperative radiographic evaluation, which evolved to total graft osteointegration at 12 months; in addition, 4 patients with no osteointegration at 6 months presented partial osteointegration 12 months after the procedure. However, 6 patients did not present osteointegration at both the 6- and 12-month examinations, and 3 patients could not be evaluated for osteointegration due to the presence of screens or other prosthetic devices. There

Table 2 Report of the radiographic evaluation of osteointegration of the transplanted bone grafts in the irradiated and non-irradiated groups 6 and 12 months after surgery using the Exeter technique and according to the proposed classification

Groups	Patients	Osteointegration classification	
		6 months after surgery	12 months after surgery
Irradiated	Patient #1	2	1
	Patient #2	3	2
	Patient #3	2	1
	Patient #4	4	4
	Patient #5	3	3
	Patient #6	2	1
	Patient #7	3	3
Non-irradiated	Patient #8	3	3
	Patient #9	2	1
	Patient #10	2	1
	Patient #11	3	2
	Patient #12	2	1
	Patient #13	3	3
	Patient #14	2	1
	Patient #15	3	2
	Patient #16	3	2
	Patient #17	4	4
	Patient #18	3	3
	Patient #19	2	1
	Patient #20	4	4
	Patient #21	3	3

Note: Osteointegration classification: 1- Total graft osteointegration; 2- Partial graft osteointegration; 3- Absence of osteointegration; 4- Inability to evaluate osteointegration.

was a significant difference between the results obtained at the 6- and 12-month evaluations ($p = 0.031$).

► **Figures 2** and **3** compare the percentage of osteointegration in the irradiated and non-irradiated groups. No statistically significant differences were found ($p = 0.804$).

Discussion

The Exeter technique has been applied by the hip group of our institution over the last decades. Although not the aim of this study, this technique was well-described by Wilson et al,¹⁴ who evaluated 705 cases with a high success rate (98.8%).

In revision hip arthroplasty surgeries, the first expected event of the biological response after bone transplantation is graft consolidation, as reported by Jasty and Harris.¹⁵ The graft can only consolidate, and, in some circumstances, it can also be integrated into the host bone. Therefore, consolidation and osteointegration are two different processes. Consolidation refers to the blending of the graft and the host bone through the formation of bone between them, whereas osteointegration is the replacement of the graft by the receptor bone through cellular reabsorption and recolonization, resulting in a progressive substitution.¹⁶

The time for the osteointegration process to occur depends on the mechanical stability, the amount of graft used, and the biological response of the recipient. Osteointegration is extremely important for bone stock restoration and longer prosthesis durability.¹⁷

We performed a postoperative retrospective evaluation of 21 patients submitted to revision hip arthroplasty procedures with the Exeter technique using irradiated and non-irradiated grafts. The epidemiological data of these patients, including age and gender, are only descriptive, because the number of cases was insufficient to perform a statistical analysis in this sample. However, Böhm and Bischel¹⁸ reported that there were no differences in graft integration when age, gender, body weight and diagnosis, among other criteria, were evaluated.

There is an intense concern to guarantee tissue quality and to promote the safety of patients receiving homologous tissues regarding the transmission of infectious, contagious diseases. To reduce possible contaminations, serological screening, history and social behavior evaluation, molecular biologic tests to detect RNA from the human immunodeficiency virus (HIV) and hepatitis C virus (HCV), clinical exams and microbiological controls are carried out in bone tissue donors; in addition, the procedures are performed using aseptic techniques.¹⁰ However, contamination during tissue collection, processing, preservation and storage is possible.¹⁹

The microbiological safety of musculoskeletal tissues can be increased with graft sterilization.

Gamma radiation is the most used modality in tissue banks, and it is an effective method to provide terminal sterilization for biological tissues; however, there are reports of the possible deleterious effects on the mechanical and biological properties of the tissues depending on the radiation dose applied.¹⁰ As such, lower radiation doses, ranging from 15 to 25 kGy, are often used, whereas high doses (over 25 kGy) are seldom applied.

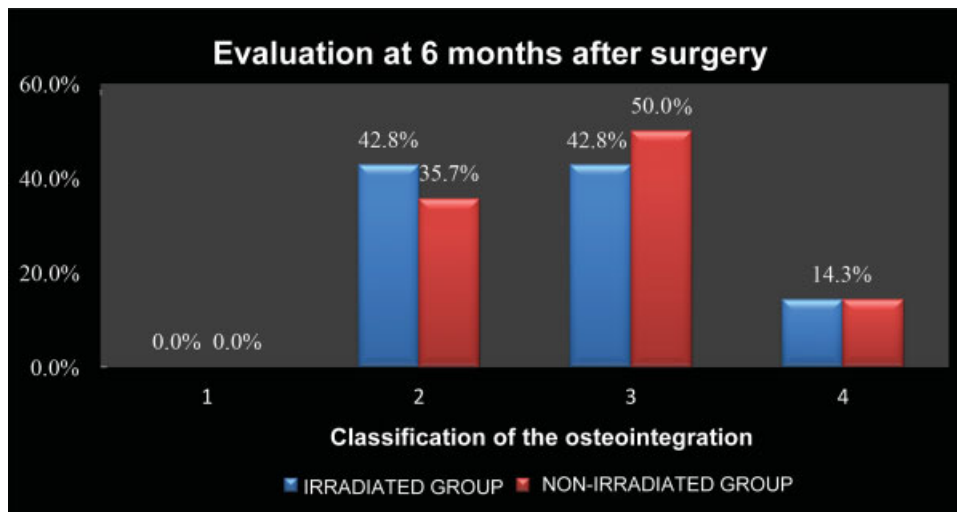


Fig. 2 Comparison of the osteointegration percentage 6 months after revision hip arthroplasty procedures using irradiated or non-irradiated bone grafts and the Exeter technique. Osteointegration classification: 1- Total graft osteointegration; 2- Partial graft osteointegration; 3- Absence of osteointegration; 4- Inability to evaluate osteointegration.

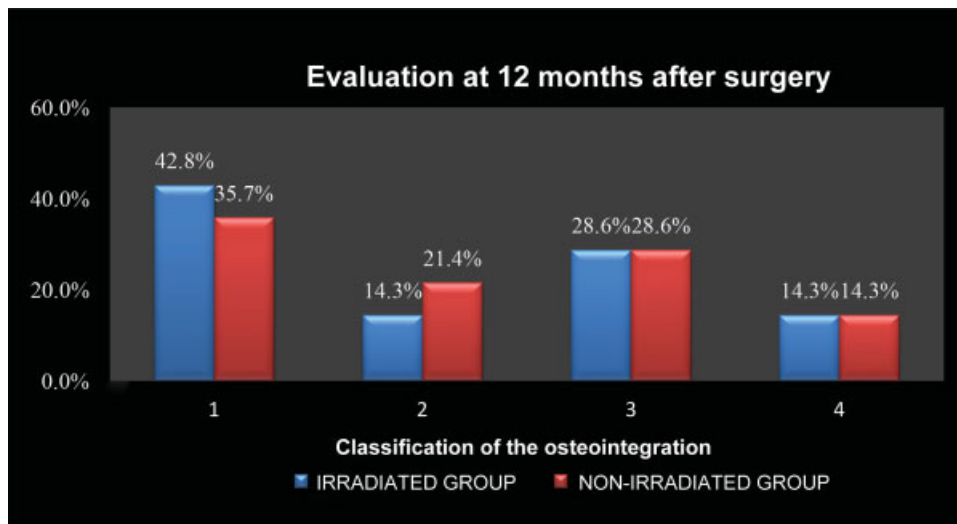


Fig. 3 Comparison of the osteointegration percentage 12 months after revision hip arthroplasty procedures using irradiated or non-irradiated bone grafts and the Exeter technique. Osteointegration classification: 1- Total graft osteointegration; 2- Partial graft osteointegration; 3- Absence of osteointegration; 4- Inability to evaluate osteointegration.

Osteointegration analysis through follow-up radiographic images was proposed by Conn et al,¹² who considered that the graft was integrated when the radiodensity between the graft and the recipient bone was identical, with the formation of a continuous trabecular template at the graft-receptor interface; this template denotes a new trabecular pattern according to the loads applied to this region, and it is followed by bone tissue reorganization. Later, Azuma et al¹³ considered the graft incorporated when the scleral line at the graft-receptor interface disappeared and normal graft density was restored. Our group decided to associate these definitions to better evaluate bone integration. However, this analysis through radiographic imaging can be subjective and difficult to interpret, especially in the presence of synthetic material, such as metal screens, acetabular reinforcing rings, and screws.

The best technique to prove osteointegration is the histological study of the transplanted graft; however, this technique is not performed routinely, mainly because of its invasiveness.²⁰ The comparison between osteointegration at 6 and 12 months after transplantation shows significant differences ($p = 0.031$), which can be explained by the greater radiological evidences of osteointegration at 12 months.

When we compared the osteointegration between the groups using irradiated and non-irradiated grafts, we did not observe statistically significant differences, but we believe that further studies may determine if the use of irradiated bones with controlled doses of gamma radiation (25 kGy) is as effective in bone reconstructions for revision hip arthroplasty procedures as non-irradiated grafts. These results were also described by Emms et al,²¹ who studied the use of irradiated grafts in acetabular reconstructions

in medium and long periods of time (2 to 12 years) in 110 patients, and reported good postoperative follow-up results, comparable to those obtained with non-irradiated grafts.

Conclusion

There was no significant difference in the use of irradiated or non-irradiated grafts in revision hip arthroplasties with the Exeter technique

Conflicts of Interest

The authors have none to declare.

References

- 1 Associação Brasileira de Transplantes de Órgãos (ABTO). Registro Brasileiro de Transplantes. Ano XXII n. 4, jan/fev 2016. Available at: <http://www.abto.org.br/abtov03/default.aspx?mn=457&c=900&s=0>
- 2 Halliday BR, English HW, Timperley AJ, Gie GA, Ling RS. Femoral impaction grafting with cement in revision total hip replacement. Evolution of the technique and results. *J Bone Joint Surg Br* 2003; 85(06):809–817
- 3 Zabeu JL, Mercadante MT. Substitutos ósseos comparados ao enxerto ósseo autólogo em cirurgia ortopédica. Revisão sistemática da literatura. *Rev Bras Ortop* 2008;43(03):59–68
- 4 Antebi U, Mathor MB, Silva AF, Guimarães RP, Honda EK. Efeitos da radiação ionizante nas proteínas presentes em ossos humanos desmineralizados, liofilizados ou congelados. *Rev Bras Ortop* 2016;51(02):224–230
- 5 Sutherland CJ, Wilde AH, Borden LS, Marks KE. A ten-year follow-up of one hundred consecutive Müller curved-stem total hip-replacement arthroplasties. *J Bone Joint Surg Am* 1982;64(07):970–982
- 6 Friedlaender GE, Goldberg VM. Bone and cartilage allografts: biology and clinical applications. Illinois: American Academy of Orthopaedic Surgeons; 1991
- 7 Graham NM, Stockley I. The use of structural proximal femoral allografts in complex revision hip arthroplasty. *J Bone Joint Surg Br* 2004;86(03):337–343
- 8 Dzedzic-Goclawska A. The application of ionising radiation to sterilise connective tissue allografts. In: Phillips GO. Radiation and tissue banking. World Scientific Singapore; 2000:57–99
- 9 Vastel L, Masse C, Crozier E, et al. Effects of gamma irradiation on mechanical properties of defatted trabecular bone allografts assessed by speed-of-sound measurement. *Cell Tissue Bank* 2007;8(03):205–210
- 10 Nguyen H, Morgan DA, Forwood MR. Sterilization of allograft bone: effects of gamma irradiation on allograft biology and biomechanics. *Cell Tissue Bank* 2007;8(02):93–105
- 11 Pekkarinen T, Hietalal O, Jämsä T, Jalovaara P. Gamma irradiation and ethylene oxide in the sterilization of native reindeer bone morphogenetic protein extract. *Scand J Surg* 2005;94(01):67–70
- 12 Conn RA, Peterson LF, Stauffer RN, Lstrup D. Management of acetabular deficiency: long term results of bone grafting the acetabulum in total hip arthroplasty. *Trans Orthop Res Soc* 1985;9:451–452
- 13 Azuma T, Yasuda H, Okagaki K, Sakai K. Compressed allograft chips for acetabular reconstruction in revision hip arthroplasty. *J Bone Joint Surg Br* 1994;76(05):740–744
- 14 Wilson MJ, Hook S, Whitehouse SL, Timperley AJ, Gie GA. Femoral impaction bone grafting in revision hip arthroplasty: 705 cases from the originating centre. *Bone Joint J* 2016;98-B(12):1611–1619
- 15 Jasty M, Harris WH. Salvage total hip reconstruction in patients with major acetabular bone deficiency using structural femoral head allografts. *J Bone Joint Surg Br* 1990;72(01):63–67
- 16 Galia CR, Moreira LF. The Biology of Bone Grafts: Recent Advances in Arthroplasty, 2012. Samo K, Fokter, IntechOpen, InTech; 235–254. DOI: 10.5772/27381.
- 17 Schreurs BW, Slooff TJ, Gardeniers JW, Buma P. Acetabular reconstruction with bone impaction grafting and a cemented cup: 20 years' experience. *Clin Orthop Relat Res* 2001;(393):202–215
- 18 Böhm P, Bischel O. The use of tapered stems for femoral revision surgery. *Clin Orthop Relat Res* 2004;(420):148–159
- 19 Phillips GO. Module 5: Processing. In: Multimedia distance learning package on tissue banking. Singapura: IAEA; 1997
- 20 Devito FS, Aristides RS, Honda EK, Chueire AG. O uso de enxerto homólogo na revisão de artroplastias do quadril com cimentação do componente acetabular. *Acta Ortop Bras* 2006;14(05):280–282
- 21 Emms NW, Buckley SC, Stockley I, Hamer AJ, Kerry RM. Mid- to long-term results of irradiated allograft in acetabular reconstruction: a follow-up report. *J Bone Joint Surg Br* 2009;91(11):1419–1423