

ORIGINAL ARTICLE

## Isolation and molecular detection of *Avipoxvirus* from field outbreaks in Mymensingh, Bangladesh

Saifur Rahman, Md. Ariful Islam, Md. Shafiqul Islam, K. H. M. Nazmul Hussain Nazir, Md. Shahidur Rahman Khan  
Department of Microbiology and Hygiene, Bangladesh Agricultural University, Mymensingh, Bangladesh.

### ABSTRACT

**Objective:** The present study was performed for isolation, identification, and molecular detection of *Avipoxvirus* [*Turkeypox virus* (TPV), *Fowlpox virus* (FPV), and *Pigeonpox virus* (PPV)] from field outbreaks in some selected areas of Mymensingh division, Bangladesh.

**Materials and Methods:** A total of 60 suspected cutaneous nodular samples (10 TPV, 20 PPV, and 30 FPV) were collected. The samples were then subjected to isolation and identification by chicken embryo propagation followed by confirmation using polymerase chain reaction (PCR).

**Results:** The TPV, FPV, and PPV were successfully isolated and identified from the nodular samples using embryo propagation and PCR technique targeting pox virus *p4b* gene. Out of 10 Turkeypox suspected field samples, five (50%) were positive for TPV. Similarly, among 30 Fowl pox suspected field samples, 12 (40%), and out of 20 Pigeonpox suspected field samples, eight (40%) were found to be positive for FPV and PPV, respectively. The overall prevalence of avipox (TPV, FPV, and PPV) virus infections in Mymensingh division was 41.67% ( $n = 25/60$ ).

**Conclusion:** This study has shown that TPV, FPV, and PPV are circulating in Mymensingh division. The isolated TPV, FPV, and PPV field isolates can be used as vaccine candidates to develop an effective vaccine for effective controlling of the avipox in Mymensingh division and surrounding areas.

### ARTICLE HISTORY

Received November 28, 2018  
Revised January 07, 2019  
Accepted January 09, 2019  
Published January 29, 2019

### KEYWORDS

Turkeypox virus; fowlpox virus;  
pigeonpox virus; PCR



This is an Open Access article distributed under the terms of the Creative Commons Attribution 4.0 Licence (<http://creativecommons.org/licenses/by/4.0>)

### Introduction

Poultry is one of the most flourishing sectors in Bangladesh. With the advancement of the poultry industry in Bangladesh, nowadays, people are showing their interests in rearing turkey according to a report of “City Farmer News” (2018). *Avipoxvirus* infection has emerged as a threat to turkey and other avian species like chicken, pigeon, and quails during 4–6 weeks of age [1,2]. Though every member of *Avipoxvirus* is host specific as well as can be distinguished antigenically, yet a cross relationship is present among these species [3]. The disease is characterized by the development of discrete nodular proliferative lesions in the non-feathered areas like the combs, wattles, eyelids, legs, and mucous membranes of the oral cavity, upper respiratory, and digestive systems [4]. It is still a malady and an enzootic to the growing chicken of any age, sex, and breed either in organized or in rural poultry

farming system in Bangladesh [5]. This is an economically important disease in commercial poultry farming [6] as it may cause to reduce egg production and growth rate and increase the mortality rate [7]. Though it is an economically important disease of poultry, vaccination to the commercial flocks has helped to reduce the losses associated with the disease in the population of chickens [8]. The disease is quite common among the indigenous chickens, which are unvaccinated to pox virus [9]. These birds, therefore, may play an important epidemiological role in the maintenance and transmission of the virus to the commercial flocks [1]. In Bangladesh, Fowl pox (FP), Pigeonpox (PP), and Turkeypox (TP) infections are commonly found, which are caused by members of avipox group like *Fowlpox virus* (FPV), *Pigeonpox virus* (PPV), and *Turkeypox virus* (TPV), respectively.

**Correspondence** Md. Shahidur Rahman Khan ✉ [msrkh001@yahoo.com](mailto:msrkh001@yahoo.com) 📧 Department of Microbiology and Hygiene, Bangladesh Agricultural University, Mymensingh, Bangladesh.

**How to cite:** Rahman S, Islam MA, Islam MS, Nazir KHMNH, Khan MSR. Isolation and molecular detection of *Avipoxvirus* from field outbreaks in Mymensingh, Bangladesh. *J Adv Vet Anim Res* 2019; 6(1):54–9.

Along with rural chicken and pigeon production, nowadays, people are rearing turkey in small scale and scattered condition. There is a paucity of actual economic or survey data in Bangladesh on turkey rearing, productivity, and economic value. But according to the news of "The Financial Express" (2016), a farmer stated that he started his farm in 2014 with only 22 turkey birds brought from India. Now, there are 200 birds on his farm. He sold around 700 birds in the last 2 years. Each pair of the birds was sold by Bangladesh Taka 6,000–8,000. Turkey grows faster like broiler chickens and become suitable for marketing within 12–20 weeks. The rearing method is similar to other poultry birds rearing like chickens, ducks, and quails (City Farmer News, 2018). That is why turkey farming is getting popularity to farmers. However, the TPV infection in turkeys during their early age has been found as a big problem. Although vaccines are available against FPV and PPV infections, no suitable vaccine is available against TPV infection. Thus, farmers are usually using FPV vaccine to save their turkeys from TPV infection. To our knowledge, limited research studies have been conducted to prove the antigenic similarities between TPV and FPV. Therefore, vaccine developed from local TPV isolate could be a possible way to control the disease.

On the basis of clinical signs and lesions, avipox disease can be diagnosed straightforward [10], while the conventional laboratory diagnosis of FPV, PPV, and TPV is carried out by histopathological examinations, propagation of virus on chorioallantoic membrane (CAM) of embryonated chicken eggs or cell cultures, and serologic methods [11,12,13]. Polymerase chain reaction (PCR) has been proved as the most sensitive technique for routine diagnosis [14–18]. PCR along with restriction endonuclease enzyme analysis and then sequence analysis of the amplified fragments can also be used for the molecular detection, differentiation, and characterization of FPV, PPV, and TPV isolates [19–21].

In Bangladesh, few research studies have been conducted on isolation and detection of TPV, FPV, and PPV [5,11,22]; however, comparative studies among these viruses were yet to be reported in Bangladesh. Considering the facts, the present study was undertaken to isolate, identify, and carry out molecular detection of the TPV, FPV, and PPV from the field outbreaks using embryonated hen eggs followed by molecular techniques, which can further be used to select appropriate vaccine candidates against these infections.

## Materials and Methods

### *Ethical approval*

The research methodology was reviewed and ethical approval was issued by the Animal Welfare and Ethical

Committee, Bangladesh Agricultural University (BAU). The approval number is 10/AWEC/BAU/2018.

### *Sampling, sample collection, and inoculum preparation*

To perform the present research work, different areas in Mymensingh division like the Veterinary Teaching Hospital of BAU, Mymensingh, Trishal-Mymensingh, Fulbaria-Mymensingh, Police lines area-Mymensingh, Fatema nagar-Mymensingh, Sarishabari-Jamalpur, Nakhla-Sherpur, and Netrokona Sadar Thana-Netrokona were selected as the study areas for sampling during the period from February 2016–May 2017 from the natural outbreaks of the avipox disease. A total of 60 samples (nodular lesions) were collected from outbreak areas; of which, 10 were TP suspected field samples, 30 were FP suspected field samples, and 20 were PP suspected field samples (Fig. 1).

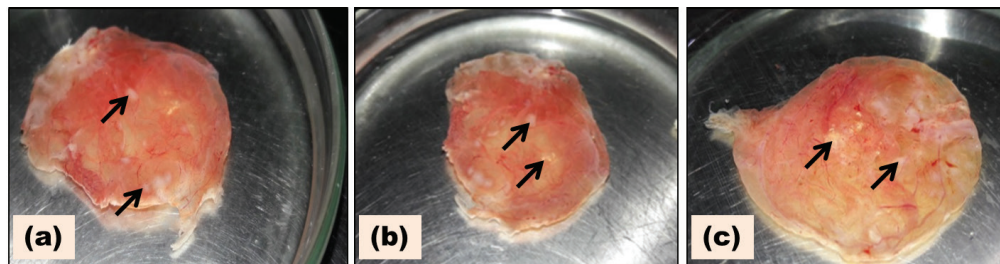
The nodular tissues were collected aseptically from the suspected birds and transported to the Virology Laboratory at the Department of Microbiology and Hygiene, BAU, Mymensingh by maintaining the proper cool chain. In the laboratory, the TP, FP, and PP suspected bird samples (nodular lesions) were subjected to grinding for the preparation of inocula (20% suspension) as described by Kabir et al. [23]. Parts of sterile inocula were used for inoculation and the remaining inocula were preserved at –20°C for future use.

### *Virus isolation*

The TPV, FPV, and PPV were isolated by inoculating the prepared inocula into 10–12 days old embryonated hen eggs through CAM route. For this, at first, the embryonated egg was marked with a marker at the center of the air sac followed by the creation of an artificial air sac over the CAM. Using a sterilized 1 ml tuberculin syringe fitted with a 1/2 inch needle, 0.5 ml of sterile inoculum was inoculated into the CAM. The openings on the air sac and shell of the inoculated eggs were sealed with melted wax. The eggs were then placed in egg trays in a horizontal position with the artificial air cell keeping upward and were incubated for 5–6 days at 37°C in egg incubator (Incubator and Hatcher, MG800H ECO, Italy). The eggs were candled twice daily throughout the period of incubation. The embryos that died within 24 h of inoculation were discarded considering the death due to the non-specific cause. After 5–6 days of inoculation, the embryos were chilled in the refrigerator from 4°C to 8°C for 1–2 h. After chilling, the eggs were removed from the refrigerator and the eggshell was painted with tincture of iodine over the air cell and then broken with a pair of sterile forceps. The thickened CAM was harvested for inoculum preparation. By following the same procedure, several passages were given to increase the virus concentration, and the CAMs with pock



**Figure 1.** Avipox infected birds from field outbreaks. (a) Chicken, (b) Pigeon, and (c) Turkey.



**Figure 2.** Thickened CAM with characteristic pock lesion. (a) TPV, (b) FPV, and (c) PPV. Black arrows indicate pock lesions.

lesions were collected for DNA extraction followed by PCR confirmation.

#### **Polymerase chain reaction and agarose gel electrophoresis**

The TPV, FPV, and PPV isolates were identified using PCR technique targeting pox virus *p4b* gene with the primer set (p2fPF—5' CAGCAGGTGCTAAACAACAA 3' and p2fPR—5' CGGTAGCTTAACGCCGAATA 3') having the amplification size of 578 bp [24]. Reference viral vaccines of FP and PP were used as positive control, which were collected from Livestock Research Institute, Mohakhali, Dhaka (Fowlpox vaccine, batch no. 206 and Pigeon pox vaccine, batch no. 13). DNA from the viruses was extracted by using Wizard® Genomic DNA Purification Kit (Promega, USA) as per instructions of the manufacturer. PCR reaction mixture was prepared (Master mix-12.5 µl, Forward primer-1 µl, Reverse primer-1 µl, Template DNA-4 µl, and Nuclease-free water-6.5 µl). PCR was done in a thermal cycler (Mastecycler, Eppendorf, Germany) as describe by Roy et al. [25] with slight modifications as follows: initial denaturation at 94°C for 5 min, followed by 35 cycles of denaturation at 94°C for 45 sec, annealing at 48°C for 1.5 min, elongation at 60°C for 2 min, and a final extension at 60°C for 10 min. Then, 1.5% agarose gel was prepared and electrophoresis of the PCR products was done. Then, the gel was placed on the floor of the dark chamber of UV transilluminator for image documentation.

#### **Results**

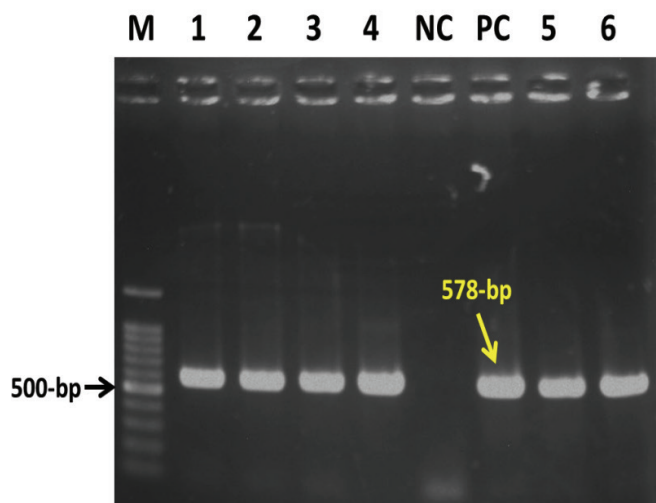
The TPV, FPV, and PPV were successfully isolated and identified from the collected nodular samples using embryo propagation and PCR technique targeting pox virus *p4b* gene. Of the 60 nodular samples tested, 25 were found to be positive for avipox (TPV, FPV, and PPV). Out of 10 TP suspected field samples, 5 (50%), out of 30 FP suspected field samples, 12 (40%), and out of 20 PP suspected field samples, 8 (40%) were found to be positive. The overall prevalence of avipox (TPV, FPV, and PPV) virus infections in Mymensingh division was 41.67%.

Development of discrete pock lesions along with thickened CAM proved the growth of FPV, PPV, and TPV viruses after several passages. First and second passages showed a negative result, while third and fourth passages showed positive results. In the fourth passage, the whitish granule or nodule like structure called pock lesion was observed in the CAM (Fig. 2). The CAMs with pock lesions were collected for DNA extraction and the presence of TPV, FPV, and PPV was confirmed by PCR (Figs. 3–5). The results of propagation and molecular detection of TPV, FPV, and PPV are presented in Table 1.

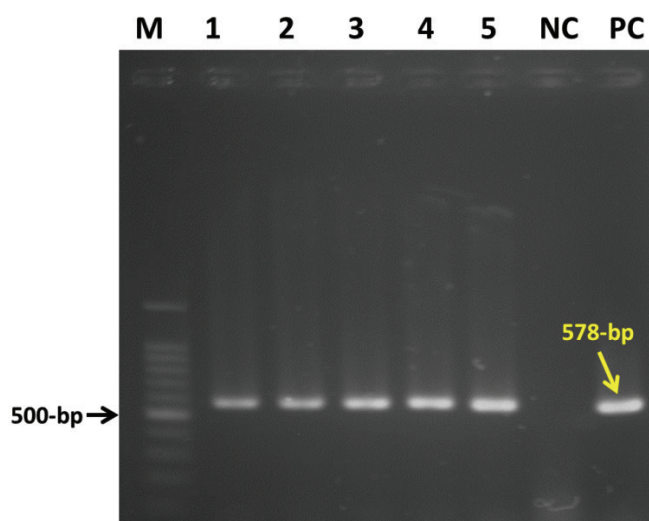
#### **Discussion**

Backyard poultry population plays an important role in the rural economy since 75%–80% of the total poultry

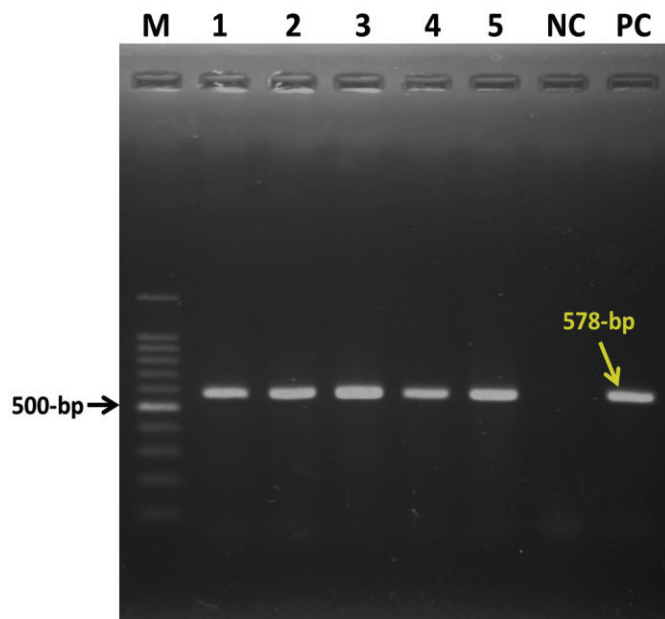




**Figure 3.** Electrophoresis results of PCR products of Turkeypox virus isolates showing specific bands on 1.5% Agarose gel. *M* = 100 bp DNA marker. Lanes 1–4 and Lanes 5–6 = Turkeypox virus isolates (578 bp). NC = negative control. PC = positive control (578 bp).



**Figure 5.** Electrophoresis results of PCR products of Pigeonpox virus isolates showing specific bands on 1.5% Agarose gel. *M* = 100 bp DNA marker. Lane 1–5 = Pigeonpox virus isolates (578 bp). NC = negative control. PC = positive control (578 bp).



**Figure 4.** Electrophoresis results of PCR products of Fowlpox virus isolates showing specific bands on 1.5% Agarose gel. *M* = 100 bp DNA marker. Lanes 1–5 = Fowlpox virus isolates (578 bp). NC = negative control. PC = positive control (578 bp).

population in Bangladesh is occupied by rural poultry [26]. The TPV, FPV, and PPV infections are causing a considerable loss in the rural poultry production. Very few research studies have been carried out on avipox infections (TPV, FPV, and PPV) in Bangladesh. The present

study has shown that the TPV, FPV, and PPV were circulating in Mymensingh division, and the overall prevalence of avipox (TPV, FPV, and PPV) virus infections was 41.67% and *p* value was recorded as 0.004 ( $p < 0.01$ ), which indicates that the results were significant. The prevalence of TPV in turkey was 50% ( $n = 5/10$ ), whereas the prevalence of FPV in chicken was 40% ( $n = 12/30$ ), which agreed with the findings of Masola et al. [27] who stated that out of 154 investigated samples, the prevalence of FPV was 42.86%. The prevalence of PPV in pigeon was 40% ( $n = 8/20$ ), which partially supported the findings of Fahmy et al. [28], who reported that the prevalence of PPV in pigeon was 62.5%.

The present research work was selected and performed considering the specific objective as the isolation, identification, and detection of TPV, FPV, and PPV field isolates using cultural and molecular techniques. For the study, samples were collected on the basis of clinical signs and lesions [10] and most of the suspected birds were up to 3–8 weeks of age, which supports the findings of Back et al. [2] where it is stated that Avipox is a common viral disease of chickens, pigeons, turkeys, ostriches, quails, pheasants, and other wild birds, particularly of young birds up to 4–6 weeks of age. After collection and processing of samples, an amount of 0.5 ml of inoculum was used for the inoculation of each fertile 10–12 days old embryonated hen eggs through CAM route. After inoculation of TPV, FPV, and PPV, the development of discrete pock lesions along with thickening of CAM proved the growth of TPV, FPV, and PPV. The finding of the present

**Table 1.** Results of embryonated egg propagation and molecular detection of TPV, FPV, and PPV Using CAM route and PCR, respectively.

Types of samples	Number of samples propagated	Number of samples positive (prevalence) using propagation technique	Total no. of suspected Samples (CAMs with pock lesions)	PCR positive samples from field cases (percentage positive)
TPV	10	5 (50%)	5	5 (100%)
FPV	30	12 (40%)	12	12 (100%)
PPV	20	8(40%)	8	8 (100%)

study supports the findings of Zhao et al. [29] and Buxton and Fraser [30] who mentioned thickening of CAM upon inoculation with fowlpox and pigeonpox viruses. Pandey and Mallick [31] also reported large and small secondary pock, necrosis, and edematous lesion on CAM of developing chick embryo upon inoculation with fowlpox and pigeonpox viruses. The highest growth of pox virus was observed on fifth to sixth days post inoculation. No growth observed on first-to-second day postinoculation of fowlpox and pigeonpox viruses, which confirms the finding of Cunningham [3]. Cunningham [3] described that the lesion produced on CAM by fowlpox and pigeonpox viruses on the sixth day was compact gray and was about 5 mm thick with a central necrotic area. Collected CAMs were subjected to molecular detection by PCR for confirmation. Molecular detection rate of TPV, FPV, and PPV from the collected CAMs was 100% in this study, which supports the finding of Roy et al. [25] where the genome detection rate of TPV, FPV, and PPV was almost 100% by PCR. Results of the molecular findings of the present study partially agreed with the findings of Fahmy et al. [28]; in their study, they reported that out of the eight suspected samples, only five (62.5%) were positive. Routine virus isolation on CAM of embryonated chicken eggs [12,13] and confirmation with PCR have proved to be the most sensitive techniques [8,15,16,17,20,33] for TPV, FPV, and PPV from the present research.

The species difference, sample size, hygienic, and environmental and geographic variations may contribute to the differences among the prevalence percentages, which were also stated by Masola et al. [27]. Failure in isolation of TPV, FPV, and PPV from the remaining samples could be due to the cutaneous nodules associated with other disease like papillomatosis [33] and/or mange [34], and discrepancies with the previous report of other study might be due to collection of samples at the recovery stage of the disease or might be due to presence of very low or no viruses particles in the collected samples, method of sample processing, sample treatments, age of the embryos, and quality of the field samples during the period of collection. Although the findings showed no significant differences in isolation and identification of TPV using chicken embryo propagation technique and PCR using the same primer

used for FPV and PPV, the result still cannot be concluded unless or until sequencing of PCR products and phylogenetic analysis are performed.

The limitation of the study was nucleotide sequencing analysis of the PCR detected samples to know the origin of the circulating TPV, FPV, and PPV isolates in Mymensingh division. As a continuation of the present study, identification of TPV, FPV, and PPV by PCR product sequencing and phylogenetic analysis might be required for future research work to identify their origin and relatedness.

## Conclusion

This study revealed that TPV, FPV, and PPV were circulating in Mymensingh division and found to be an important cause of rural or backyard poultry diseases. TPV, FPV, and PPV were successfully isolated and identified from the collected nodular samples from suspected diseased turkeys, chickens, and pigeons, respectively, by cultural and molecular techniques. These field isolates can be used as a vaccine candidate to develop an effective vaccine against TPV, FPV, and PPV infections, and PCR products can be used for sequencing and phylogenetic analysis.

## Acknowledgments

The authors are grateful to the Ministry of Science and Technology for financial support, and to the Head of the Department of Microbiology and Hygiene, Bangladesh Agricultural University (BAU) for providing laboratory supports.

## Conflict of Interests

The authors have declared that no conflict of interests exists.

## Authors' contribution

Saifur Rahman designed the study, interpreted the data, and drafted the manuscript. Md. Shahidur Rahman Khan and Md. Ariful Islam were involved during the study design, collection, and testing of the sample in the laboratory. Md. Shafiqul Islam and K. H. M. Nazmul Hussain Nazir took part in drafting and critical checking of this manuscript.

## References

- [1] Tripathy DN, Reed WM. Pox. In: Saif YM, Barnes HJ, Fadly AM, Glisson JR, McDougald LR, Swayne DE (eds.). *Diseases of Poultry* (CD version). 11th edition, Iowa State Press, Ames, IA, pp 253–269, 2003.
- [2] Back A, Soncini RA, Ruthes O, Madureira S, Flores R. An atypical fowl pox outbreak in broilers in southern Brazil. *Avian Dis* 1995; 39:902–6; <https://doi.org/10.2307/1592431>
- [3] Cunningham CH. Avian Pox. In: Hofstad MS, Calnek BW, Helnboldt CF, Ried WM, Yoder HW (eds.). *Diseases of poultry*. 7th edition, Iowa State University Press, Ames, IA, pp 597–609, 1974.
- [4] Medina FM, Ramirez GA, Hernandez A. Avian pox in white-tailed laurel-pigeons from the Canary Islands. *J Wildlife Dis* 2004; 40(2):351–5; <https://doi.org/10.7589/0090-3558-40.2.351>
- [5] Siddique B, Rahman MB, Amin MM, Rahman MM. Antibody titre in chicks following pigeon pox virus inoculation. *Bangladesh Vet J* 1997; 14:12–4.
- [6] Pledger A. Avian pox virus infection in a mourning dove. *Can Vet J* 2005;46:1143–5.
- [7] Ariyoshi R, Takase K, Matsuura Y, Deguchi K, Ginnaga A, Fujikawa H. Vaccination against fowlpox virus via drinking water. *J Vet Med Sci* 2003; 65(10):1127–30; <https://doi.org/10.1292/jvms.65.1127>
- [8] Odoya EM, Abegunde A, Omotainse SO, Gwankat E, Okapara UG. Outbreak of turkey pox disease in fowl pox vaccinated poult in Vom Plateau State of Nigeria. *Afr J Clin Exp Microbiol* 2006; 7: 136–8; <https://doi.org/10.4314/ajcem.v7i2.7443>
- [9] Adebajo MC, Ademola SI, Oluwaseun A. Seroprevalence of fowl pox antibodies in indigenous chickens in Jos North and South Council Areas of Plateau State, Nigeria: implication for vector vaccine. *Vet Sci*. 2012; ID 154971:1–4; <https://doi.org/10.5402/2012/154971>
- [10] Mockett APA. Fowl pox and other avian poxes. In: Jordan FTW, Pattison M (eds.). *Poultry disease*. 4th edition, Saunders, London, UK, pp 166–72, 1996.
- [11] Islam MR, Khan MSR, Islam MA, Kayesh MEH, Karim MR, Gani MO, et al. Comparative efficacy of imported fowl pox virus vaccine with locally produced one in backyard chicks. *Bangladesh J Vet Med* 2008; 6:23–6; <https://doi.org/10.3329/bjvm.v6i1.1334>
- [12] Tripathy DN, Reed WM. Pox. In: Swayne DE, Glisson JR, Jackwood MW, Pearson JE Reed WM (eds.). *A laboratory manual for the isolation and identification of Avian pathogens*. American Association of Avian Pathologists, University of Pennsylvania, New Bolton Center, Kennett Square, PA, pp 137–140, 1997.
- [13] Wang J, Meers J, Spradbrow PB, Robinson WF. Evaluation of immune effects of fowl pox vaccine strains and field isolates. *Vet Microbiol* 2006; 116:106–19; <https://doi.org/10.1016/j.vetmic.2006.03.012>
- [14] Lee LH, Lee KH. Application of the polymerase chain reaction for the diagnosis of fowl pox virus infection. *J Virol Met* 1997; 63: 113–9; [https://doi.org/10.1016/S0166-0934\(96\)02119-2](https://doi.org/10.1016/S0166-0934(96)02119-2)
- [15] Weli SC, Okeke MI, Tryland M, Nilssen O, Traavik T. Characterization of avipox viruses from wild birds in Norway. *Can J Vet Res* 2004; 68:140–5.
- [16] Singh A, Dash BB, Kataria JM, Dhama K. Application of polymerase chain reaction and restriction endonuclease analysis for the detection and differentiation of turkey-pox and fowl pox virus infections. *Indian J Ani Sci* 2007;77:521–5.
- [17] Jarvi S, Triglia D, Giannoulis A, Farias M, Bianchi K, Atkinson CT. Diversity, origins and virulence of avipox viruses in Hawaiian forest birds. *Conserv Gene* 2008; 9:339–48; <https://doi.org/10.1007/s10592-007-9346-7>
- [18] Balachandran C, Pazhanivel N, Prabhakar TG, Murugadas V, Prabakar P. Avipox virus infection in rosella parakeet (*Platyercus* sp.). *J Adv Vet Res* 2012; 2:184–7.
- [19] Coupur BE, Teo T, Boyle DB. Restriction endonuclease mapping of the fowlpox virus genome. *Virology* 1990;179:159–67; [https://doi.org/10.1016/0042-6822\(90\)90285-Y](https://doi.org/10.1016/0042-6822(90)90285-Y)
- [20] Tadese T, Reed WM. Detection of specific reticuloendotheliosis virus sequence and protein from REV-integrated fowl pox virus strains. *J Virol Met* 2003;110:99–104; [https://doi.org/10.1016/S0166-0934\(03\)00106-X](https://doi.org/10.1016/S0166-0934(03)00106-X)
- [21] Luschow D, Hoffmann T, Hafez HM. Differentiation of avian poxvirus strains on the basis of nucleotide sequences of 4b gene fragment. *Avian Dis* 2004; 48:453–62; <https://doi.org/10.1637/7111>
- [22] Haydar MR, Ara MS, Soma SS, Rahman MM, Rahman MB, Rahman MT. Isolation and molecular detection of Turkey pox virus from Turkey in Bangladesh. *Bangl J Vet Med* 2017; 15(1):87–90; <https://doi.org/10.3329/bjvm.v15i1.34061>
- [23] Kabir ML, Haque ME, Borty SC, Mustafa K, Kamal MS, Khasruzzaman AKM, et al. Isolation and molecular detection of fowl pox and pigeon pox viruses from recent outbreak in Bangladesh. *Indian J Life Sci* 2015; 5:1–7.
- [24] Manarolla G, Pisoni G, Sironi G, Rampi T. Molecular biological characterization of avian poxvirus strains isolated from different avian species. *Vet Microbiol* 2010; 140:1–8; <https://doi.org/10.1016/j.vetmic.2009.07.004>
- [25] Roy B, Joardar SN, Samanta I, Das PK, Halder A, Nandi S. Molecular characterization of fowl pox virus isolates from backyard poultry. *Adv Anim Vet Sci* 2013; 1:54–8.
- [26] Amin MM, Siddiky MNA. Efficacy of experimentally developed Fowl Cholera and Pigeon Pox vaccines. A Final Report of PLDP Research Project. p. 1, 2003.
- [27] Masola SN, Mzula A, Tuntufye HN, Kasanga CJ, Wambura PN. Isolation and molecular biological characterization of fowl pox virus from specimen of cutaneous nodular lesions from chickens in several regions of Tanzania. *Br Microbiol Res J* 2014; 4:759–71; <https://doi.org/10.9734/BMRJ/2014/8420>
- [28] Fahmy HA, Arafa A, Kanawaty ZR, Mahmoud AH. Molecular detection of pox virus in pigeon. 10th Scientific Conference (2nd International) Cairo University, 2009.
- [29] Zhao ZT, Lau GY, Shen RZ, Yuan SS, Zhou ZT, Liu GY, et al. Comparison of the volume of fowl pox virus in chick embryos by different injection routes and collection regions. *Chinese J Vet Med* 1996; 22:14–6.
- [30] Buxton A, Fraser G. *Animal microbiology*. Blackwell Scientific Publications, Oxford, UK; Distributed by Lippincott, Philadelphia, PA, 1977.
- [31] Pandey KD, Mallick BB. Cultivation of avian poxes in developing chick developing chick embryo. *Indian J Anim Health* 1975; 14:99–101.
- [32] Biswas SK, Jana C, Chand K, Rehman W, Mondal B. Detection of fowl pox virus integrated with reticuloendotheliosis virus sequences from an outbreak in backyard chickens in India. *Vet Ital* 2011; 47:147–53.
- [33] Literak I, Smid B, Valicek L. Papillomatosis in chaffinches (*Fringilla coelebs*) in the Czech Republic and Germany. *Vet Med Czeck* 2003; 48(6):169–73.
- [34] CFSPH. Mange and scabies. 2012. Available via [www.Cfsph.iastate.edu/Fast Facts/pdfs/acariasis-F.pdf](http://www.Cfsph.iastate.edu/Fast Facts/pdfs/acariasis-F.pdf) (Accessed 29 July 2013).