

Toxoplasmosis in Germany

Epidemiology, Diagnosis, Risk factors, and Treatment

Uwe Pleyer, Uwe Gross, Dirk Schlüter, Henrik Wilking, Frank Seeber

Department of Ophthalmology, Charité Campus Virchow, University Faculty of Medicine, Berlin, Corporate Member of Freie Universität Berlin, Humboldt-Universität zu Berlin, and Berlin Institute of Health: Prof. Uwe Pleyer

Institute of Medical Microbiology and German Reference Laboratory for Toxoplasma Infection, Faculty of Medicine University of Göttingen: Prof. Uwe Groß

Institute of Medical Microbiology and Hospital Epidemiology, Hannover Medical School (MHH): Prof. Dirk Schlüter

Unit 35: Gastrointestinal Infections, Zoonoses and Tropical Infections, Robert Koch Institute, Berlin: Dr. Hendrik Wilking

Unit 16: Mycotic and parasitic agents and mycobacteria, Robert Koch Institute, Berlin: Prof. Frank Seeber

Summary

Background: With approximately 30% of the world population infected, *Toxoplasma gondii* is one of the most widespread pathogenic parasites in both humans and animals and a major problem for health economics in many countries.

Methods: This review is based on the findings of individual studies, meta-analyses, and Cochrane Reviews retrieved by a selective literature survey of the Medline and Google Scholar databases.

Results: Current data indicate a high rate of *Toxoplasma gondii* infection in Germany, ranging from 20% to 77% depending on age (95% confidence interval for 18- to 29-year-olds [17.0; 23.1]; for 70- to 79-year-olds [72.7; 80.5]). Male sex, caring for a cat, and a body mass index of 30 or more are independent risk factors for seroconversion. Postnatally acquired (food-related) infection is predominant, but maternal-to-fetal transmission still plays an important role. While most infections are asymptomatic, congenital toxoplasmosis and reactivated *Toxoplasma* encephalitis in immunosuppressed persons (transplant recipients and others) are sources of considerable morbidity. *Toxoplasma gondii* infection of the retina is the most common cause of infectious uveitis in Germany. The diagnosis and treatment of this type of parasitic infection are particular to the specific organs involved in the individual patient.

Conclusion: Desirable steps for the near future include development of an effective treatment for the cystic stage and identification of biomarkers to assess the risk of reactivation and predict the disease course.

Cite this as:

Pleyer U, Gross U, Schlüter D, Wilking H, Seeber F: Toxoplasmosis in Germany—epidemiology, diagnosis, risk factors, and treatment. *Dtsch Arztebl Int* 2019; 116: 435–44. DOI: 10.3238/arztebl.2019.0435

T*oxoplasma gondii* is an extremely successful protozoan parasite that infects about one-third of the world's population (1). The World Health Organization (WHO) estimates that, in Europe, 20% of the burden of disease transmitted through food is caused by *T. gondii* infection (2). The life cycle of this single-cell organism is complex. In humans, the main oral source of infection is believed to be eating or handling inadequately cooked or raw meat containing tissue cysts (bradyzoites), or consuming fruit, vegetables, or water contaminated with oocysts (“spores”) (3) (*Figure 1*). Because of the risk of mother-to-child transmission, these zoonotic routes of infection are particularly important in cases where a woman is infected for the first time during pregnancy (4). In addition to congenital toxoplasmosis, reactivated *Toxoplasma* encephalitis in immunosuppressed patients (e.g., those with AIDS or

under heavy immunosuppression following stem cell or organ transplantation) and ocular toxoplasmosis are clinically significant manifestations of this disease (*Figure 1*). If disability-adjusted life years (DALY) per case are taken as a measure of the severity of disease, in Europe, congenital toxoplasmosis, at 2.42 DALYs per case [95% confidence interval (CI): 1.92; 3.05], is on a level with hepatitis B (2.79 [1.46; 4.45]) and invasive pneumococcal infection (2.74 [2.71; 2.77]), and ranks ahead of tetanus infection (2.02 [1.91; 2.15]) (e1). According to the WHO, toxoplasmosis is an important public health issue (4, e2). In 2016, as part of a study of adult health in Germany (DEGS1), the Robert Koch Institute surveyed *T. gondii* seroprevalence among adults in Germany for the first time (5) and found it to be 49.1%.

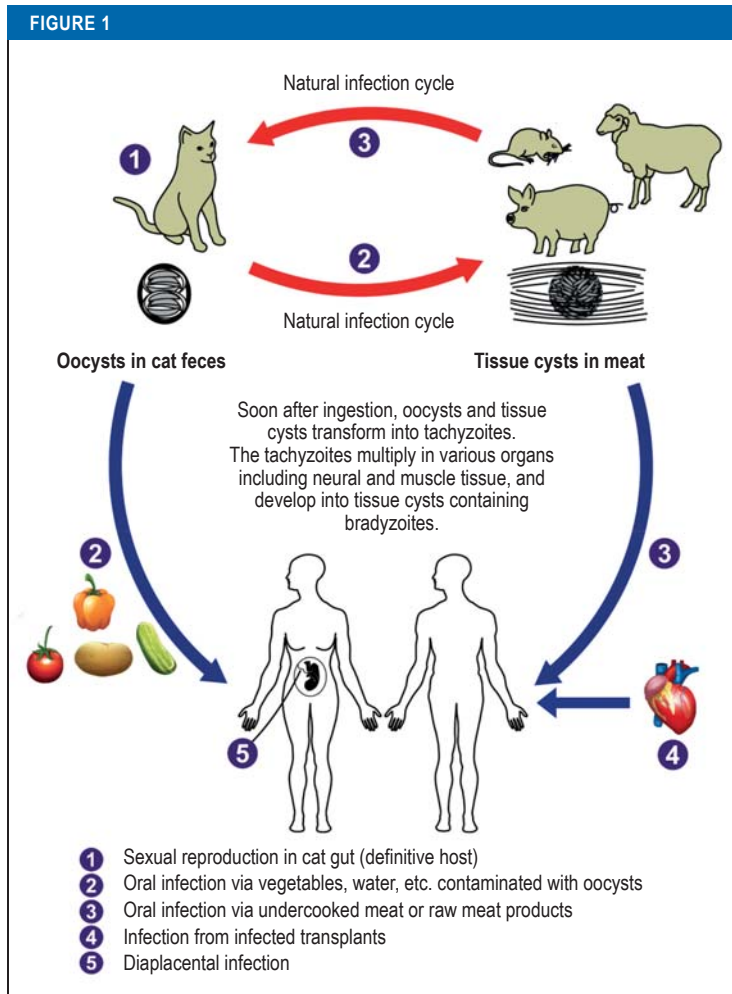
The present article is based on a literature search using the search terms “diagnosis,” “encephalitis,”

Definition

Toxoplasma gondii is a protozoan parasite that infects about one-third of the world's population.

Clinical significance

In addition to congenital toxoplasmosis, reactivated *Toxoplasma* encephalitis in immunosuppressed patients and ocular toxoplasmosis are clinically significant manifestations of this disease.



T. gondii infection cycle (simplified).

The infective pathogen is transmitted in the form of oocysts (spores) excreted in the feces of infected cats (1). Thus, *T. gondii* can be transmitted to domestic animals and rodents as well as to humans via contaminated food (2). Cats acquire the infection via tissue cysts (bradyzoites = chronic, slowly multiplying stage of the parasite) when they eat, for example, infected rodents (3). The same occurs in humans through consumption of undercooked meat from infected animals (3). Transplantation of tissue from infected persons (4) and diaplacental transmission (5) during a first infection in a pregnant woman are additional routes of infection. The acute, rapidly replicating intracellular tachyzoite stage spreads within infected organisms before transforming into bradyzoites (adapted from [e3]).

Infection cycle

T. gondii is transmitted in the form of oocysts (spores) excreted in the feces of infected cats. Thus, *T. gondii* can be transmitted to domestic animals and rodents as well as to humans via contaminated food.

“epidemiology,” “pregnancy,” “seroprevalence,” “therapy,” “toxoplasmosis,” and “uveitis.”

Learning goals

After reading this article, the reader should:

- Know the routes of infection, epidemiology, and risks of this parasitic infection
- Have a good grasp of the clinical features, organ manifestations, and sequelae of the infection
- Understand the rationale of the preventive measures and treatment options for *T. gondii* infection

Epidemiology

In Germany, *T. gondii* infections in humans are probably acquired mainly through the consumption of pork in raw sausage products (*Rohwurst*, *Mettwurst*) (5). To date there have been no reports in Germany of outbreaks caused by contaminated drinking water or surface water (e4, e5). Oocysts have also been shown to be present in air samples, so infection via the airways cannot be ruled out (e6). The influence of eating habits and food hygiene is reflected in current epidemiological data and sero-surveys on infection rates. The latter are an important surrogate in the search for information about the prevalence of infection. Seroconversion rates vary greatly around Europe, ranging from 7% to 10% in Norway and the United Kingdom to 44% and 50% in France and Germany respectively (5, e7). In adults in Germany (18 to 79 years of age), the seroprevalence of IgG antibodies against *T. gondii* is almost 50%, rising in an almost linear fashion (1% per year) from about 20% in young adults (18 to 29 years) to 77% in the 70- to 79-year-old age group (5). Men, cat owners, and the obese (BMI ≥ 30) were more often seropositive. Vegetarian eating habits and high socioeconomic status were found to be preventive factors.

Modeling on the basis of this data suggests that every year about 6390 infections occur during pregnancy, and that an estimated 345 neonates will be clinically symptomatic (5). This is far higher than the number of children with congenital toxoplasmosis reported annually to the Robert Koch Institute (between 6 and 38); the discrepancy may be explained by considerable under-reporting and/or abortions caused by unidentified infection. At the same time, these numbers confirm the importance of this zoonosis for public health (4) (Figure 2).

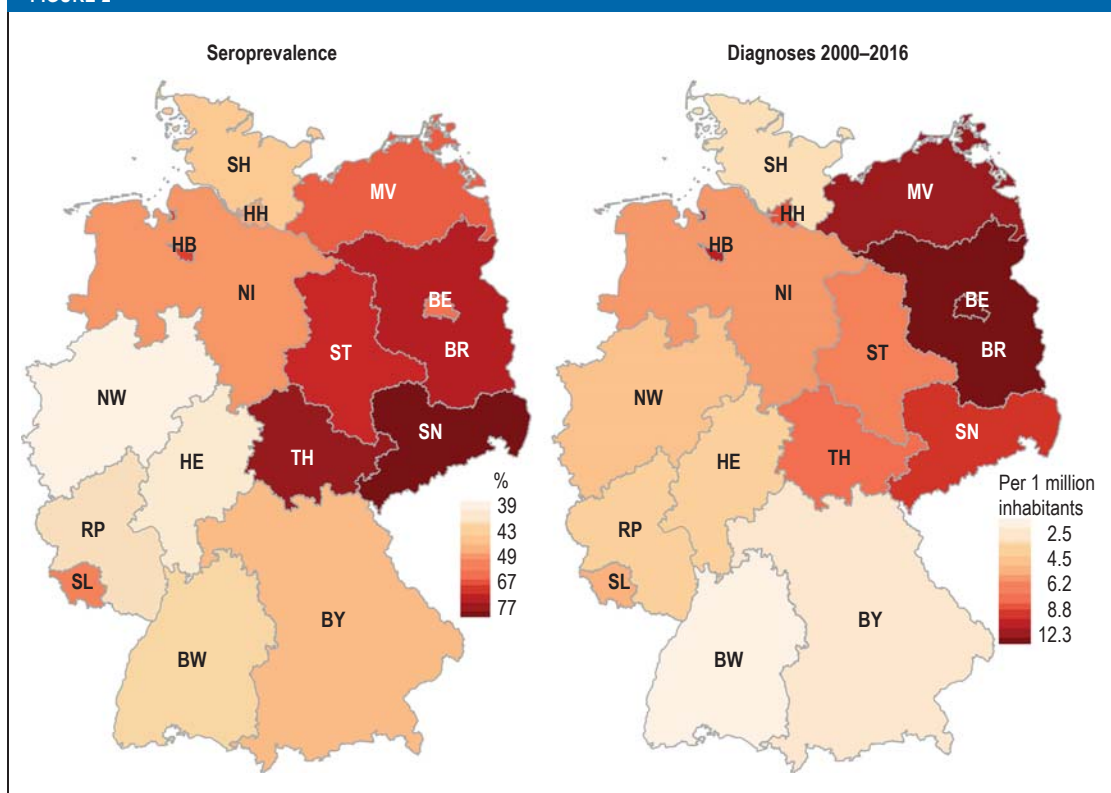
Pathogenesis and pathology

The pathophysiology and clinical course of toxoplasmosis are largely determined by the complex life cycle

Epidemiology

In Germany, *T. gondii* infections in humans are probably acquired mainly through the consumption of pork in raw sausage products. To date there have been no reports in Germany of outbreaks caused by contaminated drinking water or surface water.

FIGURE 2



The seroprevalence of *T. gondii* in the federal states of Germany in 2008 (left) and cumulative data on *T. gondii*-related diagnoses for the period 2000 to 2016 (right). The markedly higher seroprevalence in the eastern part of the country is probably due to the much higher consumption of raw pork mince and raw sausage in those states (5), as has been observed for other infectious diseases transmitted through the consumption of meat (e.g., yersiniosis) (e8, e9). Based on the analysis of hospital data on diagnoses (per 1 million head of population) from 2000 to 2016 (available at www.gbe-bund.de), using the ICD-10 four-digit codes for toxoplasmosis (B58), it can be seen that billing figures are also much higher in the eastern states. It may be concluded from this that the higher seroprevalence in eastern Germany appears to be accompanied by a higher disease burden in these states.

BE, Berlin; BR, Brandenburg; BW, Baden-Württemberg; BY, Bavaria; HB, Bremen; HE, Hesse; HH, Hamburg; MV, Mecklenburg–West Pomerania; NI, Lower Saxony; NW, North Rhine–Westphalia; RP, Rhineland–Palatinate; SH, Schleswig–Holstein; SL, Saarland; SN, Saxony; ST, Saxony–Anhalt; TH, Thuringia

of *T. gondii*, the diversity of its strains, and the immune adaptation of the pathogen (Figure 1) (3). After ingestion of the pathogen, intestinal infection of macrophages and dendritic cells results in hematogenous spread affecting first and foremost neural (brain, eyes) and lymphatic tissue, the heart, and the lungs. In cases of acute infection with lysis of infected host cells, the presence in the blood of extracellular tachyzoites (corresponding to the development stage of a parasite in which acute, rapid replication takes place) can lead to infection of organs and of the placenta as well.

Susceptibility and the severity of clinical manifestations are both subject to the interactions of pathogen- and host-specific factors and are the focus of current research (eTable 1). In Europe and North America, about 70% to 80% of infections are caused by type II genotype, which is relatively avirulent and in ocular toxoplasmosis, for example, tends to result in a chronic recurrent course. In contrast to this, particularly in South America, the genetic diversity of *T. gondii* is greater and infections are also caused by type I, type III, and “atypical” (recombinant) genotypes. The

Seroprevalence

In adults in Germany (18 to 79 years of age), the seroprevalence of IgG antibodies against *T. gondii* is almost 50%, rising in an almost linear fashion (1% per year) from about 20% in young adults (18 to 29 years) to 77% in the 70- to 79-year-old age group.

Pathogenesis and pathology

After ingestion of the pathogen, intestinal infection of macrophages and dendritic cells results in hematogenous spread affecting especially neural (brain, eyes) and lymphatic tissue, the heart, and the lungs.

clinically more serious, often fulminant course with these types is believed to be due to greater rapidity of replication, extracellular migration of the pathogen, and reduced differentiation into bradyzoites (7, e10).

The immune system plays an important part in susceptibility and the clinical course of toxoplasmosis (eFigure). While cellular immune mechanisms control the pathogen in infected cells, *T. gondii*-specific antibodies contribute to the neutralization of extracellular tachyzoites, which in women who have been previously infected helps to protect the placenta from infection. With the aid of these immune mechanisms, the pathogen can be eliminated from practically every cell in the body.

However, under the pressure of the immune response, a few parasites in neurons and myocytes transform into bradyzoites and persist intracellularly in tissue cysts. This persistence of the pathogen requires the maintenance of a protective proinflammatory immune response and the development of immunosuppressive and regulatory T cells. This is particularly important in ocular toxoplasmosis because of the highly sensitive retina, which cannot be regenerated (7, e10). Clinical studies indicate that among other factors the balance between IL-17-producing T cells on the one hand and astrocytes and regulatory T cells on the other is important, because the retina can be damaged not just by the pathogen but also by an IL-17-mediated immune pathology (7). If immunity weakens, the infection can reactivate with renewed tachyzoite replication and tissue necrosis. This manifests clinically both in (immunocompetent) patients with recurrent ocular toxoplasmosis and in AIDS patients with low CD4⁺ T cells in the brain. Despite the high prevalence of infection and pathogen persistence, clinically significant reactivated toxoplasmosis occurs only rarely in persons who are receiving strong immunosuppressants, e.g., TNF blockers in patients with ankylosing spondylitis (8, e11, e12). This may emphasize the importance of local immune mechanisms, but it may also, e.g., in AIDS patients, underline the role being played by the retrovirus itself, with impaired antiparasitic function of HIV-infected microglia.

The close relationship between the immune system and effective parasite control is also shown by studies that have identified genetic polymorphisms as risk factors in genes that are important for immune reactions (eTable 1).

Clinical manifestations of toxoplasmosis

In most cases toxoplasmosis is asymptomatic or accompanied by mild flu-like symptoms. Fewer than

10% of infected persons develop a mononucleosis-type pattern of symptoms including fever, headache, and aching limbs, along with lymphadenitis, especially of the cervical and occipital lymph nodes. These become hard, tender to the touch, and may remain swollen for several weeks. In a few cases, an uncharacteristic maculopapular rash, reactive arthritis, or organ findings such as hepatosplenomegaly, myocarditis, or pneumonia have been observed (1, 6).

Clinically significant manifestations include congenital and ocular toxoplasmosis and, in immunosuppressed patients, organ manifestations that can often be life-threatening (encephalitis, pneumonia) (4, 15–17).

Congenital infection

The WHO estimates the global annual incidence of congenital toxoplasmosis at about 190 100 cases and considers it an underestimated burden of disease with considerable sequelae (4). In Germany, between 6 and 38 cases a year are notified to the Robert Koch Institute (<https://survstat.rki.de>) in accordance with the Infection Protection Act (IfSG, *Infektionsschutzgesetz*). However, since only a minority of infected children show any clinical abnormality at birth, and only these cases are reported, the real number must be considerably higher. In fact, computer modeling suggests that more than 1200 congenitally infected children are born in Germany every year (5). Placental transmission is a risk only when the first infection occurs during a pregnancy; during a second or later infection, antibodies that persist throughout life opsonize the parasites, leading to antibody-mediated phagocytosis. Rare circumstances in which transmission can occur during pregnancy include reactivation of disease in a previously *T. gondii*-seropositive pregnant woman who is immunosuppressed, or reinfection with a different genotype of the pathogen (18).

The risk of diaplacental transmission increases with gestational age, whereas the rate of clinical manifestation goes down (e13). Infection during early pregnancy with severe damage to the fetus presumably often results in abortion. No data are available on this, as embryos aborted in Germany are seldom presented for detailed examination. Especially infection during the second trimester can result in severe damage to the child, in the form of

- Micro- or hydrocephalus
- Intracerebral calcifications
- Retinchoroiditis or microphthalmia

However, this classic triad occurs in only about 5% of the affected fetuses (19).

Role of the immune system

While cellular immune mechanisms control the pathogen in infected cells, *T. gondii*-specific antibodies contribute to the neutralization of extracellular tachyzoites, which in women who have been previously infected helps to protect the placenta from infection.

Clinically significant manifestations

Clinically significant manifestations include congenital and ocular toxoplasmosis and, in immunosuppressed patients, organ manifestations that can often be life-threatening (encephalitis, pneumonia).

Surveillance data from France indicate that after a first infection during pregnancy, about 12% of babies show clinical symptoms at birth (20). Severe CNS manifestations are identified on prenatal ultrasound (e14). Postnatally, infected infants may show poor feeding, seizures, or cerebral palsy as signs of CNS involvement. Although placental transmission in the third trimester is the most common, most fetuses infected at this time appear normal on ultrasound and are asymptomatic as neonates. In about 50% of patients, however, the latent infection leads to ocular toxoplasmosis, often bilateral, during the first 20 years of life, which cannot in all cases be distinguished from postnatally acquired infection (20). Sequelae include large scotomas, significant visual impairment, and blindness.

Ocular toxoplasmosis

Retinal infection with *T. gondii* is an important cause of irreversible visual impairment and is worldwide the most common cause of infectious posterior uveitis. In Germany, about 4% of uveitis manifestations have been traced to *T. gondii* infection (16, e15). Ocular involvement in congenital toxoplasmosis was described as early as 1923 and led to a dogmatic belief in (exclusively) mother-to-child infection. In the 1980s, as other routes of infection for postnatal toxoplasmosis were being identified, this belief was revised. Ocular toxoplasmosis (16, e16) follows a course of necrotizing posterior uveitis so characteristic that it is often regarded as “diagnosis at a glance.” As a retinochoroiditis, the infection affects the inner layers of the retina, with persistence of the pathogen in tissue cysts and a tendency to reactivations (16, e16). In Europe 5-year recurrence rates between 54% and 63% have been reported, while the reported rates in South America are even higher (up to 80%) (21, 22). Numerous risk factors have been reported, suggesting that the host–pathogen interaction is complex and, above all, immune mediated (eTable 1) (14, 21, 22).

The importance of immune status for ocular toxoplasmosis became clear at the beginning of the AIDS epidemic. At least three alleles were associated with susceptibility to ocular manifestation in AIDS patients (e17). An HLA-B35 genotype was significantly more frequently ($p = 0.01$; relative risk [RR] = 3.04) associated with progressive retinitis. Clinically, the presentation is often atypical and fulminant and can present a considerable diagnostic challenge requiring intraocular investigation. Repeatedly, pathogens with type I alleles have been identified (11, e18) (Figure 3).

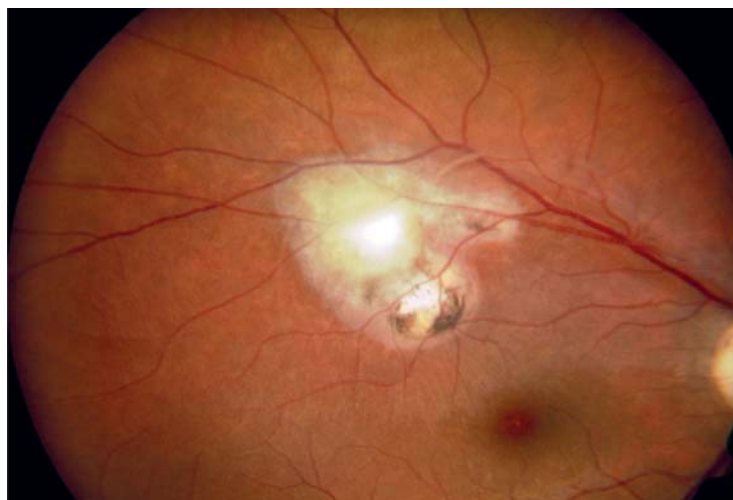


Figure 3: Retinal image of a 27-year-old woman with recurrent ocular toxoplasmosis in the right eye. Retinal necrosis can be seen above the macula, with a fresh recurrence (central “fluffy” focus) surrounded by two older, pigmented lesions. Visual acuity is reduced to 0.63, with a deep, irreversible paracentral visual field defect (Department of Ophthalmology, Charité Campus Virchow, University Faculty of Medicine, Berlin).

Immunosuppression

Infection and reactivation in transplant recipients

The risks associated with transplantation are inadequately documented and probably underestimated (23–26). Toxoplasmosis can occur in recipients both of solid organs and of hematopoietic stem cell transplants and may be due to reactivation of a pre-existing latent infection, to a newly acquired food-borne infection, or to tissue cysts contained in a transplant (24). Recent data show a significantly lower 6-month survival rate for *T. gondii*-seropositive recipients, especially after allogeneic stem cell transplantation (38% vs. 84%; $p < 0.001$) and liver transplantation (50% vs. 75%; $p < 0.001$) (23). The risk of transmission is especially high when a solid organ is transplanted from a recently infected donor into a seronegative recipient (Table). The risk is due to the tachyzoites present in blood, bone marrow, and various organs during parasitemia in the early phase of the infection. How long the risk of transmission persists after the donor has acquired the infection is not known for certain. Parasitemia has been shown as much as 5 weeks after the onset of symptoms. There is also a risk of transmission when transplants, especially of heart, liver, or kidney, from donors with tissue cysts due to chronic *T. gondii* infection are given to seronegative recipients. No exact figures are

Ocular toxoplasmosis

Retinal infection with *T. gondii* is an important cause of irreversible visual impairment and is worldwide the most common cause of infectious posterior uveitis. In Germany, about 4% of uveitis manifestations have been traced to *T. gondii* infection.

Transplant recipients

Toxoplasmosis can occur in recipients both of solid organs and of hematopoietic stem cell transplants and may be due to reactivation of a pre-existing latent infection, to a newly acquired food-borne infection, or to tissue cysts contained in a transplant.

TABLE

Simplified outline of toxoplasmosis treatment (adapted from [6])

Indication	Treatment
First infection during pregnancy	Up to the end of GW 15 Spiramycin (3.0 g = 9 MIU/day) From GW 16: Pyrimethamine (50 mg on day 1; 25 mg/day from day 2) plus sulfadiazine (50 mg/kg BW per day) plus folinic acid (10–15 mg/day)
Congenital toxoplasmosis in a neonate	For 3–12 months (depending on severity): Pyrimethamine (1 mg/kg BW per day) plus sulfadiazine (50–100 mg/kg BW per day) plus folinic acid (2–3 mg/week)
Retinochoroiditis	Pyrimethamine (50 mg on day 1; 25 mg/day from day 2) plus sulfadiazine (50 mg/kg BW per day) plus folinic acid (10–15 mg/day) or clindamycin (1.2–2.4 g/day) or trimethoprim/sulfamethoxazole (cotrimoxazole) (960 mg/day) or atovaquone (3 × 750 mg/day) Prednisone may be added* (1–2 mg/kg BW per day)
Cerebral toxoplasmosis	Pyrimethamine (50 mg on day 1; 25 mg/day from day 2) plus sulfadiazine (50 mg/kg BW per day) plus folinic acid (10–15 mg/day) Possible alternatives: cotrimoxazole (960 mg/day) or atovaquone (3 × 750 mg/day)

Note: The drugs commonly used for the treatment of toxoplasmosis—pyrimethamine, sulfadiazine, clindamycin, and cotrimoxazole—are also licensed for use in children.

* Depending on the extent of any accompanying intraocular inflammation (vitreous involvement)
GW, Gestational week; MIU, million international units; BW, body weight

available on the incidence of *T. gondii* infection when the donor is infected and the recipient seronegative, but rates of 25% to 75% in the absence of appropriate prophylaxis have been reported (e19).

Regarding solid organs, seronegative recipients of organs from seropositive donors (especially heart/lung) are at greatest risk (eTable 2). In such cases, the parasitemia results primarily in the infection of liver and lungs, with the typical signs of hepatitis and/or interstitial pneumonia (26).

The constellation with the highest risk for reactivation is transplantation of stem cells from a seronegative donor to a seropositive recipient (eTable 2). European centers report reactivation rates between 2.9% and 6% (26, 27). Mortality rates in transplant re-

cipients who develop toxoplasmosis range from 63% to 80% (26). The German Society for Hematology and Medical Oncology (DGHO, *Deutsche Gesellschaft für Hämatologie und Medizinische Onkologie*) has issued specific guidelines on prevention in allogeneic hematopoietic stem cell transplantation (27). Where the recipient is seropositive, long-term medical prophylaxis with cotrimoxazole is recommended. Other preventive measures in the transplantation setting include serological screening of both donors and recipients, medicinal prophylaxis, and instruction on hygiene (26). The transplant services of various countries have published recommendations on this topic, although these vary within Europe, e.g., as to the duration of chemoprophylaxis.

Incidence in organ donors

No exact figures are available on the incidence of *T. gondii* infection when the donor is infected and the recipient seronegative, but rates of 25% to 75% in the absence of appropriate prophylaxis have been reported.

Mortality in transplant recipients

Mortality rates in transplant recipients who develop toxoplasmosis range from 63% to 80% .

Infection and reactivation in HIV-infected patients

The importance of cellular immunity for control of the cyst stage and the risk of reactivation is shown by the high incidence of *Toxoplasma* encephalitis in AIDS patients with fewer than 200 CD4⁺ T cells/ μ L. Before the introduction of highly active antiretroviral therapy (HAART), *Toxoplasma* encephalitis and *Toxoplasma* retinitis, present in about 30% of this risk group, were regarded as AIDS-defining opportunistic infections. Today toxoplasmosis remains the most common cause of neurological disease in HIV-positive patients, often resulting in severe pathology or even death (29, e20). The clinical symptoms are generally dependent on the intracerebral and intraocular localization of reactivated foci of infection.

Diagnosis

Because infection with *T. gondii* usually gives rise to nonspecific symptoms or none at all, it requires laboratory diagnosis (30, 31). The main investigations available are serological procedures such as ELISA and immunoblotting. The use of recombinant antigens has made an important contribution to standardization (30, e21). If an acute infection is suspected, the patient's serum should be tested for *T. gondii*-specific IgG and IgM antibodies (6). If organ-specific manifestations are present, local diagnostic tests are also carried out.

Prenatal diagnosis and monitoring

Especially during pregnancy, a low-positive IgM result, perhaps continuing for a long time, accompanied by the simultaneous presence of IgG antibodies—a sign of IgM persistence after a previous infection—presents a diagnostic challenge. It is assumed that the immune response with TH₂ dominance, built up during pregnancy to protect the fetoplacental unit, plays an important role for this constellation. Absence IgM, on the other hand, makes a fresh infection unlikely. If high IgM and low IgG antibody titers are found, this suggests acute toxoplasmosis; the suspicion can be confirmed in a follow-up test 2 to 3 weeks later by a significant rise in IgG antibodies and possibly also IgA antibodies. Measuring the binding avidity of the IgG antibodies can provide a clue as to when the infection occurred: since avidity increases over the course of the immune response, demonstration of highly avid IgG antibodies—even in the presence of a weakly positive IgM finding—generally rules out an acute first infection. Low IgG avidity, on the other hand, is of no diagnostic significance (e22).

Neonates are usually investigated if the mother has shown abnormal serological findings during pregnan-

cy or if there is reason to suspect congenital toxoplasmosis. The presence of specific IgM and/or IgA antibodies in the neonatal serum generally proves prenatal infection. This can be confirmed further by demonstration of IgG antibodies produced by the child (32) as well as by the persistence or increased titers of specific IgG antibodies at a later time point (e23). In addition to serological studies, other diagnostic procedures used in neonates are cranial and abdominal ultrasonography (or magnetic resonance imaging) and ophthalmological examination. In neonates showing any abnormality, the cerebrospinal fluid is also investigated (serology, polymerase chain reaction [PCR], protein level). Determination of cellular immunity parameters can also supply diagnostic evidence of prenatal infection (33). Because a negative PCR result does not rule out a pregnancy-relevant infection (34, e24), and early initiation of therapy is necessary even for suspected primary infection, PCR testing of amniotic fluid is rarely carried out (35).

Diagnosis of ocular toxoplasmosis

Clinical examination often shows typical retinal findings, so that no further diagnostic investigation is needed (Figure 3). In populations with a high prevalence of infection, serological tests are often unhelpful in any case. In doubtful cases, intraocular studies to show the presence of specific intraocular antibodies or PCR to show the pathogen present in the aqueous humor or the vitreous body have proved useful (16).

Diagnosis in immunosuppressed patients

Serological tests are unreliable in immunosuppressed patients, especially those who are HIV-positive. In these patients, active or reactivated infection can most reliably be shown by means of PCR (36). Depending on the clinical situation, body fluids (e.g., CSF, EDTA blood, bronchoalveolar lavage fluid) or biopsy samples (e.g., brain, lung) are suitable. Since a negative PCR result does not entirely rule out active infection, histological methods may also need to be used.

Treatment

Asymptomatic infection and uncomplicated lymphadenitis do not require treatment. Patients who become infected for the first time while pregnant and those with congenital ocular toxoplasmosis need to be treated, as do immunocompromised persons (those with HIV/AIDS or neoplastic disease) and immunodeficient transplant recipients with active or reactivated infection.

Infection in HIV-infected patients

Toxoplasmosis is the most common cause of neurological disease in HIV-positive patients, often resulting in severe pathology or even death.

Abnormalities in neonates

In addition to serological studies, other diagnostic procedures used in neonates are cranial and abdominal ultrasonography (or magnetic resonance imaging) and ophthalmological examination.

Ocular toxoplasmosis represents a relative indication for treatment: therapy should be initiated in particular when the optic nerve or macula is threatened, when the patient has reduced visual acuity due to vitreous inflammation, or when the lesions are large (>1 disk diameter) (16). The main targets of drug treatment are the tachyzoite metabolic pathways of folic acid and protein synthesis; to date the tissue cysts containing bradyzoites remain virtually impregnable. The drugs most often used are spiramycin, pyrimethamine, sulfadiazine, clindamycin, and sometimes atovaquone (Table). To minimize unwanted effects, folic acid (not folic acid) is also given. During pregnancy, folic acid antagonists should be used only from the 16th gestational week onwards; before this, spiramycin can be given in the attempt to prevent placental transmission. The priority is rapid initiation of combination therapy. In cases where treatment was started within 4 weeks after maternal infection, the rate of clinical manifestations in infected children was reduced from 70% to less than 20% (35). A recent prospective randomized study also found indications that combination treatment with pyrimethamine plus sulfadiazine plus folic acid was superior to spiramycin in terms of clinical manifestations in infected newborns (37). This is especially the case when treatment is started early, within 3 weeks after maternal seroconversion during pregnancy. For ocular toxoplasmosis, in addition to the drugs already mentioned, cotrimoxazole is increasingly being used and has proved valuable for long-term prevention of recurrence (<12 months) in at-risk patients (e25, e26).

Prevention

Public health institutions in Germany have stated that greater awareness of preventive measures is needed to reduce the risk of infection (6, e27–e29). The main preventive measures relate to reducing the pathogen burden in the food chain; improving food hygiene; public education, especially of women of child-bearing age; and various precautions in immunosuppressed persons (including in transplantation medicine). Specific goals and interventions include the following:

- From the point of view of disease prevention, the goal should be to keep farm animals destined for human consumption free of *T. gondii* (e27). Veterinary data show that this can be achieved by controlling rodent pests and keeping cats out of animal sheds (38).
- Developing vaccines against the excretion of oocysts by infected cats could reduce exposure to oocysts. Live vaccines (Toxovax) are currently being

used in sheep to reduce the development of tissue cysts (e30).

- Physicians and health authorities (especially in the eastern federal states of Germany, because of the higher rates of infection there) should be made more aware of the toxoplasmosis issue. Educational prevention programs (adequate cooking of meat and thorough washing of fruit and vegetables [e28, e29]) can only reduce the rate of new infections, however, not eliminate existing cases of infection (e31).
- Screening for *T. gondii* antibodies during pregnancy, as carried out for example in France and Austria, is not currently performed in Germany (e32). However, antenatal care under the prevailing German guidelines (*Mutterschafts-Richtlinien*) does include serological tests when there are grounds for suspecting toxoplasmosis (39). In one retrospective study of 685 pregnant women, early diagnosis and treatment of acute infection in the mother led to a sharp reduction in the disease burden of newborns (35). Since recent data do not support the assumption hitherto that screening prevents only a small number of cases (5), these two facts suggest that the value of a screening program needs to be reassessed (40, e33).
- In transplantation medicine, especially allogeneic hematopoietic stem cell transplantation, the preventive measures recommended by the professional societies should be observed: these include screening of donors and recipients, drug prophylaxis, and instructions regarding hygiene (27).

Conflict of interest statement

Professor Gross has received fees for the preparation of scientific conferences and reimbursement of travel and accommodation costs from MSD. The remaining authors declare that no conflict of interest exists.

Manuscript received on 15 November 2018, revised version accepted on 23 May 2019

Dedication

We dedicate this article to the memory of our valued colleague and researcher into toxoplasmosis, Ermanno Candolfi (Strasbourg), who was taken from us much too soon.

Translated from the original German by Kersti Wagstaff.

References

1. Montoya JG, Liesenfeld O: Toxoplasmosis. *Lancet* 2004; 363: 1965–76.
2. Havelaar AH, Kirk MD, Torgerson PR, et al.: World Health Organization global estimates and regional comparisons of the burden of foodborne disease in 2010. *PLoS Med* 2015; 12: e1001923.
3. Schlüter D, Däubener W, Schares G, Groß U, Pleyer U, Lüder C: Animals are key to human toxoplasmosis. *Int J Med Microbiol* 2014; 304: 917–29.

Diagnosis in immunosuppressed patients

Because serological tests are unreliable in immunosuppressed patients, the use of PCR is recommended for direct demonstration of the parasite.

Treatment

Asymptomatic infection and uncomplicated lymphadenitis do not require treatment. Patients who become infected for the first time while pregnant and those with congenital ocular toxoplasmosis need to be treated.

4. Torgerson PR, Mastroiacovo P: The global burden of congenital toxoplasmosis: a systematic review. *Bull World Health Organ* 2013; 91: 501–8.
5. Wilking H, Thamm M, Stark K, Aebischer T, Seeber F: Prevalence, incidence estimations, and risk factors of *Toxoplasma gondii* infection in Germany: a representative, cross-sectional, serological study. *Sci Rep* 2016; 6: 22551.
6. Robert Koch-Institut: RKI-Ratgeber Toxoplasmose. *Epid Bull* 2018; 42: 451–7.
7. Fernandez C, Jaimes J, Ortiz MC, Ramirez JD: Host and *Toxoplasma gondii* genetic and non-genetic factors influencing the development of ocular toxoplasmosis: a systematic review. *Infect Genet Evol* 2016; 44: 199–209.
8. Rodrigues KF, Faria e Arantes TE, Muccioli C, Neto JL, Pinheiro MM: Incidence of *Toxoplasma retinochoroiditis* in patients with ankylosing spondylitis after using TNF-alpha blockers. *Parasitol Int* 2013; 62: 272–5.
9. Rico-Torres CP, Vargas-Villavicencio JA, Correa D: Is *Toxoplasma gondii* type related to clinical outcome in human congenital infection? Systematic and critical review. *Eur J Clin Microbiol Infect Dis* 2016; 35: 1079–88.
10. Herrmann DC, Maksimov P, Hotop A, et al.: Genotyping of samples from German patients with ocular, cerebral and systemic toxoplasmosis reveals a predominance of *Toxoplasma gondii* type II. *Int J Med Microbiol* 2014; 304: 911–6.
11. Vallochi AL, Muccioli C, Martins MC, Silveira C, Belfort R, Rizzo LV: The genotype of *Toxoplasma gondii* strains causing ocular toxoplasmosis in humans in Brazil. *Am J Ophthalmol* 2005; 139: 350–1.
12. Meenken C, Rothova A, de Waal LP, van der Horst AR, Mesman BJ, Kijlstra A: HLA typing in congenital toxoplasmosis. *Br J Ophthalmol* 1995; 79: 494–7.
13. Luma HN, Tchaleu BC, Mapoure YN, et al.: *Toxoplasma encephalitis* in HIV/AIDS patients admitted to the Douala general hospital between 2004 and 2009: a cross sectional study. *BMC Res Notes* 2013; 6: 146.
14. Garweg JG, Scherrer JN, Halberstadt M: Recurrence characteristics in European patients with ocular toxoplasmosis. *Br J Ophthalmol* 2008; 92: 1253–6.
15. El Bissati K, Levigne P, Lykins J, et al.: Global initiative for congenital toxoplasmosis: an observational and international comparative clinical analysis. *Emerg Microbes Infect* 2018; 7: 165.
16. Maenz M, Schlüter D, Liesenfeld O, Schares G, Groß U, Pleyer U: Ocular toxoplasmosis past, present and new aspects of an old disease. *Prog Retin Eye Res* 2014; 39: 77–106.
17. Parlog A, Schlüter D, Dunay IR: *Toxoplasma gondii*-induced neuronal alterations. *Parasite Immunol* 2015; 37: 159–70.
18. Elbez-Rubinstein A, Ajzenberg D, Darde ML, et al.: Congenital toxoplasmosis and reinfection during pregnancy: case report, strain characterization, experimental model of reinfection, and review. *J Infect Dis* 2009; 199: 280–5.
19. Thiebaut R, Leproust S, Chene G, Gilbert R: Effectiveness of prenatal treatment for congenital toxoplasmosis: a meta-analysis of individual patients' data. *Lancet* 2007; 369: 115–22.
20. Villena I, Ancelle T, Delmas C, et al.: Congenital toxoplasmosis in France in 2007: first results from a national surveillance system. *Euro Surveill* 2010; 15.
21. de-la-Torre A, Rios-Cadavid AC, Cardozo-Garcia CM, Gomez-Marin JE: Frequency and factors associated with recurrences of ocular toxoplasmosis in a referral centre in Colombia. *Br J Ophthalmol* 2009; 93: 1001–4.
22. Holland GN, Crespi CM, ten Dam-van Loon N, et al.: Analysis of recurrence patterns associated with toxoplasmic retinochoroiditis. *Am J Ophthalmol* 2008; 145: 1007–13.
23. Robert-Gangneux F, Meroni V, Dupont D, et al.: Toxoplasmosis in transplant recipients, Europe, 2010–2014. *Emerg Infect Dis* 2018; 24: 1497–504.
24. Prestes DP, Mendes C, Batista MV, et al.: A case-series of Toxoplasmosis in hematopoietic stem cell transplantation: still a concern for endemic countries. *Bone Marrow Transplant*. 2018;5:1336–9.
25. Mele A, Paterson PJ, Prentice HG, Leoni P, Kibbler CC: Toxoplasmosis in bone marrow transplantation: a report of two cases and systematic review of the literature. *Bone Marrow Transplant* 2002; 29: 691–8.
26. Isa F, Saito K, Huang YT, et al.: Implementation of molecular surveillance after a cluster of fatal toxoplasmosis at 2 neighboring transplant centers. *Clin Infect Dis* 2016; 63: 565–8.
27. Ullmann AJ, Schmidt-Hieber M, Bertz H, et al.: Infectious diseases in allogeneic haematopoietic stem cell transplantation: prevention and prophylaxis strategy guidelines 2016. *Ann Hematol* 2016; 95: 1435–55.
28. Silva AC, Rodrigues BS, Micheletti AM, et al.: Neuropathology of AIDS: an autopsy review of 284 cases from Brazil comparing the findings pre- and post-HAART (Highly Active Antiretroviral Therapy) and pre- and postmortem correlation. *AIDS Res Treat* 2012; 2012: 186850.
29. Ford N, Meintjes G, Calmy A, et al.: Managing advanced HIV disease in a public health approach. *Clin Infect Dis* 2018; 66: 106–10.
30. Dard C, Fricker-Hidalgo H, Brenier-Pinchart MP, Pelloux H: Relevance of and new developments in serology for toxoplasmosis. *Trends Parasitol* 2016; 32: 492–506.
31. Pomares C, Montoya JG: Laboratory diagnosis of congenital toxoplasmosis. *J Clin Microbiol* 2016; 54: 2448–54.
32. Groß U, Lüder CG, Hendgen V, et al.: Comparative immunoglobulin G antibody profiles between mother and child (CGMC test) for early diagnosis of congenital toxoplasmosis. *J Clin Microbiol* 2000; 38: 3619–22.
33. Chapey E, Wallon M, Debize G, Rabilloud M, Peyron F: Diagnosis of congenital toxoplasmosis by using a whole-blood gamma interferon release assay. *J Clin Microbiol* 2010; 48: 41–5.
34. Prusa AR, Kasper DC, Pollak A, Olischar M, Gleiss A, Hayde M: Amniocentesis for the detection of congenital toxoplasmosis: results from the nationwide Austrian prenatal screening program. *Clin Microbiol Infect* 2015; 21: 191.e1–8.
35. Hotop A, Hlobil H, Groß U: Efficacy of rapid treatment initiation following primary *Toxoplasma gondii* infection during pregnancy. *Clin Infect Dis* 2012; 54: 1545–52.
36. Villard O, Cimon B, L'Ollivier C, et al.: Serological diagnosis of *Toxoplasma gondii* infection: recommendations from the French National Reference Center for Toxoplasmosis. *Diagn Microbiol Infect Dis* 2016; 84: 22–33.
37. Mandelbrot L, Kieffer F, Sitta R, et al.: Prenatal therapy with pyrimethamine + sulfadiazine vs spiramycin to reduce placental transmission of toxoplasmosis: a multicenter, randomized trial. *Am J Obstet Gynecol* 2018; 219: 386.e1–e9.
38. Kijlstra A, Jongert E: Toxoplasma-safe meat: close to reality? *Trends in Parasitology* 2009; 25: 18–22.
39. Richtlinien des Gemeinsamen Bundesausschusses über die ärztliche Betreuung während der Schwangerschaft und nach der Entbindung. *Bundesanzeiger* 2016: 60a. www.g-ba.de/richtlinien/19/
40. Lange AE, Thyrian JR, Wetzka S, et al.: The impact of socioeconomic factors on the efficiency of voluntary toxoplasmosis screening during pregnancy: a population-based study. *BMC Pregnancy Childbirth* 2016; 16: 197.

Corresponding author:
 Prof. Uwe Pleyer
 Augenklinik, Charité Campus Virchow, Universitätsmedizin Berlin
 Corporate Member of Freie Universität Berlin
 Humboldt-Universität zu Berlin und Berlin Institute of Health
 Augustenburger Platz 1, 13353 Berlin, Germany
uwe.pleyer@charite.de

Cite this as:
 Pleyer U, Gross U, Schlüter D, Wilking H, Seeber F:
 Toxoplasmosis in Germany—epidemiology, diagnosis, risk factors, and treatment. *Dtsch Arztebl Int* 2019; 116: 435–44. DOI: 10.3238/arztebl.2019.0435

► **Supplementary material:**
 For eReferences please refer to:
www.aerzteblatt-international.de/ref2519

eFigures, eTables:
www.aerzteblatt-international.de/19m0435

CME credit for this unit can be obtained via cme.aerzteblatt.de until 15 September 2019.
Only one answer is possible per question. Please select the answer that is most appropriate.

Question 1

To which group of pathogens does *Toxoplasma gondii* belong?

- a) Bacteria
- b) Viruses
- c) Prions
- d) Nematodes
- e) Protozoa

Question 2

Which treatment regimen is used in a patient with retinochoroiditis?

- a) Tetracycline + folic acid
- b) Pyrimethamine +sulfadiazine + folinic acid
- c) Vancomycin + fluconazole
- d) Amoxicillin + fluconazole + atovaquone
- e) Spiramycin + atovaquone

Question 3

By what percentage does seroprevalence rise with every year of age in Germany from 18 onwards?

- a) 0.1%
- b) 0.5%
- c) 1%
- d) 2%
- e) 5%

Question 4

How is *T. gondii* probably most frequently transmitted in Germany?

- a) By the eating or handling of undercooked meat
- b) By contaminated blood products
- c) By contaminated drinking water
- d) By mother-to-child transmission
- e) By aerosols

Further information on CME

- Participation in the CME certification program is possible only via the Internet: cme.aerzteblatt.de. This unit can be accessed until **15 September 2019**. Submissions by letter, e-mail or fax cannot be considered.
 - The following CME units can still be accessed for credit:
 - „Pleural Effusion in Adults—Etiology, Diagnosis, and Treatment“ (issue 21/2019) until 18 August 2019;
 - „Hearing Impairment in Old Age—Detection, Treatment, and Associated Risks“ (issue 17/2019) until 21 July 2019;
 - „Otitis Externa—Investigation and Evidence-Based Treatment“ (issue 13/2019) until 23 June 2019.
 - This article has been certified by the North Rhine Academy for Continuing Medical Education. Participants in the CME program can manage their CME points with their 15-digit “uniform CME number” (einheitliche Fortbildungsnummer, EFN), which is found on the CME card (8027XXXXXXXXXX). The EFN must be stated during registration on www.aerzteblatt.de (“Mein DÄ”) or else entered in “Meine Daten,” and the participant must agree to communication of the results.
-

Question 5

Which animals are definitive hosts of *T. gondii* and a possible source of infection for human beings?

- a) Dogs
- b) Foxes
- c) Hares
- d) Cats
- e) Pigeons

Question 6

In which federal states in Germany are most cases of *T. gondii* infection diagnosed?

- a) Schleswig–Holstein + Bavaria
- b) Lower Saxony+ North Rhine–Westphalia
- c) Berlin + Brandenburg
- d) Baden–Württemberg + Hesse
- e) Rhineland–Palatinate + Saarland

Question 7

In which organ does *T. gondii* most frequently persist?

- a) Liver
- b) Pancreas
- c) Spleen
- d) Kidney
- e) Brain

Question 8

Which of the following is a typical malformation found in a child whose mother was infected by *T. gondii* during the second trimester of pregnancy?

- a) Horseshoe kidney
- b) Hypoplasia of the liver
- c) Hydrocephalus
- d) Spina bifida
- e) Macrosomia

Question 9

Which of the following is an indication for treatment of a *T. gondii* infection?

- a) Demonstration of IgG in a patient with acute conjunctivitis
- b) Interstitial pneumonia in an immunocompetent patient
- c) Lymphadenitis in a patient with acute infection
- d) Seronegative patient who has received a liver transplant
- e) Seroconverted pregnant woman with a markedly raised *T. gondii*-specific IgM titer

Question 10

What is the mortality rate in transplant recipients who develop toxoplasmosis?

- a) 3% to 20%
- b) 23% to 40%
- c) 43% to 60%
- d) 63% to 80%
- e) 83% to 100%

► Participation is possible only via the Internet: cme.aerzteblatt.de

Supplementary material to:

Toxoplasmosis in Germany

Epidemiology, Diagnosis, Risk factors, and Treatment

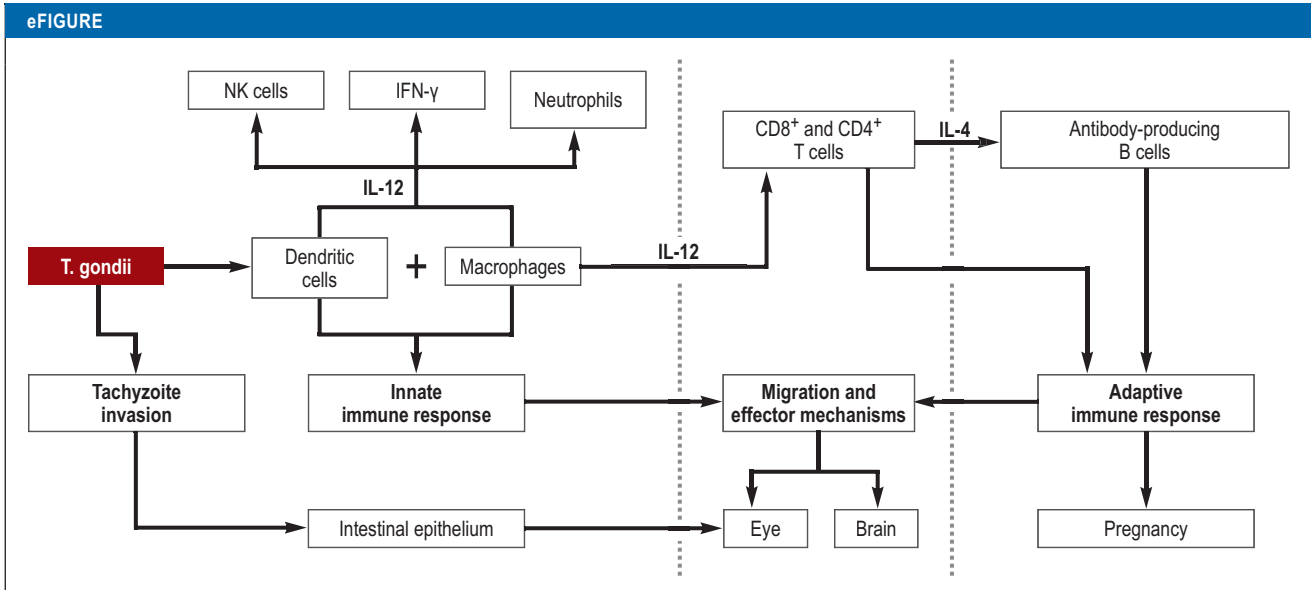
by Uwe Pleyer, Uwe Gross, Dirk Schlüter, Henrik Wilking, and Frank Seeber

Dtsch Arztebl Int 2019; 116: 435–44. DOI: 10.3238/arztebl.2019.0435

eReferences

- e1. Cassini A, Colzani E, Pini A, et al.: Impact of infectious diseases on population health using incidence-based disability-adjusted life years (DALYs): results from the Burden of Communicable Diseases in Europe study, European Union and European Economic Area countries, 2009 to 2013. *Euro Surveill* 2018; 23: 17–00454.
- e2. Suijkerbuijk AWM, van Gils PF, Bonacic Marinovic AA, et al.: The design of a social cost-benefit analysis of preventive interventions for toxoplasmosis: an example of the One Health approach. *Zoonoses Public Health* 2018; 65: 185–94.
- e3. da Silva AJ, Moser M: Toxoplasmosis. Image #3421 i; Centers for Disease Control and Prevention's Public Health Image Library 2002. <https://phil.cdc.gov/Details.aspx?pid=3421> (last accessed on 19 May 2019).
- e4. Bowie WR, King AS, Werker DH, et al.: Outbreak of toxoplasmosis associated with municipal drinking water. The BC Toxoplasma Investigation Team. *Lancet* 1997; 350: 173–7.
- e5. Jones JL, Dubey JP: Waterborne toxoplasmosis – recent developments. *Exp Parasitol* 2010; 124: 10–25.
- e6. Lass A, Szostakowska B, Korzeniewski K, Karanis P: The first detection of *Toxoplasma gondii* DNA in environmental air samples using gelatine filters, real-time PCR and loop-mediated isothermal (LAMP) assays: qualitative and quantitative analysis. *Parasitology* 2017; 144: 1791–801.
- e7. Robert-Gangneux F, Darde ML: Epidemiology of and diagnostic strategies for toxoplasmosis. *Clin Microbiol Rev* 2012; 25: 264–96.
- e8. Bremer v, Bocter N, Rehmet S, Klein G, Breuer T, Ammon A: Consumption, knowledge, and handling of raw meat: a representative cross-sectional survey in Germany, March 2001. *J Food Prot* 2005; 68: 785–9.
- e9. Rosner BM, Stark K, Höhle M, Werber D: Risk factors for sporadic *Yersinia enterocolitica* infections, Germany 2009–2010. *Epidemiol Infect* 2012; 140: 1738–47.
- e10. Xiao J, Yolken RH: Strain hypothesis of *Toxoplasma gondii* infection on the outcome of human diseases. *Acta Physiol (Oxf)* 2015; 213: 828–45.
- e11. Gonzalez-Vicent M, Diaz MA, Sevilla J, Madero L: Cerebral toxoplasmosis following etanercept treatment for idiopathic pneumonia syndrome after autologous peripheral blood progenitor cell transplantation (PBPCT). *Ann Hematol* 2003; 82: 649–53.
- e12. Lassoued S, Zabraniecki L, Marin F, Billey T: Toxoplasmic chorio-retinitis and antitumor necrosis factor treatment in rheumatoid arthritis. *Semin Arthritis Rheum* 2007; 36: 262–3.
- e13. Desmonts G, Couvreur J: [Congenital toxoplasmosis. Prospective study of the outcome of pregnancy in 542 women with toxoplasmosis acquired during pregnancy]. *Ann Pediatr (Paris)* 1984; 31: 805–9.
- e14. Vökt CA, Visca E, Tercanli S: Sonographische Befunde bei maternofetalen Infektionen. *Ther Umschau* 2008; 65: 667–74.
- e15. Jakob E, Reuland MS, Mackensen F, et al.: Uveitis subtypes in a German interdisciplinary uveitis center—analysis of 1916 patients. *J Rheumatol* 2009; 36: 127–36.
- e16. Butler NJ, Furtado JM, Winthrop KL, Smith JR: Ocular toxoplasmosis II: clinical features, pathology and management. *Clin Exp Ophthalmol* 2013; 41: 95–108.
- e17. Demarco AL, Rodrigues Mde L, Figueiredo JF, et al.: Susceptibility to toxoplasmic retinochoroiditis is associated with HLA alleles reported to be implicated with rapid progression to AIDS. *Dis Markers* 2012; 33: 309–12.
- e18. Grigg ME, Ganatra J, Boothroyd JC, Margolis TP: Unusual abundance of atypical strains associated with human ocular toxoplasmosis. *J Infect Dis* 2001; 184: 633–9.
- e19. Derouin F, Pelloux H: Prevention of toxoplasmosis in transplant patients. *Clin Microbiol Infect* 2008; 14: 1089–101.
- e20. Weiss LM, Dubey JP: Toxoplasmosis: a history of clinical observations. *Int J Parasitol* 2009; 39: 895–901.
- e21. Holec-Gasior L: *Toxoplasma gondii* recombinant antigens as tools for serodiagnosis of human toxoplasmosis: current status of studies. *Clin Vaccine Immunol* 2013; 20: 1343–51.
- e22. Reiter-Owona I: Laboratory diagnosis of toxoplasmosis – possibilities and limitations. *J Lab Med* 2005; 29: 439–45.
- e23. Lebech M, Joynson DH, Seitz HM, et al.: Classification system and case definitions of *Toxoplasma gondii* infection in immunocompetent pregnant women and their congenitally infected offspring. European Research Network on Congenital Toxoplasmosis. *Eur J Clin Microbiol Infect Dis* 1996; 15: 799–805.
- e24. Romand S, Wallon M, Franck J, Thulliez P, Peyron F, Dumon H: Prenatal diagnosis using polymerase chain reaction on amniotic fluid for congenital toxoplasmosis. *Obstet Gynecol* 2001; 97: 296–300.
- e25. Connolly MP, Haitsma G, Hernandez AV, Vidal JE: Systematic review and meta-analysis of secondary prophylaxis for prevention of HIV-related toxoplasmic encephalitis relapse using trimethoprim-sulfamethoxazole. *Pathog Glob Health* 2017; 111: 327–31.
- e26. Fernandes Felix JP, Cavalcanti Lira RP, Cosimo AB, Cardeal da Costa RL, Nascimento MA, Leite Arieta CE: Trimethoprim-Sulfamethoxazole versus placebo in reducing the risk of toxoplasmic retinochoroiditis recurrences: a three-year follow-up. *Am J Ophthalmol* 2016; 170: 176–82.
- e27. Opsteegh M, Kortbeek TM, Havelaar AH, van der Giessen JW: Intervention strategies to reduce human *Toxoplasma gondii* disease burden. *Clin Infect Dis* 2015; 60: 101–7.
- e28. Bundeszentrum für Ernährung: Listeriose und Toxoplasmose – Sicher essen in der Schwangerschaft. 2017. www.ble-medienservice.de/0346/listeriose-und-toxoplasmose-sicher-essen-in-der-schwangerschaft (last accessed on 19 May 2019).
- e29. Bundesinstitut für Risikobewertung: Schutz vor Toxoplasmose. Verbrauchertipp 2017. https://mobil.bfr.bund.de/cm/350/verbrauchertipps_schutz_vor_toxoplasmose.pdf (last accessed on 19 May 2019).
- e30. Verma R, Khanna P: Development of *Toxoplasma gondii* vaccine: a global challenge. *Hum Vaccin Immunother* 2013; 9: 291–3.
- e31. Kullenberg de Gaudry D, Grede N, Motschall E, Lins S: Analysis of German nutrition brochures for pregnant women with evidence-based patient information criteria. *Patient Educ Couns* 2015; 98: 207–12.
- e32. Prusa AR, Kasper DC, Sawers L, Walter E, Hayde M, Stillwaggon E: Congenital toxoplasmosis in Austria: prenatal screening for prevention is cost-saving. *PLoS Negl Trop Dis* 2017; 11: e0005648.
- e33. Zylka-Menhorn V: Toxoplasmose-Test Argumente für ein Screening. *Dtsch Arztebl* 2013; 110: 446.
- e34. Jokelainen P, Murat JB, Nielsen HV: Direct genetic characterization of *Toxoplasma gondii* from clinical samples from Denmark: not only genotypes II and III. *Eur J Clin Microbiol Infect Dis* 2018; 37: 579–86.
- e35. Shobab L, Pleyer U, Johnsen J, et al.: *Toxoplasma* serotype is associated with development of ocular toxoplasmosis. *J Infect Dis* 2013; 208: 1520–8.
- e36. Witola WH, Liu SR, Montpetit A, et al.: ALOX12 in human toxoplasmosis. *Infect Immun* 2014; 82: 2670–9.
- e37. Witola WH, Mui E, Hargrave A, et al.: NALP1 influences susceptibility to human congenital toxoplasmosis, proinflammatory cytokine response, and fate of *Toxoplasma gondii*-infected monocytic cells. *Infect Immun* 2011; 79: 756–66.
- e38. Jamieson SE, de Roubaix LA, Cortina-Borja M, et al.: Genetic and epigenetic factors at COL2A1 and ABCA4 influence clinical outcome in congenital toxoplasmosis. *PLoS One* 2008; 3: e2285.
- e39. Takakura A, Tessler HH, Goldstein DA, et al.: Viral retinitis following intraocular or periocular corticosteroid administration: a case series

- and comprehensive review of the literature. *Ocul Immunol Inflamm* 2014; 22: 175–82.
- e40. Sauer A, Pfaff AW, Villard O, et al.: Interleukin 17A as an effective target for anti-inflammatory and antiparasitic treatment of toxoplasmic uveitis. *J Infect Dis* 2012; 206: 1319–29.
- e41. Dutra MS, Bela SR, Peixoto-Rangel AL, et al.: Association of a NOD2 gene polymorphism and T-helper 17 cells with presumed ocular toxoplasmosis. *J Infect Dis* 2013; 207: 152–63.
- e42. Albuquerque MC, Aleixo AL, Benchimol EI, et al.: The IFN-gamma +874T/A gene polymorphism is associated with retinochoroiditis toxoplasmosis susceptibility. *Mem Inst Oswaldo Cruz* 2009; 104: 451–5.
- e43. Peixe RG, Boechat MS, Rangel AL, Rosa RF, Petzl-Erler ML, Bahia-Oliveira LM: Single nucleotide polymorphisms in the interferon gamma gene are associated with distinct types of retinochoroidal scar lesions presumably caused by *Toxoplasma gondii* infection. *Mem Inst Oswaldo Cruz* 2014; 109: 99–107.
- e44. Naranjo-Galvis CA, de-la-Torre A, Mantilla-Muriel LE, et al.: Genetic polymorphisms in cytokine genes in Colombian patients with ocular toxoplasmosis. *Infect Immun* 2018; 86.
- e45. Cordeiro CA, Moreira PR, Andrade MS, et al.: Interleukin-10 gene polymorphism (-1082G/A) is associated with toxoplasmic retinochoroiditis. *Invest Ophthalmol Vis Sci* 2008; 49: 1979–82.
- e46. Cordeiro CA, Moreira PR, Bessa TF, et al.: Interleukin-6 gene polymorphism (-174 G/C) is associated with toxoplasmic retinochoroiditis. *Acta Ophthalmol* 2013; 91: e311–4.
- e47. Cordeiro CA, Moreira PR, Costa GC, et al.: Interleukin-1 gene polymorphisms and toxoplasmic retinochoroiditis. *Mol Vis* 2008; 14: 1845–9.
- e48. Peixoto-Rangel AL, Miller EN, Castellucci L, et al.: Candidate gene analysis of ocular toxoplasmosis in Brazil: evidence for a role for toll-like receptor 9 (TLR9). *Mem Inst Oswaldo Cruz* 2009; 104: 1187–90.
- e49. de Faria Junior GM, Ayo CM, de Oliveira AP, et al.: CCR5 chemokine receptor gene polymorphisms in ocular toxoplasmosis. *Acta Trop* 2018; 178: 276–80.
- e50. Jamieson SE, Peixoto-Rangel AL, Hargrave AC, et al.: Evidence for associations between the purinergic receptor P2X(7) (P2RX7) and toxoplasmosis. *Genes Immun* 2010; 11: 374–83.



Simplified representation of dissemination and immune response in *T. gondii* infection. Once oral infection has occurred, *T. gondii* penetrates the intestinal epithelium and becomes disseminated, in part intracellularly, in dendritic cells and macrophages in the host and infects many organs. In the gut, macrophages and dendritic cells recognize intracellular tachyzoites and/or conserved structural features of the parasite (e.g., glycosylphosphatidylinositol, parasitic DNA and RNA) by means of toll-like receptors (TLR9) and other pattern-associated recognition receptors. The activated macrophages and dendritic cells produce IL-12, which induces interferon- γ production of natural killer (NK) cells and type 1 innate lymphoid cells. Alongside this activation of the innate immune system, parasite-specific CD4⁺ and CD8⁺ T cells develop, which also produce IFN- γ and are activated by dendritic cells and/or macrophages. IFN- γ induces antiparasitic effector mechanisms in infected cells, such as production of GTPases and indoleamine-2,3-dioxygenase. Likewise, the cytotoxic effect of NK and CD8⁺ T cells contributes to the elimination of infected cells. Through the production of IL-4, T cells activate B cells, which contribute to protection by producing *T. gondii*-specific antibodies.

eTABLE 1

Risk factors affecting the course of a *T. gondii* infection*

Infection route and clinical manifestation	<i>T. gondii</i> -specific risk factors	Quantitative measurement	Reference/source
Congenital			
	Genotype I versus genotypes II + III with severe clinical course	86.9 versus 72.9%; OR 2.47, 95% CI [1.1; 5.4])	(9)
Postnatal			
Cerebral toxoplasmosis	Increased incidence of genotype II	Descriptive case series; no concrete data available	(10)
Ocular toxoplasmosis	Increased severity of retinitis with genotypes I, III, or atypical pathogens Atypical genotypes may lead more often than type II to ocular toxoplasmosis and more frequent recurrences	Descriptive case series; no concrete data available OR 10.0, 95% CI [3.4; 40.8]; (p < 0.0001) (p = 0.037)	(7, 11) (e18, e34, e35)
Infection route and clinical manifestation	Host-specific factors	Quantitative measurement	Reference/source
Congenital			
	NALP1 gene polymorphisms are associated with congenital toxoplasmosis	NALP1 rs8081261 (p < 0.00268) NALP1 rs11652907 (p < 0.02)	(e36, e37)
Ocular toxoplasmosis	HLA-B62 increases susceptibility to bilateral eye involvement	OR 2.8 (p = 0.006)	(12)
	Retina-specific ABCA4 transporter increases susceptibility to congenital eye involvement	OR 2.06, 95% CI [1.14; 3.73] (p = 0.017)	(e38)
	Alpha-1 type II collagen COL2A1 increases susceptibility to congenital eye involvement	OR 1.79, 95% CI [1.06; 3.04] (p = 0.031)	(e38)
Cerebral toxoplasmosis (reactivated <i>T. gondii</i> encephalitis)	High risk of reactivation in CD4 ⁺ T cells <100/μL (e.g., after heart or stem cell transplantation)	OR 26.8, 95% CI [1.5; 16.9] (p = 0.001)	(13)
Postnatal			
Ocular toxoplasmosis	Age <21 years and male sex show higher tendency to recurrence	Descriptive case series showing increased recurrence in patients below 21 years of age (p < 0.05)	(14)
	Age >50 years: larger/atypical retinal lesions	Descriptive case series	(e39)
	Intraocular overproduction of proinflammatory cytokines (IL-17)	Descriptive case series	(e40, e41)
	Increased susceptibility to ocular toxoplasmosis in the presence of gene polymorphisms for these cytokines:		
	Interferon-γ (A/T + T/T allele)	OR 2.62, 95% CI [1.1; 6.19] (p = 0.014) OR 3.3, 95% CI [1.604; 6.835] (p = 0.0014) OR 4.2, 95% CI [2.48; 7.12] (p = 0.003)	(e42)
	Interferon-γ (GG rs2069718)	OR 2.55, 95% CI [1.11; 5.55] (p = 0.01) OR 5.27, 95% CI [3.18; 8.74] (p = 0.001) OR 6.62 (95% CI not provided) (p = 0.01) OR 5.46 (95% CI not provided) (p = 0.02)	(e43)
	Interferon-γ (874T/A)		(e44)
	IL-10 (1082A/ AA+AG) IL-10 (1082 G/A) IL-6 (174 G/C) IL-1A (889 C/T)		(e45) (e44) (e46) (e47)
	Toll-like receptor 9	OR 4.23, 95% CI [1.6; 30.8] (p < 0.001)	(e48)
	Chemokine receptor CCR5	OR 2.98 (95% CI not provided) (p = 0.018)	(e49)
Protective effect for ocular toxoplasmosis Purinergic receptor P2X7	OR 0.27, 95% CI [0.09; 0.80] (p < 0.01)	(e50)	

Infection route and clinical manifestation	<i>T. gondii</i> -specific risk factors	Quantitative measurement	Reference/ source
	HLA B35 (in AIDS patients) increased risk of reactivation	OR 3.04 (95% CI not provided) (p = 0.01)	(e17)

The following distinctions are made:

- a) Route of infection (congenital versus postnatal)
- b) Clinical manifestation (cerebral versus ocular)
- c) Pathogen-specific and host-specific factors

Data on frequency distribution and risks are taken from the original publications.

95% CI, 95% confidence interval; OR, odds ratio

eTABLE 2

Risk pattern and prophylactic measures for *T. gondii* infection in transplantation medicine*

	Risk of transmission	Risk of reactivation	Onset of symptoms	Measures/prophylaxis
Organ or tissue transplantation				
Heart or heart–lung	High for mismatch D+ /R-	Low in R+	25–195 days	Cotrimoxazole for prevention
Liver	Low for mismatch D+ /R-	Low in R+	Median 24 days	Cotrimoxazole for prevention
Kidney	Low for mismatch D+ /R-	Low in R+	Median 19 days	Not known
Bowel	Low for mismatch D+ /R-	Not known		Not known
Cornea	No risk			
Stem cell transplantation				
Autologous	No risk	Very low in R+	9–120 days	Not known
Allogeneic	Low	High in R+, independent of donor serology Increased risk in cord blood stem cell transplantation	Median 62 days	Cotrimoxazole for prevention (already used for <i>Pneumocystis</i> prophylaxis) Alternatively, pyrimethamine–sulfadoxine from month 1 to month 6 after stem cell transplantation Continued or initiated anew if GVHD or long-term immunosuppression occurs

*Adapted from (e19)

D, donor; GVHD, graft-versus-host disease; R, recipient; +, *T. gondii* seropositive; –, *T. gondii* seronegative