

## Oncology

## Renal cell carcinoma in ectopic pelvic kidney: A rare case report with relevant surgical anatomy



R.K. Gopala Krishna, Kaushik Sinha, Parvez Ahmad\*, Shiv Kinkar Mishra, Kumar Gauraw

Department of urology, Fortis Hospital, Kolkata, India

## ARTICLE INFO

## Keywords:

Ectopic kidney  
Pelvic kidney  
Surgical anatomy  
Renal cell carcinoma

## ABSTRACT

Renal Ectopia is a rare developmental anomaly, leading to failure of mature kidney to reach its normal location within the renal fossa. Most ectopic kidneys are asymptomatic and gets diagnosed as incidental finding on radiography or at surgery. The incidence of RCC in ectopic kidney are very uncommon, presenting with atypical symptoms causes a diagnostic as well as therapeutic dilemma in front of urologists. We present a case of 65 years old gentleman, having complaints of hematuria having heterogeneously enhancing SOL in left pelvic ectopic kidney.

## Introduction

There is dearth in literature discussing renal malignancy in ectopic pelvic kidney. Up till now only 12 cases has been reported in literature. The final resting state of the kidney determines the location of renal ectopia. Ectopic kidney can be found in one of the following locations: pelvic, iliac, abdominal, thoracic, contralateral or crossed. Pelvic kidney is the most common site of renal ectopia. Ectopic kidneys are more common on the left side of the body and clinically more commonly diagnosed in female.

The ectopic kidney are not more susceptible to disease than normally positioned kidney except for development of hydronephrosis or calculus formation due to its anteriorly placed pelvis. Kidney in ectopic position are dysplastic and often non-functional. Mostly these patients are asymptomatic or may present with vague abdominal complaints or ureteric colic secondary to calculus.

The relationship between ectopic kidney and malignancy is not clear. Malignancy in ectopic kidney is rare event but should be kept in mind for a patient presented with mass in pelvic region without normally located kidney or presented with hematuria. Here, we are going to report a case of left pelvic kidney with renal cell carcinoma.

## Case presentation

65 years old gentleman came in urology OPD on 17th of May with complaints of hematuria followed by unable to pass urine. On clinical examination, suprapubic fullness was noted, for which 3 ways foley's catheter was inserted. After drainage of 800ml red color urine, patient

was re-examined and found to have irregular hard lump in lower abdomen.

Routine laboratory workup done including complete blood count, RFT, LFT and serum electrolytes, found to be normal. Urinalysis shows RBC ++ along with protein. Ultrasonography of the abdomen and pelvis suggestive of ectopic pelvic left kidney and isoechoic area/SOL in the midpolar region. To confirm the finding of USG, Patient was send for CECT KUB, which suggest RT. Kidney normal in position and outline, but the LT. Kidney is unascended and located in lower abdomen in midline and malrotated with heterogeneously enhancing SOL. The main renal vein could not be identified but multiple collateral vein seen. IVC is clear. The left kidney was supplied by 2 arteries, one from distal most aspect of aorta and one from internal iliac artery. Hydronephrosis is seen with dense content ?clots in terminal ureter (Fig. 1). HRCT Thorax was found to be normal, without any metastasis.

After multidisciplinary team discussion, weighing the risk and benefit and the patients informed consent, the patient underwent Cystourethroscopy, which shows clots in bladder and left radical nephrectomy done via transperitoneal approach on 23rd of May.

The left kidney was found just below aortic bifurcation and in front of sacral promontory, densely adhered posteriorly and with pelvic great vessels. The kidney was dissected carefully and dissection was done in the midst of confirming palpable lower extremity pulses before and after this stage of operation. Kidney was devoid of Gerota's fascia and adrenal gland. Kidney was supplied with 2 renal arteries, one from distal abdominal aorta and another from left internal iliac artery, which was dissected and ligated. Multiple veins and their tributaries and ureter ligated and cut (Fig. 2).

\* Corresponding author.

E-mail address: [par05915@gmail.com](mailto:par05915@gmail.com) (P. Ahmad).<https://doi.org/10.1016/j.eucr.2019.100963>

Received 18 June 2019; Received in revised form 1 July 2019; Accepted 9 July 2019

Available online 11 July 2019

2214-4420/© 2019 Published by Elsevier Inc. This is an open access article under the CC BY-NC-ND license

<http://creativecommons.org/licenses/by-nc-nd/4.0/>.

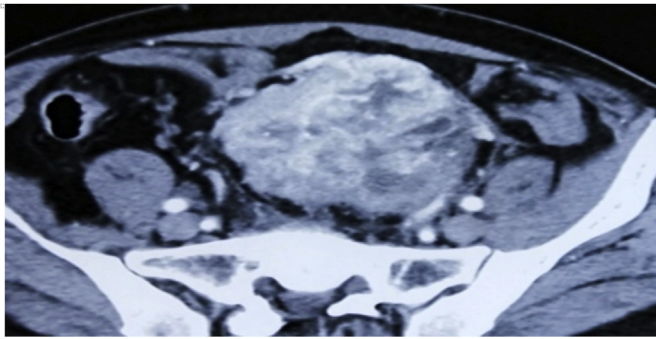


Fig. 1. CECT KUB shows malrotated left pelvic kidney with heterogeneously enhancing lesion of size approx 7.5 cm × 6.5 cm.

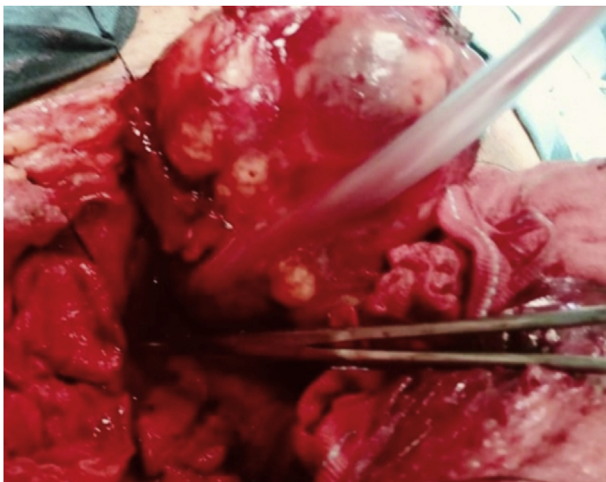


Fig. 2. Intra-operative pic of left pelvic kidney with tumour.

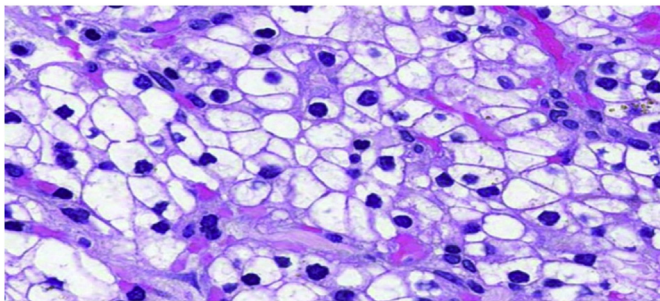


Fig. 3. Histopathology shows Renal cell carcinoma of left pelvic ectopic kidney.

Patient was discharged after 4 days and postoperative period was uneventful. HPE report s/o moderately differentiated clear cell carcinoma, clear cell comprises about 70% of tumor cells. Fuhrman nuclear was found to be grade 2 and Stage G2 T3a Nx Mx (Fig. 3).

## Discussion

Although RCC accounts for 80% of renal malignancy, RCC in ectopic kidney is very uncommon finding in literature. In Campbell- Walsh Urology, only 3 cases has been reported regarding malignancy in ectopic kidney.<sup>1</sup>

The incidence of renal ectopia in autopsy is 1 in 500 to 1 in 1200. During embryological life Ureteric bud maldevelopment, defective metanephric tissue and improper migration and rotation of kidney leads to renal ectopia.

The ectopic kidney is usually smaller and may not conform to usual reniform shape. The renal pelvis is usually anterior to parenchyma. The length of ureter usually conforms to the position of the kidney. It rarely redundant in contrast to Ptotic kidney, in which ureter achieve its full length before kidney drops. Rarely is the adrenal gland absent or abnormally positioned. Ectopic kidney is devoid of surrounding gerota's fascia.<sup>2</sup>

The vascular network of ectopic kidney is anomalous and its vascular supply depends on ultimate position of kidney. There may be one or two main renal arteries arising from distal aorta or aortic bifurcation with one or more aberrant arteries arising from common, external or internal iliac artery. In order to accommodate the changes in blood supply to the ectopic kidney, both abdominal aorta and IVC showed certain variations.<sup>3</sup>

Usually the contralateral kidney is normal but it may be associated with contralateral agenesis. Bilateral ectopic kidney occurs infrequently approx 10%. It may be associated with genital anomalies specially among female as well as with malposition of colon, skeletal and GI anomalies.<sup>4</sup>

The rarity of such cases in daily clinical practice made it a challenge for the urologists. This report describes a case of successful surgical management of a pelvic kidney with cancer. Apart from patient history and clinical examination, Imaging should be carefully analyzed to determine the orientation of the tumour, kidney, renal vessels and collecting system and their association with the underlying major vascular structures enabling the surgeon to avoid significant blood loss during dissection of the effected tissue. Follow up is required to detect any metachronous renal tumours, local recurrence and distant metastasis.

## Appendix A. Supplementary data

Supplementary data to this article can be found online at <https://doi.org/10.1016/j.eucr.2019.100963>.

## References

1. Fischer MA, Carlsson AM, Drachenberg DE, Gupta R, Norman RW. Renal cell carcinoma in a pelvic kidney. *BJU Int.* 1999;83:514. <https://doi.org/10.1089/end.2007.0380> ([PubMed] [CrossRef] [Google Scholar]).
2. Karaman N, Doğan L, Ozaslan C, Atalay C, Irkkan Ç, Bozkurt A. Renal cell carcinoma in an ectopic kidney: case report. *Acta Oncologica Turcica.* 2009;42:74–76 ([Google Scholar]).
3. Dash I, Lyburn ID, Kinder R. Renal cell carcinoma in an ectopic pelvic kidney in a patient presenting with acute urinary retention. *JSCR.* 2010;10:2 ([PMC free article] [PubMed] [Google Scholar]).
4. Mahmoudnejad N, Danesh A, Abdi H. Renal cell carcinoma in presacral pelvic kidney. *J Pak Med Assoc.* 2009;59:482–483 [PubMed] [Google Scholar]).