

Daratumumab for treatment of blastic plasmacytoid dendritic cell neoplasm. A single-case report

Blastic plasmacytoid dendritic cell neoplasm (BPDCN) is a rare malignancy derived from a hematopoietic stem cell. The normal counterpart is a precursor plasmacytoid dendritic cell. In the 2016 World Health Organization classification it is classified as a distinct entity among myeloid neoplasms.¹ It represents 0.44% of hematologic malignancies. Many patients have involvement of the skin, blood, bone marrow and lymph nodes at diagnosis. The median age at diagnosis is 61-67 years and the prognosis is poor with a median overall survival (OS) of 14-19 months for patients who respond to treatment but do not undergo hematopoietic stem cell transplantation (SCT).^{1,2,3} For patients who undergo SCT the OS is 22.7 months.²

The diagnosis of BPDCN relies on the morphology of the neoplastic cells and expression of CD4, CD56, CD123, CD303 and TCL1.⁴ CD38 is not a part of the standard panel, but Deotare *et al.* demonstrated that five out of nine cases of BPDCN in their study expressed CD38.⁵

There is no clear consensus about the optimal treatment of BPDNC, but it seems that eligible patients should be treated with induction chemotherapy as for acute lymphoid leukemia and those achieving a complete response should be consolidated with allogeneic SCT (allo-SCT) in the first remission.^{6,7} Most adults diagnosed with BPDCN are elderly and not eligible for intensive

therapy and there is an unmet need for novel, effective agents. *In vitro* and *in vivo* experiments revealed promising effects of bortezomib.⁸ Lenalidomide has been tested in a xenograft mouse model with encouraging results and showed clinical activity in combination with celecoxib and azacytidine.⁹ Venetoclax is another novel agent with activity in BPDCN.¹⁰

The proportion of patients who obtain complete remission (CR) after a first line of treatment is generally high, but most of the patients relapse afterwards.¹¹ The literature regarding the treatment of relapsed BPDCN is sparse and in general the prognosis is very poor.^{7,12}

Daratumumab is a human immunoglobulin G1 (IgG1) monoclonal antibody that targets CD38, induces tumor cell death by interaction with complement, natural killer cells or phagocytes and may activate cytotoxic T-lymphocytes and thereby contribute to disease control.^{13,14} Furthermore daratumumab has been shown to have important immunomodulatory activities in myeloma that may also play a role in BPDCN.¹⁴ Daratumumab is approved for the treatment of multiple myeloma by the US Food and Drug administration and European Medicines Agency.

We retrospectively evaluated data from a patient treated with daratumumab for BPCDN.

A 70-year-old male was presented with a cyanotic, elevated, cutaneous element (Figure 1A). A histopathological analysis of the lesion demonstrated a dense dermal infiltrate of mostly large cells with slightly irregular nuclei (Figure 1B). The epidermis was spared. By immunohisto-

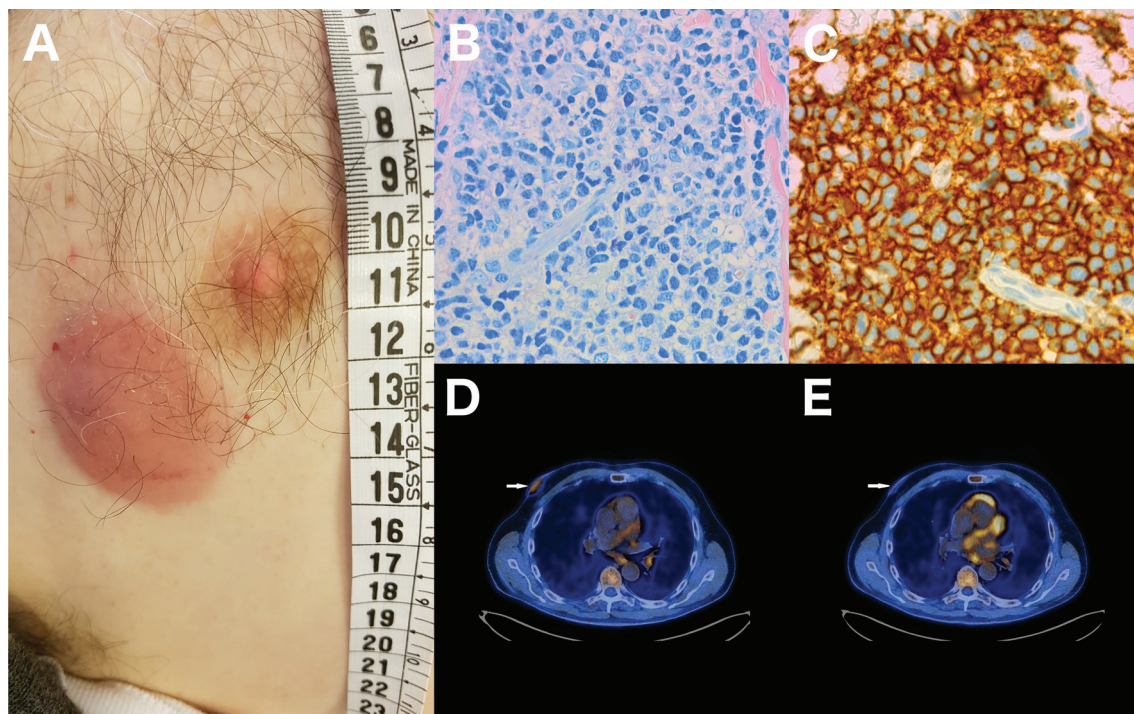


Figure 1. Clinical morphology, histochemistry, immunohistochemistry and PET-CT of the skin lesion. (A) Clinical photo. (B) Tissue section with medium-sized neoplastic cells with scant cytoplasm. (C) The neoplastic cells show immunoreactivity for CD56. (D) Fused ¹⁸F-fluor-deoxy-glucose positron emission tomography/computed tomography (FDG PET/CT) images of the focal skin lesion before the initial treatment with single-agent daratumumab. The focal skin lesion (white arrow) had moderately increased FDG before treatment with a maximum standard uptake value (SUVmax) of 3.2. (E) After the initial treatment the FDG uptake had normalised with a SUVmax of 1.5 and the lesion had reduced in thickness. The patient also had a FDG positive lymph node of the neck (not displayed here) which also reduced in SUVmax from 18.9 to 14.5 and in size from 2.2 x 1.4 cm to 1.7 x 1.0 cm.

Table 1. Immunohistochemical and flowcytometric markers.

	Positive markers	Negative markers
Skin biopsy	CD56, CD4, CD43, HLA-DR, TCL1, Bcl-2, CD33, CD123, CD68, CD11c	CD20, CD3, CD5, PAX5, CD34, CD117, CD14, CD7, TDT, MPO, lysozyme, CD13, CD1a, CD38.
Bone marrow biopsy at diagnosis	CD123, CD303, CD4, CD56, cytTCL1, CD38, HLA-DR, CD25	CD8, CD5, CD3, CD117, CD34, CD13, CD11b, CD7, TDT, CD203, CD15, CD71, NG2

chemistry the cells were positive for CD4, CD56, CD123 and TCL1 but CD38 could not be detected (Table 1 and Figure 1C). Bone marrow biopsy, blood samples, computed tomography (CT) and positron emission tomography-CT (PET-CT) revealed involvement of bone marrow, lymph nodes, spleen and skin (Figure 1D). Flow cytometry of the bone marrow aspirate revealed 4 % neoplastic plasmacytoid dendritic cells positive for CD4, CD56, CD123, CD303, TCL1 and CD38 (Table 1). Based on these findings, the diagnosis of BPDCN was made. Next generation sequencing of DNA from the skin biopsy and enriched CD56⁺ cells of the bone marrow revealed a *TET2* mutation (c.2674C>T/ pGln892Ter) in 91 % and 62 % of the cells respectively. Mutations in the *TET2* gene are common in BPDCN.¹⁵ The *TET2* mutation was only examined at the time of diagnosis.

By immunohistochemistry of the skin biopsy CD38 was not demonstrated on the neoplastic cells presumably due to denaturation of the epitope by the fixation procedure so it may be considered a false negative finding. When the neoplastic cells were examined by flow cytometry from a bone marrow aspirate that had not been exposed to fixation, CD38 was demonstrated but at a low level. Flow cytometry is generally considered to be a more sensitive technique for the demonstration of cell surface expression of molecules compared to immunohistochemistry therefore a lack of sensitivity could be another explanation for the negative finding by immunohistochemistry and the positive finding by flow cytometry.

Because of his age, the patient was ineligible for intensive therapy and allo-SCT, and due to the indolent nature of the patient's disease at the time of diagnosis an initial cycle (four once weekly infusions) of the single agent daratumumab (16 mg/kg) was given to assess the activity of daratumumab in BPDCN. After this first cycle, the bone marrow biopsy and PET-CT was repeated. The proportion of neoplastic plasmacytoid dendritic cells in the bone marrow had decreased from 4% to 0.1%. The PET-CT showed metabolic attenuation and a reduced size of the PET-positive lesions of both lymph nodes and the cutaneous lesion (Figure 1E) and concordant regression of the skin lesion by clinical assessment. After the first four doses of daratumumab monotherapy the treatment was intensified as pre-planned in order to increase the likelihood of a prolonged response. The response to monotherapy with daratumumab in this patient suggests that daratumumab should be considered as an addition to chemotherapy of BPDCN in the future.

Katrine F. Iversen,¹ Paw C. Holdgaard,² Birgitte Preiss,³ Charlotte G. Nyvold⁴ and Torben Plesner¹

¹Department of Hematology, Vejle Hospital and University of Southern Denmark, Vejle; ²Department of Nuclear Medicine, Vejle Hospital, Vejle; ³Department of Pathology, Odense University Hospital and ⁴Haematology-Pathology Research Laboratory,

Department of Hematology, Odense University Hospital, Odense, Denmark

Acknowledgments: we thank the patient for permission to present his case. We thank Oriane Cédile for performing the CD56 enrichment prior to sequencing and Thomas Kielsgaard Kristensen for the NGS sequencing.

Correspondence: KATRINE F. IVERSEN.
katrine.fladeland.iversen@rsyd.dk
doi:10.3324/haematol.2018.214635

Information on authorship, contributions, and financial & other disclosures was provided by the authors and is available with the online version of this article at www.haematologica.org.

References

1. Swerdlow SH, Campo E, Harris NL, et al. WHO classification of tumors of hematopoietic and lymphoid tissues, Revised 4th edn, volume 2. 2016. IARC Press, Lyon.
2. Pagano L, Valentini CG, Pulsoni A, et al. Blastic plasmacytoid dendritic cell neoplasm with leukemic presentation: An Italian multicenter study. *Haematologica*. 2013;98(2):239-246.
3. Alsidawi S, Westin GFM, Al-Kali A, Go RS. Blastic plasmacytoid dendritic cell neoplasm. A population-based analysis from the SEER and NCDB databases [e-letter]. *Blood*. 2016;128(22):4789.
4. Marafioti T, Paterson JC, Ballabio E, et al. Novel markers of normal and neoplastic human plasmacytoid dendritic cells. *Blood*. 2008;111(7):3778-3792.
5. Deotare U, Yee KWL, Le LW, et al. Blastic plasmacytoid dendritic cell neoplasm with a leukemic presentation: 10-Color flow cytometry diagnosis and HyperCVAD therapy. *Am J Hematol*. 2016;91(3):283-286.
6. Kim MJM, Nasr A, Kabir B, et al. Pediatric blastic plasmacytoid dendritic cell neoplasm: A systematic literature review. *J Pediatr Hematol Oncol*. 2017;39(7):528-537.
7. Il, DK, Sokol L. The advances in therapy of blastic plasmacytoid dendritic cell neoplasm. *Expert Opin Investig Drugs*. 2018;27(9):733-739.
8. Philippe L, Ceroi A, Bôle-Richard E, et al. Bortezomib as a new therapeutic approach for blastic plasmacytoid dendritic cell neoplasm. *Haematologica*. 2017;102(11):1861-1868.
9. Garcia-Recio M, Martinez-Serra J, Bento L, et al. Lenalidomide, celecoxib and azacitidine therapy for blastic plasmacytoid dendritic cell neoplasm: a case report. *Onco Targets Ther*. 2016;9:5507-5511.
10. Montero J, Stephansky J, Cai T, et al. Blastic plasmacytoid dendritic cell neoplasm is dependent on BCL-2 and sensitive to venetoclax. *Cancer Discov*. 2017;7(2):156-164.
11. Pagano L, Valentini CG, Grammatico S, Pulsoni A. Blastic plasmacytoid dendritic cell neoplasm: diagnostic criteria and therapeutic approaches. *Br J Haematol*. 2016;174(2):188-202.
12. Wang S, Wang X, Liu M, Bai O. Blastic plasmacytoid dendritic cell neoplasm: update on therapy especially novel agents. *Ann Hematol*. 2018;97(4):563-572.
13. De Weers M, Tai YT, van der Veer MS, et al. Daratumumab, a novel therapeutic human CD38 monoclonal antibody, induces killing of multiple myeloma and other hematological tumors. *J Immunol*. 2011;186(3):1840-1848.
14. Krejcik J, Casneuf T, Nijhof I, et al. Daratumumab depletes CD38+ immune regulatory cells, promotes T-cell expansion, and skews T-cell repertoire in multiple myeloma. *Blood*. 2016;128(3):384-394.
15. Menezes J, Acquadro F, Wiseman MM, et al. Exome sequencing reveals novel and recurrent mutations with clinical impact in blastic plasmacytoid dendritic cell neoplasm. *Leukemia*. 2014;28(4):823-829.