



OPEN ACCESS

Case report

Tube-ovarian abscess caused by *Rothia aeria*

Yusuke Taira,[✉] Yoichi Aoki

Obstetrics and Gynecology,
University of the Ryukyus,
Nishihara, Japan

Correspondence to

Dr Yusuke Taira,
h115474@med.u-ryukyu.ac.jp

Accepted 19 July 2019

SUMMARY

Rothia aeria is a gram-positive amorphous bacillus and was discovered in the Russian space station 'Mir' in 1997. It shows phylogenetic similarity to *Actinomyces israelii*, and as determined using 16s ribosomal RNA gene analysis *R. aeria* is classified as a bacteria of the genus *Actinomyces*. It was found to colonise in the human oral cavity, and there are some infectious reports but none specifies gynaecological infection. A 57-year-old woman, who had been continuously using intrauterine contraceptive device, presented with fever and lower abdominal pain. She was suspected tube-ovarian abscess caused by *A. israelii*, but the uterine cavity culture revealed *R. aeria* infection. Considering surgical treatment, conservative treatment by intravenous benzylpenicillin and subsequently oral ampicillin for 6 months improved the abscess, and she has no recurrence for over 1 year.

BACKGROUND

Rothia aeria, of the genus *Actinomyces*, was discovered in the Russian space station 'Mir' and was found to colonise in the oral cavity.¹ There are some infectious reports caused by *R. aeria*, but none specifies gynaecological infection. To the best of our knowledge, this is the first report of a gynaecological infection caused by *R. aeria*.²⁻⁴

CASE PRESENTATION

A 57-year-old woman presented with fever and lower abdominal pain. She had been continuously using intrauterine contraceptive device (IUCD) for 20 years without undergoing medical examination. She has been experiencing abnormal vaginal discharge for the past 1 year. Before admitting in our hospital, she underwent medical examination in an internal medicine clinic and was administered levofloxacin to treat acute cystitis but her symptoms did not improve. Subsequently, in another gynaecological clinic, she underwent transvaginal ultrasound examination that revealed a right adnexa tumour. She was then admitted in our hospital for careful examination and treatment with a suspicion of tube-ovarian abscess, after the removal of her IUCD.

INVESTIGATIONS

Initial examination at our hospital revealed the following results: white blood cell count, $15.7 \times 10^9/L$; haemoglobin level, 11.2 g/L; platelet count, $36.3 \times 10^9/L$; procalcitonin level, 0.051 ng/mL and C reactive protein (CRP) level, 31.91 mg/dL.

Subsequent gynaecological examination demonstrated right lower abdominal tenderness with no rebound or cervical tenderness.

Her vital signs were as follows: body temperature, 38.1°C; blood pressure 112/58 mm Hg and heart rate, 86 beats/min.

Vaginal speculum examination revealed a normal discharge and normal vaginal portion of the cervix.

Transvaginal ultrasound examination identified multiple cystic masses in the right adnexa (38×45 mm) and no ascites in the Douglas fossa, with normal uterus and left adnexa.

MRI revealed multiple cystic tumours with contrast effect and thickening of the right adnexa wall (figure 1).

TREATMENT

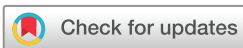First, we administered cefmetazole (2 g/day) and clindamycin (1800 mg/day) intravenously according to the treatment protocol or severe pelvic peritonitis. On day 7 of hospitalisation, the antibiotics were switched to ampicillin/sulbactam (12 g/day), which are used for treating *Actinomyces* and anaerobic infections, as an *Actinomyces* infection was suspected based on the uterine cavity culture results. On day 12 of hospitalisation, *R. aeria* was detected in the same culture (figure 2), and thus the antibiotics were switched to benzylpenicillin (24 000 U/day) according to previous reports on *R. aeria* infection treatment.²⁻⁴ The benzylpenicillin treatment improved her fever and inflammation; therefore, this conservative treatment was further continued. After 6 weeks of intravenous benzylpenicillin administration, the patient was discharged with a prescription for oral ampicillin (1500 mg/day). After 6 months of treatment with oral ampicillin, her abdominal tenderness disappeared (figure 3).

OUTCOME AND FOLLOW-UP

After 6 months of ampicillin therapy pelvic MRI and transvaginal ultrasound revealed a complete response, and there was no recurrence for over 1 year.

DISCUSSION

R. aeria was isolated from the air of the Russian space station 'Mir'; it is a gram-positive amorphous bacillus that was isolated in 2004. Unlike *Actinomyces israelii*, a gram-positive amorphous bacillus, *R. aeria* grows aerobically. However, as it shows phylogenetic similarity to *A. israelii*, as determined using 16s ribosomal RNA gene analysis and as it is also a gram-positive amorphous bacillus, *R. aeria* is classified as a bacteria of the genus *Actinomyces*.



© BMJ Publishing Group Limited 2019. Re-use permitted under CC BY-NC. No commercial re-use. See rights and permissions. Published by BMJ.

To cite: Taira Y, Aoki Y. *BMJ Case Rep* 2019;**12**:e229017. doi:10.1136/bcr-2018-229017

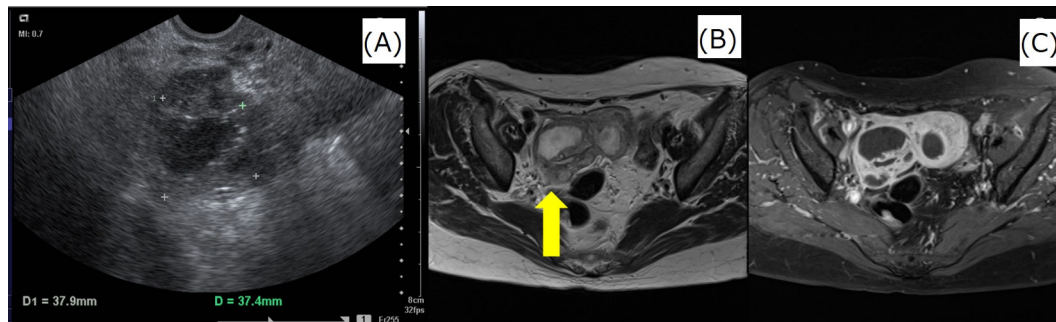


Figure 1 Images obtained at the first examination. Transvaginal ultrasound examination identified multiple cystic masses in the right adnexa. MRI revealed multiple cystic tumours with contrast effect and thickening of the right adnexal wall. (A) Transvaginal ultrasound, (B) MRI T2-weighted image and (C) MRI fat suppression gadolinium contrast T1-weighted image.

Gram-positive amorphous bacilli are classified into six genera: *Corynebacterium*, *Propionibacterium*, *Eubacterium*, *Actinomyces*, *Bifidobacterium* and *Rothia*. Furthermore, *Rothia* is classified into *R. aeria* (Li *et al*, 2004¹), *Rothia amarae* (Fan *et al*, 2002⁵), *Rothia dentocariosa* (Onishi, 1949⁶; Georg and Brown, 1967⁷), *Rothia endophytica* (Xiong *et al*, 2013⁸), *Rothia mucilaginoso* (Collins *et al*, 2000), *Rothia nasimurium* (Collins *et al*, 2000⁹) and *Rothia terrae* (Chou *et al*, 2008¹⁰).

R. aeria is considered to reside in the oral cavity and pharynx, similar to other *Actinomyces* species. Previously, *Rothia* had been reported to cause infective endocarditis,² neonatal bacteremias³ and respiratory infections⁴ in compromised hosts as opportunistic infections. Additionally, airway infection and haematogenous dissemination by intrinsic infection were reported to be the infection routes.^{3,4}

However, there are no reports on gynaecological infections caused by *R. aeria*. In this case *R. aeria* was not detected in the oral cavity, and the patient had no history of steroid administration or immunodeficiency from HIV infection.

Generally, *Actinomyces* infection in the gynaecological organs manifests as chronic pyogenic granuloma caused by *Actinomyces israelii*. Intrauterine devices are a known risk factor for such infections¹¹.

However, the long-term use of intrauterine devices is only the common risk factor for *Actinomyces* infection in gynaecological organs. The transanal and transperineal infectious routes are believed to be responsible with regard to such infections.

The causative bacterium in this case was identified using mass spectrophotometry (VITEK MS, Sysmex bioMérieux), and the bacterial DNA sequence was confirmed using ABI PRISM 310 Genetic Analyzer. *Actinomyces* infection is difficult to detect based on bacterial culture tests¹²; thus, it is often diagnosed histopathologically¹³. Moreover, *Actinomyces* species morphologically resembles *Nocardia* species¹⁴ and it is possible that *R. aeria* infection was treated as *Actinomyces* or *Nocardia* infection.

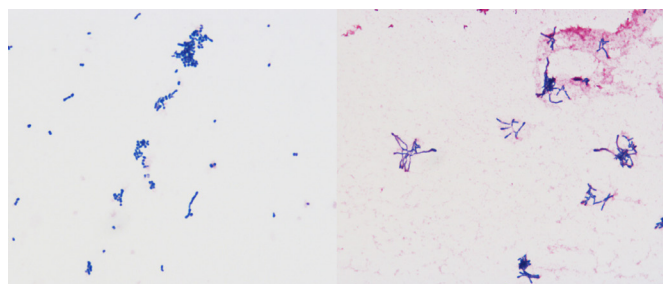


Figure 2 *Rothia aeria* as observed microscopically.

Molecular approaches such as mass spectrometry and DNA sequencing are considered to diagnose accurately the infections caused by *R. aeria*.

Furthermore, Tsuzukibashi *et al*¹⁵ reported oral *Rothia* species selective medium as a new culture medium for the isolation and possible easy detection of *Rothia* species from the oral cavity.

There are no comprehensive data on the drug susceptibility of *R. aeria*; therefore, we selected antibiotics based on previous case reports. Tarumoto *et al*² reported on *R. aeria*-induced infectious endocarditis and that it was susceptible to most antibiotics except clindamycin and vancomycin. Monju *et al*³ reported that ampicillin and cefotaxime were active against neonatal sepsis caused by *R. aeria*. Using drug susceptibility tests, *R. aeria* demonstrated good sensitivity against most antibiotics except for clindamycin. Hiyamuta⁴ reported on a respiratory infection caused by *R. aeria* that was successfully treated with benzylpenicillin. They found no reports of drug resistance, and similar to *Actinomyces*, *R. aeria*'s sensitivity to benzylpenicillin was good.

Tube-ovarian abscess was treated by the conservative administration of antibiotics, considering the timing of surgical intervention. After removal of the IUCD, which was considered to be the cause of infection in this case, and after initiating antibiotic therapy, leucocyte count, CRP level and fever gradually decreased, and the patient's entire body condition improved. Therefore, surgical intervention was deemed inessential. However, there was a possibility of reducing the duration of antibiotic treatment by surgical intervention, and we should have made an effort to reduce the risk of incidence of antibiotic-resistant bacteria, considering injury to other organs due to strong adhesions.

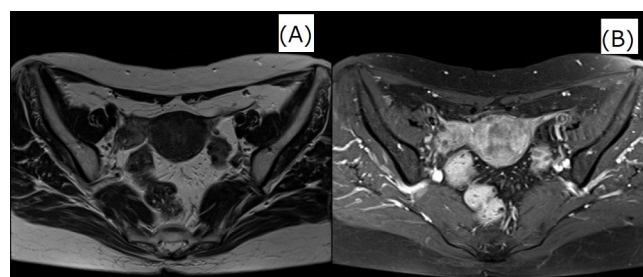


Figure 3 Images obtained after 6 months of the treatment. MRI and transvaginal ultrasonography revealed shrinkage of right adnexal mass. (A)MRI T2-weighted image and (B)MRI fat suppression gadolinium contrast T1-weighted image.

Learning points

- ▶ This is the first case report to identify *Rothia aeria* as a causative bacterium for a gynaecological infection.
- ▶ The sensibility of antibiotics was good.
- ▶ The advances of the mass spectrometer and analysis of base sequence can identify a bacterial species in detail, possibly facilitating identification of an infection due to an unprecedented bacterial species.

Contributors YT designed this manuscript and wrote the initial draft. YA contributed to the planning, conduct and reporting of the work described in the article. Both the authors have contributed to data collection and interpretation and critically reviewed the manuscript. Both the authors approved the final version of the manuscript and agree to be accountable for all aspects of the work in ensuring that questions related to the accuracy or integrity of any part of the work are appropriately investigated and resolved.

Funding The authors have not declared a specific grant for this research from any funding agency in the public, commercial or not-for-profit sectors.

Competing interests None declared.

Patient consent for publication Obtained.

Provenance and peer review Not commissioned; externally peer reviewed.

Open access This is an open access article distributed in accordance with the Creative Commons Attribution Non Commercial (CC BY-NC 4.0) license, which permits others to distribute, remix, adapt, build upon this work non-commercially, and license their derivative works on different terms, provided the original work is properly cited and the use is non-commercial. See: <http://creativecommons.org/licenses/by-nc/4.0/>

REFERENCES

- 1 Li Y, Kawamura Y, Fujiwara N, et al. *Rothia aeria* sp. nov., *Rhodococcus baikonurensis* sp. nov. and *Arthrobacter ruscicus* sp. nov., isolated from air in the Russian space laboratory Mir. *Int J Syst Evol Microbiol* 2004;54:827–35.
- 2 Taramoto N, Sujino K, Yamaguchi T, et al. A first report of *Rothia aeria* endocarditis complicated by cerebral hemorrhage. *Intern Med* 2012;51:3295–9.
- 3 Monju A, Shimizu N, Yamamoto M, et al. First case report of sepsis due to *Rothia aeria* in a neonate. *J Clin Microbiol* 2009;47:1605–6.
- 4 Hiyamuta H. First case report of respiratory infection with *Rothia aeria*. *the Journal of the Japanese Respiratory Society* 2014;48:219–23.
- 5 Fan Y, Jin Z, Tong J, et al. *Rothia amarae* sp. nov., from sludge of a foul water sewer. *Int J Syst Evol Microbiol* 2002;52:2257–60.
- 6 Onishi M. Study on the Actinomyces isolated from the deeper layer of carious dentine. *Shikagaku Zasshi* 1949;6:273–82.
- 7 Lucille K Georg, June M Brown. *Rothia*, gen. nov. an aerobic genus of the family Actinomycetaceae. *International Journal of Systematic and Evolutionary Microbiology* 1967;17:79–88.
- 8 Xiong ZJ, Zhang JL, Zhang DF, et al. *Rothia endophytica* sp. nov., an actinobacterium isolated from *Dysophylla stellata* (Lour.) Benth. *Int J Syst Evol Microbiol* 2013;63(Pt 11):3964–9.
- 9 Collins MD, Hutson RA, Bäverud V, et al. Characterization of a *Rothia*-like organism from a mouse: description of *Rothia nasimurium* sp. nov. and reclassification of *Stomatococcus mucilaginosus* as *Rothia mucilaginosus* comb. nov. *Int J Syst Evol Microbiol* 2000;50 Pt 3:1247–51.
- 10 Chou YJ, Chou JH, Lin KY, et al. *Rothia terrae* sp. nov. isolated from soil in Taiwan. *Int J Syst Evol Microbiol* 2008;58(Pt 1):84–8.
- 11 Henderson SR. Pelvic actinomycosis associated with an intrauterine device. *Obstet Gynecol* 1973;41:726–58.
- 12 Hager WD, Douglas B, Majmudar B, et al. Pelvic colonization with Actinomyces in women using intrauterine contraceptive devices. *Am J Obstet Gynecol* 1979;135:680–4.
- 13 Luff RD, Gupta PK, Spence MR, et al. Pelvic actinomycosis and the intrauterine contraceptive device. A cyto-histomorphologic study. *Am J Clin Pathol* 1978;69:581–6.
- 14 Kim UJ, Won EJ, Kim JE, et al. *Rothia aeria* infective endocarditis: a first case in Korea and literature review. *Ann Lab Med* 2014;34:317–20.
- 15 Tsuzukibashi O, Uchibori S, Kobayashi T, et al. Isolation and identification methods of *Rothia* species in oral cavities. *J Microbiol Methods* 2017;134:21–6.

Copyright 2019 BMJ Publishing Group. All rights reserved. For permission to reuse any of this content visit <https://www.bmj.com/company/products-services/rights-and-licensing/permissions/>
BMJ Case Report Fellows may re-use this article for personal use and teaching without any further permission.

Become a Fellow of BMJ Case Reports today and you can:

- ▶ Submit as many cases as you like
- ▶ Enjoy fast sympathetic peer review and rapid publication of accepted articles
- ▶ Access all the published articles
- ▶ Re-use any of the published material for personal use and teaching without further permission

Customer Service

If you have any further queries about your subscription, please contact our customer services team on +44 (0) 207111 1105 or via email at support@bmj.com.

Visit casereports.bmj.com for more articles like this and to become a Fellow