

Rare spontaneous intrahepatic portosystemic shunt in hepatitis B-induced cirrhosis: A case report

You-Wen Tan, Jian-Hui Sheng, Hui-Ying Tan, Li Sun, Yu-Mei Yin

ORCID number: You-Wen Tan (0000-0002-5464-1407); Jian-Hui Sheng (0000-0001-5989-414X); Hui-Ying Tan (0000-0002-2237-5490); Li Sun (0000-0002-7989-6190); Yu-Mei Yin (0000-0001-8906-8025).

Author contributions: Tan YW, Sheng JH and Tan HY contributed equally to this work. Tan YW and Sheng JH designed the research; Tan HY, Sun L and Yin YM collected and analyzed the data, and drafted the manuscript; Tan YW and Tan HY wrote and revised the manuscript; all authors have read and approved the final version to be published.

Informed consent statement: Informed consent was obtained from the parent.

Conflict-of-interest statement: The authors declare no conflict of interest.

CARE Checklist (2016) statement: The manuscript was prepared and revised according to the CARE 2016 Checklist.

Open-Access: This article is an open-access article which was selected by an in-house editor and fully peer-reviewed by external reviewers. It is distributed in accordance with the Creative Commons Attribution Non Commercial (CC BY-NC 4.0) license, which permits others to distribute, remix, adapt, build upon this work non-commercially, and license their derivative works on different terms, provided the original work is properly cited and the use is non-commercial. See: <http://creativecommons.org/licenses/by-nc/4.0/>

You-Wen Tan, Jian-Hui Sheng, Hui-Ying Tan, Li Sun, Yu-Mei Yin, Department of Hepatology, The Third Hospital of Zhenjiang Affiliated Jiangsu University, Zhenjiang 212003, Jiangsu Province, China

Corresponding author: You-Wen Tan, MD, PhD, Chief Doctor, Department of Hepatology, The Third Hospital of Zhenjiang Affiliated Jiangsu University, No. 300, Daijiamen, Runzhou Distinct, Zhenjiang 212003, Jiangsu Province, China. tyw915@sina.com

Telephone: +86-511-88970796

Fax: +86-511-88970796

Abstract

BACKGROUND

The portosystemic shunt is the pathway between the portal vein (PV) and systemic circulation. A spontaneous intrahepatic portosystemic shunt (SPISS) is a rare portosystemic shunt type. Here we report an extremely rare type of SPISS, a spontaneous intrahepatic PV-inferior vena cava shunt (SPIVCS).

CASE SUMMARY

A 66-year-old woman was admitted to our hospital with the complaint of abdominal distention and a decreased appetite for 1 mo. The patient had a 20-year history of hepatitis B surface antigen positivity and a 5-year history of cirrhosis. She had been treated with Chinese herbal medicine for a long time. Liver function tests showed: alanine aminotransferase, 35 U/L; aspartate aminotransferase, 42 U/L; serum albumin (ALB) 32.2 g/L; and serum ascites ALB gradient, 25.2 g/L. Abdominal ultrasonography and enhanced computed tomography showed that the left branch of the PV was thin and occluded; the right branch of the PV was thick and showed a vermicular dilatation vein cluster in the upper pole of the right kidney that branched out and converged into the inferior vena cava from the bare area of the lower right posterior lobe of the liver. We diagnosed her with an extremely rare SPIVCS caused by portal hypertension and provided symptomatic treatment after admission. One week later, her symptoms disappeared and she was discharged.

CONCLUSION

SPIVCS is a rare portosystemic shunt with a clear history of cirrhosis and portal hypertension. Clarifying the type PV shunt has important clinical significance.

Key words: Spontaneous; Intrahepatic; Portosystemic shunt; Cirrhosis; Case report

©The Author(s) 2019. Published by Baishideng Publishing Group Inc. All rights reserved.

ses/by-nc/4.0/

Manuscript source: Unsolicited manuscript**Received:** March 15, 2019**Peer-review started:** March 15, 2019**First decision:** July 30, 2019**Revised:** August 1, 2019**Accepted:** August 20, 2019**Article in press:** August 20, 2019**Published online:** September 6, 2019**P-Reviewer:** Poddighe D, Dumitrascu DL**S-Editor:** Dou Y**L-Editor:** Wang TQ**E-Editor:** Qi LL

Core tip: Here we report a spontaneous intrahepatic portal vein (PV)-inferior vena cava shunt. A 66-year-old woman was admitted to our hospital with a 20-year history of HBsAg and a 5-year history of cirrhosis. Abdominal ultrasonography and enhanced computed tomography showed that the left branch of the PV was thin and occluded; the right branch of the PV was thick and showed a vermicular dilatation vein cluster in the upper pole of the right kidney that branched out and converged into the inferior vena cava from the bare area of the lower right posterior lobe of the liver.

Citation: Tan YW, Sheng JH, Tan HY, Sun L, Yin YM. Rare spontaneous intrahepatic portosystemic shunt in hepatitis B-induced cirrhosis: A case report. *World J Clin Cases* 2019; 7(17): 2573-2579

URL: <https://www.wjgnet.com/2307-8960/full/v7/i17/2573.htm>

DOI: <https://dx.doi.org/10.12998/wjcc.v7.i17.2573>

INTRODUCTION

Liver cirrhosis is often accompanied by portal hypertension, which often manifests as esophageal varices, ascites, splenomegaly, hypersplenism, upper gastrointestinal hemorrhage, portosystemic shunt encephalopathy, and spontaneous bacterial peritonitis^[1]. Spontaneous portosystemic shunt (SPSS), a common but insufficient clinical manifestation, is a result of compensation of portal hypertension in cirrhosis^[2]. The shunt can be congenital or acquired^[3]. The incidence rate of SPSS in patients with cirrhosis is 38%-40%, and the incidence rate of splenorenal shunt (SRS) is 14%-21%^[4]. The most common types of SPSS are SRS and umbilical vein recanalization^[5]. Rare types include collateral veins in gastric varices, gallbladder varices, thrombotic portal vein (PV), intestinal-caval shunt, and right portal-renal vein shunt^[6]. Spontaneous intrahepatic portosystemic shunt (SPISS), a rare SPSS type, includes PV branches that directly shunt to the intrahepatic vein and PV branches that shunt to the extrahepatic inferior vena cava (IVC).

We recently encountered a 66-year-old woman with a 20-year history of hepatitis B surface antigen (HBsAg) positivity. We found that she had an extremely rare SPISS, a spontaneous intrahepatic PV-IVC shunt (SPIVCS) caused by portal hypertension.

CASE PRESENTATION

Chief complaints

A 66-year-old woman was admitted to our hospital with the complaint of a 1-mo history of abdominal distention and decreased appetite.

History of present illness

She had no history of ascites, gastrointestinal bleeding, or hepatic encephalopathy. She had no history of alcohol abuse or hepatitis C.

History of past illness

The patient also had a 20-year history of HBsAg positivity and had been treated with Chinese herbal medicine for a long time. In the past 5 years, she had been diagnosed with cirrhosis induced by hepatitis B by a rural doctor.

Personal and family history

No alcohol abuse and no other drug and herbal used. No additional family history. While her daughter had history of HBsAg positivity but no history of hereditary diseases.

Physical examination upon admission

A physical examination revealed a blood pressure of 135/82 mmHg, heart rate of 78 beats/min, temperature of 36.8°C, and breathing rate of 18 times/min. Her skin was dark and gloomy; no yellowing of the skin and mucosa was evident; visible liver palms and spider angioma, an abdominal bulge, and visible abdominal wall vein exposure were evident, and splenomegaly (4 cm below the left midclavicular line-left ribs junction) were evident; no abdominal pain was reported; and the ascites buckle sign was positive.

Laboratory examinations

Routine bloodwork revealed the following: red blood cell count, $2.13 \times 10^9/L$; hemoglobin, 6.12 g/L; white blood cell count, $2.43 \times 10^9/L$; neutrophil count, $1.86 \times 10^9/L$; and platelet count, $5.25 \times 10^{12}/L$. Liver function test results were as follows: alanine aminotransferase, 35 U/L (10-40 U/L); aspartate aminotransferase, 42 U/L (10-40 U/L); serum total bilirubin, 17.2 $\mu\text{mol}/L$ (1.71-17.1 $\mu\text{mol}/L$); direct bilirubin, 4.26 $\mu\text{mol}/L$ (0-6.8 $\mu\text{mol}/L$); serum albumin (ALB), 32.2 g/L (35-53 g/L); serum globulin 28 g/L (20-40 g/L); alkaline phosphatase, 89 U/L (40-120 U/L); glutamyl transphthalase, 63 U/L (10-40 U/L); and serum ammonia, 45 $\mu\text{mol}/L$ (27-82 $\mu\text{mol}/L$). Hepatitis B virus (HBV) markers were as follows: HBsAg, 26 IU/mL (< 0.05 IU/mL); anti-HBs, 0.001 mIU/mL (< 10 mIU/mL); anti-hepatitis B e antigen, 2.143 Paul Ehrlich international units (PEIU)/mL (< 0.2 PEIU/mL); anti-hepatitis B core antigen, 3.221 PEIU/mL (< 0.9 PEIU/mL).

Other results were as follows: HBV DNA, not detected (< 20 IU/mL); alpha fetoprotein, 4.25 $\mu\text{g}/L$ (< 20 ng/mL); ascites examination, clear; Li Fanta test, negative; nucleated cell count, $0.82 \times 10^9/L$; monocyte ratio, 55%; polymorphonuclear cell ratio, 45%; and serum ascites ALB gradient, 25.2 g/L.

Antinuclear antibody, anti-smooth muscle antibody, anti-liver/kidney microsome antibody type 1, anti-nuclear glycoprotein antibody, anti-soluble acid nucleoprotein antibody, soluble acidic nucleoprotein antibody, anti-hepatocyte cytoplasmic antigen type 1 antibody, anti-soluble liver antigen/hepatopancreatic antigen antibody, and other tests were negative. Other levels were: immunoglobulin G (IgG), 13.1 g/L (7.11-16 g/L); IgG4, 0.08 g/L (≤ 2.01 g/L); and ceruloplasmin, 0.33 g/L (0.2-0.6 g/L).

Imaging examinations

Abdominal ultrasonography revealed that echoes of the liver showed dense thickening and an uneven intrahepatic structure disorder; the liver capsule was unclear and irregular. The right branch of the PV showed obvious dilatation (local dilatation, up to 48 mm), was connected with the IVC, and showed a turbulent local spectrum, as shown in [Figure 1](#).

Abdomen enhanced computed tomography (CT) revealed that the left branch of the PV was thin and occluded, while the right branch of the PV was thick, showed a vermicular dilatation vein cluster, branched out, and converged into the IVC from the bare area of the lower right posterior lobe of the liver, forming a venous dilatation vein cluster in the upper pole of the right kidney ([Figure 2](#) and [3](#)). In addition, a vermicular dilatation vein shadow was seen in the inner wall of the lower esophagus, perineural space, and hepatic-gastric space and the splenic vein diameter was increased to 1.7 cm. A portion of the liver lobe was disordered and the hepatic fissure was widened. The spleen was enlarged and numerous liquid shadows were visible in the abdominal cavity.

FINAL DIAGNOSIS

A rare SPISS in hepatitis B-induced cirrhosis.

TREATMENT

After admission, 3000 mL of ascites fluid was drained, 20 g of human ALB was intravenously infused, and 100 mg of spironolactone and 40 mg of furosemide were administered per day. One week later, the abdominal distension was relieved, her appetite improved, and she was discharged with maintenance therapy of propranolol 20 mg/d.

OUTCOME AND FOLLOW-UP

Follow-up of liver function and ultrasonography every 3 mo after discharge showed no further deterioration of liver function and ascites.

DISCUSSION

The portosystemic shunt is the pathway between the PV and the systemic circulation^[7]. By etiology, it can be divided into congenital and spontaneous types^[8] as

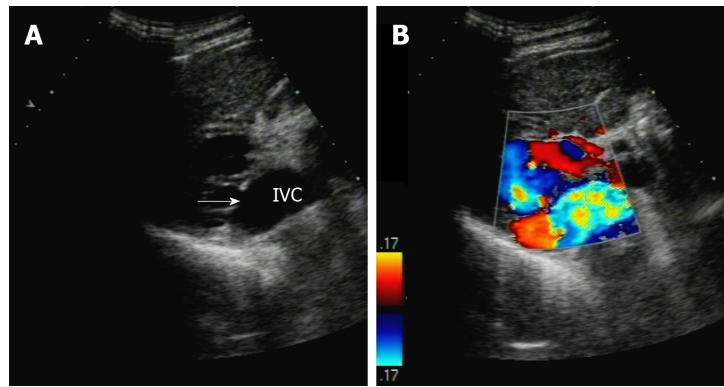


Figure 1 Ultrasonography revealed a spontaneous intrahepatic portosystemic shunt. A: The branch of the right portal vein connects to the inferior vena cava through (arrow); B: The extrahepatic venous plexus showed turbulent spectrum locally. IVC: Inferior vena cava.

well as intrahepatic and extrahepatic types according to anatomical location^[9].

SPISS is a spontaneous venous pathway that extends from the intrahepatic venous system to the circular venous system^[10]. It is mostly acquired, but a congenital type has not been identified^[11]. Lalonde *et al*^[12] reported a SPIVCS case which may belong to the congenital type because the patient was only a 15-year-old adolescent with no evidence of liver cirrhosis or portal hypertension. There are still two types of SPISS: one in which the intrahepatic PV branch shunts to the intrahepatic vein, and another in which the intrahepatic PV shunts to the IVC through the lateral hepatic branch. The first type can occur in cases of tumors, liver trauma, or Budd-Chiari syndrome (BCS)^[13,14]. The second type is very rarely discussed and refers to the right posterior branch of the PV connected with the IVC through the right posterior lobe of the liver in the right adrenal region. SPIVCS is common in cirrhosis patients with portal hypertension. Its possible anatomical basis is that the right branch of the PV communicates with the IVC through the accessory hepatic vein or the subcapsular venous plexus of the liver. Since there is no standard proper term to describe this type of shunt, we refer to it as SPIVCS.

Abernethy malformation is also a SPSS that requires differentiation from SPISS, a rare congenital extrahepatic portosystemic shunt malformation caused by abnormal development of the PV system^[15]. Morgan and Supefina classified Abernethy malformations as follows^[16]: type I, complete portosystemic shunt without PV perfusion in the liver; and type II, partial portosystemic shunt with partial portosystemic blood perfusion in the liver. Type I primarily affects children and women and is often accompanied by other congenital malformations such as biliary atresia, polysplenoma, heart defects, and liver tumors. Type II is rarer, primarily affects men, and features few other congenital malformations. Moreover, Abernethy malformation has no underlying diseases such as cirrhosis or portal hypertension and primarily affects children^[17].

We retrieved the PubMed database using “intrahepatic portosystemic shunt,” “intrahepatic portal cavity shunt,” “spontaneous intrahepatic portosystemic shunt,” and “porto inferior vena cava shunt” keywords and MeSH terms, respectively. By January 31, 2019, six articles describing intrahepatic SPSS similar to ours were found, as shown in Table 1.

During liver transplantation for severe hepatic encephalopathy, Vennarecci^[18] found a very thick shunt between the right branch of the PV and IVC, which made the operation more difficult. The shunt vein was torn during the operation, causing a massive hemorrhage. After hemostasis was achieved, the surgical strategy was changed to hepatectomy from the left side to the right side. Therefore, the SPIVCS shunt will increase the liver transplantation difficulty. Another SPISS type, which involves the PV branches directly shunting to the intrahepatic vein, can be caused by intrahepatic tumors and trauma or occur spontaneously^[19].

BCS characterized by obstructive lesions of the hepatic vein and the IVC is another cause of SPISS that is shunted to the vena cava system via the subcapsular or intrahepatic veins^[14]. The use of a transjugular intrahepatic portosystemic shunt is an effective treatment for BCS-induced SPISS.

Kwon *et al*^[10] reported a case of laparoscopic surgery used to circumcise the inflow of varicose veins. Their patient’s hepatic encephalopathy improved postoperatively and liver function returned to normal. No shunt reappeared on a CT scan 8 mo later.

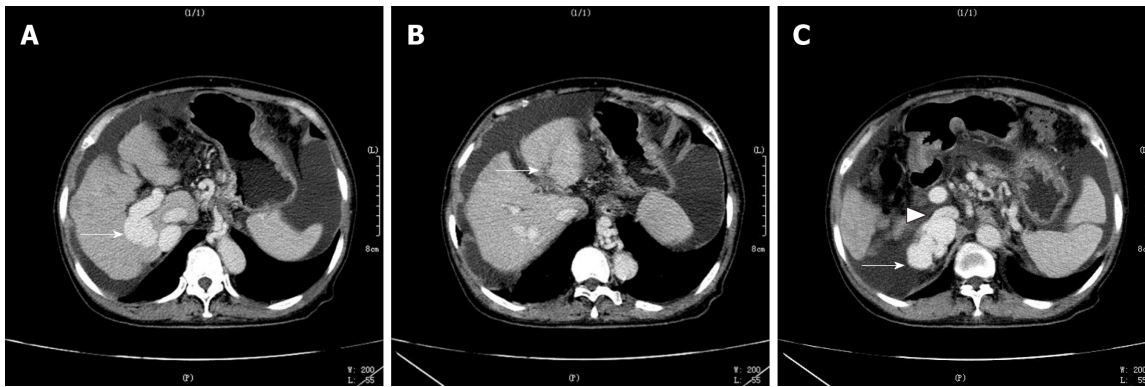


Figure 2 Abdomen enhanced computed tomography revealed a spontaneous intrahepatic portosystemic shunt. A: The right branch of portal vein (PV) was thick and showed vermicular dilatation vein cluster (arrow); B: The left branch of PV was thin and occluded (arrow); C: The right branch of PV connected with inferior vena cava (arrowhead), extrahepatic dilatation and distortion of blood vessels (arrow).

CONCLUSION

SPIVCS is a rare portosystemic shunt with a clear history of cirrhosis and portal hypertension. Clarifying the PV shunt has important clinical significance: (1) it aids the differential diagnosis of PV aneurysm and right adrenal lesion; (2) it guides clinical treatment because patients with PV shunt are more likely to suffer from hepatic encephalopathy induced by elevated blood ammonia; and (3) for patients who need surgical or other interventions such as abdominal puncture, the shunt helps the surgeon plan ahead of time.

Table 1 Clinical characteristics and treatment of spontaneous intrahepatic portosystemic shunt in literature reports

Reporters	Country	Sex	Old (yr)	History of liver disease	Encephalopathy	Serum ammonia	Liver function test	Splenomegaly	The maximum diameters of shunt
Kwon <i>et al</i> ^[10]	Korea	Woman	42	No	Yes	146 µg/dL	ALT, 152 U/L; AST, 112 U/L;	No	30.4 mm
Qi <i>et al</i> ^[20]	China	Man	58	Cirrhosis (HBV)	No	35 µmol/L	TBIL, 48.9 µmol/L, ALT, 66.04 U/L, AST, 93.11 U/L	Moderate	ND
Tsauo <i>et al</i> ^[21]	China	Woman	36	Cirrhosis (AIH)	ND	ND	ND	Yes	ND
Vennarecci <i>et al</i> ^[18]	Italy	ND	ND	ND	Yes	ND	ND	Yes	ND
Lalonde <i>et al</i> ^[12]	Belgium	Man	15	No	No	ND	Abnormal liver function	No	20 mm
Peng-Xu Ding <i>et al</i> ^[14]	China	Woman	42	Cirrhosis (HCV)	ND	ND	ND	ND	ND

TBIL: Total bilirubin; ALT: Alanine aminotransferase; AST: Aspartate aminotransferase; ALB: Albumin; ND: No describe; HBV: Hepatitis B virus; AIH: Autoimmune hepatitis.

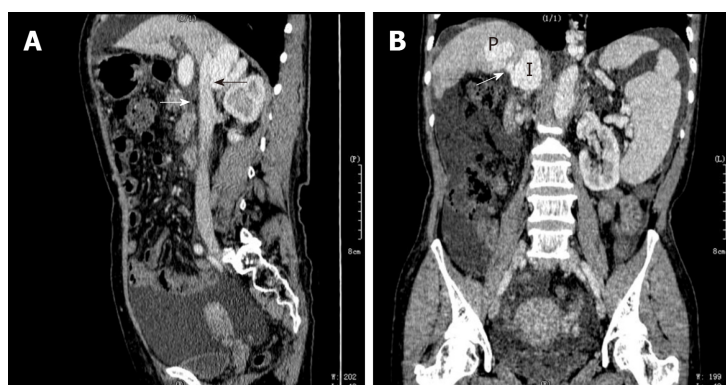


Figure 3 Abdomen enhanced computed tomography revealed a spontaneous intrahepatic portosystemic shunt at sagittal and coronal position. A: The right branch of portal vein (PV) shunt out of the liver to communicate with inferior vena cava (IVC) (arrow) at sagittal position (black arrow); B: The right branch of PV shunt out of the liver to communicate with IVC (arrow) at coronal position.

REFERENCES

- 1 **Simpson JA**, Conn HO. Role of ascites in gastroesophageal reflux with comments on the pathogenesis of bleeding esophageal varices. *Gastroenterology* 1968; **55**: 17-25 [PMID: 5663501 DOI: 10.1016/S0016-5085(19)34094-6]
- 2 **Lipinski M**, Saborowski M, Heidrich B, Attia D, Kasten P, Manns MP, Gebel M, Potthoff A. Clinical characteristics of patients with liver cirrhosis and spontaneous portosystemic shunts detected by ultrasound in a tertiary care and transplantation centre. *Scand J Gastroenterol* 2018; **53**: 1107-1113 [PMID: 30270689 DOI: 10.1080/00365521.2018.1498913]
- 3 **Pocha C**, Maliakkal B. Spontaneous intrahepatic portal-systemic venous shunt in the adult: case report and review of the literature. *Dig Dis Sci* 2004; **49**: 1201-1206 [PMID: 15387347 DOI: 10.1023/B:DDAS.0000037813.24605.d5]
- 4 **Li M**, Li Q, Lei Q, Hu J, Wang F, Chen H, Zhen Z. Unusual bleeding from hepaticojunostomy controlled by side-to-side splenorenal shunt: A case report. *Medicine (Baltimore)* 2018; **97**: e11784 [PMID: 30095636 DOI: 10.1097/MD.00000000000011784]
- 5 **Zardi EM**, Uwechie V, Caccavo D, Pellegrino NM, Cacciapaglia F, Di Matteo F, Dobrina A, Laghi V, Afeltra A. Portosystemic shunts in a large cohort of patients with liver cirrhosis: detection rate and clinical relevance. *J Gastroenterol* 2009; **44**: 76-83 [PMID: 19159076 DOI: 10.1007/s00535-008-2279-1]
- 6 **von Herbay A**, Frieling T, Häussinger D. Color Doppler sonographic evaluation of spontaneous portosystemic shunts and inversion of portal venous flow in patients with cirrhosis. *J Clin Ultrasound* 2000; **28**: 332-339 [PMID: 10934332 DOI: 10.1002/1097-0096(200009)28:7<332::AID-JCU3>3.0.CO;2-9]

- 7 **Pillai AK**, Andring B, Patel A, Trimmer C, Kalva SP. Portal hypertension: a review of portosystemic collateral pathways and endovascular interventions. *Clin Radiol* 2015; **70**: 1047-1059 [PMID: 26188844 DOI: 10.1016/j.crad.2015.06.077]
- 8 **Henseler KP**, Pozniak MA, Lee FT, Winter TC. Three-dimensional CT angiography of spontaneous portosystemic shunts. *Radiographics* 2001; **21**: 691-704 [PMID: 11353116 DOI: 10.1148/radiographics.21.3.g01ma14691]
- 9 **Kamel IR**, Lawler LP, Corl FM, Fishman EK. Patterns of collateral pathways in extrahepatic portal hypertension as demonstrated by multidetector row computed tomography and advanced image processing. *J Comput Assist Tomogr* 2004; **28**: 469-477 [PMID: 15232377 DOI: 10.1097/00004728-200407000-00006]
- 10 **Kwon JN**, Jeon YS, Cho SG, Lee KY, Hong KC. Spontaneous intrahepatic portosystemic shunt managed by laparoscopic hepatic vein closure. *J Minim Access Surg* 2014; **10**: 207-209 [PMID: 25336823 DOI: 10.4103/0972-9941.141528]
- 11 **Golli M**, Kriaa S, Said M, Belguith M, Zbidi M, Saad J, Nouri A, Ganouni A. Intrahepatic spontaneous portosystemic venous shunt: value of color and power Doppler sonography. *J Clin Ultrasound* 2000; **28**: 47-50 [PMID: 10602106 DOI: 10.1002/(SICI)1097-0096(200001)28:1<47::AID-JCU8>3.0.CO;2-V]
- 12 **Lalonde L**, Van Beers B, Trigaux JP, Delos M, Melange M, Pringot J. Focal nodular hyperplasia in association with spontaneous intrahepatic portosystemic venous shunt. *Gastrointest Radiol* 1992; **17**: 154-156 [PMID: 1551514 DOI: 10.1007/BF01888534]
- 13 **Borentain P**, Soussan J, Resseguier N, Botta-Fridlund D, Dufour JC, Gérolami R, Vidal V. The presence of spontaneous portosystemic shunts increases the risk of complications after transjugular intrahepatic portosystemic shunt (TIPS) placement. *Diagn Interv Imaging* 2016; **97**: 643-650 [PMID: 26947721 DOI: 10.1016/j.diii.2016.02.004]
- 14 **Ding PX**, Li Z, Han XW, Zhang WG, Zhou PL, Wang ZG. Spontaneous intrahepatic portosystemic shunt in Budd-Chiari syndrome. *Ann Vasc Surg* 2014; **28**: 742.e1-742.e4 [PMID: 24495329 DOI: 10.1016/j.avsg.2013.06.031]
- 15 **Lemoine C**, Nilsen A, Brandt K, Mohammad S, Melin-Aldana H, Superina R. Liver histopathology in patients with hepatic masses and the Abernethy malformation. *J Pediatr Surg* 2019; **54**: 266-271 [PMID: 30528201 DOI: 10.1016/j.jpedsurg.2018.10.083]
- 16 **Morgan G**, Superina R. Congenital absence of the portal vein: two cases and a proposed classification system for portosystemic vascular anomalies. *J Pediatr Surg* 1994; **29**: 1239-1241 [PMID: 7807356 DOI: 10.1016/0022-3468(94)90812-5]
- 17 **Soota K**, Klair JS, LaBrecque D. Confusion for Fifteen Years: A Case of Abernethy Malformation. *Clin Gastroenterol Hepatol* 2018; **16**: A50 [PMID: 29330099 DOI: 10.1016/j.cgh.2018.01.003]
- 18 **Vennarecci G**, Levi Sandri GB, Laurenzi A, Ettore GM. Spontaneous intrahepatic portocaval shunt in a patient undergoing liver transplantation. *Dig Liver Dis* 2014; **46**: e9 [PMID: 24629821 DOI: 10.1016/j.dld.2014.02.011]
- 19 **Soon MS**, Chen YY, Yen HH. Hepatobiliary and pancreatic: spontaneous intrahepatic portosystemic venous shunt. *J Gastroenterol Hepatol* 2006; **21**: 918 [PMID: 16704549 DOI: 10.1111/j.1440-1746.2006.04481.x]
- 20 **Qi X**, Ye C, Hou Y, Guo X. A large spontaneous intrahepatic portosystemic shunt in a cirrhotic patient. *Intractable Rare Dis Res* 2016; **5**: 58-60 [PMID: 26989653 DOI: 10.5582/irdr.2016.01000]
- 21 **Tsauo J**, Shin JH, Han K, Yoon HK, Ko GY, Ko HK, Gwon DI. Transjugular Intrahepatic Portosystemic Shunt for the Treatment of Chylothorax and Chylous Ascites in Cirrhosis: A Case Report and Systematic Review of the Literature. *J Vasc Interv Radiol* 2016; **27**: 112-116 [PMID: 26723922 DOI: 10.1016/j.jvir.2015.09.022]



Published By Baishideng Publishing Group Inc
7041 Koll Center Parkway, Suite 160, Pleasanton, CA 94566, USA
Telephone: +1-925-2238242
Fax: +1-925-2238243
E-mail: bpgoffice@wjgnet.com
Help Desk: <https://www.f6publishing.com/helpdesk>
<https://www.wjgnet.com>

