

ARMC5 Alterations in Primary Macronodular Adrenal Hyperplasia (PMAH) and the Clinical State of Variant Carriers

Chika Kyo,¹ Takeshi Usui,^{2,3} Rieko Kosugi,^{1,2} Mizuki Torii,¹ Takako Yonemoto,^{1,2} Tatsuo Ogawa,¹ Masato Kotani,¹ Naohisa Tamura,^{1,3} Yutaro Yamamoto,⁴ Takuyuki Katabami,⁴ Isao Kurihara,⁵ Kohei Saito,^{1,2,3,5} Naotetsu Kanamoto,⁶ Hidenori Fukuoka,⁷ Norio Wada,⁸ Hiroyuki Murabe,⁹ and Tatsuhide Inoue¹

¹Center for Diabetes, Endocrinology and Metabolism, Shizuoka General Hospital, Shizuoka, 4208527, Japan; ²Department of Medical Genetics, Shizuoka General Hospital, Shizuoka, 4208527, Japan; ³Research Support Center, Shizuoka General Hospital, Shizuoka, 4208527, Japan; ⁴Division of Metabolism and Endocrinology, Department of Internal Medicine, St. Marianna University School of Medicine Yokohama City Seibu Hospital, Yokohama, 2410811, Japan; ⁵Division of Endocrinology, Metabolism, and Nephrology, Department of Internal Medicine, Keio University School of Medicine, Tokyo, 1600016, Japan; ⁶Department of Endocrinology, Osaka City General Hospital, Osaka, 5340021, Japan; ⁷Division of Diabetes and Endocrinology, Kobe University Hospital, Kobe, 6500017, Japan; ⁸Department of Diabetes and Endocrinology, Sapporo City General Hospital, Sapporo, 0608604, Japan; and ⁹Department of Endocrinology and Rheumatology, Kurashiki Central Hospital, Kurashiki, 7108602, Japan

ORCID numbers: 0000-0002-8301-6766 (T. Usui).

Context: Primary macronodular adrenal hyperplasia (PMAH) is a rare type of Cushing or subclinical Cushing syndrome and is associated with bilateral multinodular formation. *ARMC5* is one of the responsible genes for PMAH.

Objectives: This study was performed to identify the genotype-phenotype correlation of *ARMC5* in a cohort of Japanese patients.

Patients and Methods: Fourteen patients with clinically diagnosed PMAH and family members of selected patients were studied for *ARMC5* gene alteration and clinical phenotype. The associated nonadrenal tumor tissues were also studied.

Results: Of fourteen patients with PMAH, 10 had pathogenic or likely pathogenic variants of *ARMC5*. We found two variants. Five unrelated patients had identical variants (p.R619*). In two patients, the variant was found in offspring with the asymptomatic or presymptomatic state. Six of ten patients who tested positive for the *ARMC5* pathogenic or likely pathogenic variant carried nonadrenal tumors; however, no loss of heterozygosity (LOH) or second hit of the *ARMC5* gene was evident. The *ARMC5* variant-positive group showed a significantly higher basal cortisol level. Furthermore, age-dependent cortisol hypersecretion was seen in the *ARMC5* variant-positive group.

Conclusions: *ARMC5* pathogenic variants are common (71%) in Japanese patients with PMAH. p.R619* might be a hot spot in Japanese patients with PMAH. Asymptomatic or presymptomatic pathogenic variant carriers were found among the family members of the patients. Although 50% of *ARMC5* variant carriers had nonadrenal neoplastic lesions, no LOH or second hit of *ARMC5* in the tumor tissues was evident. The *ARMC5* variant-positive mutant group showed a higher basal cortisol level than the negative group.

Abbreviations: CS, Cushing syndrome; DEX, dexamethasone; LOH, loss of heterozygosity; PMAH, primary macronodular adrenal hyperplasia; SCS, subclinical Cushing syndrome.

Copyright © 2019 Endocrine Society

This article has been published under the terms of the Creative Commons Attribution Non-Commercial, No-Derivatives License (CC BY-NC-ND; <https://creativecommons.org/licenses/by-nc-nd/4.0/>).

Freeform/Key Words: PMAH, *ARMC5*, variant carrier, the second hit

Primary macronodular adrenal hyperplasia (PMAH), formally called ACTH-independent macronodular adrenal hyperplasia, is one of the subtypes of Cushing syndrome (CS) or subclinical CS (SCS) and is characterized by multiple nodules in bilateral adrenal cortexes [1–3]. The prevalence of PMAH was reported to be <1% among all cases of endogenous CS [4]. Patients with PMAH display latent onset and slow progression of symptoms, leading to a late diagnosis of PMAH between the ages of 40 and 70 years old, with a high proportion of SCS [5, 6].

Although the pathophysiology of PMAH is not fully elucidated, previous studies have indicated that aberrant G-protein-coupled membrane receptors are expressed in the hyperplastic adrenal cells regulating cortisol synthesis [7]. Germline and somatic mutations of several genes were also reported to be involved in the mechanisms causing PMAH. Genes associated with PMAH include *PDE11A* (phosphodiesterase 11A) [8], *GNAS* (the stimulatory G protein alpha subunit) [9, 10], *APC* (adenomatous polyposis coli) [10, 11], and *FH* (fumarate hydratase) [10, 12], among others [13].

In 2013, *ARMC5* pathogenic germline variants were first identified in 55% (18 of 33) of patients with PMAH [14]. Subsequently, several studies reported damaging variants of *ARMC5* in patients with PMAH with frequencies ranging from 21% to 44% [15–19]. *ARMC5* was found to be the major responsible gene in PMAH [20]. A series of clinical genome sequencing studies revealed that *ARMC5* variants play an important role in adrenal tumorigenesis in PMAH [21]. *ARMC5* somatic variants have been detected in hyperplastic adrenocortical nodules of patients with PMAH in addition to germline mutations, supporting a “two-hit” model for *ARMC5* as a tumor suppressor gene [14, 22]. The second hit of *ARMC5* has been reported to cause extra-adrenal neoplasms, such as meningioma, in patients with PMAH who carried the *ARMC5* variant [16, 23]. However, the *ARMC5* contribution to the formation of other neoplasms in these patients has not been reported, despite the ubiquitous expression of *ARMC5* [24]. Previous studies showed that patients with PMAH and *ARMC5* mutations had a higher degree of autonomous cortisol secretion and larger adrenal nodules than patients with PMAH without *ARMC5* mutations [1, 17, 18]. *Armc5* knockout mice mimic the phenotype of PMAH [25, 26]. However, the temporal cortisol production profile or morphological changes in adrenal glands in *ARMC5* variant-positive patients had never been studied in humans.

1. Methods

A. Study Population

Fourteen patients with PMAH were recruited from seven endocrine facilities, without any exclusion criteria. This study included 13 patients with apparently sporadic PMAH and one patient with familial PMAH (Table 1, case 5). A diagnosis of CS was established by an expert endocrinologist at the time of presentation according to the Endocrine Society clinical guidelines for the diagnosis of CS [27]. SCS was defined as previously described [28]. Patients with apparently sporadic PMAH were defined as those without a family history based on the descriptions given by the patients. We define the presymptomatic state of PMAH as putative adrenal involvement in imaging study, without autonomous cortisol secretion.

We collected the clinical data and blood samples and surgically removed tumor samples for selected cases. We also studied family members of two probands (Table 1, cases 1 and 9). This

Table 1. Clinical Data and Genotypes of the Patients in This Study

Case	Age (y) ^a	Sex	CS or SCS	Familial	Nonadrenal Tumors
1	69	F	SCS	–	Breast cancer Colon cancer
2	51	F	SCS	–	—
3	58	F	SCS	–	Cervical cancer
4	64	M	SCS	–	—
5	71	F	CS	+	Breast cancer
6	44	M	SCS	–	—
7	53	F	SCS	–	Parathyroid tumor
8	47	M	SCS	–	Pancreatic neuroendocrine tumor
9	56	M	SCS	–	Thyroid cancer
10	73	F	CS	–	Thyroid adenoma
11	62	M	SCS	–	—
12	46	M	CS	–	—
13	59	M	SCS	–	—
14	46	M	SCS	–	—

Abbreviations: F, female; M, male.

^aAge at diagnosis.

study was approved by the Ethics Committee of Clinical Studies in Shizuoka General Hospital. All participants provided informed consent.

B. Hormonal Evaluation and Assays

Serum cortisol concentrations were measured via the chemiluminescence enzyme immunoassay method with an Elecsys Cortisol II (Roche Diagnostics GmbH, Mannheim, Germany) in cases 1 to 4, 6, 8, 10, 11, and 14; chemiluminescence (Immulite 2000; Siemens, Los Angeles, CA) in cases 5, 7, and 12; serum cortisol chemiluminescence enzyme immunoassay kits (Beckman Coulter, Fullerton, CA) in case 9; and chemiluminescence enzyme immunoassay (Fujifilm Corp., Tokyo, Japan) in case 13 [29–32]. Plasma ACTH levels were measured by Elecsys II in cases 1 to 6, 8 to 11, 13, and 14. Immulite (Siemens) was used in cases 7 and 12 [33, 34].

C. Genetic Analysis

Genomic DNA from the subjects was extracted from the peripheral blood or saliva with a genomic DNA purification kit (Qiagen, Hilden, Germany or DNA genoTek, Ottawa, Canada). The proband's genomic DNA was screened for variants in *ARMC5*. Each protein coding exon was amplified by PCR. After the PCR products were purified with a QIAquick PCR purification kit (Qiagen), direct sequencing was performed with a 3500 Genetic Analyzer (Applied Biosystems, Foster City, CA). Genomic DNA was also extracted from the surgically removed nonadrenal tumors for the patients who had accompanying tumors. Genomic DNA was extracted from a paraffin block with a NucleoSpin FFPE DNA kit (Takara, Shiga, Japan) according to the manufacturer's instructions. The variant data were evaluated with the Human Gene Mutation Database, and the pathogenicity was judged by the guidelines of the American College of Medical Genetics [35].

D. Statistical Analysis

We used *t* tests to compare the following hormonal parameters between patients with and without variants: basal cortisol level, late-night cortisol level, cortisol level after 1 mg of dexamethasone (DEX), and morning ACTH level. Univariate regression analysis was performed to clarify the associations between age and hormonal parameters, and slopes and *P* values were calculated. *P* < 0.05 was considered statistically significant. All statistical analyses were performed in JMP, version 13 (SAS Institute Inc., Cary, NC).

2. Results

A. Clinical Profiles and Genotypes of the Patients

Table 1 shows all the studied patients in this report. Of fourteen patients (eight men and six women), only one patient had a family history of PMAH (case 5 in **Table 1**). Among them, 10 patients (71%) harbored one of the five distinct genetic variants in the *ARMC5* gene (**Table 2**). Three of the variants (p.R619*: c.1855C>T, p.R898W: c.2692C>T, and p.R654*: c.1855) have been reported as pathogenic. Two unreported variants were found in two patients: case 10 (p.R362Q; c.1085G>A) and case 13 (p.G143fs*8; c.427_454del). p.R362Q was identified as a likely pathogenic variant, and p.G143fs*8 was judged as a pathogenic variant in accordance with the guidelines of the American College of Medical Genetics. The average age at diagnosis of pathogenic or likely pathogenic variant carrier or noncarrier was 57 years old in both groups. Five unrelated patients showed identical pathogenic nonsense variants (p.R619*). In case 5, two family members who had a diagnosis of PMAH had the same variants as the proband (data not shown).

B. Genotypes and Clinical Phenotypes of the Family Members

In one sporadic case (case 1), the clinical phenotype and genotype were examined for one of the daughters (age 39) with her informed consent. Her genotype of *ARMC5* was identical to that of the proband [**Fig. 1(a)**]; however, the basal cortisol level was 7.1 µg/dL and was suppressed to 0.7 µg/dL after the 1 mg DEX administration. The CT showed a small adrenal nodule in the left adrenal gland [**Fig. 1(b)**]. In case 9, two of the offspring (age 26 and 31) had the same *ARMC5* variant as the proband [**Fig. 1(c)**]. Neither of them showed basal cortisol elevation or suppression of ACTH, and III-1 showed cortisol suppression by 1 mg DEX [**Fig. 1(d)**]. The imaging study showed adrenal enlargement in the 31-year-old offspring but not in the 26-year-old offspring [**Fig. 1(e)–1(g)**].

C. *ARMC5* Gene in the Nonadrenal Tumors of Patients With PMAH

Among the 10 *ARMC5* variant carriers, five patients (50%) had accompanying nonadrenal tumors (**Table 1**). No loss of heterozygosity (LOH) or second hit of the *ARMC5* gene was demonstrated in any of the tumors examined in these five patients (cases 1, 5, 7, 9, and 10)

Table 2. Genotype and Clinical Data of the Patients

Case	Genotype	Basal Cortisol (µg/dL)	ACTH (pg/mL)	Late-Night Cortisol (µg/dL)	Cortisol After 1 mg DEX ^a (µg/dL)
1	p.R619* (c.1855C>T)	18.8	2.84	11	16.7
2	p.R619* (c.1855C>T)	13.7	7.53	7.3	6.4
3	Wild type	8.5	10.1	3.3	3.2
4	Wild type	7.09	13.3	6.9	9.25
5	p.R898W (c.2692C>T)	13.8	<1.0	13.6	15.4
6	p.R619* (c.1855C>T)	7.8	8.2	4.9	5.6
7	p.R654* (c.1855C>T)	10.7	8.4	7.9	5.2
8	Wild type	7.4	7.79	6.1	5.8
9	p.R619* (c.1855C>T)	12.8	<1.0	10.2	13.1
10	p.R362Q (c.1085G>A)	17.4	<2.0	16.1	27.6
11	p.R619* (c.1855C>T)	16.6	<2.0	12.4	ND
12	p.G143Sfs*8 (c.427_454del)	11.8	5.3	6.5	8.4
13	Wild type	8.6	10.1	5.3	2.1
14	p.R654* (c.1960C>T)	9.2	6.2	3.5	8.8

Abbreviation: ND, not done.

^a1 mg DEX is taken orally at 11 PM, and a single blood sample is drawn at 8 AM the next morning.

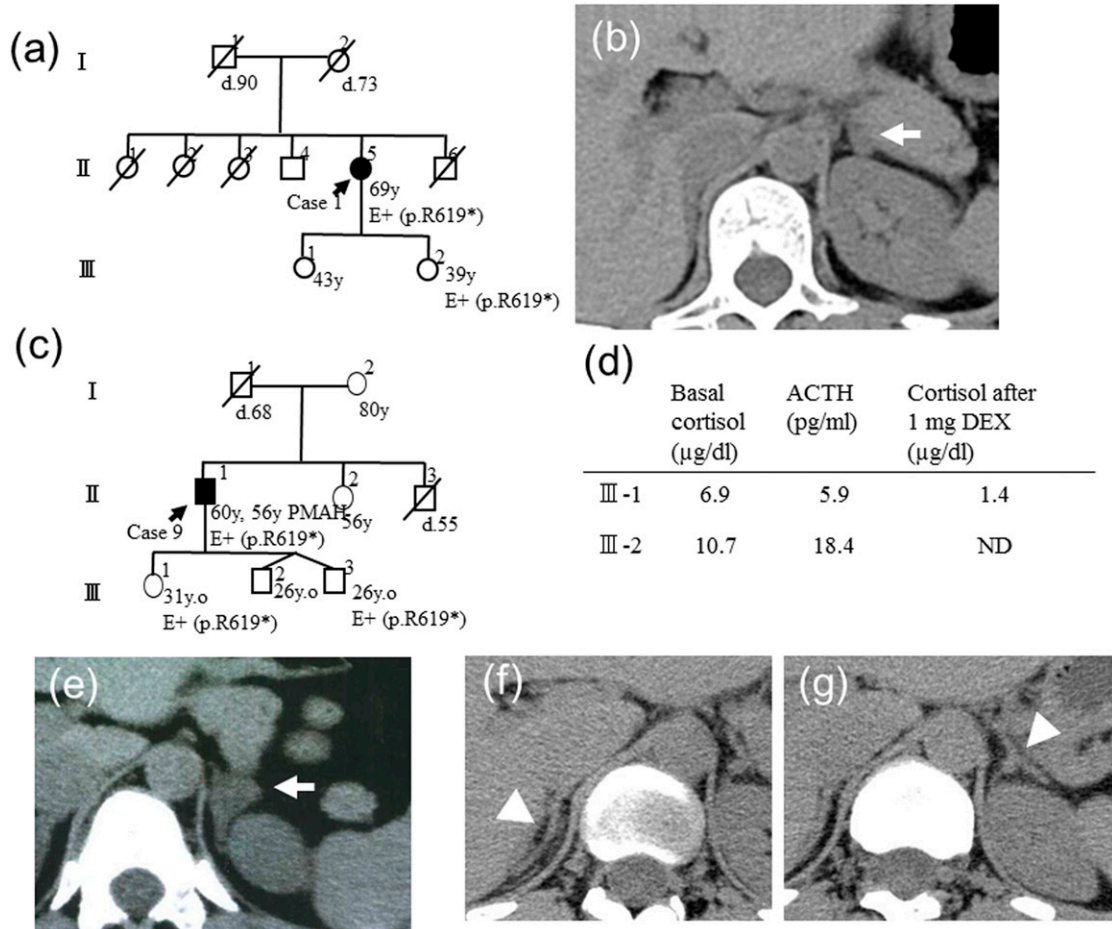


Figure 1. The genotype-phenotype relationship of the family members of cases 1 and 4. (a) The pedigree of case 1. (b) III-2 had p.R619* and showed a small adrenal nodule on the left adrenal gland. (c) The pedigree of case 4. The *ARMC5* genotypes of III-1 and III-3 were analyzed, and p.R619* was found in both individuals. (d) The clinical data of III-1 and III-2 are shown. The imaging findings of (e) III-1 and (f) III-3 right adrenal gland and (g) left adrenal gland are shown. The arrows indicate the nodule or enlarged adrenal gland. The arrowheads indicate the normal adrenal glands.

who had nonadrenal tumors (cases 1 and 5, breast cancer; case 7, parathyroid tumor; case 9, thyroid cancer; and case 10, thyroid adenoma) (data not shown).

D. Endocrinological Characteristics of *ARMC5* Pathogenic or Likely Pathogenic Variants

The *ARMC5* pathogenic or likely pathogenic variant–positive group showed significantly higher basal cortisol and lower serum ACTH levels compared with the *ARMC5* variant–negative group [Fig. 2(a), 2(b)]. Both late-night cortisol and cortisol after 1 mg DEX administration were higher in the *ARMC5* pathogenic or likely variant–positive group but with no statistical significance [Fig. 2(c), 2(d)].

E. Correlations Between Age and Endocrinological Profiles of Patients With *ARMC5* Pathogenic or Likely Pathogenic Variants

Figure 3 shows the results of morning basal cortisol level, morning ACTH level, late-night cortisol level, and cortisol level after 1 mg DEX (d) by age of the patients in the *ARMC5* pathogenic or likely pathogenic variant–positive group. The late-night cortisol level and cortisol level after dexamethasone administration were positively correlated with patient age

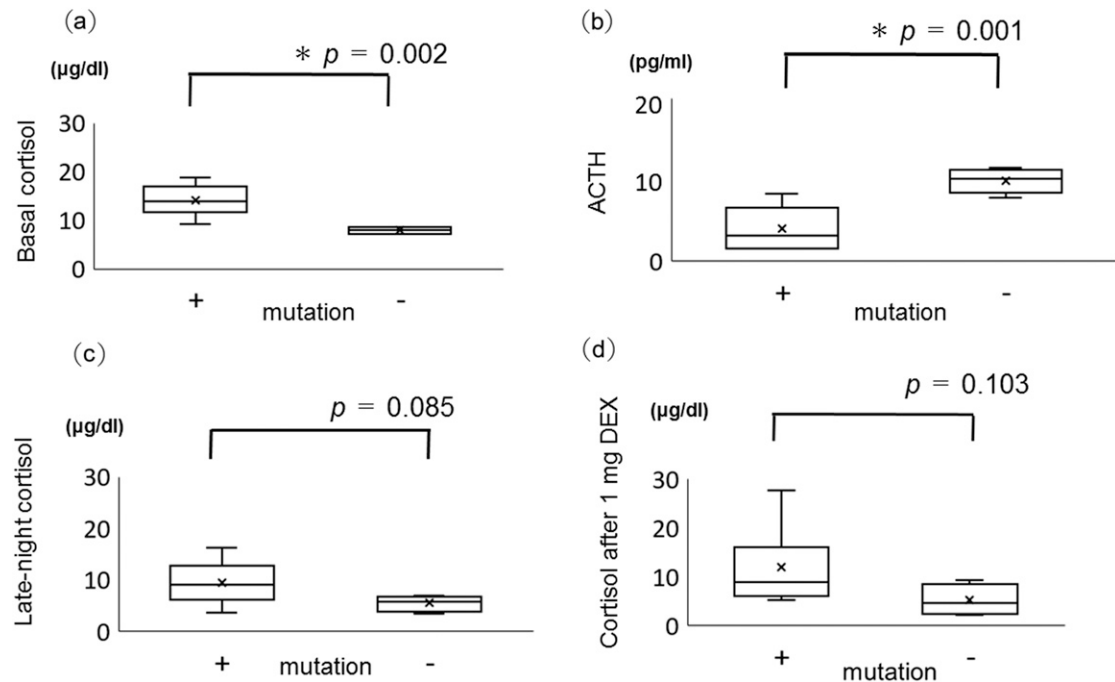


Figure 2. (a) Basal cortisol level, (b) plasma ACTH level, (c) late-night cortisol level, and (d) cortisol level after 1 mg DEX in *ARMC5* pathogenic or likely pathogenic variant–positive patients (+) and negative patients (–). Box plots show median (interior line), minimum and maximum (whiskers), and average (x). * $P < 0.05$.

[Fig. 3(c), 3(d)]. The basal cortisol level showed an age-dependent increase, and the ACTH level tended to decrease in an age-dependent manner, but both were not significant [Fig. 3(a), 3(b)].

Discussion

In the current study, the prevalence of *ARMC5* pathogenic or likely pathogenic variants was detected in 10 of 14 (71%) of all studied patients and 9 of 13 (69%) in patients with apparently sporadic PMAH. Although this case study included a small sample, the frequency of variant-positive patients with PMAH was higher than that in previous reports [14, 15, 17–19, 36]. *ARMC5* gene alteration might play a major role in the pathogenicity of PMAH in the Japanese population. We identified two *ARMC5* variants, p.R362Q and p.G143Sfs*8. The p.R362Q variant was in the sixth ARM-repeat domain and was judged as likely pathogenic. The p.G143Sfs*8 variant was in the first ARM-repeat domain and was judged as pathogenic. These variants might be responsible for the PMAH phenotype in each patient and suggest a wider spectrum of variants in the *ARMC5* gene. c.1855C>T (p.R619*) was identified in five unrelated PMAH probands from distinct regions in Japan, suggesting that p.R619* might be a hot spot in Japanese patients with PMAH.

In this study, we described asymptomatic or presymptomatic *ARMC5* pathogenic variants in the offsprings of cases 1 and 9. Two out of three offspring, aged 39 and 31, showed a putative early stage of an adrenal lesion of PMAH in the imaging study, although they did not show autonomous cortisol secretion. One family member with an *ARMC5* pathogenic variant, who did not show adrenal enlargement in the imaging study, was younger than the above two offspring, at the age of 26. It might be that *ARMC5* variant carriers develop the clinical phenotype in an age-dependent manner [37]. In addition, these findings suggest that morphological changes in the adrenal glands might proceed to endocrinological alterations in *ARMC5* pathogenic variant carriers. It is well known that in some families, there is a high

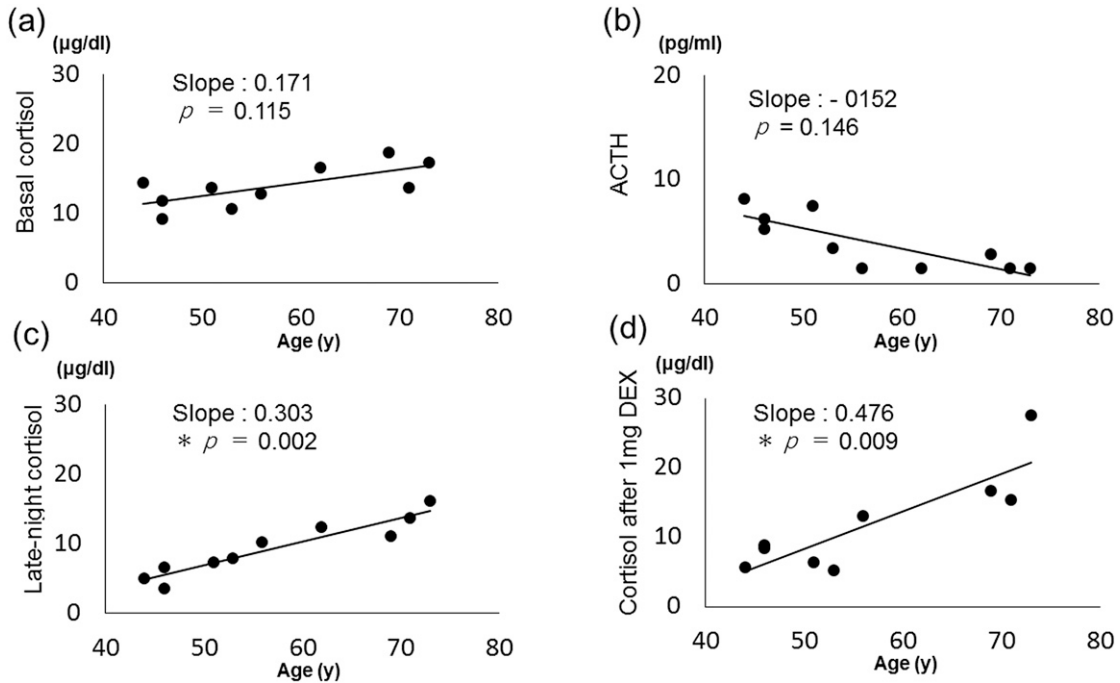


Figure 3. Correlations of age with (a) basal cortisol level, (b) plasma ACTH, (c) late-night cortisol level, and (d) cortisol level after 1 mg DEX in *ARMC5* pathogenic or likely pathogenic variant-positive patients. * $P < 0.05$.

penetrance of the PMAH phenotype [38–40]. However, the majority of patients with PMAH usually do not reveal a family history of the disease, as in this study. The penetrance of *ARMC5* pathogenic variants has not been clarified. Close and continuous clinical examination including imaging studies might increase the detected frequency of familial PMAH, because the diagnosis is based on endocrinological and imaging studies, which are not routinely carried out in the family members of patients with PMAH. A follow-up study of these patients might give us useful information on this issue.

Because the *ARMC5* gene is regarded as a tumor suppressor gene, a second hit is necessary for tumorigenesis in adrenal nodule formation [14]. The *ARMC5* variants were also demonstrated in extra-adrenal tumors, such as meningioma. Therefore, *ARMC5* pathogenic variants cause genetically defined multiorgan tumors [23]. In the current study, 50% of patients who had *ARMC5* pathogenic or likely pathogenic variants had accompanying nonadrenal tumors, such as breast cancer, thyroid cancer, parathyroid tumor, and thyroid adenoma, suggesting a role of *ARMC5* gene alteration in these nonadrenal tumorigenesis. However, neither LOH nor a second hit of the *ARMC5* gene was evident in this study. The role of *ARMC5* gene alteration in nonadrenal neoplasms was not clarified in this study. Promoter and intron domains and the copy number of the *ARMC5* gene were not examined, so the second hit may have been missed by methodological problems. Furthermore, haploinsufficiency was not completely ruled out in these tumors [25, 41, 42].

The basal cortisol levels were significantly higher in the *ARMC5* pathogenic or likely pathogenic variant group than in the nonvariant group. In contrast, the ACTH levels were significantly lower in the *ARMC5* pathogenic or likely pathogenic variant group than in the nonvariant group. These observations were consistent with previous reports [15, 17]. The late-night cortisol levels and cortisol levels after 1 mg DEX were significantly higher in the older patients in the *ARMC5* pathogenic or likely pathogenic variant group, which was consistent with the phenotype of the knockout mouse [25, 26]. Altogether, these findings suggest that *ARMC5* pathogenic or likely pathogenic variant carriers might be asymptomatic until an older age. The penetrance of *ARMC5*-related PMAH might be underestimated because of the time course of clinical phenotypes and the lack of a survey program for the

family members of the proband. These considerations should be taken into account when investigating the penetrance of *ARMC5* pathogenic variants.

In conclusion, our results suggest that *ARMC5* pathogenic germline variants are common in Japanese patients with PMAH despite the lack of family history. The pathogenic variant carriers develop a putative early stage of PMAH in an age-dependent manner, suggesting a higher penetrance of *ARMC5*-related PMAH than previously estimated. Our results demonstrate the importance of *ARMC5* screening for PMAH family members to detect insidious PMAH.

Acknowledgments

We are grateful to Dr. Eiji Nakatani, Research Support Center, Shizuoka General Hospital, for statistical analysis.

Financial Support: This work is a part of the Medical Research Support Project of the Shizuoka Prefectural Hospital Organization.

Additional Information

Correspondence: Takeshi Usui, MD, PhD, Department of Medical Genetics, Research Support Center, Shizuoka General Hospital, 4-27-1 Kita-andou Aoi-ku, Shizuoka City, 420-8527, Japan. E-mail: takeshi-usui@i.shizuoka-pho.jp.

Disclosure Summary: The authors have nothing to disclose.

Data Availability: All data generated or analyzed during this study are included in this published article or in the data repositories listed in References.

References and Notes

1. Kirschner MA, Powell RD, Jr, Lipsett MB. Cushing's syndrome: nodular cortical hyperplasia of adrenal glands with clinical and pathological features suggesting adrenocortical tumor. *J Clin Endocrinol Metab.* 1964;**24**(10):947–955.
2. Aiba M, Hirayama A, Iri H, Ito Y, Fujimoto Y, Mabuchi G, Murai M, Tazaki H, Maruyama H, Saruta T, Suda T, Demura H. Adrenocorticotrophic hormone-independent bilateral adrenocortical macronodular hyperplasia as a distinct subtype of Cushing's syndrome. Enzyme histochemical and ultrastructural study of four cases with a review of the literature. *Am J Clin Pathol.* 1991;**96**(3):334–340.
3. Lieberman SA, Eccleshall TR, Feldman D. ACTH-independent massive bilateral adrenal disease (AIMBAD): a subtype of Cushing's syndrome with major diagnostic and therapeutic implications. *Eur J Endocrinol.* 1994;**131**(1):67–73.
4. Lacroix A. ACTH-independent macronodular adrenal hyperplasia. *Best Pract Res Clin Endocrinol Metab.* 2009;**23**(2):245–259.
5. Swain JM, Grant CS, Schlinkert RT, Thompson GB, vanHeerden JA, Lloyd RV, Young WF. Corticotropin-independent macronodular adrenal hyperplasia: a clinicopathologic correlation. *Arch Surg.* 1998;**133**(5):541–545, discussion 545–546.
6. Ohashi A, Yamada Y, Sakaguchi K, Inoue T, Kubo M, Fushimi H. A natural history of adrenocorticotropin-independent bilateral adrenal macronodular hyperplasia (AIMAH) from pre-clinical to clinically overt Cushing's syndrome. *Endocr J.* 2001;**48**(6):677–683.
7. Lacroix A, Ndiaye N, Tremblay J, Hamet P. Ectopic and abnormal hormone receptors in adrenal Cushing's syndrome. *Endocr Rev.* 2001;**22**(1):75–110.
8. Vezzosi D, Libé R, Baudry C, Rizk-Rabin M, Horvath A, Levy I, René-Corail F, Ragazzon B, Stratakis CA, Vandecasteele G, Bertherat J. Phosphodiesterase 11A (*PDE11A*) gene defects in patients with ACTH-independent macronodular adrenal hyperplasia (AIMAH): functional variants may contribute to genetic susceptibility of bilateral adrenal tumors. *J Clin Endocrinol Metab.* 2012;**97**(11):E2063–E2069.
9. Fragoso MC, Domenice S, Latronico AC, Martin RM, Pereira MA, Zerbini MC, Lucon AM, Mendonca BB. Cushing's syndrome secondary to adrenocorticotropin-independent macronodular adrenocortical hyperplasia due to activating mutations of *GNAS1* gene. *J Clin Endocrinol Metab.* 2003;**88**(5):2147–2151.
10. Hsiao HP, Kirschner LS, Bourdeau I, Keil MF, Boikos SA, Verma S, Robinson-White AJ, Nesterova M, Lacroix A, Stratakis CA. Clinical and genetic heterogeneity, overlap with other tumor syndromes, and

- atypical glucocorticoid hormone secretion in adrenocorticotropin-independent macronodular adrenal hyperplasia compared with other adrenocortical tumors. *J Clin Endocrinol Metab.* 2009;**94**(8):2930–2937.
11. Yamakita N, Murai T, Ito Y, Miura K, Ikeda T, Miyamoto K, Onami S, Yoshida T. Adrenocorticotropin-independent macronodular adrenocortical hyperplasia associated with multiple colon adenomas/carcinomas which showed a point mutation in the APC gene. *Intern Med.* 1997;**36**(8):536–542.
 12. Matyakhina L, Freedman RJ, Bourdeau I, Wei M-H, Stergiopoulos SG, Chidakel A, Walther M, Abu-Asab M, Tsokos M, Keil M, Toro J, Linehan WM, Stratakis CA. Hereditary leiomyomatosis associated with bilateral, massive, macronodular adrenocortical disease and atypical cushing syndrome: a clinical and molecular genetic investigation. *J Clin Endocrinol Metab.* 2005;**90**(6):3773–3779.
 13. Faillot S, Assié G. Endocrine tumours: the genomics of adrenocortical tumors. *Eur J Endocrinol.* 2016;**174**(6):R249–R265.
 14. Assié G, Libé R, Espiard S, Rizk-Rabin M, Guimier A, Luscap W, Barreau O, Lefèvre L, Sibony M, Guignat L, Rodriguez S, Perlemoine K, René-Corail F, Letourneur F, Trabulsi B, Poussier A, Chabbert-Buffet N, Borson-Chazot F, Groussin L, Bertagna X, Stratakis CA, Ragazzon B, Bertherat J. *ARMC5* mutations in macronodular adrenal hyperplasia with Cushing's syndrome. *N Engl J Med.* 2013;**369**(22):2105–2114.
 15. Albiger NM, Regazzo D, Rubin B, Ferrara AM, Rizzati S, Taschin E, Ceccato F, Arnaldi G, Pecori G, Giraldo F, Stigliano A, Cerquetti L, Grimaldi F, De Menis E, Boscaro M, Iacobone M, Occhi G, Scaroni C. A multicenter experience on the prevalence of *ARMC5* mutations in patients with primary bilateral macronodular adrenal hyperplasia: from genetic characterization to clinical phenotype. *Endocrine.* 2017;**55**(3):959–968.
 16. Alencar GA, Lerario AM, Nishi MY, Mariani BM, Almeida MQ, Tremblay J, Hamet P, Bourdeau I, Zerbini MC, Pereira MA, Gomes GC, Rocha MS, Chambo JL, Lacroix A, Mendonca BB, Fragoso MC. *ARMC5* mutations are a frequent cause of primary macronodular adrenal hyperplasia. *J Clin Endocrinol Metab.* 2014;**99**(8):E1501–E1509.
 17. Espiard S, Drougat L, Libé R, Assié G, Perlemoine K, Guignat L, Barrande G, Brucker-Davis F, Doullay F, Lopez S, Sonnet E, Torremocha F, Pinsard D, Chabbert-Buffet N, Raffin-Sanson ML, Groussin L, Borson-Chazot F, Coste J, Bertagna X, Stratakis CA, Beuschlein F, Ragazzon B, Bertherat J. *ARMC5* mutations in a large cohort of primary macronodular adrenal hyperplasia: clinical and functional consequences. *J Clin Endocrinol Metab.* 2015;**100**(6):E926–E935.
 18. Fauz FR, Zilbermint M, Lodish MB, Szarek E, Trivellin G, Sinaii N, Berthon A, Libé R, Assié G, Espiard S, Drougat L, Ragazzon B, Bertherat J, Stratakis CA. Macronodular adrenal hyperplasia due to mutations in an armadillo repeat containing 5 (*ARMC5*) gene: a clinical and genetic investigation. *J Clin Endocrinol Metab.* 2014;**99**(6):E1113–E1119.
 19. Yu L, Zhang J, Guo X, Chen X, He Z, He Q. *ARMC5* mutations in familial and sporadic primary bilateral macronodular adrenal hyperplasia. *PLoS One.* 2018;**13**(1):e0191602.
 20. Bonnet-Serrano F, Bertherat J. Genetics of tumors of the adrenal cortex. *Endocr Relat Cancer.* 2018;**25**(3):R131–R152.
 21. Lodish M, Stratakis CA. A genetic and molecular update on adrenocortical causes of Cushing syndrome. *Nat Rev Endocrinol.* 2016;**12**(5):255–262.
 22. Zhang Q, Cui L, Gao JP, Yan WH, Jin N, Chen K, Zang L, Du J, Wang XL, Guo QH, Yang GQ, Yang LJ, Ba JM, Gu WJ, Lv ZH, Dou JT, Mu YM, Lu JM. Whole-genome sequencing revealed armadillo repeat containing 5 (*ARMC5*) mutation in a Chinese family with ACTH-independent macronodular adrenal hyperplasia. *Endocr J.* 2018;**65**(3):269–279.
 23. Elbelt U, Trovato A, Kloth M, Gentz E, Finke R, Spranger J, Galas D, Weber S, Wolf C, König K, Arlt W, Büttner R, May P, Allolio B, Schneider JG. Molecular and clinical evidence for an *ARMC5* tumor syndrome: concurrent inactivating germline and somatic mutations are associated with both primary macronodular adrenal hyperplasia and meningioma. *J Clin Endocrinol Metab.* 2015;**100**(1):E119–E128.
 24. Berthon A, Fauz F, Bertherat J, Stratakis CA. Analysis of *ARMC5* expression in human tissues. *Mol Cell Endocrinol.* 2017;**441**:140–145.
 25. Berthon A, Fauz FR, Espiard S, Drougat L, Bertherat J, Stratakis CA. Age-dependent effects of *Armc5* haploinsufficiency on adrenocortical function. *Hum Mol Genet.* 2017;**26**(18):3495–3507.
 26. Hu Y, Lao L, Mao J, Jin W, Luo H, Charpentier T, Qi S, Peng J, Hu B, Marcinkiewicz MM, Lamarre A, Wu J. *Armc5* deletion causes developmental defects and compromises T-cell immune responses. *Nat Commun.* 2017;**8**(1):13834.
 27. Nieman LK, Biller BMK, Findling JW, Newell-Price J, Savage MO, Stewart PM, Montori VM. The diagnosis of Cushing's syndrome: an Endocrine Society clinical practice guideline. *J Clin Endocrinol Metab.* 2008;**93**(5):1526–1540.

28. Yanase T, Oki Y, Katabami T, Otsuki M, Kageyama K, Tanaka T, Kawate H, Tanabe M, Doi M, Akehi Y, Ichijo T. New diagnostic criteria of adrenal subclinical Cushing's syndrome: opinion from the Japan Endocrine Society. *Endocr J*. 2018;**65**(4):383–393.
29. RRID:AB_2802131, http://antibodyregistry.org/AB_2802131.
30. RRID:AB_2810257, http://antibodyregistry.org/AB_2810257.
31. RRID:AB_2802133, http://antibodyregistry.org/AB_2802133.
32. RRID:AB_2810227, http://antibodyregistry.org/AB_2810227.
33. RRID:AB_2783634, http://antibodyregistry.org/AB_2783634.
34. RRID:AB_2783635, http://antibodyregistry.org/AB_2783635.
35. Richards S, Aziz N, Bale S, Bick D, Das S, Gastier-Foster J, Grody WW, Hegde M, Lyon E, Spector E, Voelkerding K, Rehm HL; ACMG Laboratory Quality Assurance Committee. Standards and guidelines for the interpretation of sequence variants: a joint consensus recommendation of the American College of Medical Genetics and Genomics and the Association for Molecular Pathology. *Genet Med*. 2015;**17**(5):405–424.
36. Gagliardi L, Schreiber AW, Hahn CN, Feng J, Cranston T, Boon H, Hotu C, Oftedal BE, Cutfield R, Adelson DL, Braund WJ, Gordon RD, Rees DA, Grossman AB, Torpy DJ, Scott HS. *ARMC5* mutations are common in familial bilateral macronodular adrenal hyperplasia. *J Clin Endocrinol Metab*. 2014;**99**(9):E1784–E1792.
37. Emms H, Tsiroiu I, Cranston T, Tsagarakis S, Grossman AB. Do patients with incidentally discovered bilateral adrenal nodules represent an early form of *ARMC5*-mediated bilateral macronodular hyperplasia? *Endocrine*. 2016;**53**(3):801–808.
38. Gagliardi L, Hotu C, Casey G, Braund WJ, Ling KH, Dodd T, Manavis J, Devitt PG, Cutfield R, Rudzki Z, Scott HS, Torpy DJ. Familial vasopressin-sensitive ACTH-independent macronodular adrenal hyperplasia (VPs-AIMAH): clinical studies of three kindreds. *Clin Endocrinol (Oxf)*. 2009;**70**(6):883–891.
39. Suzuki S, Tatsuno I, Oohara E, Nakayama A, Komai E, Shiga A, Kono T, Takiguchi T, Higuchi S, Sakuma I, Nagano H, Hashimoto N, Mayama T, Koide H, Sasano H, Nakatani Y, Imamoto T, Ichikawa T, Yokote K, Tanaka T. Germline deletion of *Armc5* in familial primary macronodular adrenal hyperplasia. *Endocr Pract*. 2015;**21**(10):1152–1160.
40. Zhu J, Cui L, Wang W, Hang XY, Xu AX, Yang SX, Dou JT, Mu YM, Zhang X, Gao JP. Whole exome sequencing identifies mutation of *EDNRA* involved in ACTH-independent macronodular adrenal hyperplasia. *Fam Cancer*. 2013;**12**(4):657–667.
41. Correa R, Zilbermint M, Berthon A, Espiard S, Batsis M, Papadakis GZ, Xekouki P, Lodish MB, Bertherat J, Faucz FR, Stratakis CA. The *ARMC5* gene shows extensive genetic variance in primary macronodular adrenocortical hyperplasia. *Eur J Endocrinol*. 2015;**173**(4):435–440.
42. Paige AJ. Redefining tumour suppressor genes: exceptions to the two-hit hypothesis. *Cell Mol Life Sci*. 2003;**60**(10):2147–2163.