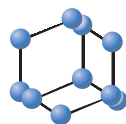



REVIEW ARTICLE


**BENTHAM
SCIENCE**

Chronic Urticaria: An Overview of Treatment and Recent Patents


 Kam L. Hon^{1,*}, Alexander K.C. Leung², Wing G.G. Ng² and Steven K. Loo³

¹Department of Paediatrics, The Chinese University of Hong Kong, Shatin, Hong Kong; ²Department of Pediatrics, The University of Calgary, Alberta Children's Hospital, Calgary, Alberta, Canada; ³The Institute of Integrative Medicine, The Chinese University of Hong Kong, Shatin, Hong Kong

Abstract: Background: Up to 1% of the general population in the USA and Europe suffer from chronic urticaria (CU) at some point in their lifetime. CU has an adverse effect on the quality of life.

Objective: This study aims to provide an update on the epidemiology, pathogenesis, clinical manifestations, diagnosis, aggravating factors, complications, treatment and prognosis of CU.

Methods: The search strategy included meta-analyses, randomized controlled trials, clinical trials, reviews and pertinent references. Patents were searched using the key term "chronic urticaria" at the following links: www.google.com/patents, www.uspto.gov, and www.freepatentsonline.com.

Results: CU is a clinical diagnosis, based on the episodic appearance of characteristic urticarial lesions that wax and wane rapidly, with or without angioedema, on most days of the week, for a period of six weeks or longer. Triggers such as medications, physical stimuli, and stress can be identified in 10 to 20% of cases. C-reactive protein/erythrocyte sedimentation rate, and complete blood cell count with differential are the screening tests that may be used to rule out an underlying disorder. The mainstay of therapy is reassurance, patient education, avoidance of known triggers, and pharmacotherapy. Second-generation H1 antihistamines are the drugs of choice for initial therapy because of their safety and efficacy profile. If satisfactory improvement does not occur after 2 to 4 weeks or earlier if the symptoms are intolerable, the dose of second-generation H1 antihistamines can be increased up to fourfold the manufacturer's recommended dose (all be it off license). If satisfactory improvement does not occur after 2 to 4 weeks or earlier if the symptoms are intolerable after the fourfold increase in the dosage of second-generation H1 antihistamines, omalizumab should be added. If satisfactory improvement does not occur after 6 months or earlier if the symptoms are intolerable after omalizumab has been added, treatment with cyclosporine and second-generation H1 antihistamines is recommended. Short-term use of systemic corticosteroids may be considered for acute exacerbation of CU and in refractory cases. Recent patents for the management of chronic urticaria are also discussed. Complications of CU may include skin excoriations, adverse effect on quality of life, anxiety, depression, and considerable humanistic and economic impacts. On average, the duration of CU is around two to five years. Disease severity has an association with disease duration.

Conclusion: CU is idiopathic in the majority of cases. On average, the duration of CU is around two to five years. Treatment is primarily symptomatic with second generation antihistamines being the first line. Omalizumab has been a remarkable advancement in the management of CU and improves the quality of life beyond symptom control.

Keywords: Angioedema, antihistamines, hives, immunomodulators, pruritus, vasculitis, wheals.

1. INTRODUCTION

Urticaria (also called hives, wheals, or nettle rash) is characterized by pruritic, erythematous, and edematous wheals [1-10]. The hallmark of urticaria is that individual

lesions wax and wane rapidly, usually lasting less than 4 hours [8, 9]. In clinical practice, it is important to ascertain whether lesions last less or more than 24 hours as this increases the likelihood of urticarial vasculitis. Urticaria can be classified as acute or chronic. Chronic Urticaria (CU) conventionally refers to recurrent wheals, on most days of the week, which occur for a period of \geq six weeks. CU can be further divided into two different subtypes, namely, chronic idiopathic urticaria (also called chronic spontaneous urti-

*Address correspondence to this author at the Department of Paediatrics, The Chinese University of Hong Kong, 6/F, Clinical Sciences Building, Prince of Wales Hospital, Shatin, Hong Kong; Tel: (852) 3505 2982; Fax: (852) 2636 0020; E-mail: ehon@hotmail.com

ARTICLE HISTORY

Received: October 29, 2018
Revised: March 19, 2019
Accepted: March 19, 2019

DOI:
10.2174/1872213X13666190328164931



caria) and chronic inducible urticaria (also called physical urticaria) [10, 11]. In most patients, CU is a sporadic and self-limited disorder [12]. Treatment is mainly symptomatic. Other than second-generation H1 antihistamines which form the first line of treatment, many other medications for the treatment of CU have been described [1]. This paper reviews the epidemiology, pathogenesis, aggravating factors, clinical manifestations, treatment, and prognosis of CU. Recent patents related to the management of CU are also discussed.

2. EPIDEMIOLOGY

CU affects up to 1% of the general population in the USA and Europe at some point in their lifetime [2, 13-15]. Both children and adults can develop CU though the condition is more common in adults [1]. A population-based study in Korea reported that the crude prevalence of CU was 2,256.5 per 100,000 person-years and the prevalence increased every year between 2010 and 2014 [16]. A hospital-based study in Korea showed that the prevalence of CU in children is approximately 1.8%, which appears to be similar to that in adults [17]. However, a lower prevalence of angioedema is observed among the pediatric populations [17, 18]. Atopy is, however, more prevalent in children (58%) than in adults (23%) ($p < 0.05$) [1]. There is evidence that CU is strongly associated with autoimmunity with a similar prevalence in adults and children [1, 19-21].

CU typically begins in the third to fifth decade of life [12, 13, 22]. The female to male ratio is approximately 2:1 [1-3, 12-14, 22, 23]. In a multicenter epidemiologic survey conducted in China, female preponderance was not observed in patients < 20 years of age [24]. Data from Korea showed an age peak at 0 to 9 years in addition to the usual age peak at an older age range [17, 25]. In most studies, the peak age of CU occurrence is between 20 and 40 years [26].

3. PATHOGENESIS

CU can be idiopathic or inducible. Chronic idiopathic urticaria accounts for as many as 80 to 90% of adults and children with CU. Lesions in patients with chronic idiopathic urticaria occur spontaneously, without physical or environmental stimuli [1, 19, 27]. Chronic inducible urticaria is less common and requires specific triggers which can be medications, physical stimuli or stress for the urticaria to occur [28].

It is not uncommon for chronic idiopathic urticaria and chronic inducible urticaria to coexist in the same patient [11, 28].

CU can also be a manifestation of an auto-immune or an auto-inflammatory disease and be distinguished from urticarial vasculitis [1, 19, 20, 21, 29].

4. AGGRAVATING FACTORS AND ASSOCIATED DISORDERS

Triggering factors for chronic inducible urticaria include physical stimuli, stress, and anti-inflammatory medications [8, 9, 30]. Physical stimuli such as heat (heat urticaria), cold (cold urticaria), extreme humidity, pressure (pressure urticaria, also called delayed pressure urticaria), exercise (exercise-induced urticaria), sweating (cholinergic urticaria), vibration (vibratory urticaria), water (aquagenic urticaria), and

sunlight (solar urticaria) are common triggering factors [31]. Stress is another common aggravating factor. Patients often report more severe symptoms during times of psychological stress [32-34]. Drugs such as Non-Steroidal Anti-Inflammatory Drugs (NSAIDs) and beta-lactams are well-known triggers [35]. NSAIDs may aggravate the skin lesions in up to 25 to 50% of patients with CU [36]. Ingestion of food (notably peanuts, eggs, chocolate), hot and spicy food, alcoholic beverages etc. may aggravate the skin lesions in some patients [8, 9, 37].

Autoimmune disorders such as hypothyroidism, hyperthyroidism, celiac disease, Sjögren syndrome, systemic lupus erythematosus, rheumatoid arthritis, and type 1 diabetes mellitus are more commonly seen in patients with CU [14, 22, 38]. In a recent cross-sectional study of 11,271 patients with CU, CU was significantly associated with irritable colon syndrome (odds ratio: 1.86; 95% confidence interval: 1.47 to 2.19; $p < .001$) [39]. The authors speculated that mast cells may have a role in the coexistence of these two conditions. The association of CU with malignancy is less clear as data have been conflicting [40].

Urticaria can be a manifestation in auto-inflammatory syndromes such as Cryopyrin-Associated Periodic Syndrome (CAPS) [41, 42]. CAPS is a rare hereditary inflammatory disorder encompassing a continuum of three phenotypes: Familial Cold Autoinflammatory Syndrome (FCAS), Muckle-Wells Syndrome (MWS), and Neonatal-Onset Multisystem Inflammatory Disease [NOMID, also known as Chronic Infantile Neurologic Cutaneous and Articular syndrome (CINCA)]. FCAS is the mildest phenotype, characterized by recurrent urticaria, arthralgia, and fever after a general exposure to cold [43-45]. MWS is the intermediate phenotype caused by genetic mutations on the NLRP3 (CIAS1) gene that encodes the cryopyrin protein [46]. The NLRP3 mutation is autosomal dominant. Chronic, recurrent, generally non-pruritic (not itchy) urticaria is usually present during early infancy but occasionally starts in early childhood. Inflammation can occur spontaneously without an apparent provocation or result from triggers such as cold, stress, or exercise. MWS is characterized by renal amyloidosis, sensorineural hearing loss, and conjunctivitis [46]. The most severe is NOMID [Syndrome for diagnosis: dwarfing, persistently open fontanelle; recurrent meningitis; recurrent subdural effusions with temporary alternate-sided hemiplegia; high-tone deafness; visual defect with pseudo papilledema; slowing intellectual development; recurrent acute polyarthritis; erythema marginatum, splenomegaly and iron-resistant hypochromic anemia]. The hallmark of NOMID is the neonatal onset of cutaneous symptoms along with an end-organ damage. These include the "triad" of arthropathy, chronic urticaria, and Central Nervous System (CNS) involvement [47, 48]. NOMID more commonly results from *de novo* mutations. Schnitzler syndrome is a late-onset acquired autoinflammatory syndrome, in which, the cytokine IL-1 plays a crucial role. IL-1 blocking therapies are efficient for the inflammation-linked symptoms but not for the monoclonal component [49, 50].

5. PATHOPHYSIOLOGY

The wheal and angioedema associated with CU are caused by active and degranulating mast cells with the re-

lease of histamine, bradykinin, prostaglandins, leukotrienes, eosinophil and neutrophilic chemotactic factors, platelet-activating factor, and cytokines. The mast cell mediators lead to vasodilation and an increase in vascular permeability with the resultant formation of urticaria. Autoimmunity plays a major role and is the main underlying mechanism. Chronic idiopathic urticaria can be caused either by IgE autoantibodies against auto-allergens or IgG autoantibodies directed against the mast cells high-affinity receptor Fc-epsilon-RI and/or IgE [11, 28]. The concept of autoimmunity originated from the observation that thyroid disorders and thyroid autoantibodies are more prevalent in CU patients [4, 5, 14, 20, 51-53]. It has been shown that approximately 50% of patients with CU have autoantibodies directed against the subunit of the receptor of IgE or IgE itself, leading to the degranulation of mast cells [31]. Autoantibodies, especially mast cell-activating autoantibodies, can be found in a significant number of patients with CU [54].

Interleukin 3 (IL-3) is also relevant to the pathogenesis of urticaria. There is evidence suggesting the upregulation of IL-3 and TNF-alpha expression in lesional and uninvolved skin in different types of urticaria [55, 56]. Cytokines are involved in the pathology of urticaria, possibly by inducing subthreshold inflammation in endothelial cells of uninvolved skin. Activated status of basophils in chronic urticaria leads to the IL-3 hyper-responsiveness and the enhancement of histamine release induced by anti-IgE stimulus [56].

6. CLINICAL MANIFESTATIONS

CU typically presents with edematous wheals that are raised and circumscribed [1, 10]. Lesions range from a few millimeters to several centimeters in diameters [1]. They are usually round or annular but may be serpiginous. Larger plaques may occur if the lesions coalesce together. Lesions may appear flattened rather than raised if the patient is currently taking H1 antihistamines [1]. Although any part of the body may be affected, those areas subjected to pressure and rubbing (e.g., axillae) are more commonly affected.

Wheals of CU usually last 30 minutes to 24 hours and resolve without residual marks [1]. Pruritus is the most predominant symptom and lesions can be intensely pruritic [57]. Many patients report worsening of the itch at nighttime [1]. Lesions of urticaria may also be pricking or burning in nature.

Approximately 40 to 50% of CU patients have accompanied angioedema [58]. Wheals and angioedema commonly occur together, but may also occur at different times [37]. Angioedema refers to transient, episodic submucosal or subcutaneous, nonpitting and less well-defined edema which normally lasts less than 24 hours [8, 9]. Rather than being pruritic, the affected sites are more likely to have a numb or tingling sensation and, at times, pain. They are usually asymmetric in distribution and commonly affected areas include lips, periorbital areas, cheeks, extremities, and genitals [1, 9].

Wheals in patients with physical urticaria (not including delayed pressure urticaria) usually occur within 15 minutes after the stimulus and last for less than 2 hours [1]. The lesions are edematous and erythematous. Some patients may

exhibit dermographism (also called dermatographia) which is a phenomenon whereby stroking the skin with a firm object results in a linear wheal-and-flare response following the site of the pressure [59].

A subset of CU patients might have systemic symptoms such as fatigue, headache, arthralgias/arthritis, flushing, wheezing, palpitations, nausea, and abdominal pain [33, 60]. In a survey of 155 patients with concomitant hives, joint pain or swelling (55.3%), headache/fatigue (47.6%), flushing (42.7%), wheezing (30.1%), gastrointestinal complaints (26.2%), and palpitations (9.7%) were reported [3]. This subgroup of patients tend to have a more severe and long-lasting disease [1, 22].

7. DIAGNOSIS

Most cases of CU can be diagnosed clinically following a detailed history (duration of episodic and transient wheals for a period of six weeks or longer, use of medications, physical stimuli) and careful physical examination (characteristic erythematous, edematous wheals that wax and wane rapidly, with or without accompanying angioedema) [19, 38, 61]. Usually, no cause can be identified in 80 to 90% of patients with CU [15, 21, 62, 63]. Inducible physical CU can be confirmed by tests (e.g. cold ice cube test for cold urticaria) [64]. The differential diagnoses of urticarial vasculitis, as well as auto-immune and auto-inflammatory associated urticaria need careful consideration in clinical and laboratory investigations [65].

8. LABORATORY INVESTIGATIONS

C- Reactive protein/erythrocyte sedimentation rate, and complete blood cell count with differential are screening tests that may be used to rule out an underlying disorder [10, 11, 66, 67]. CU patients usually have normal complete blood cell count result. A high eosinophil count suggests atopy or parasitic infestation. Significant elevations in C- reactive protein/erythrocyte sedimentation rate suggest an underlying systemic disease such as autoimmune, rheumatologic, infectious, or neoplastic disease [68, 69]. An abnormal serum thyroid stimulating hormone (TSH) level is suggestive of a thyroid disease. Serum complement levels should be ordered if urticarial vasculitis is suspected as affected patients often have decreased C1, C1q, C2, C3, and/or C4 levels.

Further investigational laboratory tests include the autologous serum skin test, tests of basophil activation, and tests for autoantibodies to the IgE receptor or the Fc region of IgE [70].

Blood levels of IgG-anti-FcεRI, IgG anti-IGE, total IgE, IgE anti-self and other autoantibodies, and autologous serum skin testing are important [71-74]. There are recent data linking low basophil counts with more rapid resolution in children [75]. The clinical history should guide the need for additional tests, given the link to coeliac disease, rheumatoid arthritis and diabetes [76]. However, results of these tests usually do not affect the management of CU [1, 27].

Skin biopsy is not routinely needed for the diagnosis of CU. Nevertheless, a lesional skin biopsy of a newly formed wheal (preferably < 24hours) should be performed and submitted for Hematoxylin and Eosin (H & E) staining and im-

munofluorescence if urticarial vasculitis is suspected. Histological findings in early lesions show a perivascular neutrophilic infiltrate involving postcapillary venules with fibrin deposition and extravasation of red blood cells. Eosinophils may be noted early. Immunofluorescence may show deposition of complement and fibrin in the blood vessels and, occasionally, immunoglobulin M, immunoglobulin G, and immunoglobulin A along the basement membrane zone of the skin [1].

9. COMPLICATIONS

Excoriations of the skin may result from vigorous scratching. CU has an adverse effect on the quality of life such as disruptions of sleep and daily activities [1, 10, 18, 26, 77]. The condition is often associated with anxiety and depression disorders [28]. In addition, CU has considerable humanistic and economic impacts [1, 10, 18, 26, 77].

10. PROGNOSIS

On average, the duration of CU is around two to five years [6, 7, 32, 78, 79]. Studies have shown that spontaneous remission occurs in 17%, 39%, and 67% of children with CU after 1, 3, and 5 years, respectively [30, 80]. While remission rate at one year in children might be higher [81], it is about 30 to 50% for adult CU patients who do not have an identified triggering factor or underlying disorder [21]. Prospective studies have shown that disease severity has an association with disease duration; that is, the more severe disease tends to last longer [78]. A recent study showed that children with CU who had basophil-activating serum activity and low blood basophil counts had earlier disease resolution than their counterparts [82].

Disease management for CU may affect its prognosis. In a retrospective study, it was found that the remission rate was considerably longer in those affected patients who were not taking a standard dose of oral antihistamine for disease control [82]. The co-existing disease may also have an effect on prognosis. A prospective study of 228 patients with moderate to severe CU showed that those with systemic hypertension tended to have more persistent symptoms and a significantly lower resolution rate [83]. Moreover, the comorbidity of inducible urticaria and concomitant recurrent angio-edema may also be linked to longer CU duration [84]. All the patients should have a blood pressure measurement as this can affect prognosis, and also undergo an assessment of the QoL. Urticaria is a common disease with marked effects on the QoL [85, 86]. Hence, the use of disease-modifying and costly medications such as omalizumab may be justified [87, 88].

11. TREATMENT

Urticaria is alarming for patients as it is often acute at the time of onset and can affect large areas of the skin. Patients need reassurance and education. The mainstay of therapy is the avoidance of known triggers and pharmacotherapy [6, 7, 32, 37, 38, 88]. The majority of individuals with CU have no identifiable triggers, thereby making avoidance impractical [58]. Its treatment is mainly symptomatic [19, 59, 89]. According to the 2014 American practice parameters, the pharmacological treatment involves a stepwise approach [59].

Based on the consensus between American, UK and European guidelines published between 2014 and 2018, principles on the management of CU are essentially similar with patient education, trigger avoidance, first and second-generation antihistamines, immunomodulating drugs and biologics [10, 37, 70, 80, 89]. The up-titration of antihistamines is a guideline recommendation, however, not a licensed use [10, 37, 80, 89]. The age at which each medication is licensed in the USA, UK and Europe varies [6, 90]. One report specifically mentions the cut-off age of 12 years to differentiate children from adults [91].

Omalizumab, a monoclonal antibody against IgE, has been proven to be an effective and safe agent for the treatment of patients ≥ 12 years whose CU is refractory to higher dose H1 receptor blocking antihistamines [92, 93].

11.1. Stepwise Approach

Step 1 consists of monotherapy with a second-generation H1 receptor blocking antihistamine [10, 59]. Second-generation H1 receptor blocking antihistamines selectively antagonize the peripheral H1 receptors and are less sedating and less anticholinergic [80]. They are preferred over the first-generation antihistamines which have adverse effects of sedation and anticholinergic effects [10]. Second-generation H1 antihistamines are the drugs of choice for initial therapy because of their safety and efficacy profile [94-96]. Examples of second-generation H1 antihistamines are loratadine (Claritin, Claratyne), desloratadine (Aerius, Clarinex, Dasselta, Desloridis) cetirizine (Zyrtec), levocetirizine (Xyzal), azelastine (Allergodil, Astelin, Optivar), bilastine (Bilaxten), and fexofenadine (Allegra) [94-96].

The EAACI/GA²LEN/EDF/WAO guidelines strongly support the use of second-generation H1-antihistamines for CU [89]. In children, several studies regarding the safety and efficacy of cetirizine, levocetirizine, loratadine, fexofenadine, desloratadine, and rupatadine have been performed [90]. The regular dosage of second-generation H1-antihistamines could be increased up to 2-4 times if symptoms are not resolved or improved within the first 2-4 weeks of treatment; if there is still no improvement, another H1-antihistamine could be tried [97, 98]. A few studies performed in children with CU have shown that around 35-38% of these patients required double doses of second-generation H1-antihistamines, while only 6% and 5% needed triple or quadruple dosage, respectively. Interestingly, younger children seemed to respond better to regular doses, while older children required higher doses to achieve resolution of their symptoms [97, 99]. Some authors recommended adding an H2-antihistamine (cimetidine, ranitidine) for patients who still have not been able to achieve complete remission of their symptoms [100].

Step 2. For those patients whose symptoms are not adequately controlled within one to two weeks, step 2 may have to be initiated. Step 2 consists of one or more of the following treatment options: Increasing the dose of the current second-generation H1 antihistamine (up to four times the manufacturer's recommended dose), adding another second-generation H1 antihistamine, adding an H2 receptor blocking antihistamine such as ranitidine (Zantac) or famotidine (Pepcid), adding a leukotriene receptor antagonist such as montelukast (Singulair) or zafirlukast (Accolate), and/or adding a

Table 1. Treatments for Chronic Urticaria [89, 97, 98].

Step 1	➤ Establish a diagnosis. Reassurance, patient education, avoidance of known triggers	[10, 89, 97, 98]
	➤ Second-generation H1 antihistamines	
Step 2	➤ Optimize dosages of second-generation H1 antihistamines	[10, 11, 89, 97, 98]
	➤ Adding another second-generation H1 antihistamine, or a leukotriene receptor antagonist such as montelukast	
Step 3	➤ Increase the dose of potent first-generation H1 antihistamines such as or doxepin and hydroxyzine and titrating the dose as tolerated	[10, 11, 89, 97]
	➤ Any medications that did not seem to work should be discontinued	
Step 4	➤ Omalizumab, cyclosporin, corticosteroid, etc.	[10, 28, 89, 97, 98]
	➤ Once CU is controlled, “step-down” in treatment is recommended	
	➤ Second-generation H1 antihistamines may be withdrawn periodically to identify spontaneous remission of the disease	
	➤ CU should be treated until spontaneous remission occurs	

Current and future potential treatments for chronic urticaria.

first-generation H1 antihistamines such as doxepin (Sinequan), hydroxyzine (Atarax, Vistaril), chlorpheniramine (Piriton, Chlor-Trimeton), or diphenhydramine (Benadryl, Unisom, Somnex) [59, 80]. Montelukast and zafirlukast block leukotriene receptors and can be used in isolation or as an add on treatment for patients with CU. These medications may be more efficacious for patients with NSAID-induced CU [7, 101, 102].

LTRAs have been used successfully in children with asthma or other allergic diseases but not pediatric CU. A recent systematic review on adult patients showed most trials indicating that leukotriene antagonists are not superior to placebo or antihistamine therapy, while combination therapy of leukotriene antagonist and antihistamines appeared to be more efficacious compared to antihistamine alone. The side effect profile and tolerability of leukotriene antagonist are acceptable. The use of leukotriene antagonist as a monotherapy cannot be recommended [103].

Step 3. For patients whose symptoms are not adequately controlled in spite of the measures taken in step 2, step 3 may need to be followed. Step 3 consists of increasing the dose of potent first-generation H1 antihistamines such as doxepin and hydroxyzine and titrating the dose as tolerated.

First-generation H1 antihistamines block both central and peripheral H1 receptors. They have similar efficacy as second-generation H1 antihistamines but adverse effects associated with their use such as drowsiness, sedation, daytime somnolence, and impaired concentration which make them less favorable [11]. Any medications used in step 2 that did not seem to work should be discontinued.

These are no longer recommended in children due to undesired side effects of sedation, impairment of alertness and cognition [104]. However, some authors have reported the efficacy and safety of ketotifen (a non-competitive H1-antihistamine and mast-cell stabilizer) in patients with CU [105].

Step 4. For patients whose symptoms are not adequately controlled in spite of the measures taken in step 3 (refractory

CU), step 4 may need to be followed. Medications used in step 4 include anti-inflammatory medications such as dapsone (Aczone), hydroxychloroquine (Plaquenil), or sulfasalazine (Salazopyrin, Sulazine, Azulfidine), leukotriene receptor antagonists such as montelukast or zafirlukast, systemic glucocorticoids, immunosuppressants such as cyclosporine (Neoral, Sandimmune), tacrolimus (Prograf, Advagraf), mycophenolate (cellCept, Myfortic), or sirolimus (Rapamune) and a biologic agent such as omalizumab (Xolair) [7, 95, 106] (Table 1).

A meta-analysis of randomized clinical trials in 2016 provides high-quality evidence for the efficacy and safety of omalizumab in patients with CSU and for treating these patients with 300mg of omalizumab every 4 weeks [107]. Overall, omalizumab seems to be safe with few side effects reported (mainly mild skin reactions at the injection site and, in rare cases, anaphylaxis), but its high cost has limited its use [90, 91, 108, 109].

The 2018 version of the evidence- and consensus-based guideline developed by the European Academy of Allergology and Clinical Immunology (EAACI), the EU-founded network of excellence, the Global Allergy and Asthma European Network (GA²LEN), the European Dermatology Forum (EDF), and the World Allergy Organization (WAO), with the participation of 48 delegates of 42 national and international societies, recommends second-generation H1 antihistamines to be the drug of choice for the management of CU and are preferred over first-generation H1 antihistamines [10].

If sufficient improvement does not occur after 2 to 4 weeks or earlier if the symptoms are intolerable, the dose of second-generation H1 antihistamines can be increased up to fourfold the manufacturer's recommended dose [10]. If sufficient improvement does not occur after 2 to 4 weeks or earlier if the symptoms are intolerable after the fourfold increase in the dosage of second-generation H1 antihistamines, omalizumab should be added [10]. If sufficient improvement does not occur after 6 months or earlier if the

symptoms are intolerable after omalizumab has been added, treatment with cyclosporine and second-generation H1 antihistamines are recommended. Short-term (maximum, 10 days) use of systemic corticosteroids may be considered for acute exacerbation of CU and in refractory cases [58] but the long-term use of systemic corticosteroids is not justified.

Omalizumab is a recombinant DNA-derived humanized monoclonal antibody that binds to the constant region of the IgE molecule, avoiding the interaction between free IgE with high and low-affinity IgE receptors [92, 93]. This leads to a downregulation of high-affinity IgE receptor expression on inflammatory cells [110]. Lately, the interest in omalizumab as a second-line therapy for patients with CU has increased significantly following several studies demonstrating its effectiveness and safety in both adults and children [87]. In children, omalizumab is currently approved for moderate-to-severe uncontrolled allergic asthma and CSU (≥ 12 years) [91-93]. At least 5 doses are necessary to prevent recurrence and obtain complete remission of CU [87]. In phase 3, multi-center, randomized, double-blind study with omalizumab for the treatment of chronic idiopathic or spontaneous urticaria, omalizumab diminished clinical symptoms and signs of chronic idiopathic urticaria in patients who had remained symptomatic despite the use of approved doses of H-antihistamines [70, 111].

Calcineurin inhibitors, such as cyclosporine and tacrolimus are preferred by some authors to treat severe symptoms [112-113]. Cyclosporine has also been used as an adjuvant therapy in the treatment of difficult to control CU [70]. In children, few studies have shown its effectiveness [114]. Doshi and colleagues reported seven patients treated with cyclosporine [115]. All the patients reached cessation of the symptoms within the first 8 weeks of treatment, with no evidence of side effects [115]. Uncommon side effects such as hypertension, nephrotoxicity, headache, nausea, abdominal pain and infections have been reported. A close monitoring of blood pressure, renal function, and cyclosporine levels is recommended [116].

Oral corticosteroids are highly effective in controlling symptoms of CU. However, they have an extensive list of adverse effects [117]. Because of the potential adverse effects, oral corticosteroids should only be used short-term for refractory cases and the lowest effective dose should be used [80]. When a high dose of corticosteroids needs to be given for a prolonged period of time, other immunosuppressants should be considered. Current guidelines advocate that the use of corticosteroids in CU is restricted only for exacerbations and for short periods of time (3-7 days) due to their side effects [89, 90, 104, 118, 119].

There is less evidence to justify the use of sirolimus, mycophenolate mofetil and dapsone; while hydroxychloroquine or sulphasalazine is rarely used [120, 121].

Treatment of the rare auto-inflammatory urticarial syndromes is challenging. Several reports have demonstrated the efficacy of anakinra for urticaria associated with these diseases [122, 123].

Once CU is controlled, a “step-down” in treatment is recommended. When CU can be controlled with second-generation H1 antihistamines alone, it is recommended that

the medication be withdrawn periodically in order to identify spontaneous remission of the disease [28]. CU should be treated until spontaneous remission occurs.

CONCLUSION

CU is a clinical diagnosis, based on the episodic appearance of characteristic urticarial lesions, with or without angioedema, on most days of the week, or for a period of six weeks or longer. No specific cause could be identified in the majority of cases. CU is a sporadic and self-limited disorder. Approximately two-thirds of CU patients resolve within 5 years. However, some may persist for many years, impairing patients' quality of life. Its treatment is primarily symptomatic and involves mainly the use of second-generation H1 antihistamines at diagnosis. If satisfactory improvement does not occur, other treatment options should be considered. Recent patents including newer antihistamine and immunomodulating medications have been reviewed. The efficacy of these medications needs to be subjected to rigorous randomized trials. Omalizumab has been a remarkable advancement in the management of CU which improves the QoL beyond symptom control.

CURRENT & FUTURE DEVELOPMENTS

CU is idiopathic in the majority of cases, and some resolve spontaneously. Treatment is primarily symptomatic. Second-generation non-impairing non-sedating H1-antihistamines are recommended as first-line medications for initial treatment. New effective and safe therapeutic options have emerged for the treatment of patients with CU refractory to the standard dosage of a second-generation non-impairing non-sedating H1-antihistamine. Up-dosing with a second-generation non-impairing non-sedating H1-antihistamine higher than the licensed dosage may be recommended as the second-line treatment. Omalizumab often effectively and safely induces remission in H1-antihistamine-resistant CU and is used as a third-line treatment for this indication. Subcutaneous omalizumab injections at monthly intervals are recommended as a novel effective and safe therapeutic option for CU refractory to the above. Research in progress will help to define some specific aspects of these new approaches and further establish their significance in the treatment algorithm.

There have been no recent patents on newer antihistamines beyond the first and second generation antihistamines [70]. Most of the patents are for Dexamipexole and its enantiomer, pramipexole which are cell depleters. Dexamipexole has already been in phase II trials. Toxicity and adverse effect profile of CU is not yet available. The targeted eosinophil-lowering effects of dexamipexole in clinical studies for amyotrophic lateral sclerosis are significant [124]. All doses tested were well tolerated. The overall adverse event rate was similar for dexamipexole and placebo, and notably with no increase in infection-related adverse events.

Patents for the use of anti-IL-1beta compound Il-3 inhibitors and an NLRP3 inhibitor are discussed. Both the anti-IL-1beta compounds and the NLRP3 are likely to have a role in auto-inflammatory syndromes rather than CU [42, 65, 125-127].

Pertinent European and US patents are described in the following paragraphs.

European Patents

Gram and colleagues disclosed an invention related to the novel use of IL-1 β -ligand/IL-1 receptor disrupting compounds (herein referred to as "IL-1beta Compounds"); such as small molecular compounds disrupting IL-1 β ligand - IL-1 receptor interaction, IL-1 β antibodies or IL-1 receptor antibodies, e.g. IL-1 β binding molecules described herein, antibodies disclosed herein, IL-1 β binding compounds or IL-1 receptor binding compounds, and/or RNA compounds decreasing either IL-1 β ligands or IL-1 receptor protein levels, in the treatment and/or prevention of auto-inflammatory syndromes, and the use of methods of treating and/or preventing auto-inflammatory syndromes in mammals, particularly humans [EP2468302 (2012)] [128].

United States Patents

There have only been few patents contributed for chronic urticarial in recent years.

Vairo *et al.* disclosed a method for the treatment of a chronic inflammatory condition in a patient which comprises administering an agent to the patient of which blocks or inhibits IL-3 signalling events in the patient [US20150017180] [129]. There is no information as to whether further clinical trials are underway. The treatment modality is for a chronic inflammatory condition and not specific for CU.

Bozik *et al.* disclosed methods of treating CU and related conditions in a subject by administering a therapeutically effective amount of dexpramipexole or a pharmaceutically acceptable salt in the subject to treat the condition [US20160193186 (2016)] [130]. In some cases, the levels of mast cells, basophils, eosinophils, or a combination thereof reduced following administration of a therapeutically effective amount of dexpramipexole or a pharmaceutically acceptable salt thereof. Some patients were directed to treatment for a condition characterized by elevated levels of mast cells, basophils, eosinophils, or a combination thereof, comprising administering of a therapeutically effective amount of dexpramipexole or a pharmaceutically acceptable salt thereof, wherein the levels of mast cells, basophils, eosinophils, or a combination thereof reduced. In some cases, the condition was characterized by elevated levels of mast cells, basophils, eosinophils, or a combination thereof in the bone marrow, peripheral blood, tissue, or a combination thereof. In some cases, patients were directed to treatment of a condition characterized by the increased levels of activation of mast cells, basophils, eosinophils, or a combination thereof, comprising the administration of a therapeutically effective amount of dexpramipexole or a pharmaceutically acceptable salt, wherein the levels of activation of mast cells, basophils, eosinophils reduced. In some patients, the condition was characterized by elevated levels of mast cells, basophils, eosinophils, or a combination thereof in the bone marrow, peripheral blood, tissue, or a combination thereof.

In 2018, Bozik *et al.* further disclosed methods of treating conditions, which may be associated with elevated levels

of mast cells, basophils, eosinophils, or a combination thereof, with a therapeutically effective amount of dexpramipexole or pharmaceutical acceptable salt thereof. [US20180015073 (2018)] [131].

Alpan *et al.* disclosed methods for treating or relieving at least one symptom of urticarial disorders including chronic idiopathic urticaria, angioedema, and anaphylaxis, or a combination of these disorders in a mammal, including humans. The method comprises administering the mammal with a therapeutically effective amount of pramipexole, dexpramipexole or pharmaceutically acceptable salts thereof [US20160271112 (2016)] [132].

Chen *et al.* described methods and compositions for inhibiting the expression of an apoptosis-related speck-like protein containing a caspase recruitment domain (ASC), the expression of NLRP3, and/or the formation of the NLRP3 inflammasome complex by using diacerein or its analogs. Also provided are methods and compositions for the treatment and/or prevention of a disorder mediated by ASC and/or NLRP3, and/or by the formation of the NLRP3 inflammasome complex by using diacerein or its analogs [US20170049733 (2017)] [133].

WIPO Patents

Alpan *et al.* disclosed methods for treating or relieving at least one symptom of urticarial disorders including chronic idiopathic urticaria, angioedema, and anaphylaxis, or a combination of these disorders in a mammal, including humans. The method comprises administering to the mammal a therapeutically effective amount of pramipexole, dexpramipexole or pharmaceutically acceptable salts thereof [WIPO WO2015061777] [134]. This patent is not specific to urticaria.

Patents for Test Kits

Harbeck *et al.* disclosed a rapid, non-invasive and highly specific and sensitive diagnostic assay for the identification of individuals with autoimmune chronic urticaria, which makes use of CD203c, and additional proteins, as markers for the disease. Test kits for the diagnosis of an individual suspected of having autoimmune chronic urticaria were also disclosed. Also disclosed are a method of identifying compounds useful for treating autoimmune chronic urticaria and a method of treating autoimmune chronic urticaria [USP20130183248 (2013)] [135]. This is a patent of the diagnostic assay and not a treatment.

ETHICS APPROVAL AND CONSENT TO PARTICIPATE

Not applicable.

HUMAN AND ANIMAL RIGHTS

No Animals/Humans were used for studies that are the basis of this research.

CONSENT FOR PUBLICATION

Not applicable.

AVAILABILITY OF DATA AND MATERIALS

Not applicable.

FUNDING

None.

CONFLICT OF INTEREST

Professor Hon, and Professor Leung, disclose no relevant financial relationship. Prof. Kam L. Hon, Prof. Alexander K.C. Leung, Ms Ng and Dr. Loo confirm that this article has no conflict of interest.

ACKNOWLEDGEMENTS

Professor Kam L. Hon is the principal author. Prof. Alexander K.C. Leung, Ms. Ng and Dr. Loo are the co-authors who contributed and helped with the drafting of this manuscript.

REFERENCES

- [1] Greaves M. Chronic urticaria. *J Allergy Clin Immunol* 2000; 105(4): 664-72.
- [2] Juhlin L. Recurrent urticaria: Clinical investigation of 330 patients. *Br J Dermatol* 1981; 104(4): 369-81.
- [3] Doong JC, Chichester K, Oliver ET, Schwartz LB, Saini SS. Chronic idiopathic urticaria: Systemic complaints and their relationship with disease and immune measures. *J Allergy Clin Immunol Pract* 2017; 5(5): 1314-8.
- [4] Beltrani VS. Urticaria and angioedema. *Dermatol Clin* 1996; 14(1): 171-98.
- [5] Beltrani VS. Urticaria: Reassessed. *Allergy asthma Proc* 2004; 25(3): 143-9.
- [6] Kudryavtseva AV, Neskorođova KA, Staubach P. Urticaria in children and adolescents: An updated review of the pathogenesis and management. *Pediatr Allergy Immunol* 2019; 30(1): 17-24.
- [7] Antia C, Baquerizo K, Korman A, Alikhan A, Bernstein JA. Urticaria: A comprehensive review. *J Am Acad Dermatol* 2018; 79(4): 617-33.
- [8] Leung AK, Hegde HR. Exercise-induced angioedema and asthma. *Am J Sport Med* 1989; 17(3): 442-3.
- [9] Leung AKC, Robson WLM. Penile and oral angioedema associated with peanut ingestion. *J Natl Med Assoc* 2006; 98(12): 2011-2.
- [10] Zuberbier T, Aberer W, Asero R, Abdul Latiff AH, Baker D, Ballmer-Weber B, *et al.* The EAACI/GA²LEN/EDF/WAO guideline for the definition, classification, diagnosis and management of urticaria. *Allergy* 2018; 73(7): 1393-414.
- [11] Beck L, Bernstein J, Maurer M. A review of international recommendations for the diagnosis and management of chronic urticaria. *Acta Derm Venereol* 2008; 97(2): 149-58.
- [12] Buss YA, Garrelfs UC, Sticherling M. Chronic urticaria-which clinical parameters are pathogenetically relevant? A retrospective investigation of 339 patients. *J Dtsch Dermatol Ges* 2007; 5(1): 22-9.
- [13] Ferrer M. Epidemiology, healthcare, resources, use and clinical features of different types of urticaria. *Alergológica* 2005. *J Investig Allergol Clin Immunol* 2009; 19(Suppl 2): 21-6.
- [14] Helligren L. The prevalence of urticaria in the total population. *Acta Allergol* 1972; 27(3): 236-40.
- [15] Lapi F, Cassano N, Pegoraro V, Cataldo N, Heiman F, Cricelli I, *et al.* Epidemiology of chronic spontaneous urticaria: Results from a nationwide, population-based study in Italy. *Br J Dermatol* 2016; 174(5): 996-1004.
- [16] Lee N, Lee J-D, Lee H-Y, Kang DR, Ye Y-M. Epidemiology of chronic urticaria in Korea using the Korean health insurance database, 2010-2014. *Allergy Asthma Immunol Res* 2017; 9(5): 438.
- [17] Lee SJW, Ha EK, Jee HM, Lee KS, Lee SJW, Kim MA, *et al.* Prevalence and risk factors of urticaria with a focus on chronic urticaria in children. *Allergy Asthma Immunol Res* 2017; 9(3): 212.
- [18] Maurer M, Abuzakouk M, Bérard F, Canonica W, Oude Elberink H, Giménez-Arnau A, *et al.* The burden of chronic spontaneous urticaria is substantial: Real-world evidence from ASSURE-CSU. *Allergy* 2017; 72(12): 2005-16.
- [19] Konstantinou GN, Asero R, Ferrer M, Knol EF, Maurer M, Raap U, *et al.* EAACI taskforce position paper: Evidence for autoimmune urticaria and proposal for defining diagnostic criteria. *Allergy* 2013; 68(1): 27-36.
- [20] Fraser K, Robertson L. Chronic urticaria and autoimmunity. *Skin therapy lett* 2018; 18(7): 5-9.
- [21] Confino-Cohen R, Chodick G, Shalev V, Leshno M, Kimhi O, Goldberg A. chronic urticaria and autoimmunity: Associations found in a large population study. *J Allergy Clin Immunol* 2012; 129(5): 1307-13.
- [22] Sabroe RA, Seed PT, Francis DM, Barr RM, Black AK, Greaves MW. Chronic idiopathic urticaria: Comparison of the clinical features of patients with and without anti-FcεpsilonRI or anti-IgE autoantibodies. *J Am Acad Dermatol* 1999; 40(3): 443-50.
- [23] Kozel MMA, Bossuyt PMM, Mekkes JR, Bos JD. Laboratory tests and identified diagnoses in patients with physical and chronic urticaria and angioedema: A systematic review. *J Am Acad Dermatol* 2003; 48(3): 409-16.
- [24] Zhong H, Song Z, Chen W, Li H, He L, Gao T, *et al.* Chronic urticaria in Chinese population: A hospital-based multicenter epidemiological study. *Allergy* 2014; 69(3): 359-64.
- [25] Kim BR, Yang S, Choi JW, Choi CW, Youn SW. Epidemiology and comorbidities of patients with chronic urticaria in Korea: A nationwide population-based study. *J Dermatol* 2018; 45(1): 10-6.
- [26] Dias GAC, Pires GV, Valle SOR do, Dortas SD, Levy S, França AT, *et al.* Impact of chronic urticaria on the quality of life of patients followed up at a university hospital. *An Bras Dermatol* 2016; 91(6): 754-9.
- [27] Sabroe RA, Fiebiger E, Francis DM, Maurer D, Seed PT, Grattan CEH, *et al.* Classification of anti-FcεpsilonRI and anti-IgE autoantibodies in chronic idiopathic urticaria and correlation with disease severity. *J Allergy Clin Immunol* 2002; 110(3): 492-9.
- [28] Maurer M, Zuberbier T, Siebenaar F, Krause K. Chronic urticaria - What does the new guideline tell us? *J Dtsch Dermatol Ges* 2018; 16(5): 584-93.
- [29] Gruber BL, Baeza ML, Marchese MJ, Agnello V, Kaplan AP. Prevalence and functional role of anti-IgE autoantibodies in urticarial syndromes. *J Invest Dermatol* 1988; 90(2): 213-7.
- [30] Sahiner UM, Civelek E, Tuncer A, Yavuz ST, Karabulut E, Sackesen C, *et al.* Chronic urticaria: Etiology and natural course in children. *Int Arch Allergy Immunol* 2011; 156(2): 224-30.
- [31] Awasika O, Qureshi A, Ehrlich A, Fonacier L. Chronic urticaria" Recommendations from an allergist and immunologist. *Dermat contact, atopic, Occup drug* 2018; 29(5): 292-3.
- [32] Kaplan AP. Chronic urticaria: Pathogenesis and treatment. *J Allergy Clin Immunol* 2004; 114(3): 465-74.
- [33] Leznoff A, Sussman GL. Syndrome of idiopathic chronic urticaria and angioedema with thyroid autoimmunity: A study of 90 patients. *J Allergy Clin Immunol* 1989; 84(1): 66-71.
- [34] Kim YS, Han K, Lee JH, Kim NI, Roh JY, Seo SJ, *et al.* Increased risk of chronic spontaneous urticaria in patients with autoimmune thyroid diseases: A nationwide, population-based study. *Allergy Asthma Immunol Res* 2017; 9(4): 373-7.
- [35] Sánchez Jorge J, Sánchez A, Cardona R. Prevalence of drugs as triggers of exacerbations in chronic urticaria. *J Investig Allergol Clin Immunol* 2018. DOI: 10.18176/jiaci.0287.
- [36] Zinelli C, Caffarelli C, Strid J, Jaffe A, Atherton DJ. Measurement of nitric oxide and 8-isoprostane in exhaled breath of children with atopic eczema. *ClinExpDermatol* 2009; 34(5): 607-12.
- [37] Powell RJ, Leech SC, Till S, Huber PAJ, Nasser SM, Clark AT, *et al.* BSACI guideline for the management of chronic urticaria and angioedema. *Clin Exp Allergy* 2015; 45(3): 547-65.
- [38] Schaefer P. Acute and Chronic urticaria: Evaluation and treatment. *Am Fam Physician* 2017; 95(11): 717-24.
- [39] Shalom G, Magen E, Babaev M, Horev A, Freud T, Ben Yakov G, *et al.* Chronic urticaria and irritable bowel syndrome: A cross-sectional study of 11 271 patients. *Br J Dermatol* 2018; 178(3): e204-6.

- [40] Larenas-Linnemann D, Saini SS, Azamar-Jácome AA, Maurer M. Chronic urticaria can be caused by cancer and resolves with its cure. *Allergy* 2018; 73(7): 1562-6.
- [41] Cush JJ. Autoinflammatory syndromes. *Dermatol Clin* 2013; 31(3): 471-80.
- [42] Yu JR, Leslie KS. Cryopyrin-associated periodic syndrome: An update on diagnosis and treatment response. *Curr Allergy Asthma Rep* 2011; 11(1): 12-20.
- [43] Kile RL, Rusk HA. A case of cold urticaria with an unusual family history. *J Am Med Assoc* 1940; 114(12): 1067-8.
- [44] Stych B, Dobrowolny D. Familial cold auto-inflammatory syndrome (FCAS): Characterization of symptomatology and impact on patients' lives. *Curr Med Res Opin* 2008; 24(6): 1577-82.
- [45] Montealegre Sanchez GA, Hashkes PJ. Neurological manifestations of the Mendelian-inherited autoinflammatory syndromes. *Dev Med Child Neurol* 2009; 51(6): 420-8.
- [46] Muckle TJ, Well SM. Urticaria, deafness, and amyloidosis: A new heredo-familial syndrome. *Q J Med* 1962; 31: 235-48.
- [47] Kilcline C, Shinkai K, Bree A, Modica R, Von Scheven E, Frieden IJ. Neonatal-onset multisystem inflammatory disorder: The emerging role of pyrin genes in autoinflammatory diseases. *Arch Dermatol* 2005; 141(2): 248-53.
- [48] Leslie KS, Lachmann HJ, Bruning E, McGrath JA, Bybee A, Gallimore JR, *et al.* Phenotype, genotype, and sustained response to anakinra in 22 patients with autoinflammatory disease associated with CIAS-1/NALP3 mutations. *Arch Dermatol* 2006; 142(12): 1591-7.
- [49] Gusdorf L, Lipsker D. Schnitzler Syndrome: A review. *Curr Rheumatol Rep* 2017; 19(8): 46.
- [50] Ciccarelli F, De Martinis M, Ginaldi L. An update on autoinflammatory diseases. *Curr Med Chem* 2014; 21(3): 261-9.
- [51] Joint task force on practice parameters. The diagnosis and management of urticaria: A practice parameter part I: Acute urticaria/angioedema part II: Chronic urticaria/angioedema. Joint task force on practice parameters. *Ann Allergy Asthma Immunol* 2000; 85(6 Pt 2): 521-44.
- [52] DeShazo RD, Kemp SF. Allergic reactions to drugs and biologic agents. *JAMA* 1997; 278(22): 1895-906.
- [53] Kasumagic-Halilovic E, Beslic N, Ovcina-Kurtovic N. Thyroid autoimmunity in patients with chronic urticaria. *Med Arch (Sarajevo, Bosnia Herzegovina)* 2017; 71(1): 29-31.
- [54] Maurer M, Church MK, Weller K. Chronic urticaria in children: Still itching for insight. *JAMA Dermatology* 2017; 153(12): 1221-2.
- [55] Hermes B, Prochazka AK, Haas N, Jurgovsky K, Sticherling M, Henz BM. Upregulation of TNF-alpha and IL-3 expression in lesional and uninvolved skin in different types of urticaria. *J Allergy Clin Immunol* 1999; 103(2 Pt 1): 307-14.
- [56] Lourenço FD, Azor MH, Santos JC, Prearo E, Maruta CW, Rivitti EA, *et al.* Activated status of basophils in chronic urticaria leads to interleukin-3 hyper-responsiveness and enhancement of histamine release induced by anti-IgE stimulus. *Br J Dermatol* 2008; 158(5): 979-86.
- [57] Kulthanan K, Tuchinda P, Chularojanamontri L, Chanyachailert P, Korkij W, Chunharas A, *et al.* Clinical practice guideline for diagnosis and management of urticaria. *Asian Pacific J allergy Immunol* 2016; 34(3): 190-200.
- [58] Fine LM, Bernstein JA. Urticaria guidelines: Consensus and controversies in the European and American guidelines. *Curr Allergy Asthma Rep* 2015; 15(6): 30.
- [59] Bernstein JA, Lang DM, Khan DA, Craig T, Dreyfus D, Hsieh F, *et al.* The diagnosis and management of acute and chronic urticaria: 2014 Update. *J Allergy Clin Immunol* 2014; 133(5): 1270-7.
- [60] Dreskin SC, Andrews KY. The thyroid and urticaria. *Curr Opin Allergy Clin Immunol* 2005; 5(5): 408-12.
- [61] Kozel MMA, Ansari Moein MC, Mekkes JR, Meinardi MMHM, Bossuyt PMM, Bos JD. Evaluation of a clinical guideline for the diagnoses of physical and chronic urticaria and angioedema. *Acta Derm Venereol* 2002; 82(4): 270-4.
- [62] Gaig P, Olona M, Muñoz Lejarazu D, Caballero MT, Domínguez FJ, Echechipia S, *et al.* Epidemiology of urticaria in Spain. *J Investig Allergol Clin Immunol* 2004; 14(3): 214-20.
- [63] Ben-Shoshan M, Grattan CE. Management of pediatric urticaria with review of the literature on chronic spontaneous urticaria in children. *J Allergy Clin Immunol Pract* 2018.
- [64] Hochstadter EF, Ben-Shoshan M. Cold-induced urticaria: Challenges in diagnosis and management. *BMJ Case Rep* 2013.
- [65] Marzano A V, Tavecchio S, Venturini M, Sala R, Calzavara-Pinton P, Gattomo M. Urticarial vasculitis and urticarial autoinflammatory syndromes. *G Ital Dermatol Venereol* 2015; 150(1): 41-50.
- [66] Kolkhir P, Pogorelov D, Olisova O. CRP, D-dimer, fibrinogen and ESR as predictive markers of response to standard doses of levocetirizine in patients with chronic spontaneous urticaria. *Eur Ann Allergy Clin Immunol* 2017; 49(4): 189-92.
- [67] Kolkhir P, Altrichter S, Hawro T, Maurer M. C-reactive protein is linked to disease activity, impact, and response to treatment in patients with chronic spontaneous urticaria. *Allergy* 2018; 73(4): 940-8.
- [68] Llamas-Velasco M, Fraga J, Requena L, Sánchez-Pérez J, Merino EO, García-Diez A. Urticaria with inflammatory infiltrate predominantly neutrophilic or neutrophilic urticaria. Study of its clinical and histopathological characteristics and its possible association with rheumatologic disease. *Actas Dermosifiliogr* 2012; 103(6): 511-9.
- [69] Zuberbier T. Urticaria. *Allergy* 2003; 58(12): 1224-34.
- [70] Criado PR, Criado RFJ, Maruta CW, Reis VMS dos. Chronic urticaria in adults: State-of-the-art in the new millennium. *An Bras Dermatol* 2015; 90(1): 74-89.
- [71] Wittig HJ, Belloit J, De IF, Royal G. Age-related serum immunoglobulin E levels in healthy subjects and in patients with allergic disease. *J Allergy Clin Immunol* 1980; 66(4): 305-13.
- [72] Takahagi S, Mihara S, Iwamoto K, Morioka S, Okabe T, Kameyoshi Y, *et al.* Coagulation/fibrinolysis and inflammation markers are associated with disease activity in patients with chronic urticaria. *Allergy* 2010; 65(5): 649-56.
- [73] Rojanapremsuk T, Kasprovicz S, Schafer E, Story R, Clarke MS, Walls T, *et al.* Clinicopathologic findings in (anti-FcεpsilonR1alpha) autoimmune-related chronic urticaria. *J Cutan Pathol* 2015; 42(5): 329-32.
- [74] Ulambayar B, Chen Y-H, Ban G-Y, Lee J-H, Jung C-G, Yang E-M, *et al.* Detection of circulating IgG autoantibody to FcεR1α in sera from chronic spontaneous urticaria patients. *J Microbiol Immunol Infect* 2017. DOI: 10.1016/j.jmii.2017.10.003.
- [75] Maouia A, Youssef M, Leban N, Ben Chibani J, Helal AN, Kassab A. CRP relevance in clinical assessment of chronic spontaneous urticaria Tunisian patients. *Cutan Ocul Toxicol* 2017; 36(4): 387-92.
- [76] Cherrez-Ojeda I, Robles-Velasco K, Bedoya-Riofrío P, Schmid-Grendelmeier P, Cherrez S, Colbatzky F, *et al.* Checklist for a complete chronic urticaria medical history: An easy tool. *World Allergy Organ J* 2017; 10(1): 34.
- [77] Itakura A, Tani Y, Kaneko N, Hide M. Impact of chronic urticaria on quality of life and work in Japan: Results of a real-world study. *J Dermatol* 2018; 45(8): 963-70.
- [78] Kozel MM, Mekkes JR, Bossuyt PM, Bos JD. Natural course of physical and chronic urticaria and angioedema in 220 patients. *J Am Acad Dermatol* 2001; 45(3): 387-91.
- [79] Curto-Barredo L, Archilla L, Vives G, Pujol R, Giménez-Arnau A. Clinical features of chronic spontaneous urticaria that predict disease prognosis and refractoriness to standard treatment. *Acta Derm Venereol* 2018; 98(7): 641-7.
- [80] Antia C, Baquerizo K, Korman A, Alikhan A, Bernstein JA. Urticaria: A comprehensive review: Treatment of chronic urticaria, special populations, and disease outcomes. *J Am Acad Dermatol* 2018; 79(4): 617-33.
- [81] Siles R, Xu M, Hsieh FH. The utility of serum tryptase as a marker in chronic spontaneous urticaria. *Acta Derm Venereol* 2013; 93(3): 354-5.
- [82] Netchiporouk E, Sasseville D, Moreau L, Habel Y, Rahme E, Ben-Shoshan M. Evaluating comorbidities, natural history, and predictors of early resolution in a cohort of children with chronic urticaria. *JAMA Dermatology* 2017; 153(12): 1236-42.
- [83] Nebiolo F, Bergia R, Bommarito L, Bugiani M, Heffler E, Carosso A, *et al.* Effect of arterial hypertension on chronic urticaria duration. *Ann Allergy Asthma Immunol* 2009; 103(5): 407-10.
- [84] Sánchez-Borges M, Caballero-Fonseca F, Capriles-Hulett A, González-Aveledo L, Maurer M. Factors linked to disease severity and time to remission in patients with chronic spontaneous urticaria. *J Eur Acad Dermatology Venereol* 2017; 31(6): 964-71.
- [85] Singh-Franco D, Ghin HL, Robles GI, Borja-Hart N, Perez A. Levocetirizine for the treatment of allergic rhinitis and chronic

- idiopathic urticaria in adults and children. *Clin Ther* 2009; 31(8): 1664-87.
- [86] Zuberbier T, Balke M, Worm M, Edenharter G, Maurer M. Epidemiology of urticaria: A representative cross-sectional population survey. *Clin Exp Dermatol* 2010; 35(8): 869-73.
- [87] Labrador-Horrillo M, Ferrer M. Profile of omalizumab in the treatment of chronic spontaneous urticaria. *Drug Des Devel Ther* 2015; 9: 4909.
- [88] Kaplan AP. Therapy of chronic urticaria: A simple, modern approach. *Ann Allergy Asthma Immunol* 2014; 112(5): 419-25.
- [89] Zuberbier T, Aberer W, Asero R, Bindslev-Jensen C, Brzoza Z, Canonica GW, *et al.* The EAACI/GA(2) LEN/EDF/WAO guideline for the definition, classification, diagnosis, and management of urticaria: The 2013 revision and update. *Allergy* 2014; 69(7): 868-87.
- [90] Blanca RDP. Chronic urticaria in children: A review. Available at: <https://www.emjreviews.com/dermatology/article/chronic-urticaria-in-children-a-review/>
- [91] Licari A, Marseglia A, Caimmi S, Castagnoli R, Foiadelli T, Barberi S, *et al.* Omalizumab in children. *Pediatr Drugs* 2014; 16(6): 491-502.
- [92] Maurer M, Rosén K, Hsieh H-J, Saini S, Grattan C, Giménez-Arnau A, *et al.* Omalizumab for the treatment of chronic idiopathic or spontaneous urticaria. *N Engl J Med* 2013; 368(10): 924-35.
- [93] Cordeiro Moreira AS, Rosmaninho Lopes de Soares E Silva MI, Pereira Guilherme MA, Da Silva Ferreira JA, Fonseca Moreira da Silva JP. Use of omalizumab in the treatment of chronic urticaria. *Eur Ann Allergy Clin Immunol* 2016; 48(6): 242-6.
- [94] Brinkhaus B, Ortiz M, Witt CM, Roll S, Linde K, Pfaf F, *et al.* Acupuncture in patients with seasonal allergic rhinitis: A randomized trial. *Ann Intern Med* 2013; 158(4): 225-34.
- [95] Zuberbier T. A summary of the new international EAACI/GA2LEN/EDF/WAO guidelines in urticaria. *World Allergy Organ J* 2012; 5(Suppl 1): S1-5.
- [96] Sharma M, Bennett C, Cohen SN, Carter B. H1-antihistamines for chronic spontaneous urticaria. *Cochrane database Syst Rev* 2014; (11): CD006137.
- [97] Lee XHM, Ong LX, Cheong JYV, Sultana R, Rao R, Lim HH, *et al.* A stepwise approach in the management of chronic spontaneous urticaria in children. *Asia Pac Allergy* 2016; 6(1): 16-28.
- [98] Lee XHM, Ong LX, Cheong JYV, Sultana R, Rao R, Lim HH, *et al.* No Tit A stepwise approach in the management of chronic spontaneous urticaria in children. *Asia Pac Allergy* 2016; 6(1): 16-28.
- [99] Uysal P, Avcil S, Erge D. High-dose anti-histamine use and risk factors in children with urticaria. *Türk Pediatr Arşivi* 2016; 51(4): 198-203.
- [100] Choi SH, Baek HS. Approaches to the diagnosis and management of chronic urticaria in children. *Korean J Pediatr* 2015; 58(5): 159-64.
- [101] Erbagci Z. The leukotriene receptor antagonist montelukast in the treatment of chronic idiopathic urticaria: A single-blind, placebo-controlled, crossover clinical study. *J Allergy Clin Immunol* 2002; 110(3): 484-8.
- [102] Pacor ML, Di Lorenzo G, Corrocher R. Efficacy of leukotriene receptor antagonist in chronic urticaria. A double-blind, placebo-controlled comparison of treatment with montelukast and cetirizine in patients with chronic urticaria with intolerance to food additive and/or acetylsalicylic acid. *Clin Exp Allergy* 2001; 31(10): 1607-14.
- [103] De Silva N, Damayanthi H, Rajapakse A, Rodrigo C, Rajapakse S. Leukotriene receptor antagonists for chronic urticaria: A systematic review. *Allergy, Asthma Clin Immunol* 2014; 10(1): 24.
- [104] Pite H, Wedi B, Borrego LM, Kapp A, Raap U. Management of childhood urticaria: Current knowledge and practical recommendations. *Acta Derm Venereol* 2013; 93(5): 500-8.
- [105] Sokol KC, Amar NK, Starkey J, Grant JA. Ketotifen in the management of chronic urticaria: Resurrection of an old drug. *Ann Allergy Asthma Immunol* 2013; 111(6): 433-6.
- [106] Boehm I, Bauer R, Bieber T. Urticaria treated with dapson. *Allergy* 1999; 54(7): 765-6.
- [107] Zhao Z-T, Ji C-M, Yu W-J, Meng L, Hawro T, Wei J-F, *et al.* Omalizumab for the treatment of chronic spontaneous urticaria: A meta-analysis of randomized clinical trials. *J Allergy Clin Immunol* 2016; 137(6): 1742-1750.e4.
- [108] Giménez-Arnau AM, Toubi E, Marsland AM, Maurer M. Clinical management of urticaria using omalizumab: The first licensed biological therapy available for chronic spontaneous urticaria. *J Eur Acad Dermatol Venereol* 2016; 30(Suppl 5): 25-32.
- [109] Netchiporouk E, Nguyen CH, Thuraisingham T, Jafarian F, Maurer M, Ben-Shoshan M. Management of pediatric chronic spontaneous and physical urticaria patients with omalizumab: Case series. *Pediatr Allergy Immunol* 2015; 26(6): 585-8.
- [110] Holgate ST, Djukanovic R, Casale T, Bousquet J, Djukanović R, Casale T, *et al.* Anti-immunoglobulin E treatment with omalizumab in allergic diseases: An update on anti-inflammatory activity and clinical efficacy. *ClinExpAllergy* 2005; 35(4): 408-16.
- [111] Maurer M, Abuzakouk M, Bérard F, Canonica W, Oude Elberink H, Giménez-Arnau A, *et al.* The burden of chronic spontaneous urticaria is substantial: Real-world evidence from ASSURE-CSU. *Allergy* 2017; 72(12): 2005-16.
- [112] Bradley JS, Byington CL, Shah SS, Alverson B, Carter ER, Harrison C, *et al.* The management of community-acquired pneumonia in infants and children older than 3 months of age: Clinical practice guidelines by the pediatric infectious diseases society and the infectious diseases society of America. *Clin Infect Dis* 2011; 53(7): e25-76.
- [113] Kaplan AP. What the first 10,000 patients with chronic urticaria have taught me: A personal journey. *J Allergy Clin Immunol* 2009; 123(3): 713-7.
- [114] Ohtsuka T. Response to oral cyclosporine therapy and high sensitivity-CRP level in chronic idiopathic urticaria. *Int J Dermatol* 2010; 49(5): 579-84.
- [115] Doshi DR, Weinberger MM. Experience with cyclosporine in children with chronic idiopathic urticaria. *Pediatr Dermatol* 2009; 26(4): 409-13.
- [116] Marchese ML, Eimer L, Stringa O. Ciclosporin and its use in dermatology: Introduction. *Arch Argent Dermatol* 2014; 64(3): 89-97.
- [117] Kim S, Baek S, Shin B, Yoon S, Park SY, Lee T, *et al.* Influence of initial treatment modality on long-term control of chronic idiopathic urticaria. *PLoS One* 2013; 8(7): e69345.
- [118] Maurer M, Magerl M, Metz M, Zuberbier T. Revisions to the international guidelines on the diagnosis and therapy of chronic urticaria. *J Dtsch Dermatol Ges* 2013; 11(10): 971-7.
- [119] Kurt E, Bavbek S, Pasaoglu G, Abadoglu O, Misirligil Z. Use of alternative medicines by allergic patients in Turkey. *Allergol Immunopathol (Madr)* 2004; 32(5): 289-94.
- [120] Morgan M. Treatment of refractory chronic urticaria with sirolimus. *Arch Dermatol* 2009; 145(6): 637-9.
- [121] Shahar E, Bergman R, Guttman-Yassky E, Pollack S. Treatment of severe chronic idiopathic urticaria with oral mephistolol mofetil in patients not responding to antihistamines and/or corticosteroids. *Int J Dermatol* 2006; 45(10): 1224-7.
- [122] Sönnichsen A, Saulite I, Mangana J, Kerl K, Mehra T, Desislava I, *et al.* Interleukin-1 receptor antagonist (anakinra) for Schnitzler syndrome. *J Dermatolog Treat* 2016; 27(5): 436-8.
- [123] Néel A, Henry B, Barbarot S, Masseur A, Perrin F, Bernier C, *et al.* Long-term effectiveness and safety of interleukin-1 receptor antagonist (anakinra) in Schnitzler's syndrome: A french multicenter study. *Autoimmun Rev* 2014; 13(10): 1035-41.
- [124] Dworetzky SI, Hebrank GT, Archibald DG, Reynolds IJ, Farwell W, Bozik ME. The targeted eosinophil-lowering effects of dexpropimexole in clinical studies. *Blood Cells Mol Dis* 2017; 63: 62-5.
- [125] Koné-Paut I, Piram M. Targeting interleukin-1 β in CAPS (Cryopyrin-Associated Periodic) syndromes. *Autoimmun Rev* 2012; 12(1): 77-80.
- [126] Geogin-Lavialle S, Fayand A, Rodrigues F, Bachmeyer C, Savey L, Grateau G. Autoinflammatory diseases: State of the art. *Presse Med* 2019.
- [127] Imagawa T, Nishikomori R, Takada H, Takeshita S, Patel N, Kim D, *et al.* Safety and efficacy of canakinumab in Japanese patients with phenotypes of cryopyrin-associated periodic syndrome as established in the first open-label, phase-3 pivotal study (24-week results). *Clin Exp Rheumatol* 2019; 31(2): 302-9.
- [128] Gram, H., Jung, T. New indications for anti-IL-1beta therapy. *EP2468302 (2012)*.
- [129] Vairo, G.L., Hamilton, J.A., Cook, A.D. Treatment of chronic inflammatory conditions. *US20150017180 (2015)*.

- [130] Bozik, M.E., Dworetzky, S. Compositions and methods for treating chronic urticaria. US20160193186 (2016).
- [131] Bozik, M.E., Dworetzky, S. Compositions and methods for treating chronic urticaria. US20180015073 (2018).
- [132] Alpan, O., Enav, B.I. Therapy for chronic idiopathic urticaria, anaphylaxis and angioedema. US20160271112 (2016).
- [133] Chen, C., Lee, J., Lu, W., Brown, C.O. Methods for inhibiting expression of asc, expression of NLRP3, and/or formation of NLRP3 inflammasome complex using diacerein or its analogs. US20170049733 (2017).
- [134] Alpan, O., Enav, B. Therapy for chronic idiopathic urticaria, anaphylaxis and angioedema. WO2015061777 (2015).
- [135] Harbeck R.J., Andrews K.M., MacGlashan Jr. D. Method and kit for detection of autoimmune chronic urticaria. US20130183248 (2013).