

Erratum: Acute pulmonary embolism

Author: Luke Howard^A

Author: ^Aconsultant pulmonologist, Hammersmith Hospital, London, UK

Clinical Medicine 2019;19:243–7

Please note the correction to Fig 2, risk stratification of non-high risk pulmonary embolism (based on European Society of Cardiology 2014 guidelines), the low risk arm is for 'PESI class I–II or sPESI = 0'.

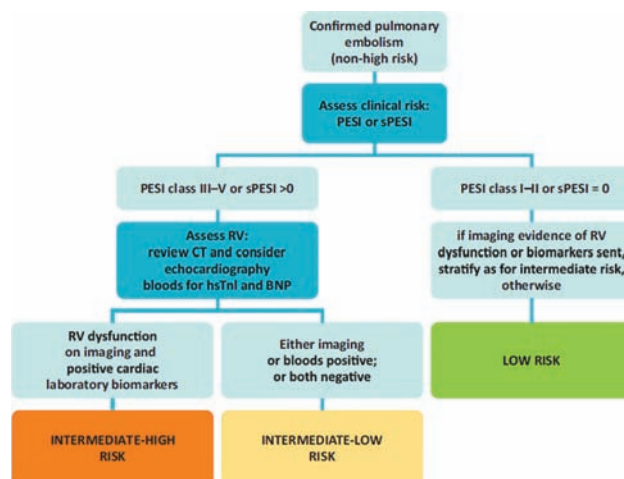


Fig 2. Risk stratification of non-high risk pulmonary embolism (based on European Society of Cardiology 2014 guidelines).³ BNP = brain natriuretic peptide; CT = computed tomography; hsTnI = high sensitive Troponin-I; PESI = Pulmonary Embolism Severity Index; RV = right ventricle; sPESI = simplified Pulmonary Embolism Severity Index.