

## Detection of coexisting toxigenic *Clostridium difficile* and nontyphoidal *Salmonella* in a healthcare worker with diarrhea: A therapeutic dilemma

Amos Lal<sup>1</sup>, Raul Davaro<sup>2</sup>, Ajay Kumar Mishra<sup>1</sup>, Kamal Kant Sahu<sup>3</sup>,  
George M. Abraham<sup>3</sup>

Departments of <sup>1</sup>Internal Medicine and <sup>3</sup>Medicine, Saint Vincent Hospital, <sup>2</sup>Division of Infectious Diseases, Worcester Medical Center, Reliant Medical Group, Worcester, MA, USA

### ABSTRACT

**Introduction:** *Clostridium difficile* infection (CDI) and nontyphoidal *Salmonella* infection (NSI) have similar clinical manifestations and are seldom seen simultaneously. The decision-making in terms of antibiotic therapy becomes difficult when both the pathogens are isolated from the same patient. **Case Presentation:** We describe a case of *Clostridium difficile* (CD) enterocolitis in a healthcare provider who concomitantly tested positive for nontyphoidal *Salmonella*. **Discussion:** To the best of our knowledge after extensive literature review (English), this is only the fourth report highlighting this association. **Conclusion:** Although *Salmonella* is not a risk factor for CDI, it can cause intestinal inflammation and alteration in the intestinal flora. When two pathogens are isolated from the same patient, it is tempting to treat both with antibiotics as highlighted. When it involves healthcare workers, there is no difference in guidelines and should not be prescribed antibiotics with intent of reducing secondary transmission.

**Keywords:** Antibiotics, *Clostridium difficile*, diarrhea, healthcare worker, nontyphoidal *Salmonella*

### Case Presentation

A 45-year-old emergency room nurse was admitted to the hospital with complaints of lower abdominal pain, three episodes of nonbloody diarrhea, and fever of 1 day duration. The abdominal pain was nonradiating and was colicky in nature. She denied any recent sick contacts except during her clinical work in the emergency room and she had no recent travel. One week prior to her current admission, she was treated with 1 week course of nitrofurantoin for cystitis as outpatient and experienced complete resolution of her urinary symptoms. Her medical history included

general anxiety disorder for which she has been on paroxetine for many years. At the time of admission, she was noted to be febrile with a temperature of 38.7°C; she was tachycardic with heart rate of 110/min and blood pressure of 155/79 mmHg. She was in no respiratory distress and was saturating 100% on room air. The remainder of her physical examination was remarkable for hyperactive bowel sounds with generalized abdominal tenderness. There was no rigidity or rebound tenderness. Her respiratory and cardiovascular examination was unremarkable.

Laboratory data revealed leucopenia and no immature forms with total white cell count of  $3.0 \times 1000/\mu\text{L}$  ( $3.9\text{--}11.0 \times 1000/\mu\text{L}$ ) with normal hemoglobin, hematocrit, and platelet counts. She had normal serum chemistry with creatinine of 0.63 mg/dL and calculated

**Address for correspondence:** Dr. Amos Lal,  
Department of Internal Medicine, 123 Summer Street, Saint  
Vincent Hospital, Worcester, MA 01608, USA.  
E-mail: Amos.Lal@stvincenthospital.com

Received: 16-03-2019 Revised: 16-03-2019 Accepted: 08-06-2019

#### Access this article online

##### Quick Response Code:



Website:  
www.jfmipc.com

DOI:  
10.4103/jfmipc.jfmipc\_227\_19

This is an open access journal, and articles are distributed under the terms of the Creative Commons Attribution-NonCommercial-ShareAlike 4.0 License, which allows others to remix, tweak, and build upon the work non-commercially, as long as appropriate credit is given and the new creations are licensed under the identical terms.

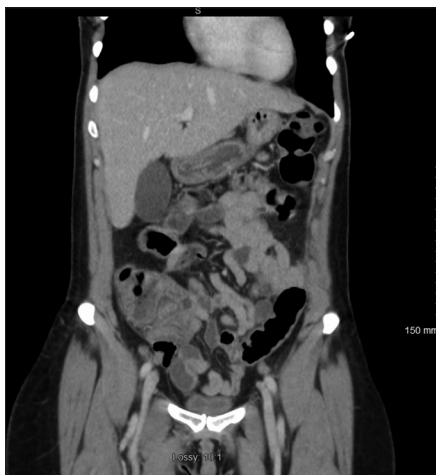For reprints contact: reprints@medknow.com

**How to cite this article:** Lal A, Davaro R, Mishra AK, Sahu KK, Abraham GM. Detection of coexisting toxigenic *Clostridium difficile* and nontyphoidal *Salmonella* in a healthcare worker with diarrhea: A therapeutic dilemma. J Family Med Prim Care 2019;8:2724-7.

glomerular filtration rate of 110 mL/min. Serum electrolytes and liver function tests were normal. Her erythrocyte sedimentation rate was 14 mm/h (2–15 mm/h), but C-reactive protein was significantly elevated to 124 mg/dL (0.0–4.9 mg/dL). A computed tomography scan of the abdomen and pelvis with contrast showed findings consistent with active colitis involving the caecum and ascending colon with adjacent inflammatory stranding [Figure 1]. The distal small bowel was also noted to be fluid-filled which was concerning for concurrent small bowel enteritis [Figure 2a and b].

There was no evidence of intraabdominal collection or perforation. With the concern for active colitis on the imaging study, the patient was given a single dose of intravenous cefoxitin in the emergency room. Due to the recent use of antimicrobial for cystitis, we entertained the possibility of CDI and oral vancomycin was introduced and cefoxitin was discontinued while the stool samples were sent for CD toxin and other stool studies including *Shigella*, *Salmonella*, *Campylobacter*, and *Escherichia coli*.

The stool studies returned positive for toxigenic *Clostridium difficile* (CD) using real-time polymerase chain reaction (Cepheid Xpert *C. difficile*/Epi, Cepheid, Sunnyvale CA, USA) and was negative for epidemic strain BI/NAP1/027. The patient showed remarkable improved within 48 h of treatment with oral vancomycin with resolution of diarrhea, fever, and abdominal pain. On the third day of hospital admission, stool cultures returned positive for *Salmonella* sp. (Cary-Blair stool culture transport medium; Quest Diagnostics NY/NJ, USA) and was negative for *Shigella*, *Campylobacter*, and enterohemorrhagic *E. coli*. Her blood remained sterile. Since the patient's symptoms were resolving with the current antibiotic regime and absence of any other systemic complaints, decision was made to treat CDI with 10 days of oral vancomycin and no additional treatment for *Salmonella* in stools. At her 2 weeks of follow-up, the patient was asymptomatic with no further episodes of abdominal pain, diarrhea, or fever. She had no untoward effects from the oral antibiotics therapy.



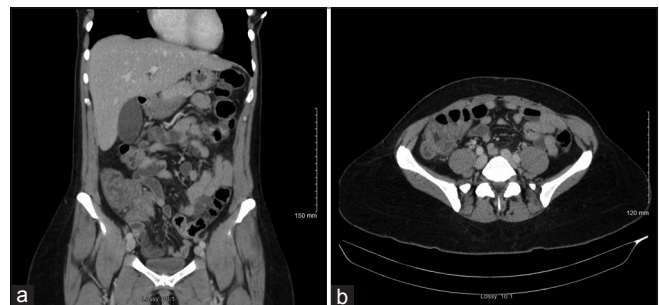
**Figure 1:** Axial section of CT scan of abdomen with intravenous contrast showing wall thickening of cecum with adjacent mild inflammatory stranding

## Discussion

*Clostridium difficile* infection (CDI) causes close to 500,000 infections annually worldwide, although the exact magnitude depends on the type of diagnostic tests used.<sup>[1]</sup> Nontyphoidal *Salmonella* infection (NSI) is a common foodborne illness causing 93 million enteric infections worldwide annually and 1.4 million cases in the United States.<sup>[2–5]</sup> The majority of *Salmonella* cases in the United States are of nontyphoidal type.<sup>[3]</sup> Both infections, CDI and NSI, have similar clinical manifestations and are seldom seen simultaneously in a patient and can be difficult to distinguish if presented at the same time. The decision-making in terms of antibiotic therapy becomes difficult when both the pathogens are isolated from the same patient. To increase the complexity, if the patient is involved in a profession where disease transmissibility is a concern, the temptation to treat the carrier state is tangible. We have been able to find three reports in the literature (English) with simultaneous CDI and NSI, and none of the patients was a healthcare worker.<sup>[6–8]</sup>

Epidemiologically, it has been shown that up to 3% on healthy adults may be colonized asymptotically with CD and this number increases significantly in the healthcare setting.<sup>[9,10]</sup> Healthcare workers are clearly at increased risk of developing CDI owing to their direct contact with patients, and this population includes physicians, nurses, and laboratory personnel.<sup>[10,11]</sup> CD spores are present ubiquitously on inanimate objects and are resistant to commonly used decontaminants; they can persist for long periods of time without loss of viability and are transmitted via feco-oral pathway.<sup>[10,12]</sup>

Concomitant CDI and *Salmonella* infection in immunocompetent host is not commonly seen. To the best of our knowledge after extensive literature review (English), this is only the fourth report highlighting this association. Whether it was a coinfection versus colonization and detection of coexisting nontyphoidal *Salmonella* is debatable. In either case, the detection of these two pathogens in clinical setting raises concerns for antibiotics of choice and duration. The differentiation between colonization versus active infection with nontyphoidal *Salmonella* may not always be possible in a clinical setting; when it presents in a healthcare worker, the



**Figure 2:** (a) Coronal section of CT scan of abdomen with intravenous contrast showing wall thickening of distal small bowel with fluid-filled bowel indicating concurrent enteritis. (b) Axial section of CT scan of abdomen with intravenous contrast showing similar findings as Figure 2(a) in a different plane

decision becomes even more challenging considering concerns of infection transmission. Literature review from the previous reports is described in Table 1.

Our patient was exposed to nitrofurantoin which is a lower risk of inducing CDI compared to antibiotics such as clindamycin, carbapenems, and fluoroquinolones.<sup>[13]</sup>

Coinfection with *Salmonella* and CD has been reported in the past. Monkemuller *et al.* described a case where nontyphoidal *Salmonella* infection mimicked pseudomembranous colitis as a severe presentation of the disease.<sup>[14]</sup> Although *Salmonella* is not a risk factor for CDI, it can cause intestinal inflammation and alteration in the intestinal flora.<sup>[15,16]</sup> Some researchers have postulated that CD toxin had a protective effect by decreasing the transepithelial and paracellular migration of enteropathic bacteria, thereby reducing chances of bacterial colitis caused by pathogens like *Salmonella*.<sup>[17]</sup> *Salmonella* can both colonize and cause active infection; however, certain *Salmonella* species are more adapted for causing human infections when compared to others. *Salmonella typhi* is known to be an obligate human pathogen, whereas nontyphoidal *Salmonella* can be seen in cattle as well.<sup>[18]</sup>

Clinical presentation of *Salmonella* gastroenteritis and CDI can be very similar. When both pathogens are isolated from the same patient, it is tempting to treat both with antibiotics as highlighted in our literature review [Table 1]. Despite clear guidelines, often times patients are prescribed antibiotics with the intent of reducing the transmission of *Salmonella*. Hand hygiene appears to be the cornerstone to reduce transmission of bacteria.<sup>[19,20]</sup> When it comes to healthcare workers, there is no difference in guidelines and should not be prescribed antibiotics with intent of reducing secondary transmission.<sup>[20]</sup> Normally, patients shed bacteria for up to 4 weeks after acute infection and antibiotics given during the acute phase with prolong the carrier state by altering the normal gut flora.<sup>[21,22]</sup> As far as infection control measures and fitness for work are concerned, healthcare workers can return to work after cessation of diarrhea.<sup>[23]</sup>

Treatment guidelines for CDI are being revised regularly. Current recommendations are in favor for treatment of CDI with oral vancomycin 125 mg four times a day resulting in quicker response than metronidazole.<sup>[24,25]</sup> In critically ill patients with severe disease, early surgery is found to reduce mortality in the group of patients with intact immune system, age 65 years and more, mounting good leucocytotic response and with moderate rise in serum lactate values.<sup>[24,26]</sup>

CDI is also associated with older age, recent hospitalization, multiple comorbidities, use of gastric acid blockers, inflammatory bowel disease, and immunosuppression. It has become more common in younger and healthier patients in community settings. However, in cases where a patient is tested for nontyphoidal *Salmonella* as in the case that we present; the decision-making becomes more difficult. Treatment includes discontinuing the contributing antibiotic, if possible. Appropriate diagnostic testing and restricted use of antibiotics (Antimicrobial stewardship programs) by an astute internist and family physician in the community can be of significant impact in this matter.<sup>[27]</sup>

In conclusion, awareness of cases where two pathogens are concurrently isolated in a patient is of prime importance, especially in this era of rising prevalence of *C difficile*-associated disease (CDAD) and drug resistance. The importance of decision-making based on the clinical response of patient after antibiotic therapy cannot be overemphasized. Also, the guidelines state clear directives with regard to no additional antibiotic use for healthcare professionals suffering such infections and no additional need for quarantine after resolution of gastrointestinal symptoms.

### Declaration of patient consent

The authors certify that they have obtained all appropriate patient consent forms. In the form the patient(s) has/have given his/her/their consent for his/her/their images and other clinical information to be reported in the journal. The

**Table 1: Literature review for previous reports describing the association of CDI and *Salmonella***

Study	Age/sex	Recent history of antibiotic use	Steroid use or other immunosuppression	Treatment	Outcome
Brettle <i>et al.</i> <sup>[6]</sup>	24/F	Erythromycin	None	Vancomycin	Survived
Brettle <i>et al.</i> <sup>[6]</sup>	65/F	Co-trimoxazole	Prednisone	Vancomycin Chloramphenicol	Survived
Brettle <i>et al.</i> <sup>[6]</sup>	79/M	Ampicillin Flucloxacillin	None	Not mentioned	Survived
Brettle <i>et al.</i> <sup>[6]</sup>	75/M	Chloramphenicol Amoxicillin Erythromycin	Chronic obstructive pulmonary disease (COPD) (possible steroid use)	Not mentioned	Died
Grinblat <i>et al.</i> <sup>[7]</sup>	86/M	None	None	Metronidazole	Survived
Grinblat <i>et al.</i> <sup>[7]</sup>	80/F	None	None	Metronidazole Ciprofloxacin	Survived
Halvorson <i>et al.</i> <sup>[8]</sup>	20/F	None	None	Imipenem Cilastatin Vancomycin Metronidazole	Died

patients understand that their names and initials will not be published and due efforts will be made to conceal their identity, but anonymity cannot be guaranteed.

## Financial support and sponsorship

Nil.

## Conflicts of interest

There are no conflicts of interest.

## References

- McDonald LC, Gerding DN, Johnson S, Bakken JS, Carroll KC, Coffin SE, et al. Clinical practice guidelines for *Clostridium difficile* infection in adults and children: 2017 update by the Infectious Diseases Society of America (IDSA) and Society for Healthcare Epidemiology of America (SHEA). *Clin Infect Dis* 2018;66:987-94.
- Trong TA, Nicholas AF, Melita AG, Karen HK, Frederick JA, John AC. Global burden of invasive nontyphoidal *Salmonella* disease, 2010. *Emerg Infect Dis J* 2015;21:941.
- Voetsch AC, Van Gilder TJ, Angulo FJ, Farley MM, Shallow S, Marcus R, et al. FoodNet estimate of the burden of illness caused by nontyphoidal *Salmonella* infections in the United States. *Clin Infect Dis* 2004;38(Suppl. 3):S127-34.
- Mead PS, Slutsker L, Dietz V, McCaig LF, Bresee JS, Shapiro C, et al. Food-related illness and death in the United States. *Emerg Infect Dis* 1999;5:607-25.
- Chalker RB, Blaser MJ. A review of human salmonellosis: III. Magnitude of *Salmonella* infection in the United States. *Rev Infect Dis* 1988;10:111-24.
- Brettle RP, Poxton IR, Murdoch JM, Brown R, Byrne MD, Collee JG. *Clostridium difficile* in association with sporadic diarrhoea. *Br Med J (Clin Res Ed)* 1982;284:230-3.
- Grinblat J, Weiss A, Grosman B, Dicker D, Beloosesky Y. Diarrhea in elderly patients due to *Clostridium difficile* associated with *Salmonella* and *Shigella* infection. *Arch Gerontol Geriatr* 2004;39:277-82.
- Halvorson SAC, Cedfeldt AS, Hunter AJ. Fulminant, non-antibiotic associated *Clostridium difficile* colitis following *Salmonella* gastroenteritis. *J Gen Int Med* 2011;26:95-7.
- Brazier JS, Fitzgerald TC, Hosein I, Cefai C, Looker N, Walker M, et al. Screening for carriage and nosocomial acquisition of *Clostridium difficile* by culture: A study of 284 admissions of elderly patients to six general hospitals in Wales. *J Hosp Infect* 1999;43:317-9.
- Ghose C. *Clostridium difficile* infection in the twenty-first century. *Emerg Microbes Infect* 2013;2:e62.
- Bouza E, Martin A, Van den Berg RJ, Kuijper EJ. Laboratory-acquired *clostridium difficile* polymerase chain reaction ribotype 027: A new risk for laboratory workers? *Clin Infect Dis* 2008;47:1493-4.
- Gerding DN, Johnson S, Peterson LR, Mulligan ME, Silva J, Jr. *Clostridium difficile*-associated diarrhea and colitis. *Infect Control Hosp Epidemiol* 1995;16:459-77.
- Brown KA, Khanafer N, Daneman N, Fisman DN. Meta-analysis of antibiotics and the risk of community-associated *Clostridium difficile* infection. *Antimicrob Agents Chemother* 2013;57:2326-32.
- Monkemuller K, Patasiute I, Walther F, Peitz U, Fry LC, Malferttheiner P. Pseudomembranous colitis due to *Salmonella enterica* serotype infantis. *Endoscopy* 2006;38:546.
- Santos RL, Raffatellu M, Bevins CL, Adams LG, Tükel C, Tsois RM, et al. Life in the inflamed intestine, *Salmonella* style. *Trends Microbiol* 2009;17:498-506.
- Feltis BA, Kim AS, Kinneberg KM, Lyerly DL, Wilkins TD, Erlandsen SL, et al. *Clostridium difficile* toxins may augment bacterial penetration of intestinal epithelium. *Arch Surg* 1999;134:1235-41; discussion 1241-32.
- Feltis BA, Garni RM, Wells CL. *Clostridium difficile* toxins and enterococcal translocation *in vivo* and *in vitro*. *J Surg Res* 2001;97:97-102.
- Cianflone NFC. Salmonellosis and the GI tract: More than just peanut butter. *Curr Gastroenterol Rep* 2008;10:424-31.
- Shane AL, Mody RK, Crump JA, Tarr PI, Steiner TS, Kotloff K, et al. 2017 Infectious Diseases Society of America Clinical Practice Guidelines for the diagnosis and management of infectious diarrhea. *Clin Infect Dis* 2017;65:1963-73.
- Guerrant RL, Van Gilder T, Steiner TS, Thielman NM, Slutsker L, Tauxe RV, et al. Practice guidelines for the management of infectious diarrhea. *Clin Infect Dis* 2001;32:331-51.
- Sirinavin S, Garner P. Antibiotics for treating *Salmonella* gut infections. *Cochrane Database Syst Rev* 2000;Cd001167.
- Onwuezobe IA, Oshun PO, Odigwe CC. Antimicrobials for treating symptomatic non-typhoidal *Salmonella* infection. *Cochrane Database Syst Rev* 2012;11:CD001167.
- Hohmann EL. Nontyphoidal salmonellosis. *Clin Infect Dis* 2001;32:263-9.
- Cózar-Llistó A, Ramos-Martinez A, Cobo J. *Clostridium difficile* infection in special high-risk populations. *Infect Dis Ther* 2016;5:253-69.
- Johnson S, Louie TJ, Gerding DN, Cornely OA, Chasan-Taber S, Fitts D, et al. Vancomycin, metronidazole, or tolevamer for *Clostridium difficile* infection: Results from two multinational, randomized, controlled trials. *Clin Infect Dis* 2014;59:345-54.
- Lamontagne F, Labbe AC, Haecck O, Lesur O, Lalancette M, Patino C, et al. Impact of emergency colectomy on survival of patients with fulminant *Clostridium difficile* colitis during an epidemic caused by a hypervirulent strain. *Ann Surg* 2007;245:267-72.
- Winslow BT, Onysko M, Thompson KA, Caldwell K, Ehlers GH. Common questions about *Clostridium difficile* infection. *Am Fam Physician* 2014;89:437-42.