

## Review

## Open Access

Nicole Ernst\* and Nicolai Adolphs

# Role of distraction osteogenesis in craniomaxillofacial surgery

DOI 10.1515/iss-2016-0027

Received October 11, 2016; accepted November 6, 2016; previously published online December 8, 2016

**Abstract:** In the field of orthopedic surgery, distraction osteogenesis (DO) is well known for limb lengthening procedures or secondary corrective surgery in the fracture treatment of the extremities. The principle of gradual expansion of bone and surrounding soft tissues as originally described by G.A. Ilizarov is also applicable to the craniofacial skeleton when growth deficiency is present, and the patients affected by craniofacial or dentofacial anomalies may require distraction procedures. The surgical management is comparable. After osteotomy and the mounting of a specific craniomaxillofacial distraction device, active distraction is started after a latency phase of several days, with a distraction rate of up to 1 mm/day until the desired amount of distraction has been achieved. Subsequently, distractors are locked to provide appropriate stability within the distraction zone for callus mineralization during the consolidation phase of 3–6 months, which is followed by a further remodeling of the bony regenerate. After 14 years of clinical application, the role and significance of craniomaxillofacial DO are discussed after reviewing the files of all patients who were treated by craniomaxillofacial distraction procedures.

**Keywords:** dentofacial anomaly; gradual expansion; Ilizarov method.

## Introduction

In 1904/1905, the Italian Codivilla already reported about the possibility of lengthening the lower limb by continuous

traction [1]. However, the first successful callus distraction of a human femur after bilateral diaphyseal fractures was performed in 1923 by August Bier in Berlin [2]. Within the field of maxillofacial surgery, distraction approaches were already described between 1920 and 1930. In 1926, Wassmund reported about the possibility of closing an open-bite situation by applying elastic traction to the upper jaw after its subtotal surgical mobilization. Almost at the same time, Rosenthal in Leipzig managed to reconstruct the lower face of a female patient affected by mandibular hypoplasia by applying a tooth-borne expansion device to the anterior lower jaw after bony separation. Probably due to the politic situation during the following period of time, these observations have not been further investigated by these authors [3]. The principle of distraction osteogenesis (DO) and its application to the extremities has been initially described in detail by the Russian surgeon G.A. Ilizarov who was working in Kurgan, Siberia, after World War II. There he was engaged in the treatment of complicated fractures and pseudarthroses of the lower limbs. For that purpose, he was using simple external fixation devices with threads to apply compression to the fracture zones. However, one of his patients occasionally failed to activate the threads correctly and “distracted” the bony segments instead of compressing them. Ilizarov observed ongoing callus formation and mineralization in the former fracture zone and continued to investigate this observation systematically. Subsequently, he developed his method – the “Ilizarov technique” – for fracture treatment, management of bony defect situations, and limb lengthening using the “tension stress effect”: metabolic tissue activation and improved vascularization by the application of gradual traction [4–6]. Within the field of craniomaxillofacial surgery, experimental work about mandibular DO was published by Snyder and Michieli in the 1970s [7, 8]. However, the clinical application of DO to the craniomaxillofacial skeleton has been emphasized by the U.S. plastic surgeon Joseph G. McCarthy who initially reported about the successful reconstruction of the lower face in children affected by craniofacial microsomia in the late 1980s and subsequently extended the indications of the method [9, 10]. Twenty-five years after an initial

\*Corresponding author: Nicole Ernst, Department of Craniomaxillofacial Surgery, Charité Universitätsmedizin Berlin, Centre 9 for Traumatology and Reconstructive Surgery, Campus Virchow Klinikum, Berlin, Germany, E-mail: nicole.ernst@charite.de  
Nicolai Adolphs: Department of Craniomaxillofacial Surgery, Charité Universitätsmedizin Berlin, Centre 9 for Traumatology and Reconstructive Surgery, Campus Virchow Klinikum, Berlin, Germany

“hype” for the method, the application of craniomaxillofacial distraction nowadays is more restricted. According to web-based surveys, there seems to be a lack of evidence for the indication of craniomaxillofacial distraction procedures [11]. Nevertheless, the method can be regarded as an established treatment option in selected patients who are affected by obvious growth restriction or deficiency of the craniomaxillofacial skeleton. Based on 14 years of personal experience, the role and significance of craniomaxillofacial DO are discussed with regard to the corresponding literature and illustrated by three typical patient cases. Accordingly, craniomaxillofacial DO plays a minor role with regard to overall surgical procedures within the field; however, if severe growth restriction is present or has to be expected, the principle of gradual tissue expansion should be regarded as an additional reconstructive option for patients affected by craniofacial or dentofacial anomalies within an staged individual treatment plan.

## Materials and methods

After the preceding experimental research work [12–14], craniomaxillofacial DO has been implemented in 2003 at the Charité Universitätsmedizin Berlin, Campus Virchow-Klinikum (CVK), for the reconstruction of patients affected by craniofacial or dentofacial deformities or comparable skeletal deficiencies due to trauma or tumor. Specific “distraction files” of these patients have been documented from the very beginning by the senior author, including parameters of distraction, corresponding X-rays, and photo-documentation. These distraction files have been reviewed and analyzed to assess the role and significance of craniomaxillofacial DO. In addition, after the end of the therapy, qualitative assessment was performed by a simple questionnaire: Would the patient

undergo distraction again? Would distraction be recommended again? Informed consent has been obtained from all patients who were treated by craniomaxillofacial distraction procedures.

## Results

Within 14 years, 152 distraction procedures of the craniomaxillofacial skeleton have been performed representing less than 1% of all patients (>30,000) who received craniomaxillofacial therapy during the period of time. A detailed overview of the type, localization, and results of distraction is given in Table 1.

The grouping of the distraction procedures revealed that 114 distractions were applied to patients affected by dentofacial deformities (green). Thirty-one distraction procedures were performed in syndromal, syndrome-like, or cleft-related conditions (orange), 7 procedures were indicated after ablative oncologic surgery (blue), and only one alveolar ridge distraction was performed after maxillary trauma.

Transpalatal distraction (TPD) for the correction of transverse maxillary deficiency was the main distraction procedure. In 109 patients, gradual maxillary expansion with or without subsequent orthognathic surgery for the correction of an underlying dentofacial deformity was performed. In these patients, predominantly bone-borne distraction devices (n=94) were used as they offer different advantages when compared to tooth-borne orthodontic expansion appliances (Hyrax screws; n=15) [15]. TPD was also applied to a group of pediatric patients (n=8) improving the present deficiency before skeletal maturity [16].

**Table 1:** Overview of craniomaxillofacial distraction procedures from 2003 to 2016.

Region	Pathology	Type of DO (n=152)	Condition	Assessment
Craniofacial-midfacial DO (n=129)	Midfacial retrusion in craniofacial dysostosis	Frontofacial advancement (n=10)	Syndromal/cleft related	++
	Anophthalmia Tessier 4 cleft	Orbital (n=4)	Syndromal/cleft related	++
	Median craniofacial cleft syndrome	Nasal dorsum (n=1)	Syndromal/cleft related	++
	Transverse maxillary deficiency	TPD bone-borne (n=93)	Dentofacial deformity	++
	Transverse maxillary deficiency	Hyrax tooth-borne (n=15)	Dentofacial deformity	++
	Midfacial retrusion (M. Crouzon)	Le-Fort III (n=1)	Syndromal/cleft related	++
	Maxillary retrusion (CLP)	Le Fort I (n=2)	Syndromal/cleft related	+–
	Deficiency of premaxilla (CLP)	Maxillary segment (n=2)	Syndromal/cleft related	+–
	Traumatic defect	Alveolar crest (n=1)	Trauma	--
	Mandibular DO (n=23)	Postoperative defects after ablative surgery	Alveolar crest (n=6)	Oncologic
Orthognathic (crowding)		Symphysis (n=5)	Dentofacial deformity	++
Craniofacial microsomia		Ramus unilateral (n=6)	Syndromal/cleft related	+–
Syndromal deficiency (TCS)		Ramus/corpus bilateral (n=5)	Syndromal/cleft related	++
Neomandible		Alveolar crest (1)	Oncologic	++

CLP, Cleft lip and palate; TCS, Treacher-Collins syndrome.

Figure 1A–I illustrates a case series of a 39-year-old female patient affected by a typical dentofacial deformity: transverse mandibulomaxillary deficiency and skeletal class II malocclusion. Skeletal deficiency was corrected by initial mandibulomaxillary (“two-jaw”) distraction followed by orthodontic treatment and subsequent orthognathic surgery.

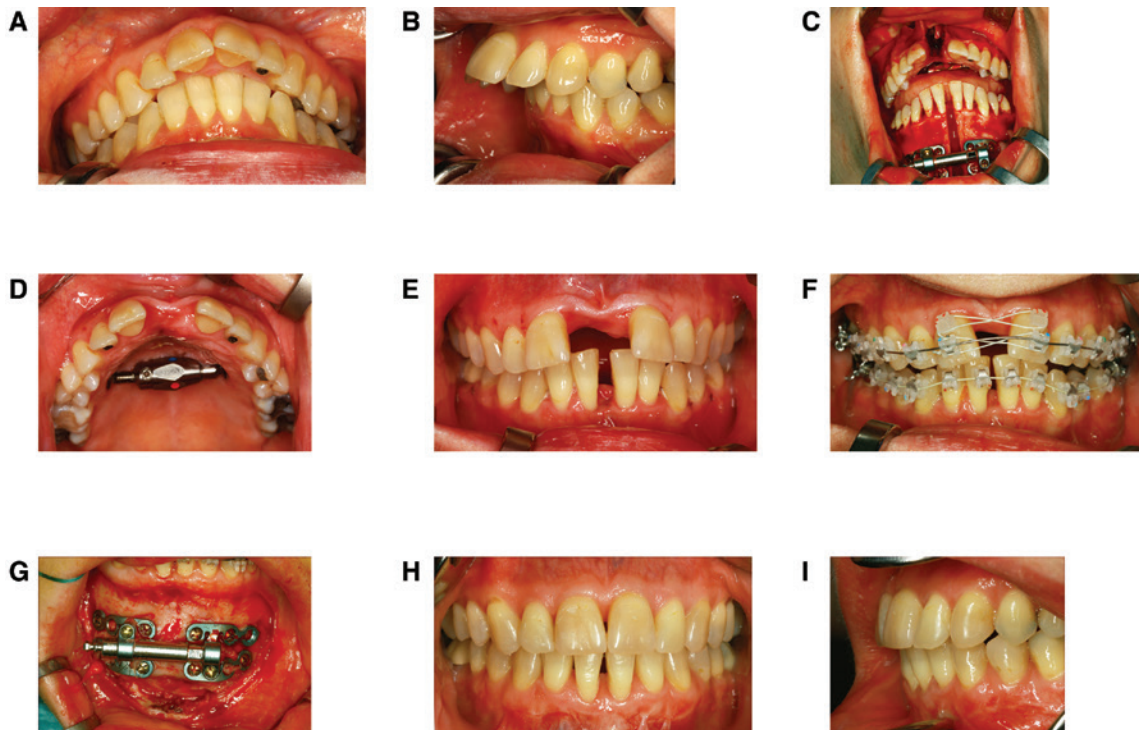
Patients affected by syndromal or cleft-related growth restrictions were the second group ( $n=31$ ) having a clear benefit of corrective surgery by craniomaxillofacial DO as demonstrated in Figure 2A–F.

In a 3-year-old boy affected by craniofacial dysostosis (M. Apert), severe midfacial retrusion after frontoorbital advancement in his first year of life was improved by computer-assisted frontofacial advancement of 17 mm by internal distraction devices. However, superimposition of predistraction and postdistraction data sets reveals a lack of advancement in the central midface. This is known to be one of the drawbacks of internal craniofacial distraction devices requiring additional corrective surgery. Staged surgeries and interdisciplinary treatment may also

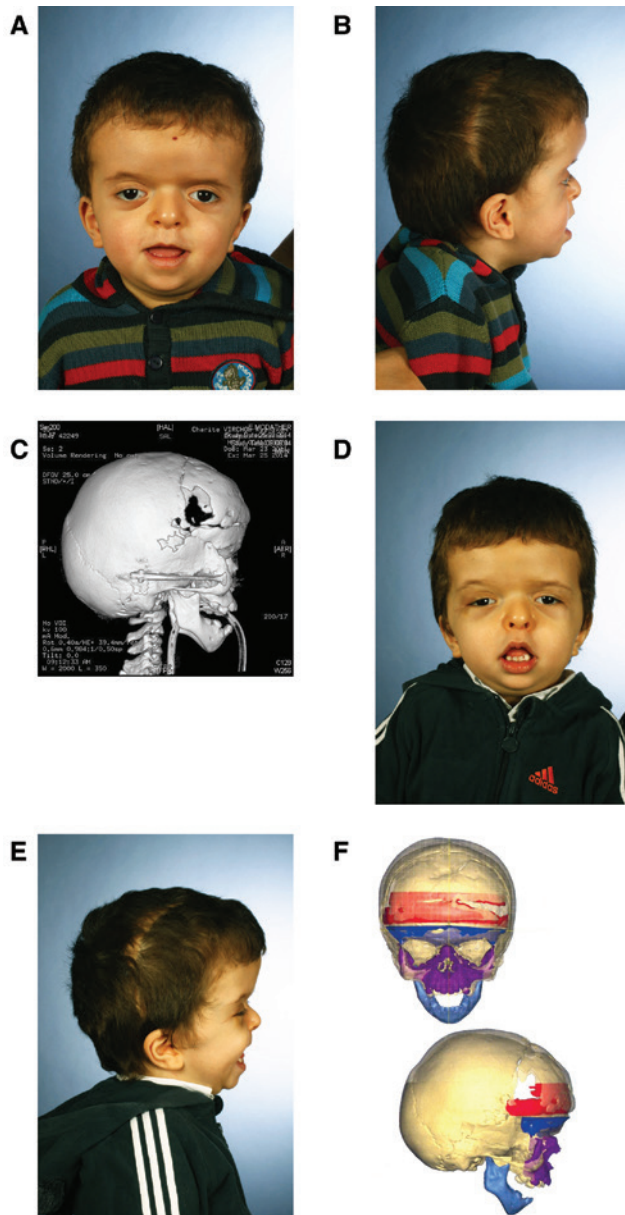
be required in rare conditions of growth restriction as demonstrated in Figure 3A–E.

An improvement of the lower facial deformity after resection of a dermoid fibroma of the left mandible in early childhood followed by microvascular fibular reconstruction at age 9 years was achieved in a 17-year-old patient by “upside-down insertion” of an alveolar ridge distraction device. Vertical augmentation of the “neomandible” will be followed by the insertion of dental implants for a contemporary prosthodontic rehabilitation of the patient. Gradual expansion proved to be helpful in the management of the hypertrophic and scarred soft tissues.

Overall, in the majority of patients, intended skeletal and soft-tissue expansion could be realized with a low rate of distraction-related complications. Therefore, and overall assessment of the results was predominantly positive (++). The activation of the devices and regular controls during the activation phase was not a real burden even in pediatric patients. Minor complications such as the loosening of devices or activation-related pain were

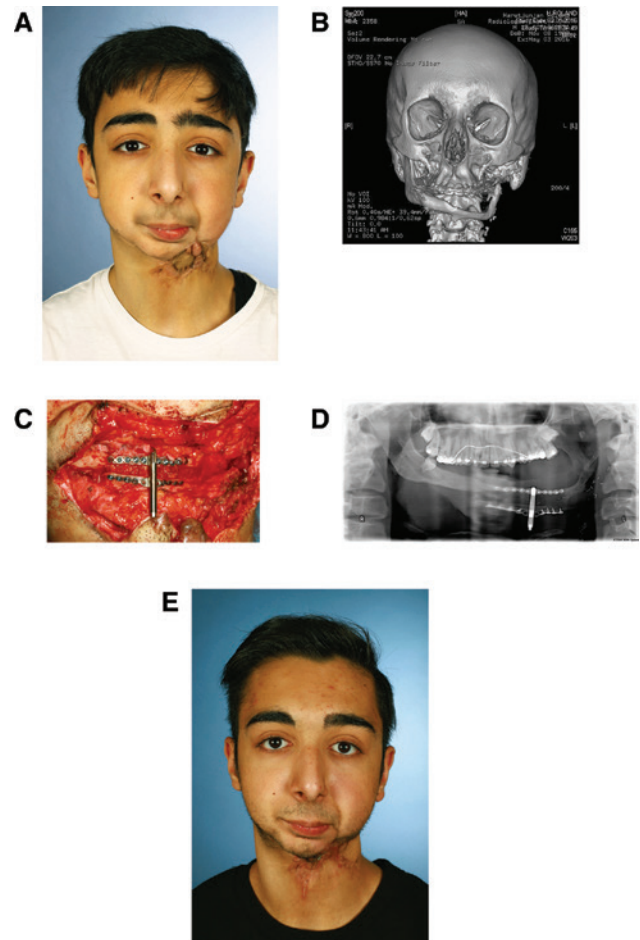


**Figure 1:** “Two-jaw distraction” for the correction of a transverse maxillary and mandibular deficiency (A) and corresponding skeletal class II malocclusion with increased overjet (B). Intraoperative situation after mounting two internal distraction devices to the upper and lower jaw. The desired amount of distraction is intraoperatively tested (C). Mandibulomaxillary expansion after the end of activation (D and E). The interdental gaps are closed by fixed orthodontic appliances during the consolidation phase (E and F). Complete bony consolidation in the symphyseal mandibular region at the time of device removal (G). Occlusal situation with physiologic overjet after additional orthognathic surgery 18 months after “two-jaw distraction” (H and I; orthodontic treatment by Dr. U. Jödecke, Fürstenwalde, Germany).



**Figure 2:** 3-year-old boy affected by craniofacial dysostosis (M. Apert) with midfacial retrusion. Frontoorbital advancement with overcorrection had been performed in the first year of life (A and B). After computer-assisted frontofacial advancement of 17 mm by internal distraction devices (C), midfacial retrusion is improved (D and E). However, superimposition of predistraction and postdistraction data sets (DePuy Synthes ProPlan CMF; Materialise, Leuven, Belgium) reveals a lack of advancement in the central midface (F; violet zone), which is known to be one of the drawbacks of internal craniofacial distraction devices requiring additional corrective surgery.

typically manageable in an outpatient setting. In the TPD group only in one mentally handicapped patient, relevant infection of the alveolar crest occurred leading to the failure of the procedure and permanent loss of teeth



**Figure 3:** 17-year-old patient with a lower facial deformity after resection of a dermoid fibroma of the left mandible in early childhood followed by microvascular fibular reconstruction at age 9 years (A and B), “upside-down insertion” and intraoperative testing of an alveolar ridge distraction device for vertical augmentation of the “neomandible” (C), OPTG 8 weeks after the end of activation with ongoing mineralization in the distraction zone (D), dental implants can be placed at time of device removal, and corresponding clinical situation (E). Hypertrophic scars have been resected during device insertion. Gradual expansion was helpful in the management of submandibular soft tissues.

and bone. In another patient who underwent alveolar ridge augmentation after traumatic tooth loss, failure occurred due to the fact that interdisciplinary prosthodontic treatment could not be realized within the appropriate time frame (–). In the group of syndromal patients, no relevant distraction-related complications occurred. In the group of patients who underwent maxillary distraction and unilateral mandibular distraction, strain during activation and long-term stability were the issues (+–). However, the majority of patients indicated that they would undergo a craniomaxillofacial distraction procedure again.

## Discussion

DO is an established method for the correction of skeletal deficiencies and is applicable to the whole skeleton [17, 18]. Almost 100 years after the first successful callus distraction in humans, the underlying physiology is better but not fully understood [19]. On the molecular level, there seems to be a complex differentiation of cells, which is mediated by mechanotransduction of the cytoskeleton corresponding to the “tension-stress effect” originally described by Ilizarov. As not only bone but also the surrounding soft tissues are expanded by gradual distraction, this principle can be regarded as an “*in vivo* bioreactor” and distraction histiogenesis seems to be a more appropriate term [20]. However, the successful application of this principle requires certain conditions. The stability in the distraction zone is crucial for the mineralization process during the consolidation phase as shown in experimental settings [12]. According to our personal experiences, the main factor for successful DO is stability; during the activation phase, there must be a characteristic haptic feedback of the tissues followed by stable conditions afterwards and then complete mineralization of the callus is likely to occur.

In orthognathic surgery, there seems to be a focus on classic osteotomies, as they provide fast and reliable results, and most of the skeletal discrepancies can be corrected by classic surgeries faster than by distraction procedures. In orthognathic patients, DO seems to be indicated if transverse maxillary deficiency is more than 6 mm and sagittal discrepancies exceed 12 mm. However, additional factors might have an influence when choosing the appropriate procedure (age, tissue conditions, patient’s compliance and comorbidities, and patient’s and surgeon’s preferences). In reconstructive surgery or syndromal patients when soft tissues should be addressed or growth impairment has to be managed, the principle of gradual expansion seems to be convincing; however, the decision is likely based on the individual situation [21, 22]. Due to the lack of appropriate studies, there is no evidence that one method is superior to the other so far.

Mandibular alveolar crest augmentation by vertical distraction was stopped after a small group of patients. The time frame for the prosthodontic rehabilitation was quite long, so the oncologic surgical protocol switched to primary microvascular reconstruction of ablative defects [23].

The role of mandibular DO in the management of craniofacial microsomia still remains unclear [24]. For the correction of dentofacial asymmetries, classic orthognathic procedures early after skeletal maturity seem to be

more convenient for the patients compared to distraction procedures, which is in accordance to the personal experiences [25]. However, in craniofacial dysostosis syndromes, such as M. Crouzon or M. Apert, which are characterized by severe growth impairment of the craniofacial skeleton, gradual expansion procedures by DO are able to correct functional and psychosocial impairment already at an early age and seem to have advantages when compared to classic osteotomies [26, 27].

However, it has to be pointed out that craniofacial distraction procedures normally are not able to correct the complex underlying pathologies within one setting and secondary corrections are typically needed. Nevertheless, a clear improvement of the initial situation can be achieved by creating additional bone stock and preparing the surrounding soft tissues for further surgical procedures within staged individualized treatment concepts [28]. Appropriate distraction devices for almost all craniomaxillofacial indications are commercially available or can be manufactured. If internal or external devices are selected, it is best decided on the individual situation. Contemporary computer-assisted workflows support planning, transfer, and evaluation of craniofacial distraction procedures [29, 30].

According to these personal experiences, craniomaxillofacial DO is certainly an option if severe skeletal deficiency or growth restriction is present or has to be expected. TPD can be recommended for the correction of transverse maxillary deficiency. Gradual frontofacial advancement is a powerful tool for the correction of craniomaxillofacial growth restriction within the individually staged interdisciplinary management of patients affected by syndromal craniosynostosis or comparable craniofacial anomalies.

## Conclusion

With regard to the overall number of patients who received craniomaxillofacial therapy in 14 years ( $n > 30,000$ ), craniomaxillofacial DO certainly plays a minor role (<1% of all patients). However, if severe growth restriction is present or has to be expected, craniomaxillofacial DO should be regarded as an additional reconstructive option for patients affected by craniofacial or dentofacial anomalies within an staged individual treatment plan.

**Acknowledgments:** Special thanks to Prof. Dr. E.J. Haberl (Pediatric Neurosurgery, University Bonn, Germany), who was involved in the craniofacial correction of patient 2;

Franz Hafner for his organizational skills in arranging the photodocumentation for this article; and Dr. Nadine Thieme (Charité Radiology Department/Head: Prof. Dr. B. Hamm) for providing DICOM datasets and CT scans in patients 2 and 3.

### Author Statement

**Research Funding:** Authors state no funding involved. **Conflict of interest:** Authors state no conflict of interest. **Informed consent:** Informed consent has been obtained from all individuals obtained in this study. **Ethical approval:** The research related to human use complied with all the relevant national regulations and institutional policies, was performed in accordance to the tenets of the Helsinki Declaration, and has been approved by the author's institutional review board or equivalent committee.

### Author Contributions

**Nicole Ernst:** Involved in most of the distraction procedures described in this review from 2007 on as surgical resident with regard to device insertion, device activation/removal and corresponding documentation. Retrospective evaluation of all patients who received transpalatal distraction procedures; concept of the manuscript and selection of illustrations.

**Nicolai Adolphs:** From 2006 as specialist, from 2009 on as consultant responsible for the treatment of patients affected by dentofacial and craniofacial anomalies; involved in the treatment of all patients that received distraction procedures; final revision of the manuscript before submission.

## References

- [1] Codivilla A. On the means of lengthening, in the lower limbs, the muscles and tissues which are shortened through deformity. *Clin Orthop Relat Res* 1994;4–9.
- [2] Wiedemann M. Callus distraction: a new method? A historical review of limb lengthening. *Clin Orthop Relat Res* 1996;291–304.
- [3] Honig JF, Grohmann UA, Merten HA. Facial bone distraction osteogenesis for correction of malocclusion: a more than 70-year-old concept in craniofacial surgery. *Plast Reconstr Surg* 2002;109:41–44.
- [4] Ilizarov GA. The tension-stress effect on the genesis and growth of tissues: part II. The influence of the rate and frequency of distraction. *Clin Orthop Relat Res* 1989;263–285.
- [5] Ilizarov GA. The tension-stress effect on the genesis and growth of tissues. part I. The influence of stability of fixation and soft-tissue preservation. *Clin Orthop Relat Res* 1989;249–281.
- [6] Ilizarov GA. Clinical application of the tension-stress effect for limb lengthening. *Clin Orthop Relat Res* 1990;8–26.
- [7] Snyder CC, Levine GA, Swanson HM, Browne EZ Jr. Mandibular lengthening by gradual distraction. Preliminary report. *Plast Reconstr Surg* 1973;51:506–508.
- [8] Michieli S, Miotti B. Lengthening of mandibular body by gradual surgical-orthodontic distraction. *J Oral Surg* 1977;35:187–192.
- [9] McCarthy JG, editor. *Distraction of the Craniofacial Skeleton*. 1st ed. New York: Springer, 1999.
- [10] McCarthy JG, Schreiber J, Karp N, Thorne CH, Grayson BH. Lengthening the human mandible by gradual distraction. *Plast Reconstr Surg* 1992;89:1–8; discussion 9–10.
- [11] Nada RM, Sugar AW, Wijdeveld MG, et al. Current practice of distraction osteogenesis for craniofacial anomalies in Europe: a web based survey. *J Craniomaxillofac Surg* 2010;38:83–89.
- [12] Adolphs N, Kunz C, Pyk P, Hammer B, Rahn B. Callus mineralization following distraction osteogenesis of the mandible monitored by scanning acoustic microscopy (SAM). *J Craniomaxillofac Surg* 2005;33:314–317.
- [13] Kunz C, Adolphs N, Buescher P, Hammer B, Rahn B. Distraction osteogenesis of the canine mandible: the impact of acute callus manipulation on vascularization and early bone formation. *J Oral Maxillofac Surg* 2005;63:93–102.
- [14] Kunz C, Adolphs N, Buescher P, Hammer B, Rahn B. Mineralization and mechanical properties of the canine mandible distraction wound following acute molding. *Int J Oral Maxillofac Surg* 2006;35:822–827.
- [15] Adolphs N, Ernst N, Menneking H, Hoffmeister B. Transpalatal distraction—state of the art for the individual management of transverse maxillary deficiency—a review of 50 consecutive cases. *J Craniomaxillofac Surg* 2014;42:1669–1674.
- [16] Adolphs N, Ernst N, Hoffmeister B, Raguse JD. Transpalatal distraction for the management of maxillary constriction in pediatric patients. *Ann Maxillofac Surg* 2015;5:44–48.
- [17] Hankemeier S, Bastian L, Gosling T, Krettek C. Principles of callus distraction. *Unfallchirurg* 2004;107:945–958.
- [18] Bell HW, Guerrero CA, editors. *Distraction Osteogenesis of the Facial Skeleton*. Hamilton, Ontario, Canada: BC Decker, Inc, 2007.
- [19] Van Sickels JE. Distraction osteogenesis: advancements in the last 10 years. *Oral Maxillofac Surg Clin North Am* 2007;19:565–574, vii.
- [20] Dhaliwal K, Kunchur R, Farhadieh R. Review of the cellular and biological principles of distraction osteogenesis: an in vivo bioreactor tissue engineering model. *J Plast Reconstr Aesthet Surg* 2016;69:e19–e26.
- [21] Labbe D, Nicolas J, Kaluzinski E, et al. Gunshot wounds: reconstruction of the lower face by osteogenic distraction. *Plast Reconstr Surg* 2005;116:1596–1603.
- [22] Super S. Distraction osteogenesis in the treatment of dentofacial deformities. *Alpha Omegan* 2009;102:68–73.
- [23] Adolphs N, Sproll C, Raguse JD, et al. Stable vertical distraction osteogenesis of highly atrophic mandibles after ablative tumour surgery of the oral cavity—a salvage pathway for mandibular reconstruction prior to oral rehabilitation with dental implants. *J Craniomaxillofac Surg* 2009;37:320–326.
- [24] Nagy K, Kuijpers-Jagtman AM, Mommaerts MY. No evidence for long-term effectiveness of early osteodistraction in hemifacial microsomia. *Plast Reconstr Surg* 2009;124:2061–2071.

- [25] Posnick JC. Surgical correction of mandibular hypoplasia in hemifacial microsomia: a personal perspective. *J Oral Maxillofac Surg* 1998;56:639–650.
- [26] Adolphs N, Haberl EJ. Kraniofaziale Chirurgie: state of the art. *Der MKG-Chirurg* 2012;5:266–278.
- [27] Arnaud E, Marchac D, Renier D. The treatment of craniosynostosis: indications and techniques. *Neurochirurgie* 2006;52:264–291.
- [28] Adolphs N, Ernst N, Menneking H, Hoffmeister B. Significance of distraction osteogenesis of the craniomaxillofacial skeleton—a clinical review after 10 years of experience with the technique. *J Craniomaxillofac Surg* 2014;42:966–975.
- [29] Adolphs N, Schulz M, Haberl HJ, Hoffmeister B. Computer-assistierte kraniofaziale Chirurgie. *Chirurg Praxis* 2016;80:663–676.
- [30] Adolphs N, Haberl EJ, Liu W, Keeve E, Menneking H, Hoffmeister B. Virtual planning for craniomaxillofacial surgery—7 years of experience. *J Craniomaxillofac Surg* 2014;42:e289–e295.

---

**Supplemental Material:** The article (DOI: 10.1515/iss-2016-0027) offers reviewer assessments as supplementary material.

## Reviewer Assessment

## Open Access

Nicole Ernst\* and Nicolai Adolphs

# Role of distraction osteogenesis in craniomaxillofacial surgery

DOI 10.1515/iss-2016-0027

Received October 11, 2016; accepted November 6, 2016

\*Corresponding author: Nicole Ernst,

Department of Craniomaxillofacial Surgery, Charité Universitaetsmedizin Berlin, Centre 9 for Traumatology and Reconstructive Surgery, Campus Virchow Klinikum

E-mail: nicole.ernst@charite.de

## Reviewers' Comments to Original Submission

### Reviewer 1: Thomas Mücke

Oct 24, 2016

<b>Reviewer Recommendation Term:</b>	Accept with Minor Revision
<b>Overall Reviewer Manuscript Rating:</b>	75
<b>Custom Review Question(s)</b>	<b>Response</b>
Is the subject area appropriate for you?	3
Does the title clearly reflect the paper's content?	4
Does the abstract clearly reflect the paper's content?	5 - High/Yes
Do the keywords clearly reflect the paper's content?	4
Does the introduction present the problem clearly?	4
Are the results/conclusions justified?	4
How comprehensive and up-to-date is the subject matter presented?	4
How adequate is the data presentation?	3
Are units and terminology used correctly?	4
Is the number of cases adequate?	4
Are the experimental methods/clinical studies adequate?	4
Is the length appropriate in relation to the content?	4
Does the reader get new insights from the article?	4
Please rate the practical significance.	5 - High/Yes
Please rate the accuracy of methods.	4
Please rate the statistical evaluation and quality control.	N/A
Please rate the appropriateness of the figures and tables.	4
Please rate the appropriateness of the references.	5 - High/Yes
Please evaluate the writing style and use of language.	4
Please judge the overall scientific quality of the manuscript.	4
Are you willing to review the revision of this manuscript?	Yes



**Comments to Author:**

The authors presented an article about the role of distraction osteogenesis in the maxillofacial field. As a review, this article is very interesting and provides important information about this operative procedure. I would like to raise some queries:

- 1) I would recommend providing more detailed information about two different indications: 1. orthognathic cases in which distraction osteogenesis is quite established and a routine procedure. 2. Reconstructive cases are not routine and need to be more emphasized.
- 2) If possible, a statistic about the osteogenic potence would be helpful, e.g. planned osteogenesis and achieved in length or even 3D volume if possible.
- 3) The authors concluded well and gave the correct practice in their conclusions. I would like to see this in 1-2 sentences in the introduction.

In conclusion, this well written article is appropriate for publication in ISS after minor revision.

**Reviewer 2 : Daniel Buchbinder**

Oct 12, 2016

<b>Reviewer Recommendation Term:</b>	Accept
<b>Overall Reviewer Manuscript Rating:</b>	75
<b>Custom Review Question(s)</b>	<b>Response</b>
Is the subject area appropriate for you?	3
Does the title clearly reflect the paper’s content?	4
Does the abstract clearly reflect the paper’s content?	4
Do the keywords clearly reflect the paper’s content?	4
Does the introduction present the problem clearly?	4
Are the results/conclusions justified?	4
How comprehensive and up-to-date is the subject matter presented?	3
How adequate is the data presentation?	3
Are units and terminology used correctly?	4
Is the number of cases adequate?	4
Are the experimental methods/clinical studies adequate?	N/A
Is the length appropriate in relation to the content?	4
Does the reader get new insights from the article?	2
Please rate the practical significance.	3
Please rate the accuracy of methods.	N/A
Please rate the statistical evaluation and quality control.	N/A
Please rate the appropriateness of the figures and tables.	4
Please rate the appropriateness of the references.	4
Please evaluate the writing style and use of language.	4
Please judge the overall scientific quality of the manuscript.	3
Are you willing to review the revision of this manuscript?	Yes
<b>Comments to Author:</b>	
This is a nice overview of distraction osteogenesis in CMF surgery.	

## Authors' Response to Reviewer Comments

Oct 31, 2016

Detailed response on reviewers comments on Ms No ISS-D-16-00027

Honoured reviewers!

Thank you very much for your real "fast track" review, your comments and suggestions on our manuscript about craniomaxillofacial distraction osteogenesis.

We would like to respond in detail to your suggestions respectively explain the open questions.

### **Reviewer 1:**

Query 1: Thank you for emphasizing this point- actually there are no clear general recommendations or consensus with regard to that issue and the techniques typically are individually adapted according to different influencing factors:

In orthognathic surgery there seems to be a focus on classic osteotomies as they provide fast and reliable results and most of the skeletal discrepancies can be corrected by classic surgeries faster than by distraction procedures. DO seems to be indicated if transverse maxillary deficiency is more than 6mm and sagittal discrepancies exceed 12 mm. However additional factors might have an influence when choosing the appropriate procedure (age, tissue conditions, patient's compliance and comorbidities, patient's and surgeon's preferences). So far there is no evidence that one method is superior to the other.

In reconstructive surgery or syndromal patients when soft tissues should be addressed or growth impairment has to be managed the principle of gradual expansion seems to be convincing – however the decision is likely based on the individual situation. Due to the lack of appropriate studies there is no evidence that one method is superior to the other so far.

We added this explanation to the discussion part.

Query 2: Osteogenic potency - we may refer to figures 1g, 2c which show the mineralised bony formations within the distraction zones clinically and radiological at the end of the consolidation time. A typical observation that was made in all patients when devices were removed – due to the individual situation a statistical model for the osteogenic potency is hard to provide – according to our personal experiences the main factor for successful DO ist stability – during activation phase there must be a characteristic haptic feedback of the tissues followed by stable conditions afterwards – then complete mineralization of the callus is likely to occur - we added this description to the discussion part.

Query 3:

We added this passage to the introduction:

Accordingly craniomaxillofacial distraction osteogenesis plays a minor role with regard to overall surgical procedures within the field however if severe growth restriction is present or has to be expected the principle of gradual tissue expansion should be regarded as an additional reconstructive option for patients affected by cranio- or dentofacial anomalies within an staged individual treatment plan.

### **Reviewer 2:**

Thank you very much for your assessment of our manuscript!

After correcting the manuscript we re-uploaded it as "review" as suggested.

Thank you for your support and best regards from Berlin  
The authors

## Reviewers' Comments to Revision

### Reviewer 1: Thomas Mücke

Nov 05, 2016

<b>Reviewer Recommendation Term:</b>	Accept
<b>Overall Reviewer Manuscript Rating:</b>	83
<b>Custom Review Question(s)</b>	<b>Response</b>
Is the subject area appropriate for you?	5 - High/Yes
Does the title clearly reflect the paper's content?	5 - High/Yes
Does the abstract clearly reflect the paper's content?	5 - High/Yes
Do the keywords clearly reflect the paper's content?	4
Does the introduction present the problem clearly?	5 - High/Yes
Are the results/conclusions justified?	4
How comprehensive and up-to-date is the subject matter presented?	4
How adequate is the data presentation?	4
Are units and terminology used correctly?	4
Is the number of cases adequate?	4
Are the experimental methods/clinical studies adequate?	N/A
Is the length appropriate in relation to the content?	4
Does the reader get new insights from the article?	5 - High/Yes
Please rate the practical significance.	5 - High/Yes
Please rate the accuracy of methods.	N/A
Please rate the statistical evaluation and quality control.	N/A
Please rate the appropriateness of the figures and tables.	5 - High/Yes
Please rate the appropriateness of the references.	5 - High/Yes
Please evaluate the writing style and use of language.	5 - High/Yes
Please judge the overall scientific quality of the manuscript.	4
Are you willing to review the revision of this manuscript?	Yes
<b>Comments to Author:</b>	
All queries were appropriately adressed. I recommend publication of this well written article.	