

[PICTURES IN CLINICAL MEDICINE]

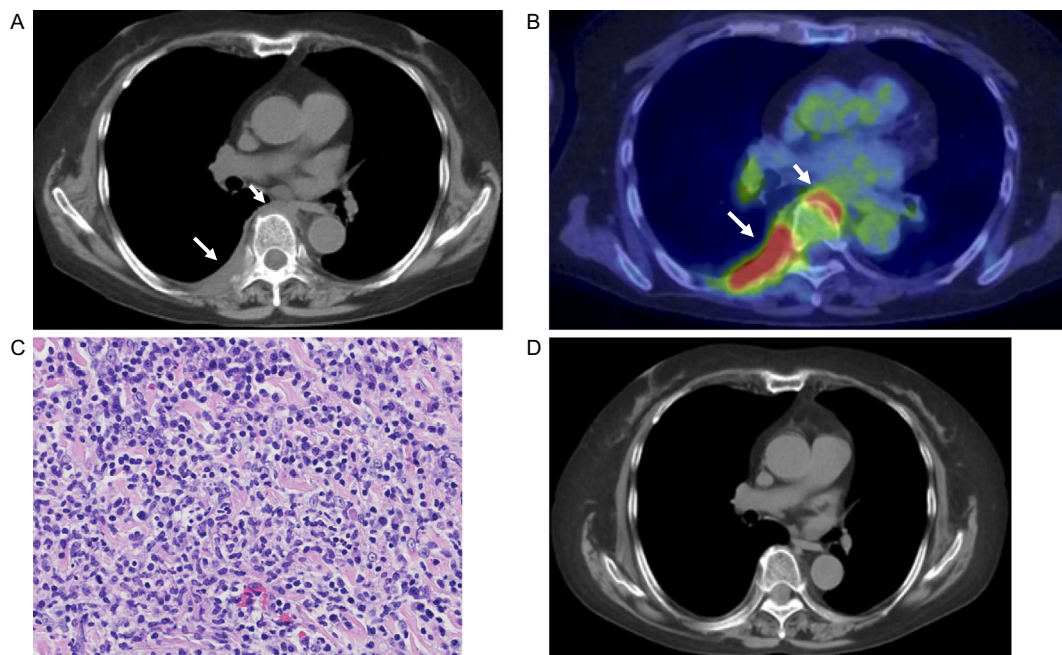
Juxta-vertebral Lesions Associated with Granulomatosis with Polyangiitis

Yumi Yoshida¹, Shinjiro Kaieda¹, Takuya Furuta² and Hiroaki Ida¹

Key words: granulomatosis with polyangiitis, juxta-vertebral lesions, rituximab

(Intern Med 58: 2587-2588, 2019)

(DOI: 10.2169/internalmedicine.2903-19)



Picture.

A 73-year-old woman was referred to our hospital for a fever, hoarseness, and progressive renal failure. A renal biopsy showed necrotizing extracapillary pauci-immune glomerulonephritis. A laryngoscopic examination revealed inflammation of the vocal cords. Myeloperoxidase antineutrophil cytoplasmic antibody (MPO-ANCA) levels were elevated. The patient met the Japanese criteria for the diagnosis of granulomatosis with polyangiitis (GPA). She was treated with high-dose steroids and cyclophosphamide, which resulted in amelioration of the clinical symptoms and improvement of the renal function. Glucocorticoid therapy was gradually tapered, and she developed a fever and back pain with another increase in the MPO-ANCA and C-reactive

protein (CRP) levels. Chest computed tomography demonstrated juxta-vertebral lesions that were 18-fluorodeoxyglucose positron emission tomography-positive (Picture A and B, arrows). A histological examination of the juxta-vertebral lesions showed nonspecific signs of inflammation and malignancy, and infectious diseases were ruled out (Picture C). Rituximab therapy improved the juxta-vertebral lesions and reduced the MPO-ANCA and CRP levels (Picture D). Juxta-vertebral lesions associated with GPA have rarely been reported (1, 2).

The authors state that they have no Conflict of Interest (COI).

¹Department of Medicine, Division of Respiriology, Neurology and Rheumatology Kurume University School of Medicine, Japan and ²Department of Pathology, Kurume University School of Medicine, Japan

Received: February 23, 2019; Accepted: March 1, 2019; Advance Publication by J-STAGE: May 22, 2019

Correspondence to Dr. Shinjiro Kaieda, shinkaieda@gmail.com

References

1. Ramirez GA, Della-Torre E, Campochiaro C, et al. Juxta-vertebral lesions in granulomatosis with polyangiitis. *Semin Arthritis Rheum* **46**: 356-360, 2016.
2. Barreto P, Pagnoux C, Luca L, et al. Dorsal prevertebral lesions in Wegener granulomatosis: report on four cases. *Joint Bone Spine* **78**: 88-91, 2011.

The Internal Medicine is an Open Access journal distributed under the Creative Commons Attribution-NonCommercial-NoDerivatives 4.0 International License. To view the details of this license, please visit (<https://creativecommons.org/licenses/by-nc-nd/4.0/>).

© 2019 The Japanese Society of Internal Medicine
Intern Med 58: 2587-2588, 2019