

## Acute eosinophilic appendicitis after generalized skin reaction due to unknown cause in a child: Case report and literature review

Maria Aggelidou,<sup>1</sup> Katerina Kambouri,<sup>1</sup> Maria Kouroupi,<sup>2</sup> Dimitrios Cassimos,<sup>3</sup> Soultana Foutzitzis,<sup>4</sup> Savas Deftereos<sup>4</sup>

<sup>1</sup>Department of Pediatric Surgery, Democritus University of Thrace, University Hospital of Alexandroupolis, Dragana, Alexandroupolis; <sup>2</sup>Department of Pathology, Democritus University of Thrace, University Hospital of Alexandroupolis, Dragana, Alexandroupolis; <sup>3</sup>Department of Pediatrics, Democritus University of Thrace, University Hospital of Alexandroupolis, Dragana, Alexandroupolis; <sup>4</sup>Department of Radiology, Democritus University of Thrace, University Hospital of Alexandroupolis, Dragana, Alexandroupolis, Greece

### Abstract

Acute eosinophilic appendicitis (AEA) is a rare variant of appendix inflammation possibly linked to allergy. Histopathological evidence of eosinophilic infiltration of the *muscularis propria* and edema separating the muscle fibers is the gold standard for the diagnosis. Here, we report a case of a young boy with AEA following a skin reaction of possible allergic origin. A 6-year-old male was presented to the emergency department with a two-day diffuse abdominal pain and tenderness in the right lower quadrant. A possible allergic reaction had occurred five days before as a pruritic rash. There was no history of allergy and the stool examination was negative for parasites. The initial diagnosis was acute appendicitis, and appendectomy was performed. The histopathological diagnosis was AEA. Further studies on the proper diagnostic and treatment approach of AEA before surgery are required.

### Introduction

Acute appendicitis (AA) is the most common surgical emergency in the pediatric population worldwide.<sup>1</sup> Luminal obstruction of the appendix due to fecalith, lymphoid hyperplasia, parasite or tumor is considered responsible for the development

of AA.<sup>2</sup> Aravindan first reported in 1997<sup>3</sup> and further studied<sup>4</sup> acute eosinophilic appendicitis (AEA) as a rare variant of appendix inflammation linked possibly to type I hypersensitivity. AEA's characteristics are the acute presentation, the dilated appendix as confirmed by abdominal ultrasound or/and computed tomography and the histopathological findings of eosinophilic infiltration of the *muscularis propria* with accompanying edema separating muscle fibers.<sup>4</sup> There is a limited literature of the AEA and there are only four cases of children (in one of them the AEA was caused by *Enterobius vermicularis*) with no history of allergy.<sup>5-7</sup> We present a case of a 6-year-old boy with AEA directly related to a possible allergic manifestation five days prior to admission.

### Case Report

A 6-year-old male presented in the emergency department with a two-days diffuse abdominal pain and tenderness in the right lower quadrant. The pain did not associate with fever, anorexia or nausea. The parents reported that five days before, a pruritic rash had appeared all over the child's body. The pediatrician diagnosed allergic dermatitis and recommended desloratadine for three days. No hematological tests were performed then because there was no previous history of allergy or atopy in the child and there was no relation to exposure to possible allergens. The last day of treatment the rash subsided but the child developed mild abdominal pain that worsened within the following two days. The physical examination revealed Mcburney and Rovsing positive signs. The child's history didn't reveal any chronic symptoms such as abdominal distension, diarrhea, failure to thrive or weight loss. Routine hematological tests demonstrated a white blood cell (WBC) count of  $17.32 \times 10^3$  cells/mL (normal ranges  $3.5 \times 10^3$  cells/mL- $10.8 \times 10^3$  cells/mL) with differential count: neutrophils: 75.6% ( $n=13.08$  K/mm<sup>3</sup>), lymphocytes: 17% ( $n=2.95$  K/mm<sup>3</sup>), monocytes: 6.2% ( $n=1.1$  K/mm<sup>3</sup>), eosinophils: 1% ( $n=0.18$  K/mm<sup>3</sup>) and basophils: 0.2% ( $n=0.04$  K/mm<sup>3</sup>) and CRP level 0.02 mg/dL. Other biochemical and serological tests were unremarkable. Abdominal ultrasonography showed a dilated appendix, the diameter of the largest part was 7.6 mm with a minimal amount of fluid in the pericecal area (Figure 1). Based on the findings the initial diagnosis was AA and an open appendectomy was performed. The appendix was edematous without any sign of supuration. The specimen was sent for

Correspondence: Maria Aggelidou, Department of Pediatric Surgery, Democritus University of Thrace, University Hospital of Alexandroupolis, Dragana, Alexandroupolis 68100, Greece.  
Tel.: +30.6944541143.  
E-mail: marartem@yahoo.gr

Key words: Acute eosinophilic appendicitis; Allergy; Children.

Contributions: the authors contributed equally.

Conflict of interest: the authors declare no potential conflict of interest.

Funding: none.

Received for publication: 3 June 2019.  
Revision received: 29 August 2019.  
Accepted for publication: 30 August 2019.

This work is licensed under a Creative Commons Attribution NonCommercial 4.0 License (CC BY-NC 4.0).

©Copyright: the Author(s), 2019  
Licensee PAGEPress, Italy  
Clinics and Practice 2019; 9:1177  
doi:10.4081/cp.2019.1177

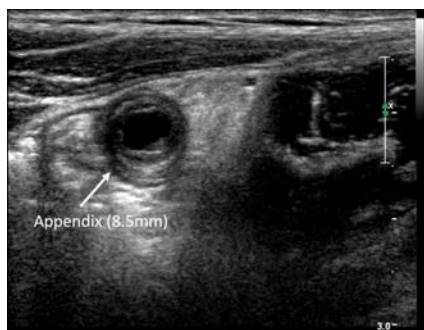
histopathological examination, which revealed eosinophilic infiltration (>25 eosinophils per-high-power-field) and edema in *muscularis propria*. No parasites were observed. The histopathological diagnosis was AEA (Figure 2). Due to this diagnosis, repeated stool tests for parasites were obtained, which were all negative. The patient was discharged on the fifth postoperative day. Our advice was to be evaluated by a pediatric allergist.

In the follow-up period of one year the course of the child's health was uneventful without any symptoms of abdominal pain, so we didn't think it was necessary to perform gastrointestinal endoscopy and biopsy. Simultaneously he was also followed up by the pediatric allergist and no signs or symptoms of allergic conditions/diseases as rhinitis, asthma, urticaria, angioedema were recorded. Furthermore, repeated blood tests with total IgE measurements and eosinophils in full blood count were within normal range. Specific IgEs were considered as unnecessary to be evaluated because there was no relation of any kind of symptoms to allergens exposure.

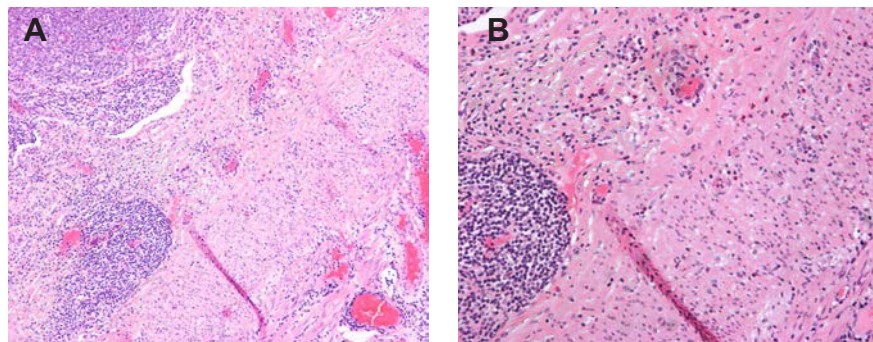
Written informed consent was provided by the patient's parents to have the case details and any accompanying images published.

## Discussion

The dominant theory regarding the etiology and pathogenesis of the AA is the luminal obstruction of the vermiform appendix by fecalith, lymphoid hyperplasia, foreign body or tumor which causes distention and increased pressure within the lumen, followed by ischemic changes of the appendiceal mucosa and invasion by bacteria.<sup>2</sup> Several studies showed a correlation between parasitic infestation by *Strongyloides stercoralis* or *E. vermicularis* and luminal obstruction.<sup>6,8-10</sup> Bhangu *et al.* suggested that factors such as environmental, geographical, dietary, genetic predisposition and infections are related to the development of AA.<sup>1</sup> First Aravindan *et al.* reported a variation of AA where an amount of eosinophils were found in *muscularis propria* of the appendix causing edema and splitting of muscle fibers.<sup>3</sup> Considering that eosinophils may be present in the *lamina propria* and *submucosa*, but not in the *muscularis propria*, the authors suggested the possibility of a type I hypersensitivity and proposed the term Eosinophilic Appendicitis to describe it.<sup>3</sup> This situation



**Figure 1. Abdomen ultrasonography image of the dilated appendix. Diameter: 7.6 mm.**



**Figure 2. Appendicitis with increased number of eosinophils, infiltrating the muscle layer of the organ. A) Magnification 10×; B) Magnification 20×.**

can later cause mucosa damage, entry of bacteria and neutrophil infiltration.<sup>3,4</sup> Kolar *et al.* reported the same conclusion in a study assessing the eosinophil counts in various histopathological groups.<sup>11</sup> A study carried out by Harlak *et al.* showed that atopy incidence in patients with AA was significantly higher compared with control group, however no correlation was found between atopy and eosinophilic infiltration of the *muscularis propria*.<sup>12</sup> Local allergic reaction to barium resulting in AEA without any other signs of allergy was reported by Manuel *et al.*<sup>13</sup> In addition, Shrestha *et al.* reported that AEA was commonly seen in the age group of 21 to 40-years-old.<sup>14</sup> In the literature there are only four cases of children (age <14 years) with AEA. In one of them, a 12-year-old female, the cause of AEA was *E. vermicularis*.<sup>6</sup> In addition, a 14-year-old male was presented as recurrent abdominal pain and the histopathological diagnosis was AEA.<sup>5</sup> Two cases were reported by Kumar *et al.* that presented as acute and subacute appendicitis.<sup>7</sup> None of these children had a history of allergy. In this case report, we describe a young boy with no previous history of allergy, with histopathological findings of AEA and a pruritic skin rash five days prior to admission. This is the first pediatric case worldwide reporting a possible correlation between an allergic manifestation and AEA. As we didn't perform upper and lower gastrointestinal (GI) endoscopy and we didn't take biopsies from the GI tract of this child, we cannot be certain whether the eosinophilic inflammation was limited to the appendix and did not involve other segments of the GI tract. However, according to the literature eosinophilic gastroenteritis (EGE) has most often a more dramatic presentation that vary depending on the extend and the depth of inflammation through the intestinal wall. The mucosal form of EGE (most common variant) is characterized by vomiting, abdominal pain, and diarrhea, blood loss in stools, iron deficiency anemia,

malabsorption and protein losing enteropathy. The muscularis form is characterized by infiltration of eosinophils predominantly in muscle layer leading to intermittent obstructive symptoms and with complications like aspiration and perforation. Serosal form is characterized by exudative ascitis with intense peripheral eosinophilia.<sup>15</sup> Our patient didn't have any of the above symptoms prior or after the operation, we didn't consider it necessary to perform a GI endoscopy.

A previous report mentioned that AEA may be related to EGE where the eosinophilic infiltration can affect any part of the gastrointestinal tract.<sup>16</sup> The differences between AEA and EGE are the following: i) EGE is more common among children younger than five-year-old while the AEA commonly seen in older patients;<sup>17</sup> ii) EGE has usually more dramatic presentation with abdominal pain, abdominal distention, vomiting, diarrhea, malabsorption, weight loss, eosinophilic ascites and can lead to serious complications such as intestinal obstruction and perforation;<sup>17</sup> iii) many patients (52% of children and 41.8% of adults) with EGE have a history of allergy;<sup>17</sup> and iv) EGE involves peripheral blood eosinophilia in contrast with the AEA where the eosinophils count is normal.<sup>16</sup>

Therefore, AEA should be evaluated as a variant of AA rather than an extension of eosinophilic gastroenteritis.<sup>15</sup>

According to the literature, the AEA is presented as uncomplicated AA however the conservative antibiotic therapy has no effect and the initial symptoms persist.<sup>18,19</sup> Due to the increased WBC and the abdomen ultrasonography findings of the dilated appendix, we did not attempt a conservative treatment and performed an appendectomy immediately.

## Conclusions

The AEA is a rare entity which until today is diagnosed only after an appendectomy by the histopathological findings. There is no appropriate treatment although Kanthikar *et al.* suggested that steroids, sodium chromoglycate, ketotifen, montelukast may be medical alternatives.<sup>20</sup> Further studies on the proper diagnostic and treatment approach of AEA before surgery are required.

## References

1. Bhangu A, Soreide K, Di Saverio S, *et al.* Acute appendicitis: modern under-

- standing of pathogenesis, diagnosis, and management. *Lancet* 2015;386:1278-87.
2. Carr NJ. The pathology of acute appendicitis. *Ann Diagn Pathol* 2000;4:46-58.
  3. Aravindan KP. Eosinophils in acute appendicitis: possible significance. *Indian J Pathol Microbiol* 1997;40:491-8.
  4. Aravindan KP, Vijayavaghvan D, Manipadam MT. Acute eosinophilic appendicitis and the significance of eosinophil-Edema lesion. *Indian J Pathol Microbiol* 2010;53:258-61.
  5. Jain G, Kanetkar SR. Eosinophilic appendicitis: Case report of five cases & review of literature. *J Med Res Pract* 2013;2:208-11.
  6. Garza-Serna U, Ramos-Mayo A, Lopez-Garnica D, et al. Eosinophilic acute appendicitis and intra-abdominal granuloma caused by *Enterobius vermicularis* in a pediatric patient. *Surg Infect Case Rep* 2016;1:103-5.
  7. Kumar V, Anuradha, Gupta N. Acute eosinophilic appendicitis: A prospective study in consecutive 400 appendectomy cases. *J Dent Med Sci* 2017;16:87-90.
  8. Cruz DB, Friedrich BK, Fontanive Junior V, da Rocha VW. Eosinophilic acute appendicitis caused by *Strongyloides stercoralis* and *Enterobius vermicularis* in an HIV-positive patient. *BMJ Case Rep* 2012;2012:bcr0120125670.
  9. Rha B, Kelly DR, Shimamura M. Eosinophilic appendicitis attributable to *Strongyloides* infection in a pediatric renal transplant patient. *J Pediatric Infect Dis Soc* 2013;2:274-7.
  10. Egeci T, Okudan M, Taskesen F, et al. Acute eosinophilic appendicitis: an unusual variant of appendix inflammation. *Kolon Rektum Hast Derg* 2013;23:107-10.
  11. Kolar A, Patil AM, Agarwal V, et al. The significance of mast cells and eosinophils counts in surgically resected appendix. *J Interdiscipl Histopathol* 2014;2:150-3.
  12. Harlak A, Gulec M, Menten O, et al. Atopy is a risk factor for acute appendicitis? A prospective clinical study. *J Gastrointest Surg* 2008;12:1251-6.
  13. Manuel DL, Neufeld M, Piechura LM, et al. Barium-induced allergic appendicitis: A case report. *J Case Rep Image Surg* 2017;3:25-8.
  14. Shrestha R, Ranabhat SR, Tiwari M. Histopathologic analysis of appendectomy specimens. *J Pathol Nepal* 2012;2:215-9.
  15. Rajeshwari K, Dravid NV, Karibasappa GN, Surana A. Acute eosinophilic appendicitis: case report of three cases with brief review of literature. *Ann Appl Bio-Sci* 2015;2:18-21.
  16. Pineton de Chambrun G, Desreumaux P, Cortot A. Eosinophilic enteritis. *Dig Dis* 2015;33:183-9.
  17. Papadopoulou A, Koutri E. Eosinophilic gastrointestinal diseases in childhood. *Ann Nutr Metab* 2018;73:18-28.
  18. Yaeger AA, Cheng PM, Tatishchev S, Whang G. Acute eosinophilic appendicitis: a radiologic-pathologic correlation. *Clin Imaging* 2018;51:337-40.
  19. Takabatake K, Imanishi T, Yoshikawa T. Acute eosinophilic appendicitis simulating uncomplicated appendicitis. *BMJ Case Rep* 2018;11:e227178.
  20. Kanthikar SN, Nikumbh DB, Desale SS. Primary eosinophilic obliterative appendicitis. *Online J Health All Sci* 2014;13:1-2.